

MISS. NAYNEE MALVIYA

33 YEARS /FEMALE

BOB

01-4-2024

Height: 158 Cms

Weight: 54 Kg

BP: - 108/70 mmhg

Pulse: - 79/- Regular

BMI: - 21.6 kg/m²

EYE: - NORMAL

The Medical Examiner should record the findings under one of the following categories:-

FIT

UNFIT on account of



Dr. D. S. Chhabra
M.D.

DR. D.S. CHHABRA

MBBS. MD.

MRS. NAYNEE MALVIYA
BANK OF BARODA33 Years /F
01-04-2024**BIOCHEMISTRY**

Test Name	Results	Normal Range
SERUM BILIRUBIN	:-	
TOTAL BILIRUBIN	0.83	0 - 1 mg/dl
DIRECT BILIRUBIN	0.12	<0.25 mg/dl
INDIRECT BILIRUBIN	0.71	< 1.0 mg/dl
S.G.O.T	23.0	0 - 45 IU/L
S.G.P.T	18.0	0 - 45 IU/L
ALKALINE PHOSPHATE	92.0	Adult - 42 - 128 IU/L Child - 150 - 630 IU/L
TOTAL PROTEIN	6.00	6.0 to 8.0 g/dl
ALBUMIN	3.83	3.2 to 5.0 g/dl
GLOBULIN	2.17	1.9 to 3.5
A:G RATIO	1.76	1.2 TO 2.3
GAMA GT	29.0	5 - 43 Iu/l

Dr. POOJA PRAPANNA
MD
DR. POOJA PRAPANNA
M.D.

MRS. NAYNEE MALVIYA
BANK OF BARODA33 Years /F
01-04-2024**LIPID PROFILE**

Test Name	Results	Normal Range
TOTAL LIPIDS	414	400 - 700 mg/dl
CHOLESTROL	136.0	<200 mg/dl- Desirable 200 - 239 mg/dl - Borderline High >240 Mg/dl High
HDL CHOLESTROL	44.0	35- 60 mg/dl
TRIGLYCERIDE	92.0	<150 mg/dl Normal 150 - 199 mg/dl Borderline High 200 - 499 mg/dl High
LDL CHOLESTROL	73.6	<100 mg/dl Optimal 100- 129 mg/dl Borderline high 160 - 189 mg/dl High
VLDL CHOLESTROL	18.4	<40 mg/dl
RISK RATIO	3.09	

Dr. POOJA PRAPANNA
MD
DR. POOJA PRAPANNA
M.D.

Note :- All pathological tests have technical and biological limitations. Please correlate clinically as well as with other investigative findings.
A review should be requested in case of any disparity. This report is not valid for medicolegal purpose.

MRS. NAYNEE MALVIYA
BANK OF BARODA33 Years /F
01-04-2024

Test Name	Results	Normal Range
-----------	---------	--------------

HAEMATOLOGY PROFILE

BLOOD GROUP	: -
"ABO " GROUP	"B"
Rh (D) Factor	Positive

(Cross matching & recheck of Blood Group is mandatory before any transfusion)

SEROLOGY PROFILE

HBsAg	Non Reactive
-------	--------------

* Test done by screening methods.
Requires confirmation at referral centre.

BIOCHEMISTRY

FASTING BLOOD SUGAR	70.0	70 - 110 mg/dl
P.P. BLOOD SUGAR	80.0	upto 140 mg/dl
BUN	8.0	5 - 21 Mg/dl
CREATININE	0.82	0.6 - 1.4 mg\dl
URIC ACID	3.42	2.5 - 6.8 mg\dl
CALCIUM	8.50	8.5 - 10.5 mg\dl

Dr. POOJA PRAPANNA
MD

DR. POOJA PRAPANNA

M.D.

MRS. NAYNEE MALVIYA
BANK OF BARODA33 Years /F
01-04-2024**URINE EXAMINATION**

Test Name	Results	Normal Range
PHYSICAL EXAMINATION		
Quantity	30 ml	.
Colour	Pale Yellow	.
Appearance	Clear	.
Deposits	Absent	.
Specific Gravity	1.015	.
Reaction	Acidic	.
CHEMICAL EXAMINATION		
Albumin	Nil	.
Sugar	Nil	.
Ketones	Absent	.
Bile Pigments	Negative	.
Bile Salt	Negative	.
Hematuria	Negative	.
MICROSCOPIC EXAMINATION		
Pus Cells	1- 2 /hpf	.
Red Blood Cells	Nil/hpf	.
Epithelial Cell	1 - 2 /hpf	.
Crystals	Nil	.
Casts	Absent	.

Dr. POOJA PRAPANNA
MD

DR. POOJA PRAPANNA

M.D.

4D SONOGRAPHY • COLOR DOPPLER • ECHO • PATHOLOGY • DIGITAL X-RAY & OPG • TMT • ECG • HOLTER

MISS. NAYNEE MALVIYA

33 Yrs./F

BOB

01st April, 2024

X-RAY CHEST PA VIEW

Bony cage is normal.

Trachea is central. C.P. angles are clear.

Cardiac contour and cardiothoracic ratio are normal.

Lung fields are clear.

DR.D.S.CHHABRA.

M.D.

4D SONOGRAPHY • COLOR DOPPLER • ECHO • PATHOLOGY • DIGITAL X-RAY & OPG • TMT • ECG • HOLTER

MISS. NAYNEE MALVIYA

33 Yrs/F

BOB

01st April, 2024

ABDOMINAL SONOGRAPHY

Liver is of normal size, shape, has smooth margins & regular contours and the parenchyma reveals normal echostructure. No focal lesion.

Gall bladder is of normal size, shape, has thin walls & the contents are clear fluid. No evidence of any calculus. Biliary tree is undilated.

Pancreas is normal, no focal / diffuse pathology. Spleen is normal.

Both kidneys are normal in size [measure about 11 cms. in length], shape and echostructure. No calculus in both. The collecting system and ureter on both side are undilated.

Urinary bladder is normal in size, shape and has thin walls.

Uterus is of normal size [measures about 8 x 5 x 3.5 cms. in diam.] and is normal in shape. The uterine outlines are smooth & regular and the myometrial & endometrial echopattern is normal. No mass.

Both ovaries are normal in size, shape and echostructure.

No adnexal / pelvic mass or cyst. No pelvic collection.

There is no ascitis. No obvious abdominal lymphadenopathy. No sub / supra diaphragmatic pathology on either side.

IMPRESSION :

Normal study.

**DR.D.S.CHHABRA.**

M.D.

MRS. NAYNEE MALVIYA

33 Years /F

BANK OF BARODA

01-04-2024

HEAMOGRAM

Test Name	Results	Normal Range
Haemoglobin (HB)	10.0	11 - 16 gm%
R.B.C. Count	4.15	3.8 - 4.8 milli./cu.mm
PCV	33.8	36 - 46 %
MCV	81.45	80 - 98 fl
MCH	24.10	27 - 32 pg
MCHC	29.59	31.5 - 34.5 %
TOTAL WBC COUNT	7,600	4,000 to 11,000 /cu.mm
DIFFERENTIAL WBC COUNT	.	
Neutrophils	56	40 - 75 %
Lymphocytes	40	20 - 40 %
Monocytes	02	02 - 08 %
Eosinophils	02	01 - 05 %
Basophils	00	00 - 01 %
PLATELET COUNT	3.33	1.5 - 4 Laes/cu.mm.
E.S.R	12	M- 0-10 at the end of 1 hr. F- 0-20 at the end of 1 hr

DR. POOJA PRAPANNA
MD

DR. POOJA PRAPANNA

M.D.



LABORATORY REPORT



Name : NAYNEE MALVIYA	Sex/Age : Female / 33 Years	Case ID : 40401600111
Ref. By :	Dis. At :	Pt. ID :
Bill. Loc. : UNIQUE DIAGNOSTIC CENTRE INDORE		Pt. Loc. :
Reg Date and Time : 01-Apr-2024 13:16	Sample Type : Serum	Mobile No. :
Sample Date and Time : 01-Apr-2024 13:16	Sample Coll. By : non	Ref Id1 :
Report Date and Time : 01-Apr-2024 15:42	Acc. Remarks : -	Ref Id2 :

TEST	RESULTS	UNIT	BIOLOGICAL REF RANGE	REMARKS
Thyroid Function Test				
Trilodothyronine (T3) <small>CMIA</small>	106.66	ng/dL	58 - 159	
Thyroxine (T4) <small>CMIA</small>	8.23	µg/dL	5.5 - 11.0	
TSH <small>CMIA</small>	2.06	µIU/mL	0.4 - 4.2	

INTERPRETATIONS

- Circulating TSH measurement has been used for screening for euthyroidism, screening and diagnosis for hyperthyroidism & hypothyroidism. Suppressed TSH (<0.01 µIU/mL) suggests a diagnosis of hyperthyroidism and elevated concentration (>7 µIU/mL) suggest hypothyroidism. TSH levels may be affected by acute illness and several medications including dopamine and glucocorticoids. Decreased (low or undetectable) in Graves disease. Increased in TSH secreting pituitary adenoma (secondary hyperthyroidism), PRTH and in hypothalamic disease thyrotropin (tertiary hyperthyroidism). Elevated in hypothyroidism (along with decreased T4) except for pituitary & hypothalamic disease.
- Mild to modest elevations in patient with normal T3 & T4 levels indicates impaired thyroid hormone reserves & incipient hypothyroidism (subclinical hypothyroidism).
- Mild to modest decrease with normal T3 & T4 indicates subclinical hyperthyroidism.
- Degree of TSH suppression does not reflect the severity of hyperthyroidism, therefore, measurement of free thyroid hormone levels is required in patient with a suppressed TSH level.

CAUTIONS

Sick, hospitalized patients may have falsely low or transiently elevated thyroid stimulating hormone. Some patients who have been exposed to animal antigens, either in the environment or as part of treatment or imaging procedure, may have circulating antianimal antibodies present. These antibodies may interfere with the assay reagents to produce unreliable results.

TSH ref range in pregnancy

First trimester
Second trimester
Third trimester

Reference range (microIU/ml)

0.24 - 2.00
0.43-2.2
0.8-2.5

Note:(LL-VeryLow,L-Low,H-High,HH-VeryHigh ,A-Abnormal)

Dr. Chetana Bora

MD Pathology

Page 1 of 2

Dr. A Mishra

M.D. Microbiology

Dr. Soma Yadav

M.D. (Pathology)

Printed On : 01-Apr-2024 15:53

Neuberg Diagnostics Private Limited

Laboratory : 3/3, South Tukoganj, Gokuldas Hospital Road, Near Madhumilan Chouraha, Indore - 452001 Madhya Pradesh ☎ 0731-4964961 / 62, 9713963333

neuberg.indore@supratechlabs.com

Regd. Office : Plot No. 7, Industrial Estate, Rajiv Gandhi Salai, Perungudi, Chennai - 600096, Tamil Nadu, India. | CIN - U85300TN2017PTC114099

www.neubergsupratech.com

DR. PRIYANK JAIN

M.D.,D.M.

CONSULTANT CARDIOLOGIST

UNIQUE DIAGNOSTIC CENTRE

45-B, Jaora Compound,
Opp. M.Y.Hospital, M.Y.H. Road,
INDORE - 452 001. (M. P.).
Phone : 2704118. 4082228

ECHOCARDIOGRAPHY REPORT

NAME : MRS. MAHIMA SHARMA Age : 24 Yrs./ F
REFERRED BY : BOB Date : 01st April, 2024

ECHOCARDIOGRAPHIC OPINION

INTERPRETATION :-

- ** No RWMA.
- ** Good biventricular function. LVEF : 60 %.
- ** Normal cardiac valves, healthy pericardium.
- ** Grade I diastolic dysfunction.

Dr. PRIYANK JAIN
MBBS, MD, DM,
Reg. No. 19547



DR. PRIYANK JAIN. M.D.,D.M.

TWO DIMENSIONAL ECHOCARDIOGRAPHY

M Mode examination revealed normal movement of both mitral leaflets during diastole.

No SAM or mitral valve prolapse is seen.

Mitral valve opening is normal. No evidence of mitral valve prolapse is seen.

Tricuspid valve is normal, pulmonary valve is normal, aortic root is normal in size, dimensions of left atrium and left ventricle are normal.

Aortic cusps are not thickened and enclosure line is central.

Aortic valve has three cusps and its opening is not restricted.

2 - D imaging in PLAX, SAX and apical views revealed a normal sized left ventricle.

Movement of septum, anterior, posterior, inferior and lateral walls is normal. Global LVEF is 60 %.

Right atrium and right ventricle are normal in size.

Tricuspid valve leaflets move normally.

Pulmonary valve is normal.

Interatrial and interventricular septa are intact.

No intracardiac mass or thrombus is seen.

No pericardial pathology is observed.

भारत सरकार



नायनी मालवीय
Naynee Malviya

जन्म वर्ष / Year of Birth : 1990
महिला / Female



7918 3136 2830

आधार - आम आदमी का अधिकार

Dr. D. S. Chhabra
M.B.B.S., M.A.
Reg. No. 3087



Paunje

आधार

भारतीय विशिष्ट पहचान प्राधिकरण
UNIQUE IDENTIFICATION AUTHORITY OF INDIA

पता: D/O बट्टी लाल मालवीय, मकान नंबर- 05, वार्ड नंबर- 18, रानी शाही मंदिर के पास, विवेकानन्द नगर आगर - मालवा, आगर, मालवा, शाजापुर, मध्य प्रदेश, 485441

Address: D/O Badri Lal Malviya, Makan Number- 05, Ward Number- 18, Rani Shati Mandir Ke Paas, Vivekanand Nagar Aagar - Malwa, Agar, Agar Malwa, Shajapur, Madhya Pradesh, 485441

1947
1800 180 1947

help@uidai.gov.in

www.uidai.gov.in

P.O. Box No. 1947, Bargarh-761 001

MEASUREMENTS :

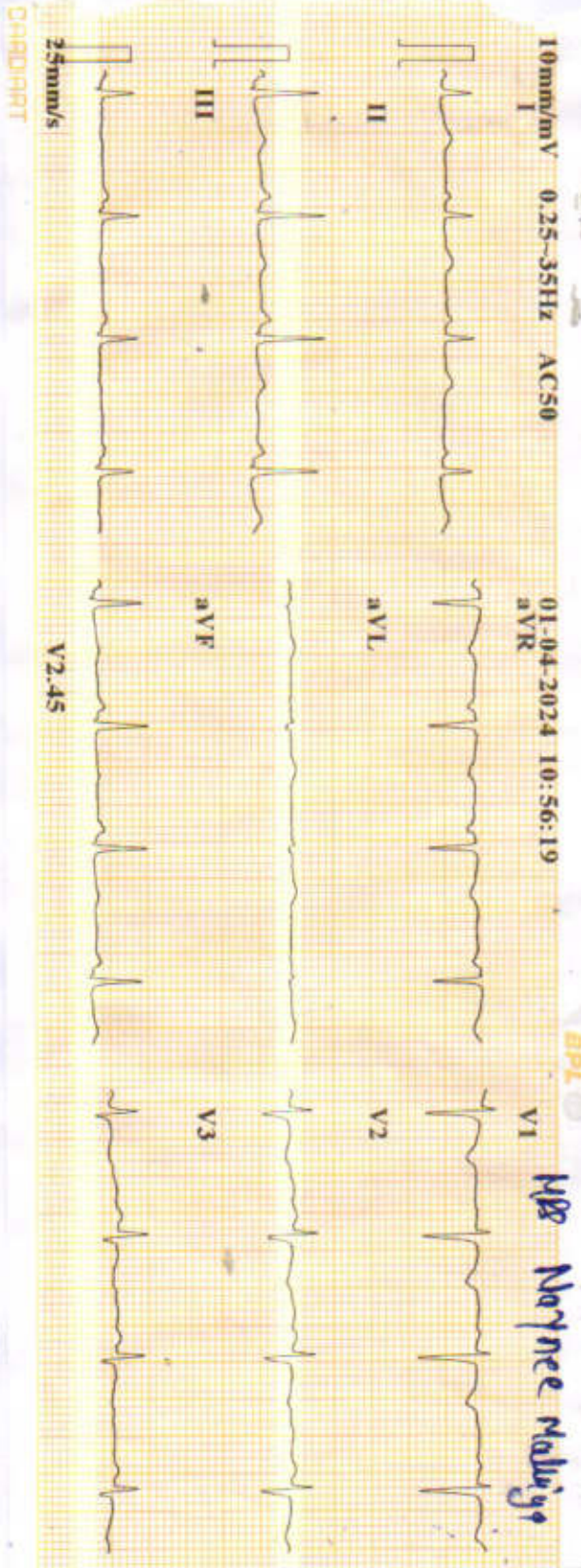
[C]	DIMENSIONS	OBSERVED VALUES	Normal Values (For Adults)
1.	Aortic Root diameter	: 2.4 cms.	2.0-3.7 cm < 2.2 cm / M ²
2.	Aortic Valve Opening	: 2.7 cms.	1.5-2.6 cm
3.	Right Ventricular Dimension	: --	
4.	Left Atrial Dimension	: 2.9 cms.	1.9-4.0 cm < 2.2 cm / M ²
5.	Left Ventricular ED Dimension	: 3.8 cms.	3.7-5.6 cm < 3.2 cm / M ²
6.	Left Ventricular ES Dimension	: 2.4 cms.	2.2-4.0 cm
7.	Inter Ventricular ED Septal thickness	: 1.1 cms.	0.6-1.2 cm
8.	Left Ventricular ED PW thickness	: 1.1 cms.	0.5-1.0 cm
9.	IVS / LVPW	: 01	< 1.3

[E]	INDICES OF LEFT VENTRICULAR FUNCTION		
1.	Mitral E - Septal Separation	: 0.5	< 0.9- cm
2.	Left Ventricular Ejection Fraction	: 60 %	60 - 80 %

DOPPLER

	Peak Flow Velocity (M/Sec.)	Peak Gradient (mmHg.)	Regurgitation
MV	Normal	--	Normal
TV	Normal	--	Normal
AV	Normal	--	Normal
PV	Normal	--	Normal

PASP : Normal



ID	: 240401-1056
Name	: 33 yr
Age	: Female
Sex	: Female
BP	: mmHg
Height	: cm
Weight	: kg
HR	: 87 bpm
P Dur	: 89 ms
PR int	: 116 ms
QRS Dur	: 107 ms
QT/QTc int	: 352/424 ms
P/QRS/T axis	: 64/65/18 °
RV5/SV1 amp	: 0.863/0.803 mV
RV5+SV1 amp	: 1.666 mV
RV6/SV2 amp	: 0.916/0.390 mV



Dr. PRIVANK JAIN
MBBS, MD, DM,
Reg. No. 19547

(Handwritten signature and initials)

MBBS Naynree Malviya

UNIQUE DIAGNOSTIC CENTRE INDORE

01 Apr 2024
Name : MISS. NAYNEE MALVIYA

Ref.by : BOB
Done by : DR. PRIYANK JAIN M.D.,DM.

