



Pathology Department

**VIDHI**  
DIAGNOSTICS

Creating life in colors

Patient's name : PATHAK FENIL  
Age/Sex : 34 Years/Male  
Referred by : MEDI WHEEL  
Collection Time : 09:40

Reg. ID : P-6510-23  
Accession : 23588  
Order Dt/time : 08/03/2024 09:40

**Complete Blood Count**

Sample Type: EDTA

Test Name	Result	Units	Biological Reference Interval
<b>Blood Counts</b>			
Haemoglobin :	14.7	Gms%	13.5 - 18.0
Total R.B.C. :	4.92	mill/c.mm	4.7 - 6.0
Total W. B. C. :	7260	/cu mm	4000 - 10500
Platelet Count :	276000	/cu.mm	1,50,000 - 4,50,000
<b>Differential Count</b>			
Neutrophils :	60	%	40 - 70
Lymphocytes :	34	%	20 - 40
Eosinophils :	03	%	1 - 4
Monocytes :	03	%	2 - 6
Basophils :	00	%	0 - 01
<b>Blood Indices</b>			
P. C. V :	43.4	%	42 - 52
M. C. V. :	88.2	fl	78 - 100
M.C.H :	29.8	pg	27 - 31
M. C. H. C :	33.8	%	32 - 36
R.D.W :	13.5	%	11.5 - 14.0

**E.S.R.( Westergren Method )**

After one hour : 04 mm/hr 1 - 7

TESTS DONE ON FULLY AUTOMATED HEMATOLOGY ANALYZER.

*Dr. Gayatri M. Mehta*

M. D. (Patho)

Reg. No. G-32215

DR GAYATRI MEHTA  
MD(PATHOLOGY)

DR. ANAND D. PARIKH  
MD(PATHOLOGY)

LAB USE ONLY (Entered by :GM Enter Date/Time:08/03/2024 17:32:00) (Verify by :GM Verify Date/Time:08/03/2024 17:32:00)



Vidhi Diagnostics | Pathology Department

L-86, Swatantra Senani Nagar, Opp. Akharnagar Petrol Pump, Nr. Akharnagar Circle, Nava-Vadaj, Ahmedabad - 380 013.

M. - Pathology : 8849893954, Ph. : 079-27621406, M. 98799 29406, 98250 09406, E-mail : vidhidiagnostics@gmail.com, Web. : www.vidhidiagnostics.com

Time (Pathology) : Mon. to Sat. 8.30 am to 8.00 pm, Sunday 9 am to 12 Noon

*Pathology means science behind medicine*

**CT SCAN & CBCT FACILITY NOW AVAILABLE**



Pathology Department



Patient's name : PATHAK FENIL  
Age/Sex : 34 Years/Male  
Referred by : MEDI WHEEL  
Collection Time : 09:40

Reg. ID : P-6510-23  
Accession : 23588  
Order Dt/time : 08/03/2024 09:40

**Blood Group**

Sample Type: EDTA sample.

Test Name	Result
BG :	" B "
RH :	POSITIVE
Remarks	Done by forward grouping method.

**Blood Glucose**

Sample Type: Serum

Test Name	Result	Units	Biological Reference Interval
Fasting Blood Glucose :	101.5	mg/dl	70 - 110
Urine Sugar :	NIL		Absent
<i>GOD-POD Method.</i>			

**Blood Glucose**

Sample Type: Serum

Test Name	Result	Units	Biological Reference Interval
Post Prandial Blood Glucose After 2hr. :	107.3	mg/dl	80 - 140
Urine Sugar :	NIL		Absent
<i>GOD-POD Method.</i>			

*Dr. Gayatri M. Mehta*

M. B. (Patho)

Reg. No. G-32215

DR GAYATRI MEHTA  
MD(PATHOLOGY)

DR. ANAND D. PARIKH  
MD(PATHOLOGY)

LAB USE ONLY (Entered by :GM Enter Date/Time:08/03/2024 17:30:00) (Verify by :GM Verify Date/Time:08/03/2024 17:30:00)



Vidhi Diagnostics | Pathology Department

L-86, Swatantra Senani Nagar, Opp. Akhbarnagar Petrol Pump, Nr. Akhbarnagar Circle, Nava-Vadaj, Ahmedabad - 380 013.

M. - Pathology : 8849893954, Ph. : 079-27621406, M. 98799 29406, 98250 09406, E-mail : vidhidiagnostics@gmail.com, Web. : www.vidhidiagnostics.com

Time (Pathology) : Mon. to Sat. 8.30 am to 8.00 pm, Sunday 9 am to 12 Noon

*Pathology means science behind medicine*

**CT SCAN & CBCT FACILITY NOW AVAILABLE**





Pathology Department



Patient's name : PATHAK FENIL  
 Age/Sex : 34 Years/Male  
 Referred by : MEDI WHEEL  
 Collection Time : 09:40

Reg. ID : P-6510-23  
 Accession : 23588  
 Order Dt/time : 08/03/2024 09:40

**Lipid Profile**

Sample Type: Serum

Test Name	Result	Units	Biological Reference Interval
<b>S. Cholesterol :</b> <small>Oxidase-esterase method.</small>	189	mg/dl	0 - 200
<b>S. Triglyceride :</b> <small>Enzymatic Colorimetry method</small>	134.9	mg/dL	0 - 200
<b>S. HDL - Cholesterol :</b> <small>Serum by Enzymatic method.</small>	46.0	mg/dL	35 - 65
<b>S. LDL - Cholesterol :</b> <small>Serum by Enzymatic method</small>	116.02	mg/dL	0 - 130
<b>S. VLDL - Cholesterol :</b>	26.98	mg/dL	0 - 30
<b>S. Chole/HDL.Ratio :</b>	4.11		1 - 6
<b>S. LDL / HDL Cholesterol Ratio :</b>	2.52		0 - 3.5

*Dr. Gayatri M. Mehta*  
 M. B. (Patho)

Reg. No. G-92215

DR. GAYATRI MEHTA  
 MD(PATHOLOGY)

DR. ANAND D. PARIKH  
 MD(PATHOLOGY)

LAB USE ONLY (Entered by :GM Enter Date/Time:08/03/2024 17:29:00) (Verify by :GM Verify Date/Time:08/03/2024 17:29:00)



Vidhi Diagnostics | Pathology Department

L-86, Swatantra Senani Nagar, Opp. Akhbaragar Petrol Pump, Nr. Akhbaragar Circle, Nava-Vadaj, Ahmedabad - 380 013.

M. - Pathology : 8849893954, Ph. : 079-27621406, M. 98799 29406, 98250 09406, E-mail : vidhidiagnostics@gmail.com, Web. : www.vidhidiagnostics.com

Time (Pathology) : Mon. to Sat. 8.30 am to 8.00 pm, Sunday 9 am to 12 Noon

*Pathology means science behind medicine*

**CT SCAN & CBCT FACILITY NOW AVAILABLE**



Patient's name : PATHAK FENIL  
Age/Sex : 34 Years/Male  
Referred by : MEDI WHEEL  
Collection Time : 09:40

Reg. ID : P-6510-23  
Accession : 23588  
Order Dt/time : 08/03/2024 09:40

HbA1C

Sample Type: EDTA

Test Name	Result	Units	Biological Reference Interval
HbA1C :	5.1	%	Non-diabetic: 4.2-6.2 Pre-diabetic : 6.3-7.2 Diabetic : 7.3-8.2
Mean Blood Glucose of Last 03 months.	100	mg/dl	

**Comment** \*As per the new 2009 update of American Diabetes Association regarding HbA1C & Mean Blood Glucose relationship.  
**NOTE:** This test is used to monitor diabetic patients compliance with the therapeutic regimen and logo It's level is proportional to both the average blood glucose concentration and the life span of the red blood cells (RBC) in circulation. HbA1c values are free of day to day glucose fluctuations and are unaffected by exercise or recent food intake.

*Dr. Gayatri M. Mehta*

M. D. (Pathol)

Reg. No. G-32215

DR GAYATRI MEHTA  
MD(PATHOLOGY)

DR. ANAND D. PARIKH  
MD(PATHOLOGY)

LAB USE ONLY (Entered by :GM Enter Date/Time:08/03/2024 17:29:00) (Verify by :GM Verify Date/Time:08/03/2024 17:29:00)



Vidhi Diagnostics | Pathology Department

L-86, Swatantra Senani Nagar, Opp. Akhbarnagar Petrol Pump, Nr. Akhbarnagar Circle, Nava-Vadaj, Ahmedabad - 380 013.

M. - Pathology : 8849893954, Ph. : 079-27621406, M. 98799 29406, 98250 09406, E-mail : vidhidiagnostics@gmail.com, Web. : www.vidhidiagnostics.com

Time (Pathology) : Mon. to Sat. 8.30 am to 8.00 pm, Sunday 9 am to 12 Noon

*Pathology means science behind medicine*

**CT SCAN & CBCT FACILITY NOW AVAILABLE**





Patient's name : PATHAK FENIL  
Age/Sex : 34 Years/Male  
Referred by : MEDI WHEEL  
Collection Time : 09:40

Reg. ID : P-8510-23  
Accession : 23588  
Order Dt/time : 08/03/2024 09:40

**BIOCHEMISTRY**

Sample type :Serum

Test Name	Result	Units	Biological Reference Interval
<b>Urea</b> , (Serum by GLDH method) :	22.1	mg/dl	10 - 50
<b>S.Uric acid</b> , (Serum by Uricase method) :	<b>9.8</b>	mg/dl	3.4 - 7.0
<b>Bun</b> :	10.3	mg/dl	6-20
<b>Creatinine</b> , (Serum by Enzymatic reaction) :	0.93	mg/dl	0.5-1.2
<b>S.G.P.T (ALT)</b> : (Serum by IFCC method )	19.2	U/L	0 - 40
<b>S.G.O.T (AST)</b> : (Serum by IFCC method )	17.9	U/L	0 - 37
<b>ALK.PHOSPHATASE</b> : (Serum by PNP method )	75	U/L	40-129
<b>G.G.T</b> :	16.1	U/L	8 - 78
<b><u>BILIRUBIN</u></b>			
<b>Total</b> :	0.69	mg/dl	Up to 1.2
<b>Direct</b> :	0.27	mg/dl	0-0.7
<b>Indirect</b> :	0.42	mg/dl	0 - 0.5
<b><u>SERUM PROTEINS</u></b>			
<b>Total Protein</b> (Serum by Biuret method) :	6.96	gms/dl	6.4 - 8.5
<b>Albumin</b> (Serum by BCG method) :	4.30	gms/dl	3.97-4.94
<b>Globulins</b> :	2.66	gms/dl	2.3 - 3.5
<b>A/G Ratio</b> :	1.617		0.9 - 2.9

*Dr. Gayatri M. Mehta*  
M.D. (Pathol)  
M.D. (Genl)

Reg. No. G-32215

DR. GAYATRI MEHTA  
MD(PATHOLOGY)

DR. ANAND D. PARIKH  
MD(PATHOLOGY)

LAB USE ONLY (Entered by :GM Enter Date/Time:08/03/2024 17:29:00) (Verify by :GM Verify Date/Time: 08/03/2024 17:29:00)



Vidhi Diagnostics | Pathology Department

L-86, Swatantra Senani Nagar, Opp. Akhbarnagar Petrol Pump, Nr. Akhbarnagar Circle, Nava-Vadaj, Ahmedabad - 380 013.

M. - Pathology : 8849893954, Ph. : 079-27621406, M. 98799 29406, 98250 09406, E-mail : vidhidiagnostics@gmail.com, Web. : www.vidhidiagnostics.com

Time (Pathology) : Mon. to Sat. 8.30 am to 8.00 pm, Sunday 9 am to 12 Noon

*Pathology means science behind medicine*

**CT SCAN & CBCT FACILITY NOW AVAILABLE**



Pathology Department



Patient's name : PATHAK FENIL  
Age/Sex : 34 Years/Male  
Referred by : MEDI WHEEL  
Collection Time : 09:40

Reg. ID : P-6510-23  
Accession : 23588  
Order Dt/time : 08/03/2024 09:40

**Thyroid Function Test**

Sample Type: Serum

Test Name	Result	Units	Biological Reference Interval
TOTAL T3 :	1.67	ng/ml	1.1 - 1.84
TOTAL T4 :	9.59	µg/dL	6.09 - 12.23
TSH(Ultra sensitive) :	1.35	µIU/mL	0.4001 - 4.049

*Dr. Gayatri M. Mehta*  
M.D. (Pathology)

Reg. No. G-32215

DR GAYATRI MEHTA  
MD(PATHOLOGY)

DR. ANAND D. PARIKH  
MD(PATHOLOGY)

LAB USE ONLY (Entered by :GM Enter Date/Time:08/03/2024 17:30:00) (Verify by :GM Verify Date/Time:08/03/2024 17:30:00)



Vidhi Diagnostics | Pathology Department

L-86, Swatantra Senani Nagar, Opp: Akhbarnagar Petrol Pump, Nr. Akhbarnagar Circle, Nava-Vadaj, Ahmedabad - 380 013.

M. - Pathology : 8849893954, Ph. : 079-27621406, M. 98799 29406, 98250 09406, E-mail : vidhidiagnostics@gmail.com, Web. : www.vidhidiagnostics.com

Time (Pathology) : Mon. to Sat. 8.30 am to 8.00 pm, Sunday 9 am to 12 Noon

*Pathology means science behind medicine*

**CT SCAN & CBCT FACILITY NOW AVAILABLE**





Patient's name : PATHAK FENIL  
Age/Sex : 34 Years/Male  
Referred by : MEDI WHEEL  
Collection Time : 09:40

Reg. ID : P-6510-23  
Accession : 23588  
Order Dt/time : 08/03/2024 09:40

**Urine Analysis**

Sample Type: Urine

Test Name	Result	Units	Biological Reference Interval
<b><u>Physical Examination</u></b>			
Quantity :	10	ml	0 - 500 ml
Colour :	Yellow		Pale Yellow
Transparency :	Slight Turbid.		Clear
Reaction :	Acidic		4.6 - 8.0
Specific Gravity :	1.015		1.016 - 1.022
Sediment :	Present		
<b><u>Chemical Examination</u></b>			
Albumin :	Present (Faint Trace)		Absent
Sugar :	NIL		Absent
Acetone :	Absent		Absent
Bile Salts :	Absent		Absent
Bile Pigments :	Absent		Absent
Urobilogen :	Absent		Absent
Nitrites :	Absent		Absent
<b><u>Microscopic Examination</u></b>			
Red blood Cells :	2-3	/h.p.f	Absent
Pus Cells :	1-2	/h.p.f	Absent
Epithelial Cells :	1-2	/h.p.f	< 10.0
Amorphous :	Absent	/h.p.f	Absent
Bacteria :	Absent	/h.p.f	Absent
Crystals :	Absent	/h.p.f	Absent
Casts :	Absent	/h.p.f	Absent
Fungus :	Not seen	/h.p.f	Absent

*Dr. Gayatri M. Mehta*

M. D. (P. )

Reg. No. G-32215

DR GAYATRI MEHTA  
MD(PATHOLOGY)

DR. ANAND D. PARIKH  
MD(PATHOLOGY)



(Entered by :GM Enter Date/Time:08/03/2024 17:31:00) (Verify by :GM Verify Date/Time:08/03/2024 17:31:00)

Vidhi Diagnostics | Pathology Department

L-86, Swatantra Senani Nagar, Opp. Akhbarnagar Petrol Pump, Nr. Akhbarnagar Circle, Nava-Vadaj, Ahmedabad - 380 013.

M. - Pathology : 8849893954, Ph. : 079-27621406, M. 98799 29406, 98250 09406, E-mail : vidhidiagnostics@gmail.com, Web. : www.vidhidiagnostics.com

Time (Pathology) : Mon. to Sat. 8.30 am to 8.00 pm, Sunday 9 am to 12 Noon

*Pathology means science behind medicine*

**CT SCAN & CBCT FACILITY NOW AVAILABLE**



Pathology Department

Patient's name : PATHAK FENIL  
 Age/Sex : 34 Years/Male  
 Referred by : MEDI WHEEL  
 Collection Time : 09:40

Reg. ID : P-6510-23  
 Accession : 23588  
 Order Dt/time : 08/03/2024 09:40

**Stool Examination**

Sample Type: Stool

Test Name	Result	Units	Biological Reference Interval
-----------	--------	-------	-------------------------------

**PHYSICAL EXAMINATION**

Quantity	10 gms
Colour	Brownish
Consistency	Solid
Mucus	Nil
Occult Blood	Negative
Peroxidase Reaction with o-Dianisidine	
Reaction	Acidic
pH Strip Method	

**MICROSCOPIC EXAMINATION**

Pus Cells	2 - 3/hpf
RBCs	Nil
Vegetable Cells	Absent
Trophozoites	Nil
Cysts	Nil
Ova	Nil
Fat Globules	Nil

----- End Of Report -----

*Dr. Gayatri M. Mehta*

M. D. (Pathol)

Reg. No. G-32215

DR GAYATRI MEHTA  
MD(PATHOLOGY)

DR. ANAND D. PARIKH  
MD(PATHOLOGY)

LAB USE ONLY (Entered by :GM Enter Date/Time 08/03/2024 17:32:00) (Verify by :GM Verify Date/Time 08/03/2024 17:32:00)



Vidhi Diagnostics | Pathology Department

L-86, Swatantra Senani Nagar, Opp. Akhbaragar Petrol Pump, Nr. Akhbaragar Circle, Nava-Vadaj, Ahmedabad - 380 013.

M. - Pathology : 8849893954, Ph. : 079-27621406, M. 98799 29406, 98250 09406, E-mail : vidhidiagnostics@gmail.com, Web. : www.vidhidiagnostics.com

Time (Pathology) : Mon. to Sat. 8.30 am to 8.00 pm, Sunday 9 am to 12 Noon

*Pathology means science behind medicine*

**CT SCAN & CBCT FACILITY NOW AVAILABLE**



Health Check up Booking Request(bobE12658), Beneficiary Code-107201

1 message

Mediwheel <wellness@mediwheel.in>  
To: vidhidiagnostics@gmail.com  
Cc: customercare@mediwheel.in

2 March 2024 at 12:50



Mediwheel  
...Your wellness partner

011-41195959

Dear VIDHI DIAGNOSTICS

We have received a booking request with the following details. Provide your confirmation by clicking on the Yes button.

**You confirm this booking?**      Yes                  No

**Name** : MR. PATHAK FENIL JYOTINDRA

**Hospital Package Name** : Mediwheel Full Body Health Checkup Male Below 40

**Appointment Date** : 08-03-2024

Member Information		
Booked Member Name	Age	Gender
MR. PATHAK FENIL JYOTINDRA	34 year	Male

**Tests included in this Package -**

- Stool Test
- Thyroid Profile
- ESR
- Blood Glucose (Fasting)
- General Physician Consultation
- TMT OR 2D ECHO
- Blood Group
- Blood Glucose (Post Prandial)
- Chest X-ray
- ECG
- USG Whole Abdomen
- Eye Check-up consultation
- Urine Sugar Fasting
- Urine Sugar PP
- Dental Consultation
- Urine analysis
- CBC
- HbA1c
- Lipid Profile
- Kidney Profile
- Liver profile

Thanks,  
Mediwheel Team

Please Download Mediwheel App



You have received this mail because your e-mail ID is registered with **Arcofemi Healthcare Limited** This is a system-generated e-mail please don't reply to this message.

Please visit to our [Terms & Conditions](#) for more informaion. [Click here to unsubscribe.](#)

© 2024 - 25, Arcofemi Healthcare Pvt Limited.(Mediwheel)





Fenil



**Vidhi Diagnostics**  
1-05, Sr. Anant-Sarjni Nagar,  
C-12, Alhambagar Bus Terminala,  
Nr. Alhambagar Circle,  
New Wedaj, Ahmedabad-13.



# Dr. Dinesh S. Modh

M.D., D.M.R.E. (Radiodiagnosis)  
Consultant Radiologist & Sonologist  
Ex. Junior Lecturer, B.J. Medical College, Civil Hospital, A'bad.



08/03/2024

Panthak fami  
34 yr male

Height! - 180cm

Weight! - 89kg

BP! - 106/72mmHg

Pulse! - 70 per min

T! - @

Rgt @  
Cvs @

SpO2! - 99

ASymptomatic

No H/o DM, HIV, Thyroid or TB

★ Eye checkup! -

→ Color vision! - Normal

→ Distance! - @16

→ Near! - N/G

★ Dental! -

→ Oral Hygiene normal

→ No H/o Cavities & Caries is seen.

Adv! -

He is medically fit

## Vidhi Diagnostics

L-83, Swatantra Senani Nagar,  
Opp. Akhbarnagar Bus Terminals,  
Nr. Akhbarnagar Circle,  
New Wadaj, Ahmedabad-13.

ISO 9001:2015 Certified Diagnostics Center

Vidhi Imaging Center

Dr. Vidhi D. Modh

MBBS  
Reg. No.: 074540

L-86, Swatantra Senani Nagar, Opp. Indian Oil Petrol Pump, Akhbarnagar Circle, Nava Vada, Ahmedabad - 380 013.

Phone : (Radiology) 079-2762 1406 | M. 98799 29406, 98250 09406 | Time (Radiology) : Mon. to Sat. 9 am to 2 pm, 5 to 9 pm, Sunday 9 am to 12 Noon

E-mail : vidhidiagnostics@gmail.com, Website : www.vidhidiagnostics.com

Multislice CT Scan | CBCT-Dental Scan | Live 3D-4D Sonography | Colour Doppler | Echo Cardiography | Interventional Radiology | Maxillofacial Radiology | Fetal Medicine  
Digital X-Ray | Digital Mammography | Digital OPG / TMJ | ECG / TMT / PFT / EEG / EMG | Audiometry | Pathology Laboratory | Health Check Up Plans | Pre Employment Check Up

**CT SCAN & CBCT FACILITY NOW AVAILABLE**



08-03-2024 10:27:39

ID: 12904

Name: ferit pathak

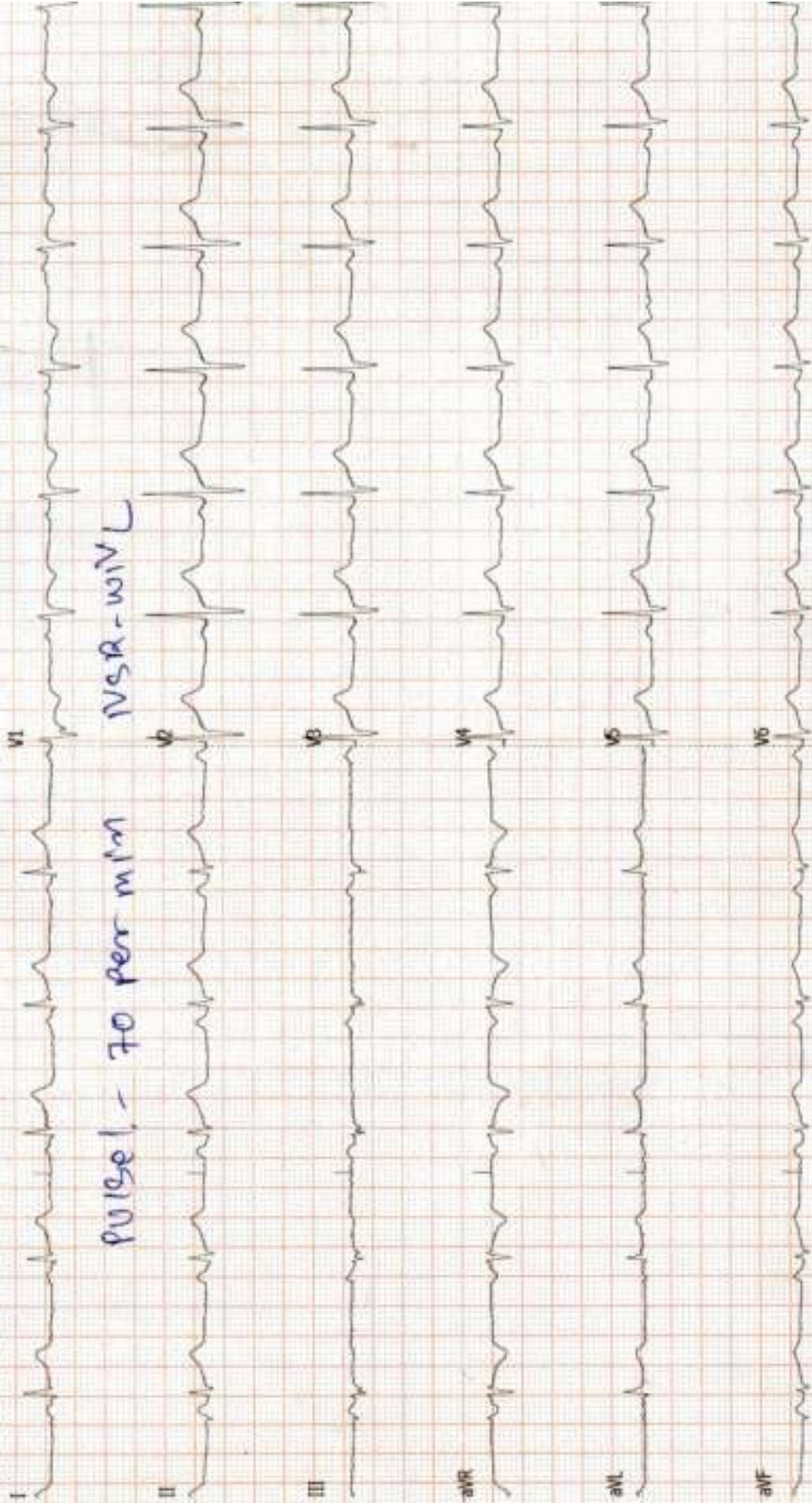
Age: 34yrs

Sex: Male

Hospital:

Department:

0.5/Hz - 35Hz AC 50Hz 25 mm/s 10 mm/mv



<< Analysis Result >>

\*\* normal ECG \*\*

Sinus rhythm

Vidhi Diagnostics

L-66, Swasthik Society, Nagpur,  
Opp. Ashwini Hospital, Jambhale,  
Nr. Ashwini Hospital Circle,  
New Wadga, Ahmednagar-43.

Dr. Avinash Patil  
Director  
G-45946



## Dr. Dinesh S. Modh

M.D., D.M.R.E. (Radiodiagnosis)

Consultant Radiologist & Sonologist

Ex. Junior Lecturer, B.J. Medical College, Civil Hospital, A'bad.



Patient's name : PATHAK FENIL  
Reg. ID : R-14098-23  
Referred by : MEDI WHEEL

Age/Sex : 34 Years/Male  
Accession : 23608  
Date : 08/03/2024

### 2D- ECHO REPORT

#### FINAL CONCLUSION:

LV IS NORMAL SIZE. GOOD LV SYSTOLIC FUNCTION NO RWMA.  
LVEF - 60%. NO CONCENTRIC LVH.  
NORMAL LV COMPLANCE.  
LA IS NORMAL SIZE. NO LA CLOT.  
RV IS NORMAL SIZE. GOOD RV SYSTOLIC FUNCTION.  
RA IS NORMAL SIZE.  
MITRAL VALVE IS NORMAL. NO MS. MILD MR (15%). NO MVP.  
AORTIC VALVE IS NORMAL. NO AS. NO AR.  
TRICUSPID VALVE IS NORMAL. NO TR. RVSP-26 mmHg. NO PAH.

NO CLOT, NO VEGETATION, NO PERICARDIAL EFFUSION.

#### DIMENSIONS:

AORTA	2.6 C.M
LEFT ATRIUM	2.7 C.M
LVDD	4.1 C.M.
IVSD	1.0 C.M
PWD	1.0 C.M
LVDS	2.6 C.M.

#### COLOUR DOPPLER FINDING:

STRUCTURE	VELOCITY m/sec
	Max
PULMONARY VALVE	0.7
MITRAL VALVE	E : 0.7 A: 0.4
AORTIC VALVE	1.0

Dr. Avinash Bhaskar  
M.B.B.S D-Cardio  
G-45946

**DR AVINASH BHASKAR**  
**CLINICAL CARDIOLOGIST**  
**9924836431**

ISO 9001:2015 Certified Diagnostics Center

Vidhi Imaging Center

L-86, Swatantra Senani Nagar, Opp. Indian Oil Petrol Pump, Akhbarnagar Circle, Nava Vada, Ahmedabad - 380 013.

Phone : (Radiology) 079-2762 1406 | M. 98799 29406, 98250 09406 | Time (Radiology) : Mon. to Sat. 9 am to 2 pm, 5 to 9 pm, Sunday 9 am to 12 Noon

E-mail : vidhidiagnostics@gmail.com, Website : www.vidhidiagnostics.com

Multislice CT Scan | CBCT-Dental Scan | Live 3D-4D Sonography | Colour Doppler | Echo Cardiography | Interventional Radiology | Maxillofacial Radiology | Fetal Medicine  
Digital X-Ray | Digital Mammography | Digital DPG/TMJ | ECG/TMT/PFT/EEG/EMG | Audiometry | Pathology Laboratory | Health Check Up Plans | Pre Employment Check Up

**CT SCAN & CBCT FACILITY NOW AVAILABLE**





## Dr. Dinesh S. Modh

M.D., D.M.R.E. (Radiodiagnosis)  
Consultant Radiologist & Sonologist  
Ex. Junior Lecturer, B.J. Medical College, Civil Hospital, A'bad.



Patient's name : PATHAK FENIL  
Reg. ID : R-14098-23  
Referred by : MEDI WHEEL

Age/Sex : 34 Years/Male  
Accession : 23608  
Date : 08/03/2024

### USG ABDOMEN

LIVER:- Liver appears normal in size & echo texture. No evidence of focal lesion is seen. IHBR appear normal. Portal vein and CBD appear normal. No e/o calculus is seen in bile duct.

GALL BLADDER:- Gall bladder is distended & appears normal. No evidence of calculus or cholecystitis is seen.

SPLEEN:- Spleen appears normal in size & shows normal echo texture. No evidence of diffuse or focal lesion is seen.

PANCREAS:- Pancreas appears normal size and echo pattern. No e/o diffuse or focal lesion is seen. Main pancreatic duct appears normal.

KIDNEY:- Both Kidneys appear normal in size & echo texture.

- No e/o calculus or hydronephrosis/ hydroureter is seen on both sides.

Cortico-medullary differentiation is maintained on both sides.

Both suprarenal regions appear normal.

No evidence of pre & para aortic lymphadenopathy is seen.

Both suprarenal regions appear normal.

No evidence of pre & para aortic lymphadenopathy is seen.

RIF & BOWEL LOOPS (By high frequency probe):- Normal.

No evidence of dilated or thickened bowel loops is seen.

No evidence of free fluid is seen in abdomen.

Urinary bladder:- appears normal. No e/o calculus or mass lesion is seen in bladder.

Prostate appears normal size and echopattern.

Dr. Dinesh S. Modh  
MD (D.M.R.E. (Radiodiagnosis))

DR DINESH S. MODH

M.D. DMRE(RADIODIAGNOSIS)

Thanks for reference.

ISO 9001:2015 Certified Diagnostics Center

Vidhi Imaging Center

L-86, Swatantra Senani Nagar, Opp. Indian Oil Petrol Pump, Akhbarnagar Circle, **Nava Vada**, Ahmedabad - 380 013.

Phone : (Radiology) 079-2762 1406 | M. 98799 29406, 98250 09406 | Time (Radiology) : Mon. to Sat. 9 am to 2 pm, 5 to 9 pm, Sunday 9 am to 12 Noon

E-mail : vidhidiagnostics@gmail.com, Website : www.vidhidiagnostics.com

Multislice CT Scan | CBCT-Dental Scan | Live 3D-4D Sonography | Colour Doppler | Echo Cardiography | Interventional Radiology | Maxillofacial Radiology | Fetal Medicine  
Digital X-Ray | Digital Mammography | Digital OPG/TMJ | ECG/TMT/PFT/EEG/EMG | Audiometry | Pathology Laboratory | Health Check Up Plans | Pre Employment Check Up

**CT SCAN & CBCT FACILITY NOW AVAILABLE**





## Dr. Dinesh S. Modh

M.D., D.M.R.E. (Radiodiagnosis)  
Consultant Radiologist & Sonologist  
Ex. Junior Lecturer, B.J. Medical College, Civil Hospital, A'bad.



Patient's name : PATHAK FENIL  
Reg. ID : R-14098-23  
Referred by : MEDI WHEEL

Age/Sex : 34 Years/Male  
Accession : 23608  
Date : 08/03/2024

### X-RAY CHEST (PA VIEW)

Both lung fields appear normal.  
No e/o consolidation or cavitations is seen.  
Both costo-phrenic angles appear clear.  
Cardiac size is within normal limits.  
Both domes of diaphragm appear normal.  
Bony thoracic cage appears normal.

Thanks for reference.

  
Dr. Dinesh S. Modh  
MD DMRE (Radiodiagnosis)  
G-23825

DR DINESH S. MODH  
M.D. DMRE(RADIODIAGNOSIS)

ISO 9001:2015 Certified Diagnostics Center

Vidhi Imaging Center

L-86, Swatantra Senani Nagar, Opp. Indian Oil Petrol Pump, Akhbarnagar Circle, Nava Vada, Ahmedabad - 380 013.

Phone : (Radiology) 079-2762 1406 | M. 98799 29406, 98250 09406 | Time (Radiology) : Mon. to Sat. 9 am to 2 pm, 5 to 9 pm, Sunday 9 am to 12 Noon

E-mail : vidhidiagnostics@gmail.com, Website : www.vidhidiagnostics.com

Multislice CT Scan | CBCT-Dental Scan | Live 3D-4D Sonography | Colour Doppler | Echo Cardiography | Interventional Radiology | Maxillofacial Radiology | Fetal Medicine  
Digital X-Ray | Digital Mammography | Digital OPG/TMJ | ECG/TMT/PFT/EEG/EMG | Audiometry | Pathology Laboratory | Health Check Up Plans | Pre Employment Check Up

**CT SCAN & CBCT FACILITY NOW AVAILABLE**