

ECHO REPORT

SRD No :XB008785	Name:JAYALAKSHMI	Age:40Y	Sex:F	Date: 24/02/24
------------------	------------------	---------	-------	----------------

Left Ventricle:-

	Diastole	Systole
IVS	1.03cm	1.16cm
LV	4.12cm	2.45cm
LVPW	1.09cm	1.24cm

EF -71% FS- 40%

AO	LA
3.22cm	3.61cm

PV - 0.82m/s
AV - 1.33m/s
MVE - 0.81m/s
MVA - 0.52m/s
E/A - 1.55

IMPRESSION:-

- Normal chambers dimension
- No RWMA
- Good LV systolic function
- No diastolic dysfunction
- No AS,AR,MR,MS,TR,PAH
- IAS/IVS intact.No clots/effussion/coaretation



Dr. SAJITH. K
MD,DNB
CONSULTANT CARDIOLOGIST
Reg:No: 19436

[Signature]
Consultant Cardiologis

NAME : MR: JAYALEKSHMI	AGE:40/F	DATE: 24/02/2024
------------------------	----------	------------------

CHEST X-RAY REPORT

CHEST X-RAY PA VIEW : Trachea central
 No cardiomegaly
 Normal vascularity
 No parenchymal lesion.
 Costophrenic and cardiophrenic angles clear

➤ **IMPRESSION** : Normal Chest Xray

ELECTRO CARDIOGRAM : NSR: 83/minute
 No evidence of ischaemia

➤ **IMPRESSION** : Normal Ecg.

Serin Lopez
 Dr. SERIN LOPEZ, MBBS
 Reg. No. 77656
 MEDICAL OFFICER
 DDRC AGILUS PATHLABS LTD.
 Aster Square, Medical College, P.O, TVM



Company name: MEDIWHEEL

DR SERIN LOPEZ MBBS
 Reg No 77656
DDRC AGILUS PATHLABS LTD

V1

V2

V3

V4

ID: 008785

Diagnosis Information:

Female / mmHg
41 Years / kg
cm

Clayton K. M.

HR : 83 bpm
 P : 123 ms
 PR : 174 ms
 QRS : 98 ms
 QT/QTc : 368/433 ms
 P/QRST : 54/57/42 ms
 RV5/SV1 : 0.718/0.420 mV

Report Confirmed by:



6

Standard

Standard

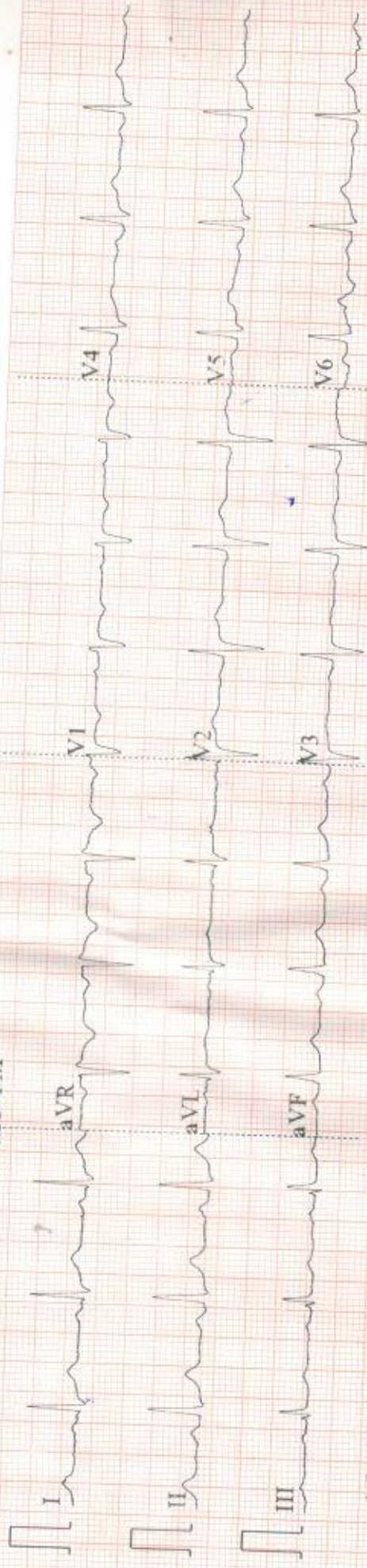L 1

L II

L III

L III Inspiration

ID: 008785 24-02-2024 01:04:53 PM



0.5-25Hz AC50 25mm/s 10mm/mV ♥77 V1.0 SEMIP V1.7 DDR-C-AGILUS

AP-00W CE

TRAC
ASY
ene
Trac
Boo
Sea
Ma
Fin

RADIOLOGY DIVISION

Acc no:4182XB008785	Name: Mrs. Jayalekshmi	Age: 40 y	Sex: Female	Date:24.02.24
---------------------	------------------------	-----------	-------------	---------------

US SCAN WHOLE ABDOMEN (TAS + TVS)

LIVER is normal in size (14.9 cm). Margins are regular. Hepatic parenchyma shows normal echogenicity. No focal lesions seen. No dilatation of intrahepatic biliary radicles. CBD is not dilated. Portal vein is normal in caliber (11.9 mm).

GALL BLADDER is distended and lumen clear. No calculi / polyp noted. Wall thickness is normal. No pericholecystic fluid seen.

SPLEEN is normal in size (11.4 cm) and parenchymal echotexture. No focal lesion seen.

PANCREAS Head and body visualized, appears normal in size and parenchymal echotexture. Pancreatic duct is not dilated.

RIGHT KIDNEY is normal in size (9.5 x 3.2 cm) and shows normal parenchymal echotexture. Cortico medullary differentiation is maintained. Parenchymal thickness is normal. No echogenic focus with shadowing suggestive of renal calculi seen. No dilatation of pelvicalyceal system seen. Ureter is not dilated. Perinephric spaces are normal.

LEFT KIDNEY is normal in size (10.6 x 4.2 cm) and shows normal parenchymal echotexture. Cortico medullary differentiation is maintained. Parenchymal thickness is normal. No echogenic focus with shadowing suggestive of renal calculi seen. No dilatation of pelvicalyceal system seen. Ureter is not dilated. Perinephric spaces are normal.

PARAAORTIC AREA No retroperitoneal lymphadenopathy or mass seen.

URINARY BLADDER is distended, normal in wall thickness, lumen clear.

UTERUS measures 9.8 x 4.8 x 5.6 cm, **myometrial echopattern is inhomogeneous. Suspicion of seedling fibroids in anterior wall.** Endometrial thickness is 9.3 mm. *Cervix appears elongated - H/o cesarean section noted.*

Both ovaries are normal. Right ovary vol - 9.5 cc. Left ovary vol - 5.4 cc and shows corpus luteum measuring 1.4 x 0.7 cm. No adnexal mass seen. No fluid in pouch of Douglas.

No ascites or pleural effusion.

Gaseous distension of bowel loops noted. No obvious bowel wall thickening seen sonologically.

CONCLUSION:-

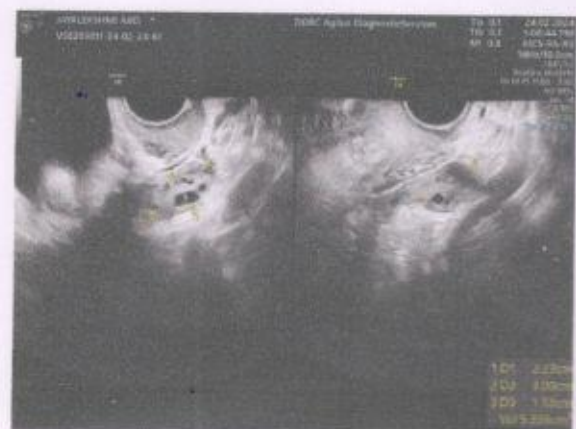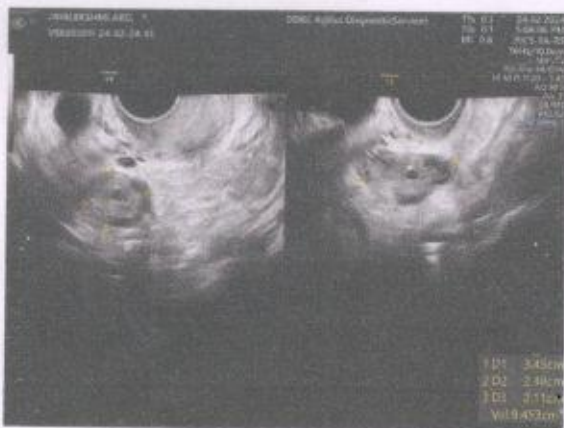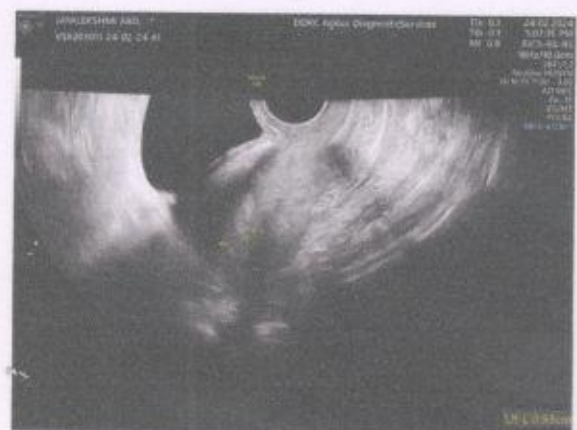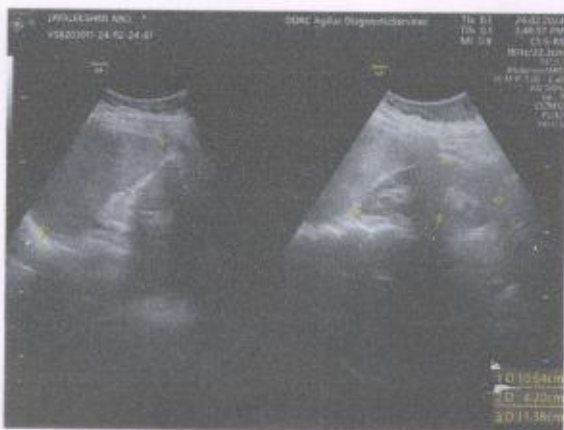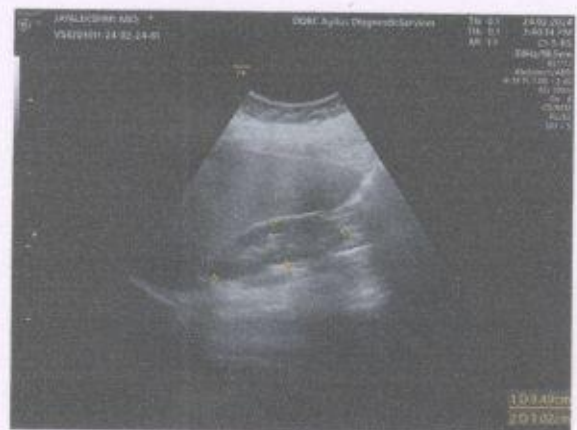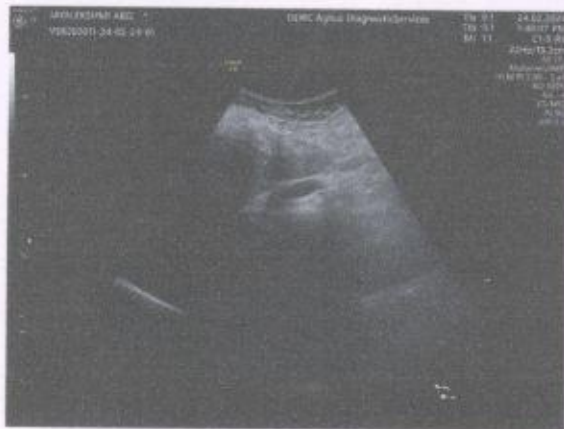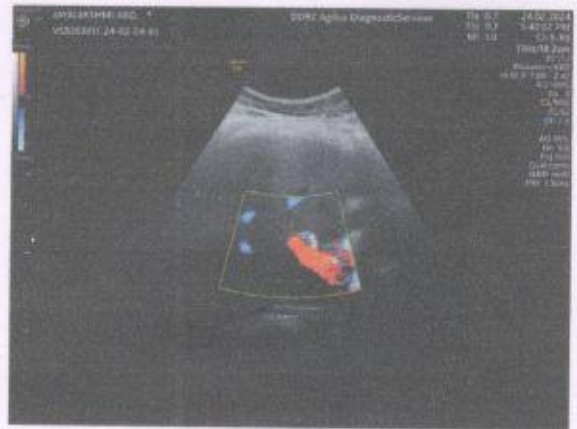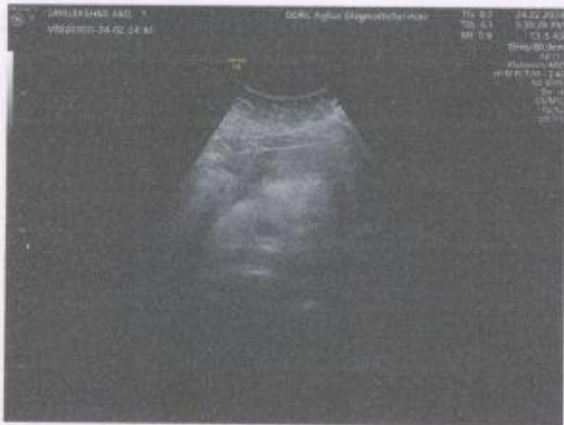- **Inhomogeneous uterine myometrium with suspicion of seedling fibroids in anterior wall .**

Nisha
Dr. Nisha Unni MD , DNB (RD)
Consultant radiologist.

*Thanks for referral. Your feedback will be appreciated.
(Please bring relevant investigation reports during all visits)
Because of technical and technological limitations complete accuracy cannot be assured on imaging.
Suggested correlation with clinical findings and other relevant investigations consultations , and if required repeat imaging recommended in the event of controversies. AR*

(For appointments / any clarification of report please contact 9496005190 between 9 am – 5.30 pm).

Corp. Office : Express House, Second Floor, Opp. Pothys Silks, Banerjee Road, Kaloor -682017
Contact :- 93334 93334, Web :- www.ddrcagilus.com Email :- info.ddrc@agilus.in



RADIOLOGY DIVISION

MAMMOGRAM REPORT (BOTH)

Acc no: 4182XB008785	Name: Mrs. Jayalekshmi	Age: 40 y	Sex: Female	Date: 24.02.24
-----------------------------	-------------------------------	------------------	--------------------	-----------------------

(i) **INDICATION** : - *Screening*

(ii) **BREAST COMPOSITION** : -

RIGHT : *Heterogeneously dense breast which may obscure small masses*

LEFT : *Heterogeneously dense breast which may obscure small masses.*

(iii) **OBSERVATION**:-

RIGHT : - No mass / asymmetry / architectural distortion / significant calcifications. *Prominent axillary fat pad seen*

LEFT :- No mass / asymmetry / architectural distortion / significant calcifications. *Prominent axillary fat pad seen*

(iv) **COMPARISON WITH THE PREVIOUS STUDIES** : - *No previous breast imaging*

(v) **ULTRASOUND FINDINGS** :-

RIGHT : **Breast composition** - Heterogeneous background echotexture.

Coarsening, hypoechogenicity of glandular elements and hyperechogenicity of periglandular stromal elements noted - possibility of fibroadenotic changes. D/ D - Nature / physiological. No mass / cysts / intramammary duct dilation. Nipple areolar complex normal. A few morphologically benign axillary lymphnodes noted, largest measuring 1.6 x 0.8 cm. Prominent subcutaneous fat pad noted in axilla

LEFT :- **Breast composition** - Heterogeneous background echotexture.

Coarsening, hypoechogenicity of glandular elements and hyperechogenicity of periglandular stromal elements noted - possibility of fibroadenotic changes. D/ D - Nature / physiological. No mass / cysts / intramammary duct dilation. Nipple areolar complex normal. A few morphologically benign axillary lymphnodes noted, largest measuring 2.5 x 0.8 cm Prominent subcutaneous fat pad noted in axilla.

(vi) **IMPRESSION** :-

RIGHT : - *BIRADS assessment category - Negative / Benign
BIRADS numeric code - 1 / 2*

LEFT :- *BIRADS assessment category - Negative / Benign.
BIRADS numeric code - 1 / 2.*

(vii) **RECOMMENDATIONS** : - *Routine mammography screening.*



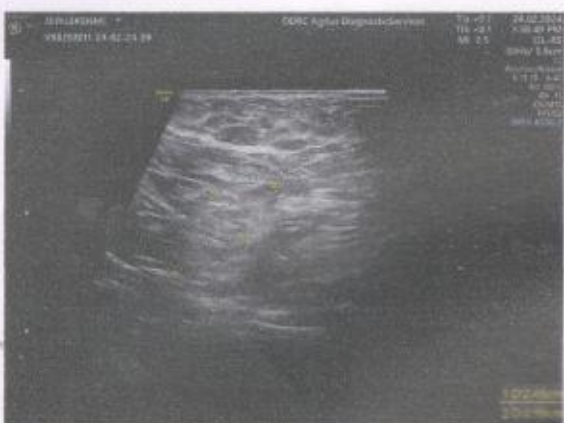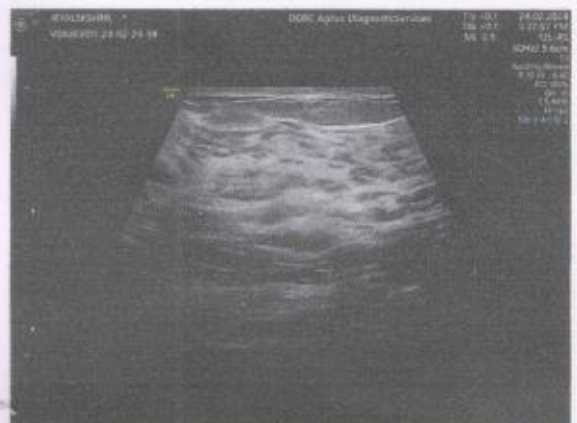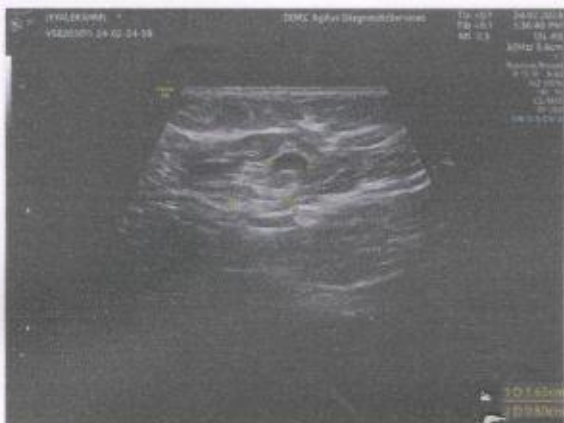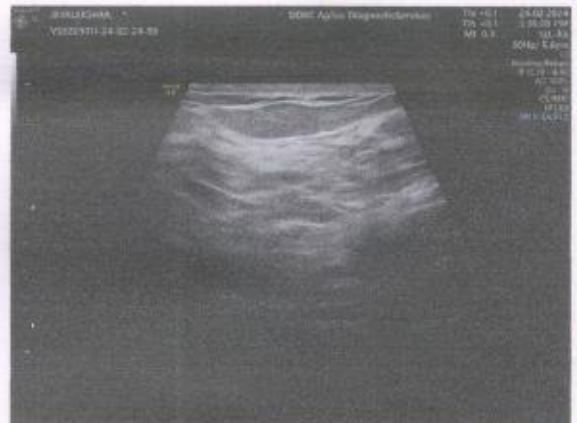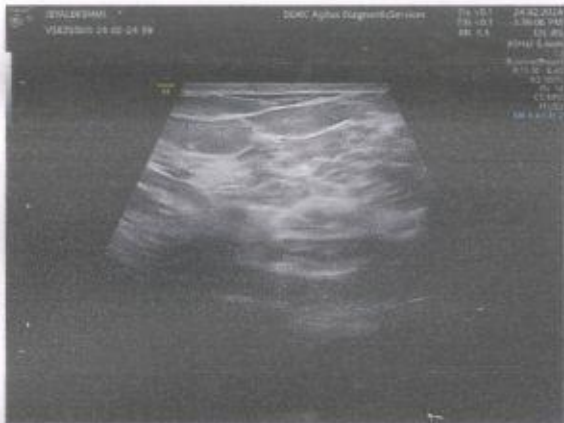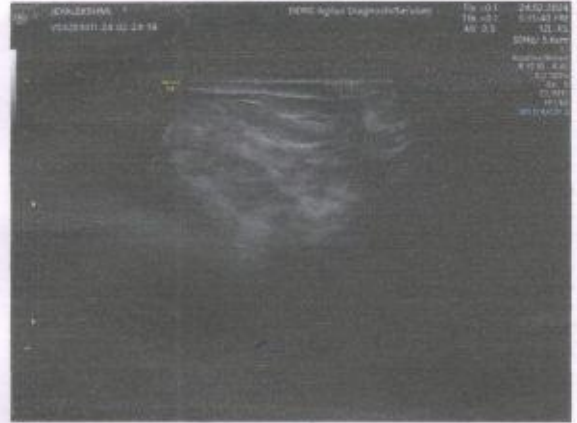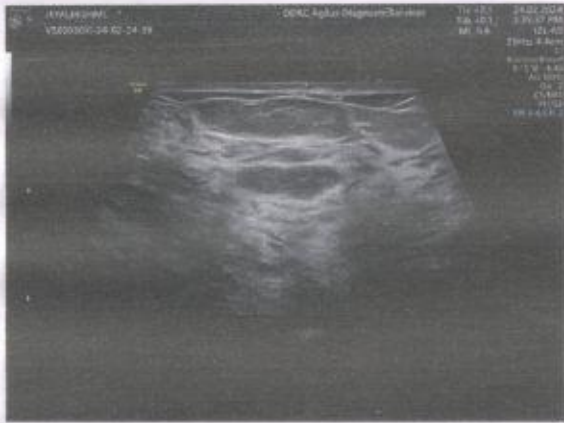Dr. Nisha Unni MD , DNB (RD)
Consultant radiologist.

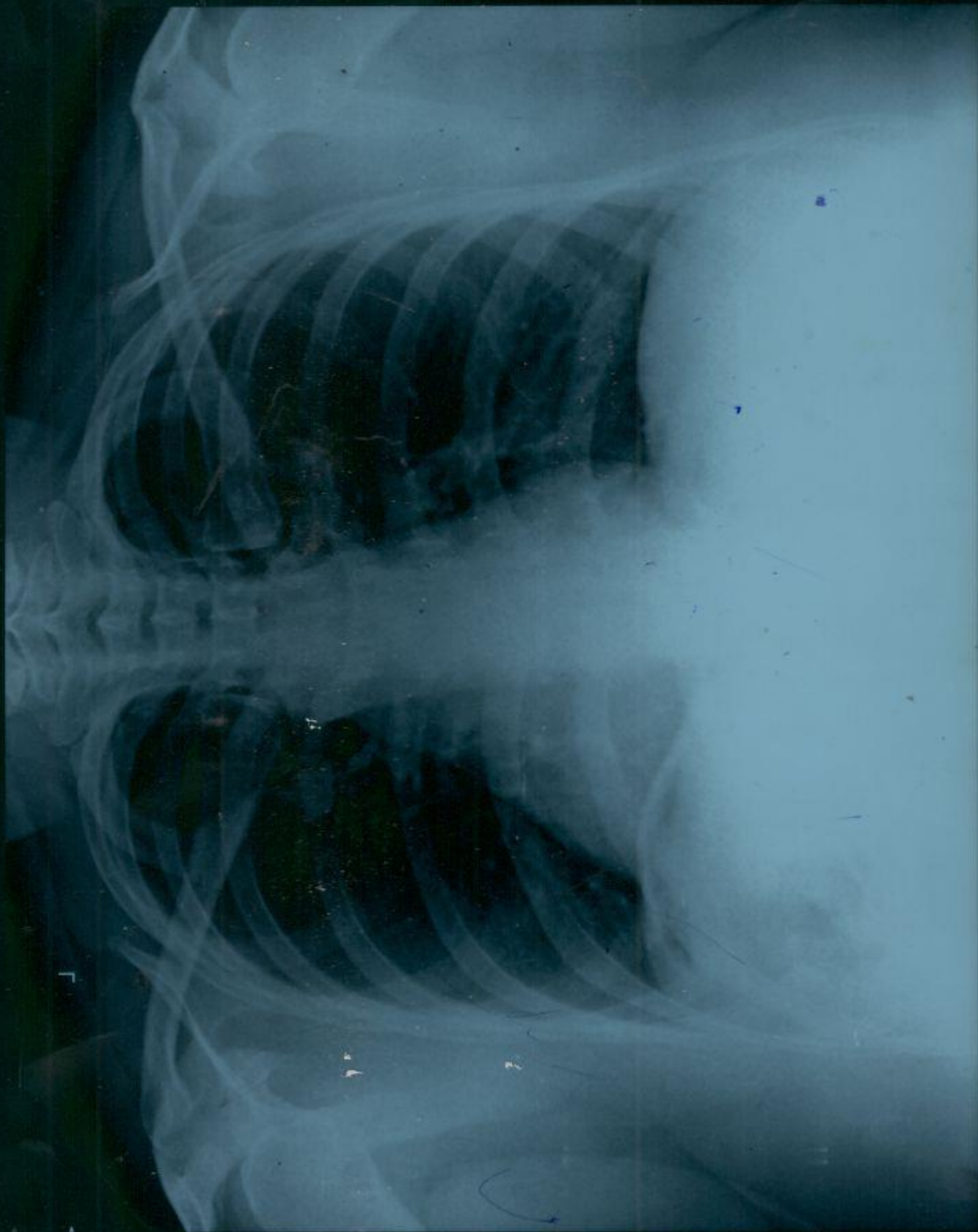
*Thanks, your feedback will be appreciated.
(Please bring relevant investigation reports during all visits).
Because of technical and technological limitations complete accuracy cannot be assured on imaging.
Suggested correlation with clinical findings and other relevant investigations consultations , and if required repeat imaging recommended in the event of controversies. AR*

For appointments please contact 9496005190 between 9 am – 5.30 pm).

DDRC *agilus* Pathlabs Limited.

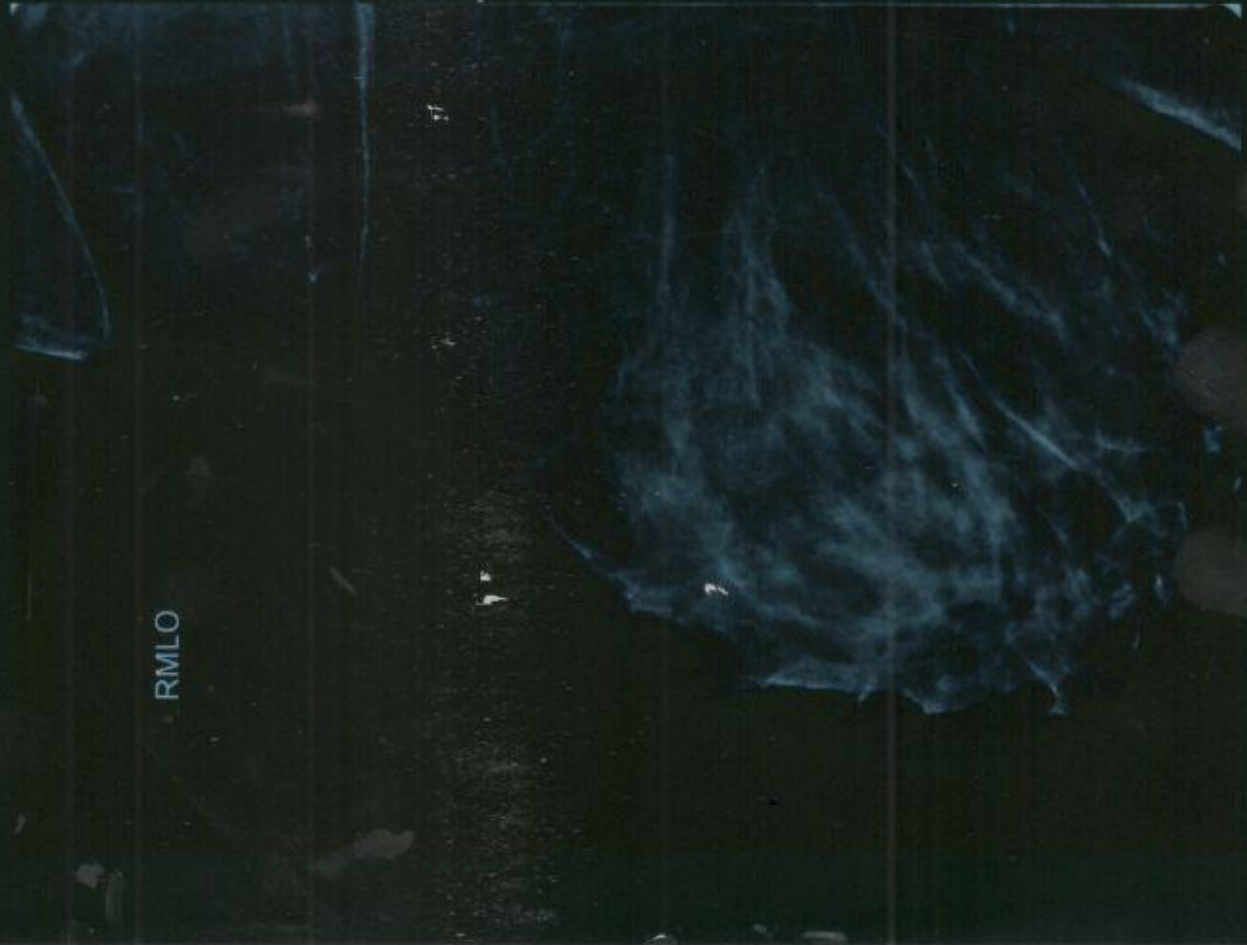Corp. Office : Express House, Second Floor, Opp. Pothys Silks, Banerjee Road, Kaloor -682017
Contact :- 93334 93334, Web :- www.ddrcagilus.com Email :- info.ddrc@agilus.in





WAVI WRCHEM NOLE
DDRC AGILUS
CHEST BY XBU0818E

L-mlo



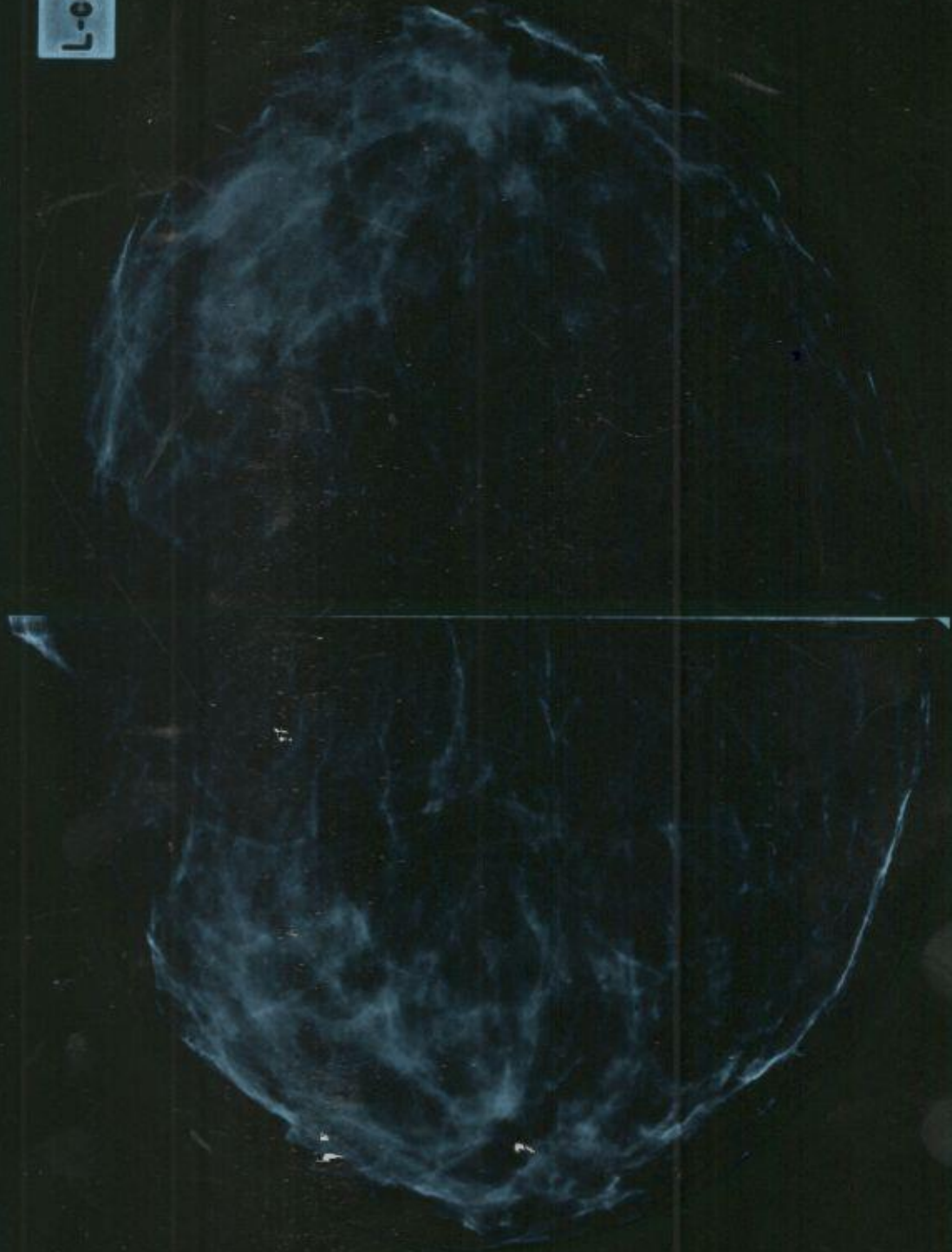
RMLO

DDRC AGILUS

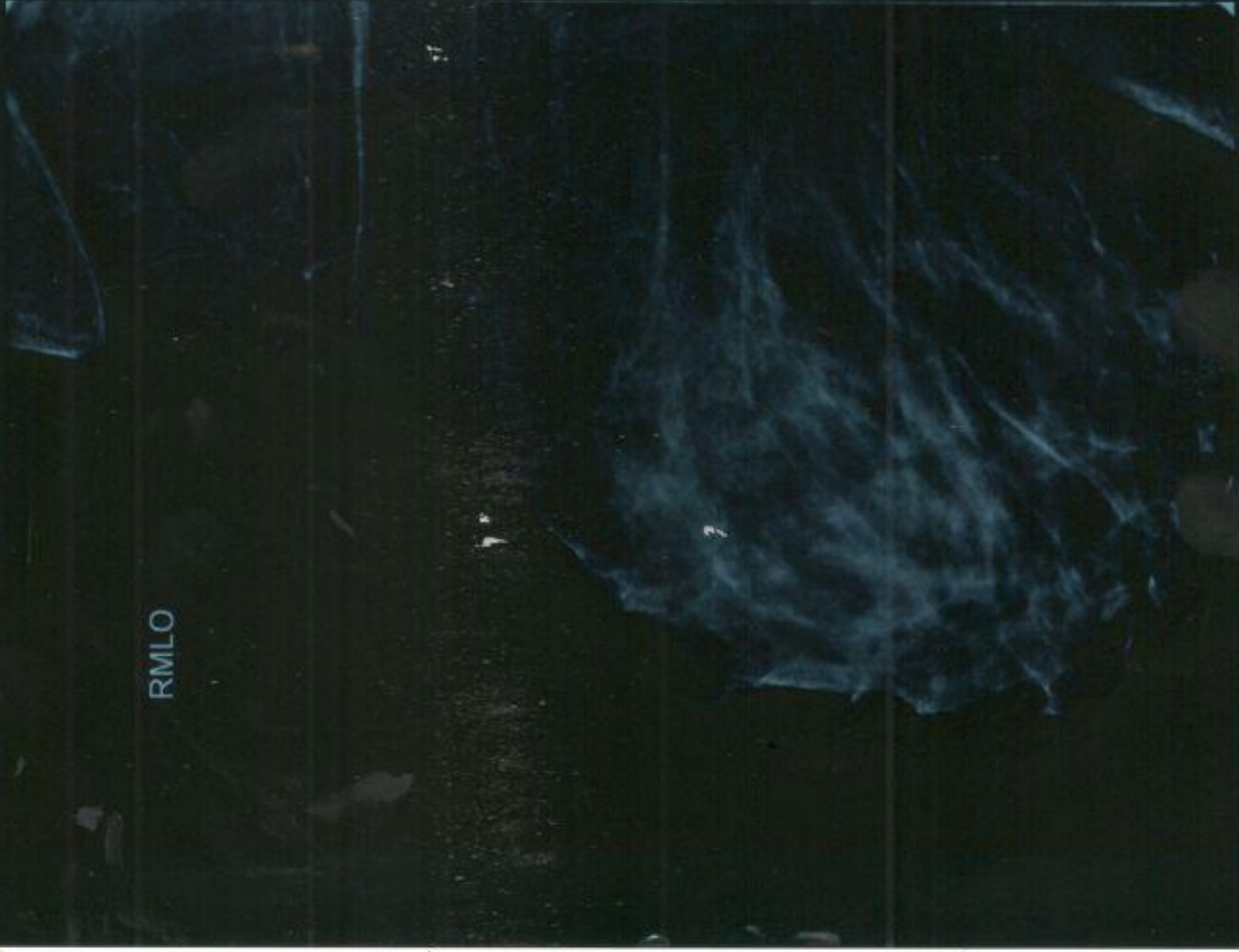MAVAT KSUMI 20X E 204/1924 MAMOCORADIV MLO YD0027E

R-CC

L-CC



L-mlo



RMLO

If the examinee is suffering from an acute life threatening situation, you may be obliged to disclose the result of the medical examination to the examinee.

1. Name of the examinee	:	Mr./Mrs./Ms. <u>Jayalakshmi</u>
2. Mark of Identification	:	(Mole/Scar/any other (specify location)):
3. Age/Date of Birth	:	<u>40</u> Gender: <u>F/M</u>
4. Photo ID Checked	:	(Passport/Election Card/PAN Card/Driving Licence/Company ID)

PHYSICAL DETAILS:

a. Height <u>157</u> (cms)	b. Weight <u>83</u> (Kgs)	c. Girth of Abdomen <u>78</u> (cms)
d. Pulse Rate <u>70</u> (/Min)	e. Blood Pressure:	Systolic <u>120</u> Diastolic <u>82</u>
	1 st Reading	
	2 nd Reading	

FAMILY HISTORY:

Relation	Age if Living	Health Status	If deceased, age at the time and cause
Father			
Mother			
Brother(s)			
Sister(s)			

HABITS & ADDICTIONS: Does the examinee consume any of the following?

Tobacco in any form	Sedative	Alcohol
<u>Nil</u>	<u>Nil</u>	<u>Nil</u>

PERSONAL HISTORY

- | | |
|---|---|
| a. Are you presently in good health and entirely free from any mental or Physical impairment or deformity. If No, please attach details. <u>Y/N</u> | c. During the last 5 years have you been medically examined, received any advice or treatment or admitted to any hospital? <u>Y/N</u> ✓ |
| b. Have you undergone/been advised any surgical procedure? <u>LSCS</u> <u>Y/N</u> | d. Have you lost or gained weight in past 12 months? <u>Y/N</u> ✓ |

Have you ever suffered from any of the following?

- | | |
|--|---|
| • Psychological Disorders or any kind of disorders of the Nervous System? <u>Y/N</u> ✓ | • Any disorder of Gastrointestinal System? <u>Y/N</u> ✓ |
| • Any disorders of Respiratory system? <u>Y/N</u> ✓ | • Unexplained recurrent or persistent fever, and/or weight loss <u>Y/N</u> ✓ |
| • Any Cardiac or Circulatory Disorders? <u>Y/N</u> ✓ | • Have you been tested for HIV/HBsAg / HCV before? If yes attach reports <u>Y/N</u> ✓ |
| • Enlarged glands or any form of Cancer/Tumour? <u>Y/N</u> ✓ | • Are you presently taking medication of any kind? <u>Y/N</u> ✓ |
| • Any Musculoskeletal disorder? <u>Y/N</u> ✓ | |

• Any disorders of Urinary System?

Y/N ✓

• Any disorder of the Eyes, Ears, Nose, Throat or Mouth & Skin

Y/N ✓

FOR FEMALE CANDIDATES ONLY

a. Is there any history of diseases of breast/genital organs?

Y/N ✓

d. Do you have any history of miscarriage/abortion or MTP

Y/N ✓

b. Is there any history of abnormal PAP Smear/Mammogram/USG of Pelvis or any other tests? (If yes attach reports)

Y/N ✓

e. For Parous Women, were there any complication during pregnancy such as gestational diabetes, hypertension etc

Y/N ✓

c. Do you suspect any disease of Uterus, Cervix or Ovaries?

Y/N ✓

f. Are you now pregnant? If yes, how many months?

Y/N ✓

CONFIDENTIAL COMMENTS FROM MEDICAL EXAMINER

➤ Was the examinee co-operative?

Y/N ✓

➤ Is there anything about the examinee's health, lifestyle that might affect him/her in the near future with regard to his/her job?

Y/N ✓

➤ Are there any points on which you suggest further information be obtained?

Y/N ✓

➤ Based on your clinical impression, please provide your suggestions and recommendations below;

..... Patient is clinically well, reports are well

➤ Do you think he/she is MEDICALLY FIT or UNFIT for employment.

MEDICAL EXAMINER'S DECLARATION

I hereby confirm that I have examined the above individual after verification of his/her identity and the findings stated above are true and correct to the best of my knowledge.

Name & Signature of the Medical Examiner : Dr Praveen S.L [Signature]

Seal of Medical Examiner : Dr. PRAVEEN S.L
MBBS
Reg. No: 74089



Name & Seal of DDRC SRL Branch :

Date & Time :

DDRC agilus Pathlabs Limited.

Corp. Office : Express House, Second Floor, Opp. Pothys Silks, Banerjee Road, Kaloor -682017
Contact :- 93334 93334, Web :- www.ddrcagilus.com Email :- info.ddrc@agilus.in

PATIENT NAME : JAYALAKSHMI

REF. DOCTOR : SELF

CODE/NAME & ADDRESS : CA00010147 -

MEDIWHEEL ARCOFEMI HEALTHCARE LIMITED
F701A, LADO SARAI, NEW DELHI,SOUTH DELHI,
DELHI,
SOUTH DELHI 110030
8800465156ACCESSION NO : **4182XB008785**

PATIENT ID : JAYAF3009834177

CLIENT PATIENT ID:

ABHA NO :

AGE/SEX : 40 Years Female

DRAWN :

RECEIVED : 24/02/2024 12:17:42

REPORTED : 26/02/2024 11:24:37

Test Report Status	<u>Preliminary</u>	Results	Biological Reference Interval	Units
--------------------	--------------------	---------	-------------------------------	-------

MEDIWHEEL HEALTH CHECKUP ABOVE 40(F)2DECHO**PHYSICAL EXAMINATION**

PHYSICAL EXAMINATION

REPORT GIVEN

**DR NISHA UNNI, MBBS,MD
(RD),DNB (Reg.No:50162)
Consultant Radiologist**

Page 1 Of 11



View Details



View Report

PERFORMED AT :DDRC AGILUS PATHLABS LIMITED
ASTER SQUARE BUILDING, ULLOOR,
MEDICAL COLLEGE P.O
TRIVANDRUM, 695011
KERALA, INDIA

Tel : 93334 93334, Fax : CIN - U85190MH2006PTC161480

Email : customercare.ddrc@agilus.in



Patient Ref. No. 66600007981078

PATIENT NAME : JAYALAKSHMI
REF. DOCTOR : SELF
CODE/NAME & ADDRESS : CA00010147 -
 MEDIWHEEL ARCOFEMI HEALTHCARE LIMITED
 F701A, LADO SARAI, NEW DELHI,SOUTH DELHI,
 DELHI,
 SOUTH DELHI 110030
 8800465156

ACCESSION NO : **4182XB008785**
PATIENT ID : JAYAF3009834177
CLIENT PATIENT ID:
ABHA NO :
AGE/SEX : 40 Years Female
DRAWN :
RECEIVED : 24/02/2024 12:17:42
REPORTED : 26/02/2024 11:24:37

Test Report Status	Preliminary	Results	Units
--------------------	-------------	---------	-------

MEDIWHEEL HEALTH CHECKUP ABOVE 40(F)2DECHO
ECG WITH REPORT
REPORT

REPORT GIVEN

2D - ECHO WITH COLOR DOPPLER
REPORT

REPORT GIVEN

USG ABDOMEN AND PELVIS
REPORT

REPORT GIVEN

CHEST X-RAY WITH REPORT
REPORT

REPORT GIVEN

MAMMOGRAPHY -BOTH
REPORT

REPORT GIVEN

HAEMATOLOGY
MEDIWHEEL HEALTH CHECKUP ABOVE 40(F)2DECHO
GLYCOSYLATED HEMOGLOBIN(HBA1C), EDTA WHOLE BLOOD

HBA1C	5.1	Non-diabetic Adult < 5.7	%
-------	-----	--------------------------	---


DR.NISHA UNNI, MBBS,MD
 (RD),DNB (Reg.No:50162)
 Consultant Radiologist


DR.HARI SHANKAR, MBBS MD
 (Reg No - TCMC:62092)
 HEAD - Biochemistry &
 Immunology


DR.VAISHALI RAJAN, MBBS DCP
 (Pathology)
 (Reg No - TCC 27150)
 HOD - HAEMATOLOGY

Page 2 Of 11



View Details



View Report

PERFORMED AT :

 DDRC AGILUS PATHLABS LIMITED
 ASTER SQUARE BUILDING, ULLOOR,
 MEDICAL COLLEGE P.O
 TRIVANDRUM, 695011
 KERALA, INDIA
 Tel : 93334 93334, Fax : CIN - U85190MH2006PTC161480
 Email : customercare.ddrc@agilus.in


Patient Ref. No. 66600007981078

PATIENT NAME : JAYALAKSHMI **REF. DOCTOR : SELF**

CODE/NAME & ADDRESS : CA00010147 - MEDIWHEEL ARCOFEMI HEALTHCARE LIMITED F701A, LADO SARAI, NEW DELHI,SOUTH DELHI, DELHI, SOUTH DELHI 110030 8800465156	ACCESSION NO : 4182XB008785 PATIENT ID : JAYAF3009834177 CLIENT PATIENT ID : ABHA NO :	AGE/SEX : 40 Years Female DRAWN : RECEIVED : 24/02/2024 12:17:42 REPORTED : 26/02/2024 11:24:37
---	--	--

Test Report Status	Preliminary	Results	Units
--------------------	-------------	---------	-------

MEAN PLASMA GLUCOSE	99.7	Pre-diabetes 5.7 - 6.4 Diabetes diagnosis: > or = 6.5 Therapeutic goals: < 7.0 Action suggested : > 8.0 (ADA Guideline 2021) < 116.0	mg/dL
---------------------	------	---	-------

BLOOD COUNTS,EDTA WHOLE BLOOD

HEMOGLOBIN	12.1	12.0 - 15.0	g/dL
RED BLOOD CELL COUNT	4.38	3.80 - 4.80	mil/ μ L
WHITE BLOOD CELL COUNT	8.69	4.0 - 10.0	thou/ μ L
PLATELET COUNT	318	150 - 410	thou/ μ L

RBC AND PLATELET INDICES

HEMATOCRIT	36.7	36.0 - 46.0	%
MEAN CORPUSCULAR VOL	83.8	83.0 - 101	fL
MEAN CORPUSCULAR HGB.	27.6	27.0 - 32.0	pg
MEAN CORPUSCULAR HEMOGLOBIN CONCENTRATION	33.0	31.50 - 34.50	g/dL
RED CELL DISTRIBUTION WIDTH	13.7	11.60 - 14.0	%
MENTZER INDEX	19.1		
MEAN PLATELET VOLUME	8.8	6.80 - 10.90	fL

WBC DIFFERENTIAL COUNT

SEGMENTED NEUTROPHILS	63	40.0 - 80.0	%
LYMPHOCYTES	32	20.0 - 40.0	%
MONOCYTES	4	2.0 - 10.0	%
EOSINOPHILS	1	1.0 - 6.0	%
BASOPHILS	0	0.0 - 1.0	%
ABSOLUTE NEUTROPHIL COUNT	5.47	2.0 - 7.0	thou/ μ L

DR.HARI SHANKAR, MBBS MD
(Reg No - TCMC:62092)
HEAD - Biochemistry & Immunology

DR.VAISHALI RAJAN, MBBS DCP
(Pathology)
(Reg No - TCC 27150)
HOD - HAEMATOLOGY



View Details



View Report

PERFORMED AT :

DDRC AGILUS PATHLABS LIMITED
ASTER SQUARE BUILDING, ULLLOOR,
MEDICAL COLLEGE P.O
TRIVANDRUM, 695011
KERALA, INDIA
Tel : 93334 93334, Fax : CIN - U85190MH2006PTC161480
Email : customercare.ddrc@agilus.in



Patient Ref. No. 66600007981078

PATIENT NAME : JAYALAKSHMI

REF. DOCTOR : SELF

CODE/NAME & ADDRESS : CA00010147 -
MEDIWHEEL ARCOFEMI HEALTHCARE LIMITED
F701A, LADO SARAI, NEW DELHI, SOUTH DELHI,
DELHI,
SOUTH DELHI 110030
8800465156

ACCESSION NO : **4182XB008785**
PATIENT ID : JAYAF3009834177
CLIENT PATIENT ID:
ABHA NO :

AGE/SEX : 40 Years Female
DRAWN :
RECEIVED : 24/02/2024 12:17:42
REPORTED : 26/02/2024 11:24:37

Test Report Status	Preliminary	Results	Units	
ABSOLUTE LYMPHOCYTE COUNT		2.75	1.0 - 3.0	thou/ μ L
ABSOLUTE MONOCYTE COUNT		0.35	0.20 - 1.0	thou/ μ L
ABSOLUTE EOSINOPHIL COUNT		0.07	0.02 - 0.50	thou/ μ L
ABSOLUTE BASOPHIL COUNT		0.00		thou/ μ L
NEUTROPHIL LYMPHOCYTE RATIO (NLR)		2.0		

ERYTHROCYTE SEDIMENTATION RATE (ESR), EDTA BLOOD

SEDIMENTATION RATE (ESR) **49 High** 0 - 20 mm at 1 hr

SUGAR URINE - POST PRANDIAL

SUGAR URINE - POST PRANDIAL NOT DETECTED NOT DETECTED

SUGAR URINE - FASTING

SUGAR URINE - FASTING NOT DETECTED NOT DETECTED

IMMUNOHAEMATOLOGY

MEDIWHEEL HEALTH CHECKUP ABOVE 40(F)2DECHO

ABO GROUP & RH TYPE, EDTA WHOLE BLOOD

ABO GROUP TYPE O
RH TYPE POSITIVE

METHOD : COLUMN AGGLUTINATION TECHNOLOGY

Interpretation(s)

Page 4 Of 11



DR. HARI SHANKAR, MBBS MD
(Reg No - TCMC:62092)
HEAD - Biochemistry &
Immunology



DR. VAISHALI RAJAN, MBBS DCP
(Pathology)
(Reg No - TCC 27150)
HOD - HAEMATOLOGY



View Details



View Report

PERFORMED AT :

DDRC AGILUS PATHLABS LIMITED
ASTER SQUARE BUILDING, ULLLOOR,
MEDICAL COLLEGE P.O
TRIVANDRUM, 695011
KERALA, INDIA
Tel : 93334 93334, Fax : CIN - U85190MH2006PTC161480
Email : customercare.ddrc@agilus.in



Patient Ref. No. 66600007981078

PATIENT NAME : JAYALAKSHMI

REF. DOCTOR : SELF

CODE/NAME & ADDRESS : CA00010147 -
MEDIWHEEL ARCOFEMI HEALTHCARE LIMITED
F701A, LADO SARAI, NEW DELHI, SOUTH DELHI,
DELHI,
SOUTH DELHI 110030
8800465156

ACCESSION NO : **4182XB008785**
PATIENT ID : JAYAF3009834177
CLIENT PATIENT ID:
ABHA NO :

AGE/SEX : 40 Years Female
DRAWN :
RECEIVED : 24/02/2024 12:17:42
REPORTED : 26/02/2024 11:24:37

Test Report Status	Preliminary	Results	Units
--------------------	-------------	---------	-------

ABO GROUP & RH TYPE, EDTA WHOLE BLOOD-Blood group is identified by antigens and antibodies present in the blood. Antigens are protein molecules found on the surface of red blood cells. Antibodies are found in plasma. To determine blood group, red cells are mixed with different antibody solutions to give A,B,O or AB.

Disclaimer: "Please note, as the results of previous ABO and Rh group (Blood Group) for pregnant women are not available, please check with the patient records for availability of the same."

The test is performed by both forward as well as reverse grouping methods.

BIO CHEMISTRY

MEDIWHEEL HEALTH CHECKUP ABOVE 40(F)2DECHO

BLOOD UREA NITROGEN (BUN), SERUM

BLOOD UREA NITROGEN	6	Adult(<60 yrs) : 6 to 20	mg/dL
---------------------	---	--------------------------	-------

Comments

Kindly correlate clinically.
Kindly contact lab within 24 hrs if clinically not correlated.

BUN/CREAT RATIO

BUN/CREAT RATIO	9.52
-----------------	------

CREATININE, SERUM

CREATININE	0.63	18 - 60 yrs : 0.6 - 1.1	mg/dL
------------	------	-------------------------	-------

GLUCOSE, POST-PRANDIAL, PLASMA

GLUCOSE, POST-PRANDIAL, PLASMA	135	Diabetes Mellitus : > or = 200. Impaired Glucose tolerance/ Prediabetes : 140 - 199. Hypoglycemia : < 55.	mg/dL
--------------------------------	-----	--	-------



DR. HARI SHANKAR, MBBS MD
(Reg No - TCMC:62092)
HEAD - Biochemistry &
Immunology



DR. VAISHALI RAJAN, MBBS DCP
(Pathology)
(Reg No - TCC 27150)
HOD - HAEMATOLOGY

Page 5 Of 11



View Details



View Report

PERFORMED AT :

DDRC AGILUS PATHLABS LIMITED
ASTER SQUARE BUILDING, ULLOOR,
MEDICAL COLLEGE P.O
TRIVANDRUM, 695011
KERALA, INDIA
Tel : 93334 93334, Fax : CIN - U85190MH2006PTC161480
Email : customercare.ddrc@agilus.in



Patient Ref. No. 66600007981078

PATIENT NAME : JAYALAKSHMI

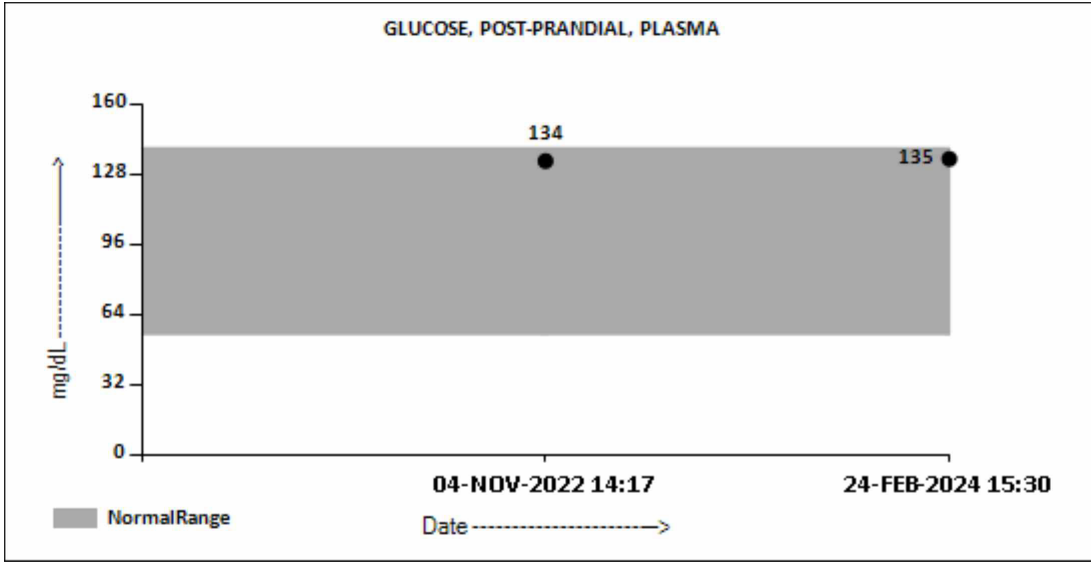
REF. DOCTOR : SELF

CODE/NAME & ADDRESS : CA00010147 -
 MEDIWHEEL ARCOFEMI HEALTHCARE LIMITED
 F701A, LADO SARAI, NEW DELHI,SOUTH DELHI,
 DELHI,
 SOUTH DELHI 110030
 8800465156

ACCESSION NO : **4182XB008785**
PATIENT ID : JAYAF3009834177
CLIENT PATIENT ID:
ABHA NO :

AGE/SEX : 40 Years Female
DRAWN :
RECEIVED : 24/02/2024 12:17:42
REPORTED : 26/02/2024 11:24:37

Test Report Status	Preliminary	Results	Units
--------------------	-------------	---------	-------



GLUCOSE FASTING,FLUORIDE PLASMA

FBS (FASTING BLOOD SUGAR)	92	Diabetes Mellitus : > or = 126. mg/dL Impaired fasting Glucose/ Prediabetes : 101 - 125. Hypoglycemia : < 55.
---------------------------	----	--

DR.HARI SHANKAR, MBBS MD
 (Reg No - TCMC:62092)
**HEAD - Biochemistry &
 Immunology**



View Details



View Report

PERFORMED AT :

DDRC AGILUS PATHLABS LIMITED
 ASTER SQUARE BUILDING, ULLOOR,
 MEDICAL COLLEGE P.O
 TRIVANDRUM, 695011
 KERALA, INDIA
 Tel : 93334 93334, Fax : CIN - U85190MH2006PTC161480
 Email : customercare.ddrc@agilus.in



Patient Ref. No. 66600007981078

PATIENT NAME : JAYALAKSHMI

REF. DOCTOR : SELF

CODE/NAME & ADDRESS : CA00010147 -
 MEDIWHEEL ARCOFEMI HEALTHCARE LIMITED
 F701A, LADO SARAI, NEW DELHI, SOUTH DELHI,
 DELHI,
 SOUTH DELHI 110030
 8800465156

ACCESSION NO : **4182XB008785**
PATIENT ID : JAYAF3009834177
CLIENT PATIENT ID:
ABHA NO :

AGE/SEX : 40 Years Female
DRAWN :
RECEIVED : 24/02/2024 12:17:42
REPORTED : 26/02/2024 11:24:37

Test Report Status	Preliminary	Results	Units
TOTAL PROTEIN		6.7 Ambulatory : 6.4 - 8.3 Recumbant : 6 - 7.8	g/dL
URIC ACID, SERUM			
URIC ACID		5.1 Adults : 2.4-5.7	mg/dL

BIOCHEMISTRY - LIPID

MEDIWHEEL HEALTH CHECKUP ABOVE 40(F)2DECHO

LIPID PROFILE, SERUM

CHOLESTEROL	224	Desirable : < 200 Borderline : 200-239 High : >or= 240	mg/dL
TRIGLYCERIDES	194 High	Normal : < 150 High : 150-199 Hypertriglyceridemia : 200-499 Very High : > 499	mg/dL
HDL CHOLESTEROL	39	General range : 40-60	mg/dL
LDL CHOLESTEROL, DIRECT	163 High	Optimum : < 100 Above Optimum : 100-129 Borderline High : 130-159 High : 160-189 Very High : >or= 190	mg/dL
NON HDL CHOLESTEROL	185	Desirable : < 130 Above Desirable : 130 -159 Borderline High : 160 - 189 High : 190 - 219 Very high : > / = 220	mg/dL
VERY LOW DENSITY LIPOPROTEIN CHOL/HDL RATIO	38.8 5.7	</= 30.0 Low Risk : 3.3 - 4.4 Average Risk : 4.5 - 7.0 Moderate Risk : 7.1 - 11.0 High Risk : > 11.0	mg/dL
LDL/HDL RATIO	4.2	Desirable/Low Risk - 0.5-3	

DR. HARI SHANKAR, MBBS MD
 (Reg No - TCMC:62092)
 HEAD - Biochemistry &
 Immunology



View Details



View Report

PERFORMED AT :

DDRC AGILUS PATHLABS LIMITED
 ASTER SQUARE BUILDING, ULLLOOR,
 MEDICAL COLLEGE P.O
 TRIVANDRUM, 695011
 KERALA, INDIA
 Tel : 93334 93334, Fax : CIN - U85190MH2006PTC161480
 Email : customercare.ddrc@agilus.in



Patient Ref. No. 66600007981078

PATIENT NAME : JAYALAKSHMI

REF. DOCTOR : SELF

CODE/NAME & ADDRESS : CA00010147 -

MEDIWHEEL ARCOFEMI HEALTHCARE LIMITED
F701A, LADO SARAI, NEW DELHI, SOUTH DELHI,
DELHI,
SOUTH DELHI 110030
8800465156

ACCESSION NO : 4182XB008785

PATIENT ID : JAYAF3009834177

CLIENT PATIENT ID:

ABHA NO :

AGE/SEX : 40 Years Female

DRAWN :

RECEIVED : 24/02/2024 12:17:42

REPORTED : 26/02/2024 11:24:37

Test Report Status	Preliminary	Results	Units
--------------------	-------------	---------	-------

Borderline/Moderate Risk- 3.1-6
High Risk- >6.0

HISTOPATHOLOGY

MEDIWHEEL HEALTH CHECKUP ABOVE 40(F)2DECHO RESULT PENDING

CYTOLOGY - CS (PAP SMEAR) RESULT PENDING

SPECIALISED CHEMISTRY - HORMONE

MEDIWHEEL HEALTH CHECKUP ABOVE 40(F)2DECHO

THYROID PANEL, SERUM

T3	140.00	Non-Pregnant : 80-200	ng/dL
		Pregnant Trimester-wise	
		1st : 81-190	
		2nd : 100-260	
		3rd : 100-260	
T4	8.84	Adults : 4.5-12.1	µg/dl
TSH 3RD GENERATION	3.820	Non-Pregnant : 0.4-4.2	µIU/mL
		Pregnant Trimester-wise :	
		1st : 0.1 - 2.5	
		2nd : 0.2 - 3	
		3rd : 0.3 - 3	


CLINICAL PATH - URINALYSIS


MEDIWHEEL HEALTH CHECKUP ABOVE 40(F)2DECHO

PHYSICAL EXAMINATION, URINE

COLOR **AMBER**

Page 9 Of 11


DR. HARI SHANKAR, MBBS MD
(Reg No - TCMC:62092)
HEAD - Biochemistry &
Immunology


DR. VAISHALI RAJAN, MBBS DCP
(Pathology)
(Reg No - TCC 27150)
HOD - HAEMATOLOGY



View Details



View Report

PERFORMED AT :

DDRC AGILUS PATHLABS LIMITED
ASTER SQUARE BUILDING, ULLOOR,
MEDICAL COLLEGE P.O
TRIVANDRUM, 695011
KERALA, INDIA
Tel : 93334 93334, Fax : CIN - U85190MH2006PTC161480
Email : customercare.ddrc@agilus.in



Patient Ref. No. 66600007981078

PATIENT NAME : JAYALAKSHMI	REF. DOCTOR : SELF	
CODE/NAME & ADDRESS : CA00010147 - MEDIWHEEL ARCOFEMI HEALTHCARE LIMITED F701A, LADO SARAI, NEW DELHI,SOUTH DELHI, DELHI, SOUTH DELHI 110030 8800465156	ACCESSION NO : 4182XB008785 PATIENT ID : JAYAF3009834177 CLIENT PATIENT ID: ABHA NO :	AGE/SEX : 40 Years Female DRAWN : RECEIVED : 24/02/2024 12:17:42 REPORTED : 26/02/2024 11:24:37

Test Report Status	Preliminary	Results	Units
--------------------	-------------	---------	-------

APPEARANCE CLEAR

CHEMICAL EXAMINATION, URINE

PH	5.0	4.7 - 7.5
SPECIFIC GRAVITY	1.026	1.003 - 1.035
PROTEIN	NEGATIVE	NOT DETECTED
GLUCOSE	NEGATIVE	NOT DETECTED
KETONES	NEGATIVE	NOT DETECTED
BLOOD	NEGATIVE	NOT DETECTED
BILIRUBIN	NEGATIVE	NOT DETECTED
UROBILINOGEN	NORMAL	NORMAL
NITRITE	NEGATIVE	NOT DETECTED

MICROSCOPIC EXAMINATION, URINE

RED BLOOD CELLS	NOT DETECTED	NOT DETECTED	/HPF
WBC	0-1	0-5	/HPF
EPITHELIAL CELLS	8-10	0-5	/HPF
CASTS	NEGATIVE		
CRYSTALS	NEGATIVE		
REMARKS	NIL		

CLINICAL PATH - STOOL ANALYSIS

MEDIWHEEL HEALTH CHECKUP ABOVE 40(F)2DECHO

PHYSICAL EXAMINATION,STOOL

COLOUR	BROWN
CONSISTENCY	SEMI FORMED
MUCUS	ABSENT NOT DETECTED

DR.VAISHALI RAJAN, MBBS DCP
(Pathology)
(Reg No - TCC 27150)
HOD - HAEMATOLOGY



View Details



View Report

PERFORMED AT :

DDRC AGILUS PATHLABS LIMITED
ASTER SQUARE BUILDING, ULLOOR,
MEDICAL COLLEGE P.O
TRIVANDRUM, 695011
KERALA, INDIA
Tel : 93334 93334, Fax : CIN - U85190MH2006PTC161480
Email : customercare.ddrc@agilus.in



Patient Ref. No. 66600007981078

