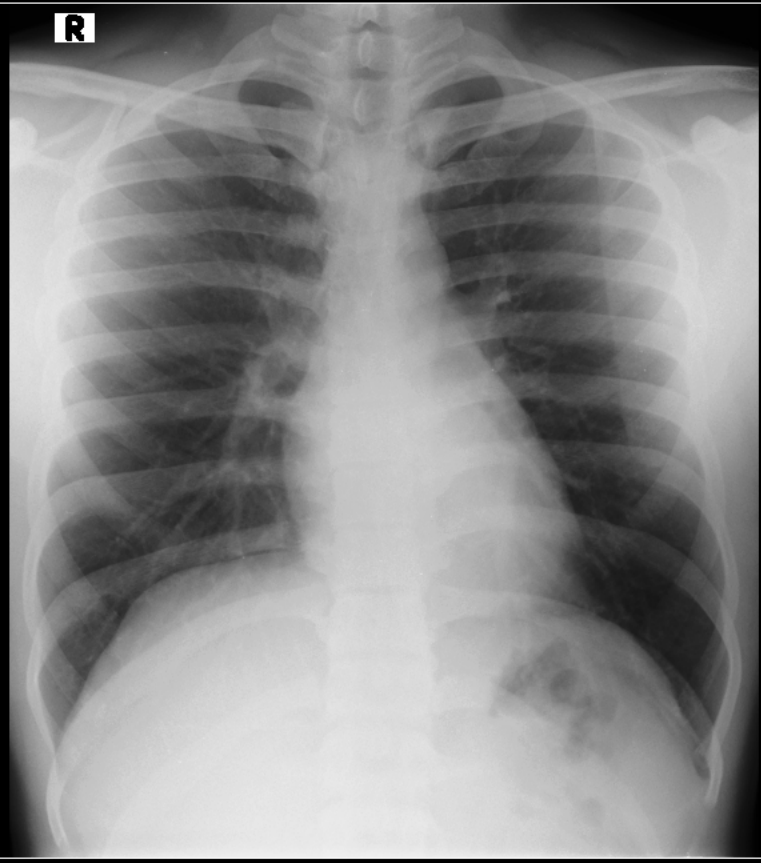




R



Navigation controls: Home, Previous (1/1), Next, Refresh, Confirm (green checkmark)



Marker



Image rotation/reversal



Trimming



Shadow-Masking Processing



Order information



Image Processing



S value/L value



Distribution Setting



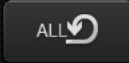GA

1.1

GS

-0.11

All QA



FPD

PC

HOS





# True Life Medical Centre Pvt. Ltd.

68/019, Opp. C.K.C.L.P School,  
Next to Dr. Zoo, Subhash Chandra  
Bose Road, Ponnuruni, Vyttila,  
ERNAKULAM - 682 019.

9745107100

mail@truelifemedicalcentre.com

www.truelifemedicalcentre.com

Located at THANC Hospital,  
Next to Aarthi Scans,  
No. 747, kilpauk,  
CHENNAI - 600 010

9940188598

chennai@truelifemedicalcentre.com

Name	MANMOHAN M	Date:	26/09/2024
Age/Sex	26 / M	OP No.	132563

## BLOOD ROUTINE EXAMINATION

Test Description	Value	Ref. Range
Hb	14.9 gm %	M-12 -16 gm % W- 11 - 14gm %
RBC	4.3 milliom/cumm	M- 4.7-6.1 milliom/cumm W- 4.2-5.4 milliom/cumm
PCV	40.3 %	35 - 40%
MCV	96.5 fl	80 - 100
MCH	34.3 Pg	27.5 - 33.2 gm
MCHC	36.9 g/dl	33.5 - 35.4 g/dl
Platelets	280000 cell/cumm	1.5 - 4 Lakh cell/cumm
WBC	4200 cells/cumm	4,500-11,000cells/cumm
Differential count		
Neutrophils	53%	50 - 60 %
Lymphocytes	41%	20 - 40 %
Eosinophils	04%	1 - 4 %
Monocytes	02%	0 - 1 %
Basophils	00%	0 - 1 %
ESR	16 mm/hr	0 - 15 mm/hr



  
**SUJATHA JAYAN, DMLT  
LAB TECHNICIAN**



# True Life Medical Centre Pvt. Ltd.

68/019, Opp. C.K.C.L.P School,  
Next to Dr. Zoo, Subhash Chandra  
Bose Road, Ponnuranni, Vyttila,  
ERNAKULAM - 682 019.

9745107100

mail@truelifemedicalcentre.com

www.truelifemedicalcentre.com

Located at THANC Hospital,  
Next to Aarthi Scans,  
No. 747, kilpauk,  
CHENNAI - 600 010

9940188598

chennai@truelifemedicalcentre.com

Name	MANMOHAN M	Date:	26/09/2024
Age/Sex	26 / M	OP No.	132563

## URINE ROUTINE AND MICROSCOPIC EXAMINATION

Test Description	Value	Ref. Range
Volume	20 ml	
Colour/Clarity	Pale Yellow/Clear	Pale Yellow
Urine pH	6.0	4.5 - 8
Specific Gravity	1.010	
Glucose	Negative	Negative
Protein	Negative	Negative
Ketone	Negative	Negative
Bile salts	Negative	Negative
Urobilinogen	Normal	Normal
WBC/HPF	2-3	0 - 2
RBC/HPF	Nil	0 - 1
Crystal/Casts type/HPF	Nil	Not seen
Bacteria/HPF	Nil	Not seen
Epithelial Cells/HPF	1-2	0 - 5
URINE COTININE	75 ng/mL	Smokers : $\geq$ 200 NonSmokers: $<$ 200



  
**SUJATHA JAYAN, DMLT**  
**LAB TECHNICIAN**





# True Life Medical Centre Pvt. Ltd.

68/019, Opp. C.K.C.L.P School,  
Next to Dr. Zoo, Subhash Chandra  
Bose Road, Ponnuranni, Vyttila,  
ERNAKULAM - 682 019.

9745107100

mail@truelifemedicalcentre.com

Located at THANC Hospital,  
Next to Aarthi Scans,  
No. 747, Kilpauk,  
CHENNAI - 600 010

9940188598

chennai@truelifemedicalcentre.com

www.truelifemedicalcentre.com

Name	MANMOHAN M	Date:	26/09/2024
Age/Sex	26 / M	OP No.	132563

## FECALYSIS

### MACRO EXAMINATION

Colour	:	Brownish-yellow
Reaction	:	Alkaline
Consistency	:	Solid
Mucus	:	Nil
Blood	:	Nil

### MICROSCOPIC EXAMINATION

OVA	:	Nil
Cyst	:	Nil
Vegetative Cells	:	Present
Bacteria	:	Present
Pus Cells	:	I-2MPF
Epithelial cells	:	O-I/HFF
Occult Blood	:	Negative

  
SUJATHA JAYAN, DMLT  
LAB TECHNICIAN





# True Life Medical Centre Pvt. Ltd.

68/019, Opp. C.K.C.L.P School,  
Next to Dr. Zoo, Subhash Chandra  
Bose Road, Ponnuranni, Vyttila,  
ERNAKULAM - 682 019.

9745107100

mail@truelifemedicalcentre.com

Located at THANC Hospital,  
Next to Aarthi Scans,  
No. 747, Kilpauk,  
CHENNAI - 600 010

9940188598

chennai@truelifemedicalcentre.com

www.truelifemedicalcentre.com

Name	MANMOHAN M	Date:	26/09/2024
Age/Sex	26 / M	OP No.	132563

## REPORT OF X RAY CHEST

**Bony Cage:** Normal. Imaged skeleton is intact with no fractures or destructive bony lesions visible. Visible soft tissues are unremarkable.

**Penetration:** Adequate; Vertebral bodies just visible behind the heart

**Inspiration:** Adequate; 7 Anterior ribs are visible.

**Rotation:** Trachea is central after factoring in patient's rotation

**Lungs:** Both lung fields are normal and not hyper inflated. Pulmonary vascularity is normal and there are no abnormal opacities. No evidence of pleural thickening. Both right and left hilums are normal. Costo-phrenic angles are clear.

Heterogenous opacity of the apical lobe of Right Lung.

**Heart:** Normal in size and shape. Cardiac borders are clear. Aorta appears normal.

**Mediastinum:** Central with no mediastinal widening.

**Diaphragm:** Normal appearance. Position of hemi-diaphragms are normal. No pneumo peritoneum seen.

No evidence of hydro or pneumothorax.

**Report:** Clinical Corelation required.



**Dr. K.K. Mohammed**

**Dr. MOHAMED KUDAKORIGOTHI**  
Reg. No. 55039,DFC-C/B 0701 B.Sc,MBBS,DPH  
D.G. Shipping Approved  
Approval No. KRL/KCH/09/2016  
Mob: 09447327569  
E-mail:kkmohammed@truelifemedicalcentre.com



# True Life Medical Centre Pvt. Ltd.

68/019, Opp. C.K.C.L.P School,  
Next to Dr. Zoo, Subhash Chandra  
Bose Road, Ponnuruni, Vyttila,  
ERNAKULAM - 682 019.

9745107100

mail@truelifemedicalcentre.com

www.truelifemedicalcentre.com

Located at THANC Hospital,  
Next to Aarthi Scans,  
No. 747, Kilpauk,  
CHENNAI - 600 010

9940188598

chennai@truelifemedicalcentre.com

Date:26/09/2024

## TO WHOMSOEVER IT MAY CONCERN

This is to certify that **MR. MANMOHAN M**, aged **26** yrs, was evaluated by me for medical Check-up at True Life Medical Centre, Kochi. He is asymptomatic. Clinical Examination is normal.

Height : 171 cm

Weight : 68 kg

BMI : 23.3 kg/m<sup>2</sup>

BP : 106/78

PULSE : 71/MT

RESPIRATION :18/MT

**MEDICALLY FIT**

**Dr. K.K.MOHAMMED**



**Dr. MOHAMED KUDAKORIGOTHI**  
Reg. No. 55039,DFC-C/B 0701 B.Sc,MBBS,DPH  
D.G. Shipping Approved  
Approval No. KRL/KCH/09/2016  
Mob: 09447327569  
E-mail:kkmohammed@truelifemedicalcentre.com





# True Life Medical Centre Pvt. Ltd.

68/019, Opp. C.K.C.L.P School,  
Next to Dr. Zoo, Subhash Chandra  
Bose Road, Ponnuruni, Vyttila,  
ERNAKULAM - 682 019.

9745107100

mail@truelifemedicalcentre.com

www.truelifemedicalcentre.com

Located at THANC Hospital,  
Next to Aarthi Scans,  
No. 747, Kilpauk,  
CHENNAI - 600 010

9940188598

chennai@truelifemedicalcentre.com

Name	MANMOHAN M	Date:	26/09/2024
Age/Sex	26 / M	OP No.	132563

## SIGHT TEST CERTIFICATE

		Right Eye	Left Eye	Both Eyes	Result
Distance Vision	Unaided	6/6	6/6	6/6	PASS
	Aided				
Near Vision	Unaided	N/6	N/6	N/6	PASS
	Aided				
Field of Vision	Horizontal plane	Normal	Normal	Normal	PASS
	Vertical plane	Normal	Normal	Normal	PASS
Colour Vision	Ishihara	Colour Index Normal			PASS
	Lantern/Others				



Dr. K.K. Mohammed

MOHAMED KUDAKORIGOTHI

Reg. No. 55039, DFC-C/B 0701 B.Sc, MBBS, DPH

D.G. Shipping Approved

Approval No. KRL/KCH/09/2016

Mob: 09447327569

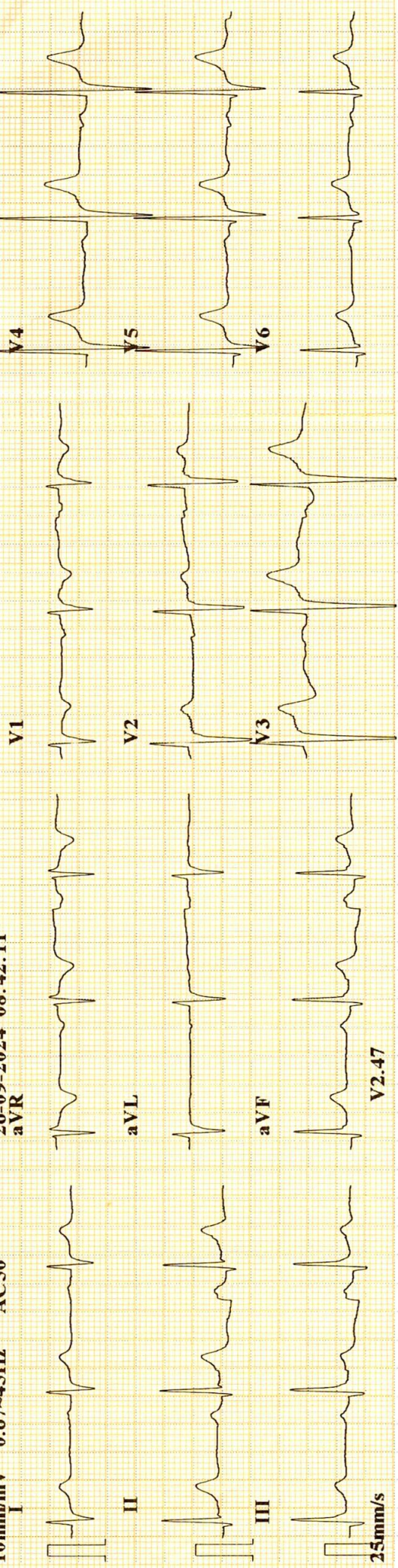
E-mail: kkmohammed@truelifemedicalcentre.com



BPL

10mm/mV 0.67-45Hz AC50

26-09-2024 08:42:11



CARDIART

*Normal ECG Right axis. No significant*  
*ST-T changes*

ID	: 240926-0843
Name	: <b>Mamohan . M</b>
Age	: 26 yr
Sex	: Male
BP	: mmHg
Height	: cm
Weight	: kg
HR	: 69 bpm
P Dur	: 123 ms
PR int	: 202 ms
QRS Dur	: 106 ms
QT/QTc int	: 361/388 ms
P/QRS/T axis	: 76/92/61 °
RV5/SV1 amp	: 1.664/0.584 mV
RV5+SV1 amp	: 2.248 mV
RV6/SV2 amp	: 0.964/0.948 mV

**Dr. MOHAMED KUDAKORIGOTHI**  
 Reg. No. 55039,DFC-C/B 0701 &.sc,MBBS,DPH  
 D.G. Shipping Approved  
 Approval No. KRL/KCH/09/2016  
 Mob: 09447327569  
 E-mail: kkmohammed@truelifemedicalcentre.com









GPS Map  
Camera Lite

Building No. 53/2267 B2 , First Floor Vilangadan Arcade Opp.  
CKCLP School, near Canara Bank, Ponnurunni, Vyttila, Kochi,  
Ernakulam, Kerala 682019, India

Latitude  
9.9742967°

Longitude  
76.3146259°

Local 09:42:48 AM  
GMT 04:12:48 AM

Altitude 8 meters  
Thursday, 26.09.2024

Note : Captured by GPS Map Camera Lite