

1



*Singh*



**MALIK RADIX HEALTH CARE PVT. LTD.**  
 C-217, C-218, Nirman Vihar,  
 Delhi-110092  
 Ph.: 011-48287456, 011-51381379  
 Regd. No. 607

RADIX  
HEALTH  
care



<sup>ENT</sup>  
Malik Radix Healthcare

C/217, C/218, Vikas Marg, Nirman Vihar, New Delhi-110092  
A Unit of Malik Radix Healthcare  
Toll Free - 1800-120-5457  
Whatsapp No. - 9811550650  
E-mail: info@radixhealthcare.org  
Website: www.radixhealthcare.org



Mrs. Ambika Singh  
Age - 35 yr / Female

(Pre-Insurance)

19/03/24

Hi emu

nose

throat

HEAD

Dr. ASHOK SINGH  
MBBS, MS (ENT)  
Senior ENT & Head  
Neck Skull Base Surgeon  
Regd. No. DMS-20202  
MALIK RADIX HEALTHCARE PVT. LTD.

### Facilities Available

- Multispeciality Hospital - 24 Hours Emergency - X-Ray/ ECG/ Ultrasound/ CT Scan - Dental- Fully Equipped Operation Theatre  
- Fully Functional Lab - 24/7 Casualty/ ICU-Nursery 24/7 Pharmacy - Labour Room - All Speciality OPD - Laproscopic Surgery -  
ECHO - Plastic Surgery

Ambika Singh

*(Signature)*

ID: 9910694489

35years Female

Heart rate	74 bpm
QRS duration	92 ms
QT/QTc	384/426 ms
PR interval	166 ms
P duration	94 ms
RR interval	810 ms
P-R-T axes	-3 26 6

MAC600 1.02

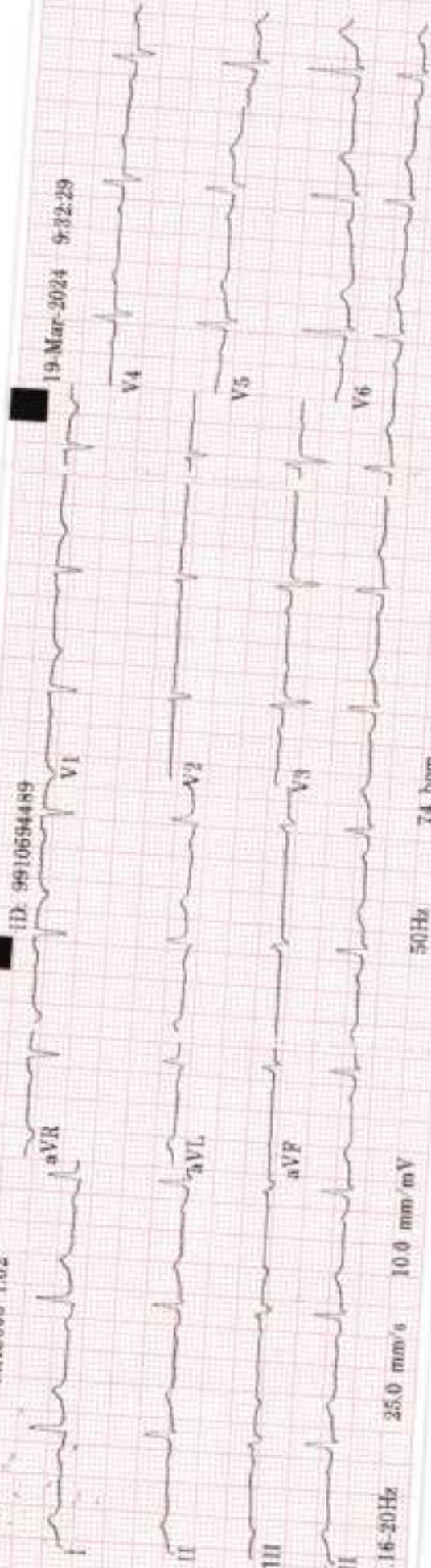12SL™ v239

19-Mar-2024 9:32:29

ID: 9910694489

0.16-20Hz 25.0 mm/s 10.0 mm/mV

50Hz 74 bpm



by 2.5s + 1 rhythm Id

2



# Malik Radix HealthCare.

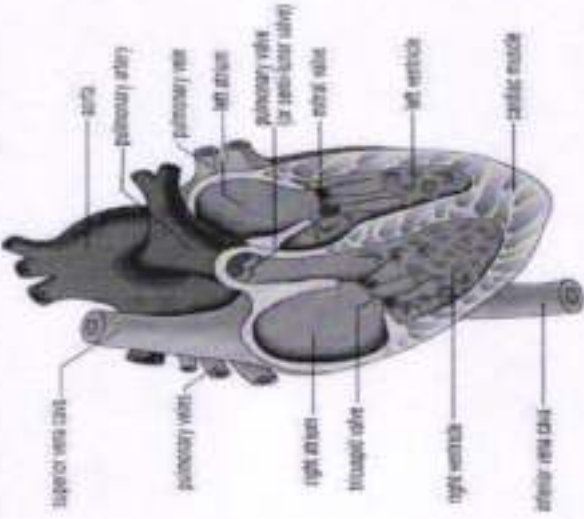
## ELECTROCARDIOGRAM

Name: MRS. AMBIKA SINGH

Age & Sex: 35 YR/ FEMALE

Ref By: MEDIWHEEL

Date: 19/03/2024



### ECG FINDINGS:

Rate 74 bpm Rhythm Sinus Mechanism Normal

Axis Normal P Wave Normal PR Interval 0.16/Sec

QRS Complex Normal QT Interval Normal Q Wave Normal

ST Segment Normal T Wave Normal

Conclusion Sinus Rhythm, Normal Axis, WNL.

Doctors Signature Dr. SHEIKH NAZIR AHMED  
M.D. Physician  
MGDCC  
DMC-46499



Name - Mrs. Ambika Singh  
Age - 35yrs / Female

(Pre-insurance)

19/03/24

Vis L 6/9 ~~8/10~~  
6/9 ~~8/10~~

DES

Mean th L N6  
N6

Color Vis L WNL

Adm

Hyperlax

(R)

*MDG*  
Dr. Madhi Gupta  
MBBS, MS, DNB  
Casualty Ophthalmologist  
Malik Radix Healthcare Pvt. Ltd.  
DMC No. 121661

Facilities Available

- Multispeciality Hospital - 24 Hours Emergency - X-Ray/ ECG/ Ultrasound/ CT Scan - Dental- Fully Equipped Operation Theatre
- Fully Functional Lab - 24/7 Casualty/ ICU-Nursery 24/7 Pharmacy - Labour Room - All Speciality OPD - Laproscopic Surgery - ECHO - Plastic Surgery



**CONSULTANTS ON PANEL**

**PEDIATRICS**

Dr. Hari Malik (MBBS, MD)  
Dr. Hari Prasad (MBBS, MD, FR)  
Dr. Ritu Jain (MBBS, MD)

**GYNACCOLOGY**

Dr. Renu Malik (MBBS, MD)  
Dr. Meenu Mathora (MBBS, MD)  
Dr. Rajni (MBBS, MD)  
Dr. Manju Gupta (MBBS, MD)  
Dr. Vandana Saini (MBBS, DGO)  
Dr. Suparna Anand (MBBS, MD)

**DENTAL**

Dr. Shrutika Malik (BDS, MDS)  
Dr. Annu Saini (BDS, MDS)  
Dr. Ruchi Thakur (BDS, MDS)  
Dr. Mahesh Mehta (BDS, MDS)  
Dr. Taran Mittal (BDS, MDS)  
Dr. Geetika Sharma (BDS)  
Dr. Shikha Verma (BDS)

**CHILD GASTROENTEROLOGY**

Dr. S. K. Mehta (MBBS, MD)

**MEDICINE**

Dr. A. S. Talwar (MBBS, MD)  
Dr. Sunny Ujjal (MBBS, MD)  
Dr. Surendra Rajan (MBBS, MD)

**RESPIRATORY MEDICINE/PULMONOLOGY**

Dr. Anshu Bhatnagar (MBBS, DNB)

**LAPROSCOPY SURGERY**

Dr. Anju Jain (MBBS, MD)  
Dr. Deepak Saini (MBBS, MD)  
Dr. Pradeep Saini (MBBS, MD)  
Dr. G. S. Garg (MBBS, MD)

**ORTHOPAEDICS**

Dr. Vikas Shrivastava (MBBS, MD, DOrtho, DNB)  
Dr. Prabhakar Aggarwal (MBBS, MD, DOrtho)  
Dr. K. K. Tewari (MBBS, MD, DOrtho)  
Dr. Deepak Kumar Anand (MBBS, MD, DOrtho)

**EYE/OPTHALMOLOGY**

Dr. Neha Gupta (MBBS, MD, DNB, FICMR)  
Dr. Himanshu Singh Puri (MBBS, MD)

**ENT**

Dr. Sharan Kumar Singh (MBBS, MD)  
Dr. Praveen Sharma (MBBS, MD)  
Dr. Ashish Singh (MBBS, MD)  
Dr. A. K. Lohan (MBBS, MD)

**RADIOLOGY (ULTRASOUND)**

Dr. K. K. Singh (MBBS, DNB)  
Dr. T. K. Vatsa (MBBS, MD)  
Dr. Rajesh Mathora (MBBS, MD)  
Dr. Ashish Tomar (MBBS, MD)

**PATHOLOGY**

Dr. Pooja Dahiya (MBBS, MD, FRCH)  
Dr. Meenu Aggarwal (MBBS, MD, FRCH)

**ANAESTHESIA**

Dr. Harsh Chahal (MBBS, MD)  
Dr. Rakshit Arora (MBBS, MD)  
Dr. P. K. Anand (MBBS, MD)  
Dr. Sangeeta Garg (MBBS, MD)

**DERMATOLOGY**

Dr. Niharika Jha (MBBS, MD)

**PLASTIC & COSMETIC SURGERY**

Dr. Anshu Jain (MBBS, MS, MCh)

**PAEDIATRIC SURGERY**

Dr. Sharmendra Singh (MBBS, MS, MCh)  
Dr. Satish Aggarwal (MBBS, MS, MCh)

**PAEDIATRIC NEPHROLOGY**

Dr. A. S. Vasudevan (MD, Dip. in Paed.)

**NEPHROLOGY**

Dr. Jyoti (MBBS, MD, Nephro)

**CARDIOLOGY**

Dr. Mahesh Tyagi (MBBS, MD)

**NEUROLOGY**

Dr. Anil Bhatia (MBBS, MD)

**GASTROENTEROLOGY**

Dr. Deepak Lohan (MBBS, MD)  
Dr. Parvath Aggarwal (MBBS, MD)  
Dr. Ashish Goyal (MBBS, MD)  
Dr. Ankur Singhal (MBBS, MD)

**UROLOGY**

Dr. Nikhil Sharma (MBBS, MCh)  
Dr. Ankur Singhal (MBBS, MD)

**PSYCHIATRY**

Dr. Mohit Sharma (MBBS, MD)

**PHYSIOTHERAPY**

Dr. Kirti Dandani  
Dr. Renu Kumar

**NUTRITIONIST**

Dr. Deepika Tuli  
Dr. Sakshi Paree

**CLINICAL PSYCHOLOGIST**

Dr. Sanku Singh

## Dr. Shrutika Malik

BDS, MDS (Endodontics)

☎ +91-98999561092

Name : Anubika

Age/Sex : 35y / F

Date : 19/3/24

**Timings : 10:00 am. to 2:00 pm.  
6:00 pm. to 8:30 pm.**

**For Appointment**

☎ 011-45152510  
☎ +91-9999254639

**CLINICAL EXAMINATION:-**

1. TMJ:-

Routine checkup

2. DENTAL STATUS:-

- a. Caries Teeth :
- b. Fracture Teeth :
- c. Root Stumps :
- d. Gingivitis :
- e. Periodontitis :
- f. Impacted Teeth :
- g. Malaligned Teeth :

O/E

Stains ++

Calculus ++

Cavities

8 Initial

Adv.

Oral prophylaxis

3. ORAL LESIONS:-

P-Kit

4. DIAGNOSIS:-

5. TREATMENT PLANNING:

6. FOLLOW UP:-

Referral To Other Consultant: Yes/ No

If Yes, please mention the Name: .....

Doctor's Signature Annu

**Facilities Available :**

- \* MULTI-SPECIALITY HOSPITAL \* MODULAR FULLY EQUIPPED OT \* NURSERY \* LAPROSCOPIC SURGERY
- \* 24X7 EMERGENCY \* OPG \* DENTAL \* 24X7 DIAGNOSTICS \* LABOUR ROOM \* ECHO \* EEG \* DIGITAL X-RAY \* CT SCAN
- \* ECG \* ULTRASOUND \* RICU/ICU \* ALL SPECIALITY OPD \* PLASTIC & COSMETIC SURGERY \* DIALYSIS \* PHARMACY





**LAB REPORT**

Reg. Date 19/03/2024  
 Name MRS. AMBIKA SINGH  
 Age 35 Yrs, 7 Mn. 29 Day  
 Ref. By MEDIWHEEL

Patient Id 2403190004  
 Gender F  
 Panel MEDIWHEEL

DOB: 21/07/1988  
 Perm. ID  
 Reported 19/03/2024 16:44:01

Test Name	Result	Units	Ref. Range
MEDIWHEEL AHC STARTER FEMALE			

**HAEMATOLOGY**

**COMPLETE HAEMOGRAM**

HAEMOGLOBIN (HB%)	11.7	gm/dl	12 - 15
TOTAL LEUCOCYTE COUNT (TLC)	5,000	/cumm	4000 - 11000

**DIFFERENTIAL LEUCOCYTE COUNT (DLC)**

NEUTROPHIL	57	%	40 - 80
LYMPHOCYTE	36	%	28 - 55
MONOCYTE	06	%	02 - 10
EOSINOPHIL	01	%	01 - 06
BASOPHIL	00	%	0 - 0

ESR (WESTEGREN'S METHOD)

ESR (WESTEGREN'S METHOD)	20	mm/1st hr.	0 - 15
--------------------------	----	------------	--------

R B C COUNT

R B C COUNT	3.94	Millions/cmm	4.247 - 5.4
-------------	------	--------------	-------------

P.C.V / HAEMATOCRIT

P.C.V / HAEMATOCRIT	37.6	%	35 - 45
---------------------	------	---	---------

M C V

M C V	95.4	fl.	80 - 100
-------	------	-----	----------

M C H

M C H	29.7	Picogram	27.0 - 31.0
-------	------	----------	-------------

M C H C

M C H C	31.1	gm/dl	33 - 37
---------	------	-------	---------

PLATELET COUNT

PLATELET COUNT	2.30	Lakh/cu mm	1.50 - 4.50
----------------	------	------------	-------------

BLOOD GROUP ABO

BLOOD GROUP ABO	" A "		
-----------------	-------	--	--

RH TYPING

RH TYPING	Negative		
-----------	----------	--	--

BLOOD SUGAR FASTING

BLOOD SUGAR FASTING	82.42	mg/dl	70 - 100
---------------------	-------	-------	----------

**THYROID PROFILE**

Free T3	3.21	ng/ml	02 - 04
---------	------	-------	---------

ELFA

Free T4	1.14	ug/dl	0.8 - 2.7
---------	------	-------	-----------

ELFA

TSH	4.770	uIU/ml	
-----	-------	--------	--

Serum/ELFA

Checked by : \_\_\_\_\_  
 Page 1 Contd...2

If test results are alarming or unexpected, patient is advised to contact the laboratory immediately for possible remedial action.

**Facilities Available**

- Multispeciality Hospital - 24 Hours Emergency - X-Ray/ ECG/ Ultrasound/ CT Scan - Dental- Fully Equipped Operation Theatre
- Fully Functional Lab - 24/7 Casualty/ ICU-Nursery 24/7 Pharmacy - Labour Room - All Speciality OPD - Laproscopic Surgery - ECHO - Plastic Surgery



**LAB REPORT**

Reg. Date	19/03/2024	Patient Id	2403190004	DOB	21/07/1988
Name	MRS. AMBIKA SINGH	Gender	F	Perm. ID	
Age	35 Yrs. 7 Mn. 29 Day	Panel	MEDIWHEEL	Reported	19/03/2024 16:44:01
Ref. By	MEDIWHEEL				

Test Name	Result	Units	Ref. Range
			0.25 - 5.50 uIU/ml

**Interpretation**

**Clinical Use**

- Diagnose Hypothyroidism and Hyperthyroidism
- Monitor T4 replacement or T4 suppressive Therapy
- Quantify TSH levels in the subnormal range

Increased Levels : Primary Hypothyroidism Subclinical Hypothyroidism, TSH dependent, Thyroid Hormone Resistance.

Decreased Levels : Grave's Disease, Autonomous Thyroid Hormone Secretion, TSH Deficiency

**LIPID PROFILE**

TOTAL CHOLESTEROL	180.50	mg/dL	130.0 - 200.0 (<200)
TRIGLYCERIDES	89.40	mg/dL	80.5 - 150.0 (<150)
H D L CHOLESTEROL DIRECT	46.55	mg/dL	42.0 - 60.0 (<40->59)
V L D L	17.9	mg/dL	4.0 - 30. (23-45)
L D L CHOLESTEROL	116.0	mg/dL	50.0 - 150.0 (50-150)
TOTAL CHOLESTEROL / HDL RATIO	3.9		3.3 - 5.1
LDL / HDL CHOLESTEROL RATIO	2.5		1.5 - 3.5

**LIVER FUNCTION TEST (LFT)**

BILIRUBIN TOTAL	1.03	mg/dl	0.2 - 1.2
CONJUGATED (D. BILIRUBIN)	0.11	mg/dl	0.00 - 0.3
UNCONJUGATED (I.D. BILIRUBIN)	0.92	mg/dl	0.2 - 0.9

Checked by : \_\_\_\_\_  
Page 2 Contd...3

If test results are alarming or unexpected, patient is advised to contact the laboratory immediately for possible remedial action.

**Facilities Available**

- Multispeciality Hospital - 24 Hours Emergency - X-Ray/ ECG/ Ultrasound/ CT Scan - Dental- Fully Equipped Operation Theatre - Fully Functional Lab - 24/7 Casualty/ ICU-Nursery 24/7 Pharmacy - Labour Room - All Speciality OPD - Laproscopic Surgery - ECHO - Plastic Surgery





**LAB REPORT**

Reg. Date	19/03/2024	Patient Id	2403190004	DOB	21/07/1988
Name	MRS. AMBIKA SINGH	Gender	F	Perm. ID	
Age	35 Yrs. 7 Mn. 29 Day	Panel	MEDIWHEEL	Reported	19/03/2024 16:44:01
Ref. By	MEDIWHEEL				

Test Name	Result	Units	Ref. Range
SGOT / AST	30.50	IU/L	0 - 35
SGPT / ALT	26.8	IU/L	0 - 35
ALKALINE PHOSPHATASE	91.50	U/L	64 - 306
TOTAL PROTEIN	8.37	gm/dl	6.0 - 8.3
ALBUMIN	4.48	gm/dl	3.2 - 5.0
GLOBULIN	3.89	gm/dl	2.5 - 5.6
A/G RATIO	1.15		0.9 - 2.0
GAMMA GT	22.14	IU/L	0.0 - 35.0
SERUM CREATININE	0.70	mg/dl	0.6 - 1.2
SERUM URIC ACID	5.55	mg/dl	2.4 - 6.0
BLOOD UREA NITROGEN (BUN)	8.20	mg/dl	6.0 - 21.0
BUN/CREAT RATIO	11.7	mg/dl	

10 - 20

Urine Routine Examination

**PHYSICAL EXAMINATION**

QUANTITY	30	ml.	
COLOUR	Pale Yellow		Pale Yellow
TRANSPARENCY	Clear		
SPECIFIC GRAVITY	1.025		
PH	6.0		

**CHEMICAL EXAMINATION**

ALBUMIN	Nil
SUGAR	Nil

**MICROSCOPIC EXAMINATION**

PUS CELLS	2-3	/HPF
RBC'S	Nil	/HPF
CASTS	Nil	

Checked by : \_\_\_\_\_  
Page 3 Contd...4

If test results are alarming or unexpected, patient is advised to contact the laboratory immediately for possible remedial action.

**Facilities Available**

- Multispeciality Hospital - 24 Hours Emergency - X-Ray/ ECG/ Ultrasound/ CT Scan - Dental- Fully Equipped Operation Theatre
- Fully Functional Lab - 24/7 Casualty/ ICU-Nursery 24/7 Pharmacy - Labour Room - All Speciality OPD - Laproscopic Surgery - ECHO - Plastic Surgery



## LAB REPORT

Reg. Date	19/03/2024	Patient Id	2403190004	DOB	21/07/1988
Name	MRS. AMBIKA SINGH	Gender	F	Perm. ID	
Age	35 Yrs. 7 Mn. 29 Day	Panel	MEDIWHEEL	Reported	19/03/2024 16:44:01
Ref. By	MEDIWHEEL				

Test Name	Result	Units	Ref. Range
CRYSTALS	NIL		
EPITHELIAL CELLS	1-2	/HPF	
BACTERIA	Nil		
OTHERS	Nil		

  
**DR. REENA DAHIYA**  
 M.B.B.S, MD (Path)  
 Checked by: Radix Healthcare Pvt. Ltd.  
 C-217, C-218, Vikas Marg, Nirman Vihar,  
 Delhi-92

**DR. MEENU AGGARWAL**  
 M.B.B.S, MD (Path.)

If test results are alarming or unexpected, patient is advised to contact the laboratory immediately for possible remedial action.

## Facilities Available

- Multispeciality Hospital - 24 Hours Emergency - X-Ray/ ECG/ Ultrasound/ CT Scan - Dental- Fully Equipped Operation Theatre  
 - Fully Functional Lab - 24/7 Casualty/ ICU-Nursery 24/7 Pharmacy - Labour Room - All Speciality OPD - Laproscopic Surgery -  
 ECHO - Plastic Surgery

R

AIRMAN YEAR





UHID	PT209114	LAB No.	XRY2310984
Name	Mrs. AMBIKA SINGH	Regn. No.	GEN2343231
Age / Sex	35 Yrs / F	Receiving Dt/Time	19-Mar-2024 10:00
		Reporting Dt/Time	19-Mar-2024 09:38 AM



**XRAY**

CHEST (PA)

Both lung fields are normal.

Cp angles are clear.

Hila are normal...

Heart size appears within normal limits.

Soft tissue shadows and bony thorax are normal.

**IMP- NORMAL CHEST X-RAY**

Advised....please correlate clinically.

\*\*\*\*\* END OF REPORT \*\*\*\*\*

DR. K.K. SINHA  
M.B.B.S. D.F.R.C.  
SENIOR CONSULTANT  
Reg. No. 25437 (DMC)

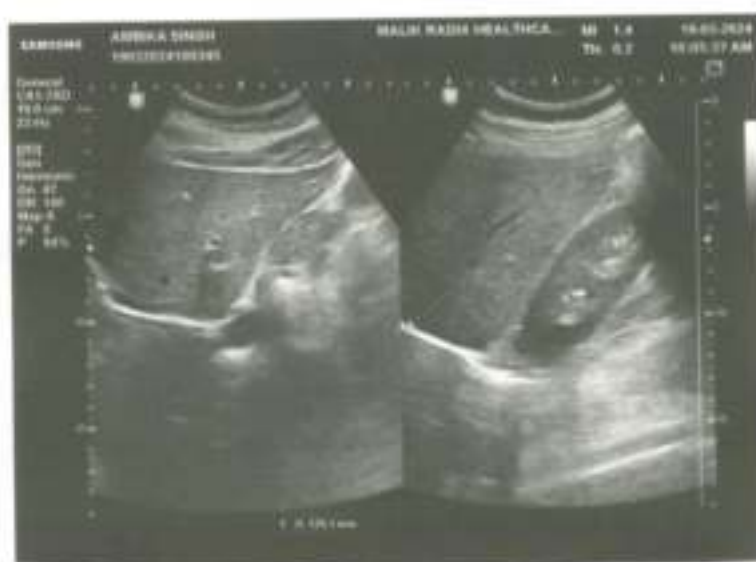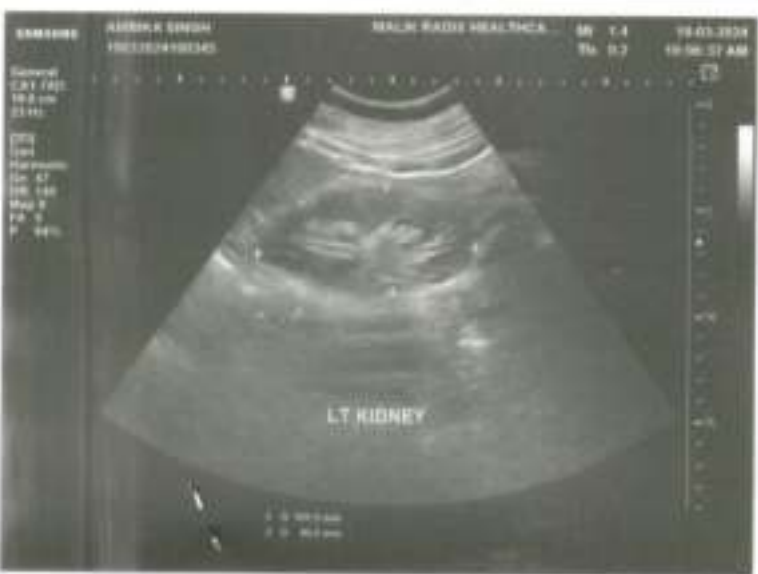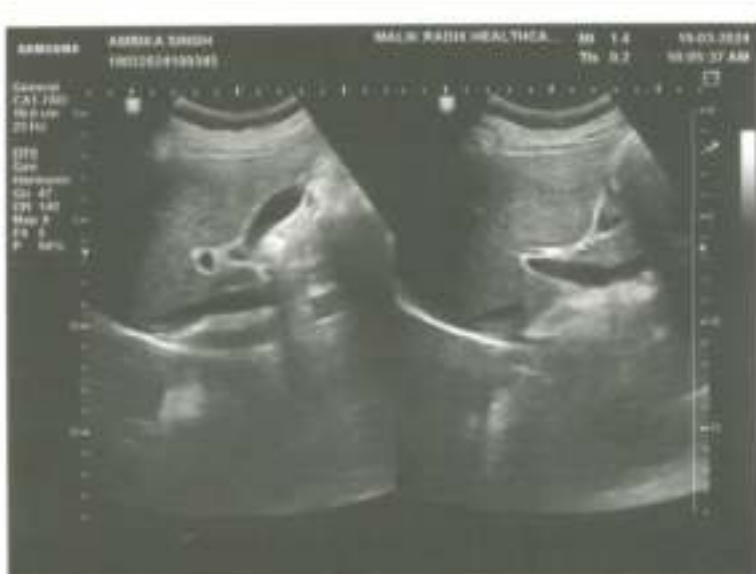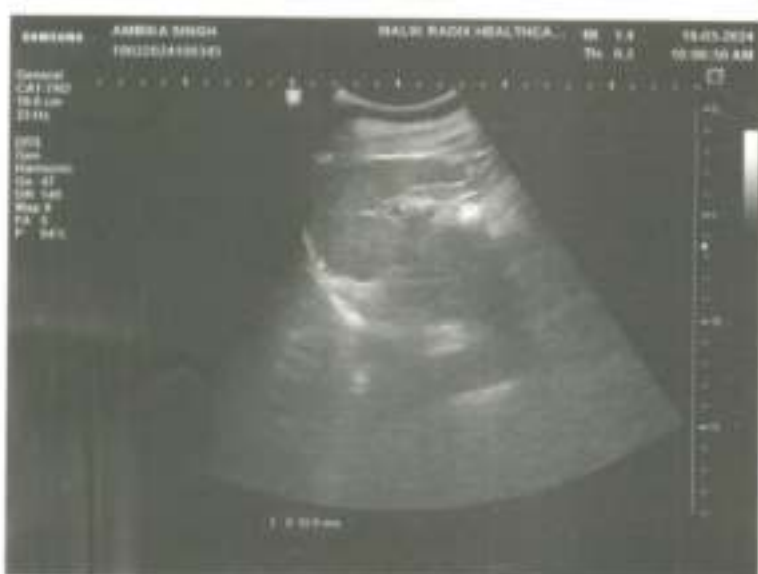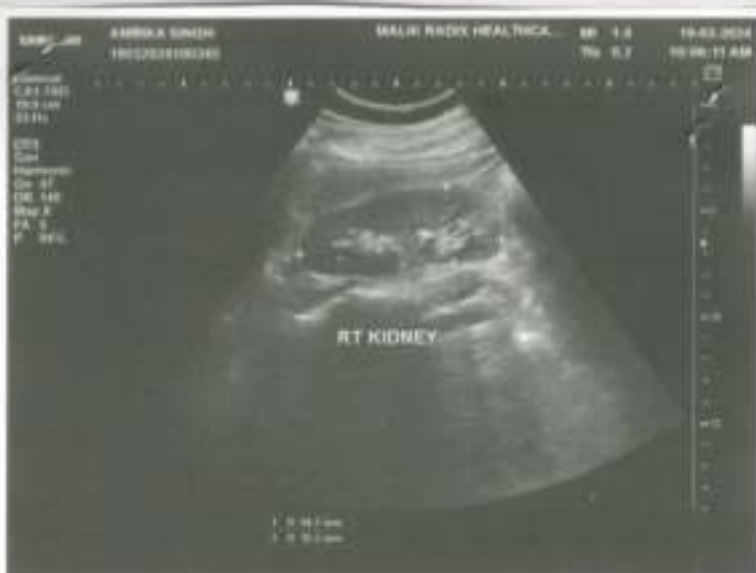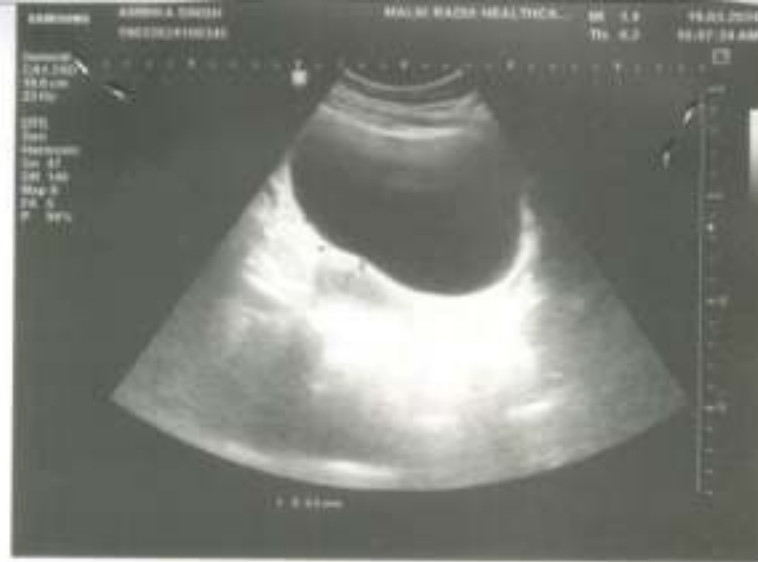DR. RAJESH MALHOTRA  
MBBS, MD (RADIOLOGY)  
CONSULTANT RADIOLOGY  
Reg.No.DMC9299

DR. T. K VOHRA  
MD (RADIODIAGNOSIS)  
SENIOR CONSULTANT  
Reg. No. 3272 (DMC)

DR. MUKESH KOSHAL  
MBBS, MD (RADIOLOGY)  
CONSULTANT RADIOLOGY  
Reg.No.DMC10407

DR. SHREYASH TIWARY  
MBBS, MD (RADIOLOGY)  
CONSULTANT RADIOLOGY  
Reg.No.DMC85802

**Facilities Available**





NAME	MRS AMBIKA SINGH	AGE	35 Y/F
REFD. BY.	HEALTH CHECK UP	DATE	19.03.24

### Ultrasound Examination of Whole Abdomen & Pelvis:

**Liver:** Liver is normal in size (12.9 cm) with normal outlines and shows normal parenchymal echotexture. No focal lesion is seen. IHBR & portal radicles are normal.

**Gallbladder:** Gallbladder is well distended. No evidence of cholecystitis or cholelithiasis seen. Common bile duct is normal in course & caliber.

**Pancreas:** Pancreas shows normal size, outlines & echotexture. No focal lesion is seen. MPD is not dilated.

**Spleen:** Spleen shows normal size (8.2 cm), outline & echotexture.

**Kidneys:** Kidneys show normal size, shape, position & echotexture. No calculus/ hydronephrosis or SOL is seen in kidneys. Cortico- medullary differentiation and cortical thickness is normal on both sides.

Right kidney measures -9.4 x 3.6 cm

Left kidney measures -10.1 x 4.9 cm

Great abdominal vessels are normal.

No ascites seen.

No para-aortic lymph nodes seen.

**Urinary bladder:** Urinary bladder is well distended. Walls and lumen appear normal.

**Uterus** is normal in size outline and echotexture. No focal lesion is seen. Endometrium is central and measures 6.6 mm. Cervix appears normal.

Both adnexa appear unremarkable.

**IMPRESSION:** Normal study

Dr Shreyash Tiwary MD ( Rad- diag)

Regn. No. DMC 85802

RADIOLOGIST :

Facilities Available