

R

NARAYANI A. KSHIRSAGAR Female / 38 YRS

Chest PA

23/05/2024 09:45:43 AM

SHRI DASHABHUJA X-RAY CLINIC. PUNE. 020-25468187.



**SHRI DASHABHUJA**  
**X-RAY CLINIC**

Digital X-Ray (CR System) Available  
OPG Facility Available

GANGAVATARANA, Ground Floor, Plot  
No. 7, S. No. 42 A/1A/2F, Dashbhujja  
Ganesh Colony, Near Dashbhujja  
Ganesh Temple, Karve Rode,  
Pune. 411038.  
Clinic : 2546 8187, 8308839383  
Res : 2422 1359, 9822041859

**Dr. LALIT P. PATHAK**

M. D. Radiologist  
Reg. No. 52382

Timing : 9.00 a.m. To 1.30 p.m.  
4.30 p.m. To 8.30 p.m.

**SUNDAY CLOSED**

Patient's Name : Ms.Narayan Kshirsagar  
Date : 23<sup>rd</sup> May 2024  
Referred By : Dr.V.Nadkarni  
Investigation : **Xray Chest PA View.**

Xray chest shows that the lung parenchyma and pleural sinuses are clear on both sides.

Both the diaphragms are in normal position.

The heart, the aorta, the mediastinum and the pulmonary vasculature appear normal.

There is no hilar or mediastinal lymphadenopathy.

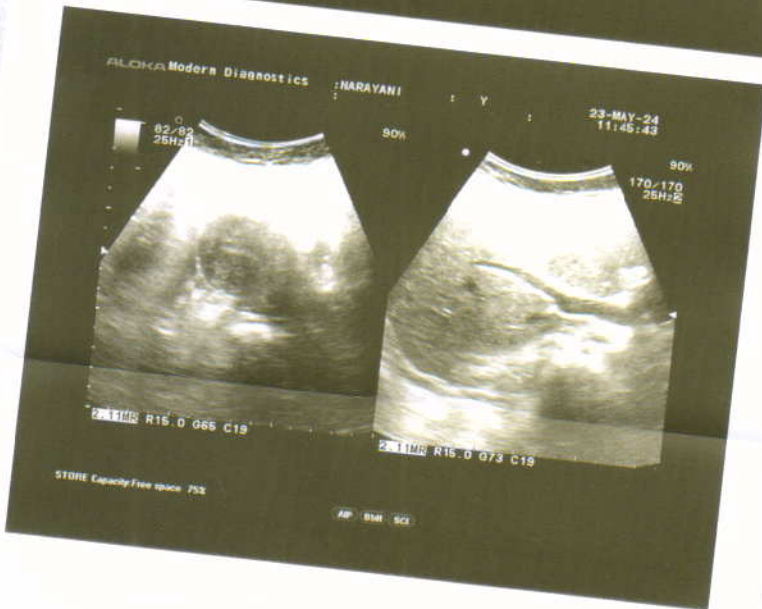
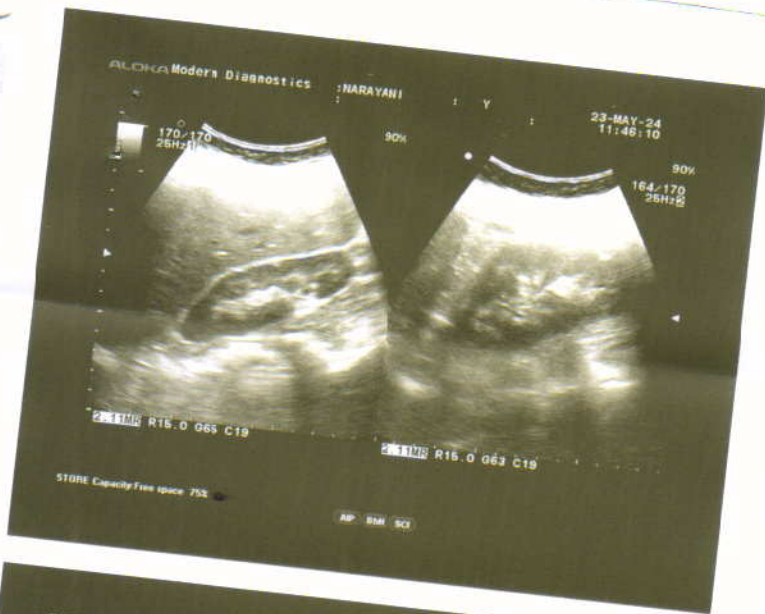
The bony thorax and soft tissues reveal no abnormality.

Conclusion : Normal xray chest.

Dr. Pradeep Naik  
MD ( Radiodiagnosis )  
MMC Reg No 47989

**CBCT, OPG & PORTABLE X-RAY FACILITY AVAILABLE**

(P.T.O)







# MODERN diagnostics

• DIGITAL X-RAY • SONOGRAPHY • COLOUR DOPPLER

## Dr. Prashant Naik

M.D. (Radiology)

Reg. No. 58314

Time : 5.00 pm to 7.00 pm By Appointment

## Dr. Kedar Athawale

DMRD DNB (Radiology)

Reg. No. 84908

Time : 11.00 am to 1.00 pm By Appointment

Patient's Name Mrs Narayani Kshirsagar  
Ref By Dr Dr V.M.Nadkarni  
Date May 23, 2024

### USG ABDOMEN & PELVIS

Liver normal in size, shape & outline & reveals normal echo-texture.  
No focal lesion seen. Intra hepatic biliary and portal vein radicles normal.  
Cholecystectomy.  
Portal vein & CBD normal. No calculus in CBD.  
Spleen & visualized pancreas show normal size & echoanatomy. Tail of pancreas not visualized due to unavoidable bowel gas.  
Both kidneys normal in size, shape, outline & position.  
Right kidney :- 92mm x 30mm.  
Left kidney :- 94mm x 51mm  
No calculus, hydronephrosis or hydroureter on either side.  
Cortico-medullary differentiation normal.  
Urinary bladder is well filled. No mural or luminal pathology seen.  
Uterus is normal in size, shape and echopattern. It measures 66x40x45 mm. The endometrial is central and measures 5 mm. A 13 mm posterior wall fibroid is seen.  
Both the ovaries are normal in size, shape and echopattern,  
RO - 29x22 mm. LO - 28x22 mm.  
No adnexal lesion is seen. No free fluid is seen in pouch of Douglas.  
Aorta & IVC normal. No lymphadenopathy. No loculated or free fluid collection seen in abdomen or pelvis. No abnormally dilated bowel loops seen.

### IMPRESSION

Uterine fibroid.

Dr. Kedar Athawale  
DMRD, DNB  
Thanks for referral

**DR. KEDAR ATHAWALE**  
DMRD DNB (Radiology)  
Reg. No. 84908