

Name : Mrs. Sankar Deep Kumar	Age: 54 Y	UHID: SCHI.0000025322
	Sex: F	*SCHI.0000025322*
Address : 161, ASIAD VILLAGE COMPLEX MADAN LAL BLOCK		OP Number: SCHIOPV39125
Plan : ARCOFEMI MED/WHEEL FEMALE AHC CREDIT PAN		BH No : SCHI-OCR-12935
INDIA OP AGREEMENT		Date : 13.11.2024 09:36

Sno	Service Type/ServiceName	Department
1	ARCOFEMI - MED/WHEEL - FULL BODY ANNUAL PLUS CHECK ADVANCED - FEMALE - 2D ECHO - PAN INDIA - FY2324	
1	GAMMA GLUTAMYL TRANSFERASE (GGT)	
2	D ECHO ✓	
3	LIVER FUNCTION TEST (LFT) ✓	
4	GLUCOSE, FASTING ✓	
5	HEMOCURAM + PERIPHERAL SMEAR ✓	
6	GYNAGCOLOGY CONSULTATION ✓	
7	DIET CONSULTATION ✓	
8	COMPLETE URINE EXAMINATION ✓	
9	URINE GLUCOSE (POST PRANDIAL) ✓	
10	PERIPHERAL SMEAR ✓	
11	ECG ✓	
12	LEOPAP TEST - PAP SMEAR ✓	
13	RENAL PROFILE (RENAL FUNCTION TEST) (RFL/KFT) ✓	
14	DENTAL CONSULTATION ✓	
15	GLUCOSE, POST PRANDIAL (1P), 2 HOURS (POST MEAL) ✓ 1.56 PM	
16	URINE GLUCOSE (FASTING) ✓	
17	SONO MAMMOGRAPHY - SCREENING ✓	
18	HEALTHY GLYCATED HEMOGLOBIN ✓	
19	X-RAY CHEST PA ✓	
20	DENT CONSULTATION ✓	
21	FITNESS BY GENERAL PHYSICIAN ✓	
22	BLOOD GROUP ABO AND RH FACTOR ✓	
23	LIPID PROFILE ✓	
24	BODY MASS INDEX (BMI) ✓	
25	OPHTHAL BY GENERAL PHYSICIAN ✓	
26	ULTRASOUND - WHOLE ABDOMEN ✓	
27	THYROID PROFILE (TOTAL T3, TOTAL T4, TSH) ✓	

am
cxb

Height: 155cm
Weight: 74.3 kg
B.P.: 130/90 mmHg
Pulse: 78/mtd
SpO2: 98%
10

ਸਾਹਿਬ ਸਰਕਾਰ
GOVERNMENT OF INDIA



ਸਰਕਾਰਦੀਪ ਕੌਰ
Salkardeep Kaur
ਜਨਮ ਮਿਤੀ/DOB: 05/05/1970
ਲਿੰਗ/FEMALE
Mobile No: 9815634177
9684 6588 6367
Vid: 9165 9143 0304 6500

ਮੇਰਾ ਆਸ਼ਾਚ, ਮੇਰੀ ਪਛਾਣ

PHC_Desk

From: noreply@apolloclinics.info
Sent: 11 November 2024 11:43
To: sabheaksingh@gmail.com
Cc: phc.klc@apollospectra.com; syamsunder.m@apollohl.com; cc.klc@apollospectra.com
Subject: Your appointment is confirmed



Doar Satkar Deep Kaur,

Greetings from Apollo Clinics,

Your corporate health check appointment is confirmed at **SPECTRA NEHRU ENCLAVE** clinic on **2024-11-13** at **09:00-09:15**.

Payment Mode	
Corporate Name	ARCOFEMI HEALTHCARE LIMITED
Agreement Name	[ARCOFEMI MEDIWHEEL FEMALE AHC CREDIT PAN INDIA OP AGREEMENT]
Package Name	[ARCOFEMI - MEDIWHEEL - FULL BODY ANNUAL PLUS CHECK ADVANCED - FEMALE - 2D ECHO - PAN INDIA - FY2324]

"Kindly carry with you relevant documents such as HR issued authorization letter and or appointment confirmation mail and or valid government ID proof and or company ID card and or voucher as per our agreement with your company or sponsor."

Note: Video recording or taking photos inside the clinic premises or during camps is not allowed and would attract legal consequences.

Note: Also once appointment is booked, based on availability of doctors at clinics tests will happen, any pending test will happen based on doctor availability and clinics will be updating the same to customers.

Instructions to be followed for a health check:

DIGITAL X-RAY REPORT

NAME: SATKAR KAUR	DATE: 13.11.2024
UHID NO : 25322	AGE: 54YRS/ SEX: F

X-RAY CHEST PA VIEW

Both the lung fields shows prominent bronchovascular markings.

Fibrotic band is seen in right mid zone.

Both the costophrenic angles are clear.

Heart size is normal.

Both the domes of diaphragm are normal.

Bony thorax appears normal.

Please correlate clinically and with lab investigations


DR. DEEPIKA AGARWAL
Consultant Radiologist

Dr. DEEPIKA AGARWAL
Consultant Radiologist
DMC No. 58777
Apollo Speciality Hospitals (P) Ltd.
A-2, Chirag Enclave, Greater Kailash-1
New Delhi-110048

RV

Normal/Enlarged/Clear/Thrombotic

PERICARDIUM

COMMENTS & SUMMARY

- ✓ Normal LV systolic function
- ✓ No RWMA, LVEF=61%
- ✓ Grade I LVDD
- ✓ No AR, PR, MR & TR
- ✓ No IC clot or mass
- ✓ Good RV function
- ✓ Normal pericardium
- ✓ No pericardial effusion

Dr. M K Gupta
M.B.B.S, MD, F1ACM
Senior Consultant Cardiologist



NAME :	SATKAR DEEP KAUR	AGE/SEX	54	YRS/ F
UHID :	25322			
REF BY :	APOLLO SPECTRA	DATE:-	13.11.2024	

ULTRASOUND WHOLE ABDOMEN

Liver: Appears normal in size and shows increased parenchymal echogenicity which is most likely due to fatty changes. Intrahepatic biliary radicles are not dilated. CBD and portal vein are normal in calibre.

Gall Bladder: normally distended with clear lumen and normal wall thickness. No calculus or sludge is seen.

Pancreas and Spleen: Appears normal in size and echotexture.

Both Kidneys: are normal in size, shape, and echopattern. The parenchymal thickness is normal and cortico-medullary differentiation is well maintained. Pelvicalyceal systems are not dilated. No calculus or mass lesion is seen. Ureter is not dilated.

Urinary Bladder: is minimally distended. No obvious focal lesion is seen.


Uterus is atrophic. Endometrium is thin.

No obvious adnexal mass is seen. No free fluid seen.

IMPRESSION:

- **FATTY CHANGES IN LIVER GRADE 1-2.**

Please correlate clinically and with lab. Investigations.


DR. DEEPIKA AGARWAL
CONSULTANT RADIOLOGIST

Dr
Dr. DEEPIKA AGARWAL
Consultant Radiologist
DMC No. 58777
Apollo
A-2, C
Apollo Speciality Hospitals (P) Ltd.
A-2, Chirag Enclave, Greater Kailash-1
New Delhi-110048

Apollo Spectra Hospitals: Plot No. A-2, Chirag Enclave, Greater Kailash -1, New Delhi -110048

Ph:011-40465555, 9910995018 | www.apollospectra.com

Apollo Specialty Hospital Pvt. Ltd.

CIN - U85100TG2009PTC099414

Regd. Office: 7-1-617/A, 615 & 616, Imperial Towers, 7th Floor, Ameerpet, Hyderabad, Telangana - 500038

Ph No:040-4904 7777 | www.apollohl.com

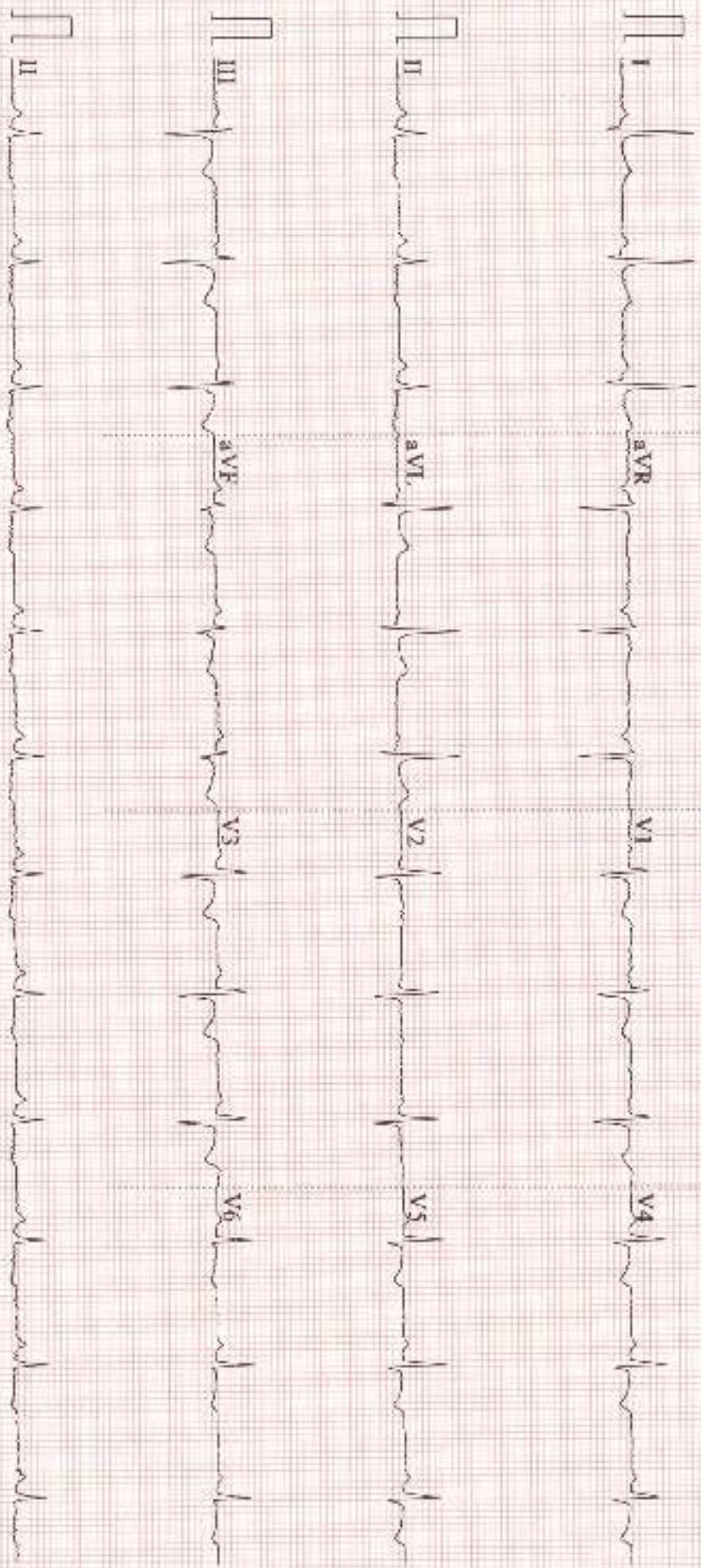
ID: 25322
Sathar deep kaur
Female 54Years
Req. No. :

13-11-2024 12:43:04
HR : 72 bpm
P : 103 ms
PR : 153 ms
QRS : 93 ms
QT/QTcBz : 373/411 ms
PQRST : 49/2/43
RV5/SV1 : 0.664/0.543 mV

Diagnosis Information:
Sinus Rhythm
T Wave Abnormality(III,III,aVF,V1,V2,V3,V4,V5,V6)

Report Confirmed by:

Ansul Singh
MD
Resident - Cardiology



NAME :	SATKAR DEEP KAUR	AGE/SEX	54 YRS/ F
UHID :	25322		
REF BY :	APOLLO SPECTRA	DATE:-	13.11.2024

USG BOTH BREAST

Both breast shows normal parenchymal pattern.

Few tiny simple cysts are seen in bilateral subareolar regions measuring 2-2.5 mm in size.

No obvious architectural distortion seen.

No abnormal ductal dilatation seen.

Skin and subcutaneous tissues are normal.


No evidence of intramammary / axillary lymphadenopathy seen on both sides.

No abnormal vascularity seen on both sides.

Bilateral subareolar regions are otherwise unremarkable.

IMPRESSION: USG breast reveals benign findings (BIRADS - 2).

Advise: Clinical Correlation.



DR. DEEPIKA AGARWAL
CONSULTANT RADIOLOGIST

Dr. DEEPIKA AGARWAL
Consultant Radiologist
DMC No: 58777
Apollo Speciality Hospitals (P) Ltd.
A-2, Chirag Enclave, Greater Kailash-1
New Delhi-110048

13/11/2024

Mrs. Sotkar Deep Kaur

544/F

C/O - Regular Check UP

D/H - Pt. gives +10 prothesis in lower left side back teeth region since 7 yrs back.

M/H - Pt. is on medication for Hypertension

O/E - Gravelly decayed dentures

Root Stumps int. $\frac{26}{5} \mid 6$

Advised .. OPG X-ray

• Extraction int. $\frac{26}{5} \mid 6$

• Scaling int. Max. + Mand. Arch.

Dr. Anamika

LMP - post
menopausal

P₂L₂ NVD

LCB - 22yr.

PH - hypomyoid 75yr

FM - nil

vitals stable

breast +

PA P/S P/V - (N)

Done

Sankar Deep Kumar

544/E

13/11/24

Adv

supraclav x +

on + off

x / mth

Patient Name : Mrs.SATKAR DEEP KAUR
Age/Gender : 54 Y 6 M 8 D/F
UHID/MR No : SCHI.0000025322
Visit ID : SCHIOPV39123
Ref Doctor : Dr.SELF
Emp/Auth/TPA ID : 81027

Collected : 13/Nov/2024 09:58AM
Received : 13/Nov/2024 10:48AM
Reported : 13/Nov/2024 03:09PM
Status : Final Report
Sponsor Name : ARCOFEMI HEALTHCARE LIMITED

DEPARTMENT OF HAEMATOLOGY

PERIPHERAL SMEAR , WHOLE BLOOD EDTA

....



Dr. SHWETA GUPTA
MBBS,MD (Pathology)
Consultant Pathology
SIN No:BED240246870



Patient Name : Mrs.SATKAR DEEP KAUR	Collected : 13/Nov/2024 09:58AM
Age/Gender : 54 Y 6 M 8 D/F	Received : 13/Nov/2024 10:48AM
UHID/MR No : SCHI.0000025322	Reported : 13/Nov/2024 03:09PM
Visit ID : SCHIOPV39123	Status : Final Report
Ref Doctor : Dr.SELF	Sponsor Name : ARCOFEMI HEALTHCARE LIMITED
Emp/Auth/TPA ID : 81027	

DEPARTMENT OF HAEMATOLOGY

ARCOFEMI - MEDIWHEEL - FULL BODY ANNUAL PLUS CHECK ADVANCED - FEMALE - 2D ECHO - PAN INDIA - FY2324

Test Name	Result	Unit	Bio. Ref. Interval	Method
HEMOGRAM , WHOLE BLOOD EDTA				
HAEMOGLOBIN	11.6	g/dL	12-15	CYANIDE FREE COLOUROMETER
PCV	35.90	%	40-50	PULSE HEIGHT AVERAGE
RBC COUNT	4.03	Million/cu.mm	3.8-4.8	Electrical Impedance
MCV	89	fL	83-101	Calculated
MCH	28.9	pg	27-32	Calculated
MCHC	32.5	g/dL	31.5-34.5	Calculated
R.D.W	16.2	%	11.6-14	Calculated
TOTAL LEUCOCYTE COUNT (TLC)	6,160	cells/cu.mm	4000-10000	Electrical Impedance
DIFFERENTIAL LEUCOCYTIC COUNT (DLC)				
NEUTROPHILS	59.9	%	40-80	Electrical Impedance
LYMPHOCYTES	30.9	%	20-40	Electrical Impedance
EOSINOPHILS	3.1	%	1-6	Electrical Impedance
MONOCYTES	5.3	%	2-10	Electrical Impedance
BASOPHILS	0.8	%	<1-2	Electrical Impedance
ABSOLUTE LEUCOCYTE COUNT				
NEUTROPHILS	3689.84	Cells/cu.mm	2000-7000	Calculated
LYMPHOCYTES	1903.44	Cells/cu.mm	1000-3000	Calculated
EOSINOPHILS	190.96	Cells/cu.mm	20-500	Calculated
MONOCYTES	326.48	Cells/cu.mm	200-1000	Calculated
BASOPHILS	49.28	Cells/cu.mm	0-100	Calculated
Neutrophil lymphocyte ratio (NLR)	1.94		0.78- 3.53	Calculated
PLATELET COUNT	205000	cells/cu.mm	150000-410000	IMPEDENCE/MICROSCOPY
ERYTHROCYTE SEDIMENTATION RATE (ESR)	14	mm at the end of 1 hour	0-20	Modified Westergren
PERIPHERAL SMEAR				

RBCs ARE NORMOCYTIC NORMOCHROMIC WITH OCCASIONAL MICROCYTIC HYPOCHROMIC CELLS.

TLC , DLC WITHIN NORMAL LIMIT. NO IMMATURE CELLS ARE SEEN.
PLATELETS ARE ADEQUATE.

Page 2 of 14



Dr. SHWETA GUPTA
MBBS,MD (Pathology)
Consultant Pathology
SIN No:BED240246870



Patient Name : Mrs.SATKAR DEEP KAUR
Age/Gender : 54 Y 6 M 8 D/F
UHID/MR No : SCHI.0000025322
Visit ID : SCHIOPV39123
Ref Doctor : Dr.SELF
Emp/Auth/TPA ID : 81027

Collected : 13/Nov/2024 09:58AM
Received : 13/Nov/2024 10:48AM
Reported : 13/Nov/2024 03:09PM
Status : Final Report
Sponsor Name : ARCOFEMI HEALTHCARE LIMITED

DEPARTMENT OF HAEMATOLOGY

ARCOFEMI - MEDIWHEEL - FULL BODY ANNUAL PLUS CHECK ADVANCED - FEMALE - 2D ECHO - PAN INDIA - FY2324



Dr. SHWETA GUPTA
MBBS,MD (Pathology)
Consultant Pathology
SIN No:BED240246870



Patient Name : Mrs.SATKAR DEEP KAUR	Collected : 13/Nov/2024 09:58AM
Age/Gender : 54 Y 6 M 8 D/F	Received : 13/Nov/2024 10:48AM
UHID/MR No : SCHI.0000025322	Reported : 13/Nov/2024 07:47PM
Visit ID : SCHIOPV39123	Status : Final Report
Ref Doctor : Dr.SELF	Sponsor Name : ARCOFEMI HEALTHCARE LIMITED
Emp/Auth/TPA ID : 81027	

DEPARTMENT OF HAEMATOLOGY

ARCOFEMI - MEDIWHEEL - FULL BODY ANNUAL PLUS CHECK ADVANCED - FEMALE - 2D ECHO - PAN INDIA - FY2324

Test Name	Result	Unit	Bio. Ref. Interval	Method
BLOOD GROUP ABO AND RH FACTOR , WHOLE BLOOD EDTA				
BLOOD GROUP TYPE	O			Forward & Reverse Grouping with Slide/Tube Aggluti
Rh TYPE	POSITIVE			Forward & Reverse Grouping with Slide/Tube Agglutination



Dr. SHWETA GUPTA
MBBS,MD (Pathology)
Consultant Pathology
SIN No:BED240246870



Patient Name : Mrs.SATKAR DEEP KAUR	Collected : 13/Nov/2024 01:51PM
Age/Gender : 54 Y 6 M 8 D/F	Received : 13/Nov/2024 02:09PM
UHID/MR No : SCHI.0000025322	Reported : 13/Nov/2024 06:07PM
Visit ID : SCHIOPV39123	Status : Final Report
Ref Doctor : Dr.SELF	Sponsor Name : ARCOFEMI HEALTHCARE LIMITED
Emp/Auth/TPA ID : 81027	

DEPARTMENT OF BIOCHEMISTRY

ARCOFEMI - MEDIWHEEL - FULL BODY ANNUAL PLUS CHECK ADVANCED - FEMALE - 2D ECHO - PAN INDIA - FY2324

Test Name	Result	Unit	Bio. Ref. Interval	Method
GLUCOSE, FASTING , NAF PLASMA	91	mg/dL	70-100	GOD - POD

Comment:

As per American Diabetes Guidelines, 2023

Fasting Glucose Values in mg/dL	Interpretation
70-100 mg/dL	Normal
100-125 mg/dL	Prediabetes
≥126 mg/dL	Diabetes
<70 mg/dL	Hypoglycemia

Note:

- 1.The diagnosis of Diabetes requires a fasting plasma glucose of > or = 126 mg/dL and/or a random / 2 hr post glucose value of > or = 200 mg/dL on at least 2 occasions.
2. Very high glucose levels (>450 mg/dL in adults) may result in Diabetic Ketoacidosis & is considered critical.

Test Name	Result	Unit	Bio. Ref. Interval	Method
GLUCOSE, POST PRANDIAL (PP), 2 HOURS , SODIUM FLUORIDE PLASMA (2 HR)	108	mg/dL	70-140	GOD - POD

Comment:

It is recommended that FBS and PPBS should be interpreted with respect to their Biological reference ranges and not with each other.
Conditions which may lead to lower postprandial glucose levels as compared to fasting glucose levels may be due to reactive hypoglycemia, dietary meal content, duration or timing of sampling after food digestion and absorption, medications such as insulin preparations, sulfonylureas, amylin analogues, or conditions such as overproduction of insulin.



Dr. SHWETA GUPTA
MBBS,MD (Pathology)
Consultant Pathology
SIN No:PLP1488146



Patient Name : Mrs.SATKAR DEEP KAUR	Collected : 13/Nov/2024 10:00AM
Age/Gender : 54 Y 6 M 8 D/F	Received : 13/Nov/2024 01:17PM
UHID/MR No : SCHI.0000025322	Reported : 13/Nov/2024 02:05PM
Visit ID : SCHIOPV39123	Status : Final Report
Ref Doctor : Dr.SELF	Sponsor Name : ARCOFEMI HEALTHCARE LIMITED
Emp/Auth/TPA ID : 81027	

DEPARTMENT OF BIOCHEMISTRY

ARCOFEMI - MEDIWHEEL - FULL BODY ANNUAL PLUS CHECK ADVANCED - FEMALE - 2D ECHO - PAN INDIA - FY2324

Test Name	Result	Unit	Bio. Ref. Interval	Method
HBA1C (GLYCATED HEMOGLOBIN) , WHOLE BLOOD EDTA				
HBA1C, GLYCATED HEMOGLOBIN	5.7	%		HPLC
ESTIMATED AVERAGE GLUCOSE (eAG)	117	mg/dL		Calculated

Comment:

Reference Range as per American Diabetes Association (ADA) 2023 Guidelines:

REFERENCE GROUP	HBA1C %
NON DIABETIC	<5.7
PREDIABETES	5.7 – 6.4
DIABETES	≥ 6.5
DIABETICS	
EXCELLENT CONTROL	6 – 7
FAIR TO GOOD CONTROL	7 – 8
UNSATISFACTORY CONTROL	8 – 10
POOR CONTROL	>10

Note: Dietary preparation or fasting is not required.

1. HbA1C is recommended by American Diabetes Association for Diagnosing Diabetes and monitoring Glycemic Control by American Diabetes Association guidelines 2023.

2. Trends in HbA1C values is a better indicator of Glycemic control than a single test.

3. Low HbA1C in Non-Diabetic patients are associated with Anemia (Iron Deficiency/Hemolytic), Liver Disorders, Chronic Kidney Disease. Clinical Correlation is advised in interpretation of low Values.

4. Falsely low HbA1c (below 4%) may be observed in patients with clinical conditions that shorten erythrocyte life span or decrease mean erythrocyte age. HbA1c may not accurately reflect glycemic control when clinical conditions that affect erythrocyte survival are present.

5. In cases of Interference of Hemoglobin variants in HbA1C, alternative methods (Fructosamine) estimation is recommended for Glycemic Control

A: HbF >25%

B: Homozygous Hemoglobinopathy.

(Hb Electrophoresis is recommended method for detection of Hemoglobinopathy)



Dr Nidhi Sachdev
M.B.B.S,MD(Pathology)
Consultant Pathologist

SIN No:EDT240094280



Patient Name : Mrs.SATKAR DEEP KAUR	Collected : 13/Nov/2024 10:00AM
Age/Gender : 54 Y 6 M 8 D/F	Received : 13/Nov/2024 11:06AM
UHID/MR No : SCHI.0000025322	Reported : 13/Nov/2024 01:39PM
Visit ID : SCHIOPV39123	Status : Final Report
Ref Doctor : Dr.SELF	Sponsor Name : ARCOFEMI HEALTHCARE LIMITED
Emp/Auth/TPA ID : 81027	

DEPARTMENT OF BIOCHEMISTRY

ARCOFEMI - MEDIWHEEL - FULL BODY ANNUAL PLUS CHECK ADVANCED - FEMALE - 2D ECHO - PAN INDIA - FY2324

Test Name	Result	Unit	Bio. Ref. Interval	Method
LIPID PROFILE , SERUM				
TOTAL CHOLESTEROL	182	mg/dL	<200	CHE/CHO/POD
TRIGLYCERIDES	94	mg/dL	<150	Enzymatic
HDL CHOLESTEROL	46	mg/dL	>40	CHE/CHO/POD
NON-HDL CHOLESTEROL	136	mg/dL	<130	Calculated
LDL CHOLESTEROL	117.2	mg/dL	<100	Calculated
VLDL CHOLESTEROL	18.8	mg/dL	<30	Calculated
CHOL / HDL RATIO	3.96		0-4.97	Calculated
ATHEROGENIC INDEX (AIP)	0.01		<0.11	Calculated

Comment:

Reference Interval as per National Cholesterol Education Program (NCEP) Adult Treatment Panel III Report.

	Desirable	Borderline High	High	Very High
TOTAL CHOLESTEROL	< 200	200 - 239	≥ 240	
TRIGLYCERIDES	<150	150 - 199	200 - 499	≥ 500
LDL	Optimal < 100 Near Optimal 100-129	130 - 159	160 - 189	≥ 190
HDL	≥ 60			
NON-HDL CHOLESTEROL	Optimal <130; Above Optimal 130-159	160-189	190-219	>220



Dr. SHWETA GUPTA
MBBS,MD (Pathology)
Consultant Pathology
SIN No:SE04844530



Patient Name	: Mrs.SATKAR DEEP KAUR	Collected	: 13/Nov/2024 10:00AM
Age/Gender	: 54 Y 6 M 8 D/F	Received	: 13/Nov/2024 11:06AM
UHID/MR No	: SCHI.0000025322	Reported	: 13/Nov/2024 01:39PM
Visit ID	: SCHIOPV39123	Status	: Final Report
Ref Doctor	: Dr.SELF	Sponsor Name	: ARCOFEMI HEALTHCARE LIMITED
Emp/Auth/TPA ID	: 81027		

DEPARTMENT OF BIOCHEMISTRY

ARCOFEMI - MEDIWHEEL - FULL BODY ANNUAL PLUS CHECK ADVANCED - FEMALE - 2D ECHO - PAN INDIA - FY2324

Test Name	Result	Unit	Bio. Ref. Interval	Method
LIVER FUNCTION TEST (LFT) , SERUM				
BILIRUBIN, TOTAL	0.90	mg/dL	0.20-1.30	DIAZO METHOD
BILIRUBIN CONJUGATED (DIRECT)	0.30	mg/dL	0.0-0.3	Calculated
BILIRUBIN (INDIRECT)	0.60	mg/dL	0.0-1.1	Dual Wavelength
ALANINE AMINOTRANSFERASE (ALT/SGPT)	40	U/L	<35	Visible with P-5-P
ASPARTATE AMINOTRANSFERASE (AST/SGOT)	31.0	U/L	14-36	UV with P-5-P
AST (SGOT) / ALT (SGPT) RATIO (DE RITIS)	0.8		<1.15	Calculated
ALKALINE PHOSPHATASE	105.00	U/L	38-126	p-nitrophenyl phosphate
PROTEIN, TOTAL	7.80	g/dL	6.3-8.2	Biuret
ALBUMIN	4.10	g/dL	3.5 - 5	Bromocresol Green
GLOBULIN	3.70	g/dL	2.0-3.5	Calculated
A/G RATIO	1.11		0.9-2.0	Calculated

Comment:

LFT results reflect different aspects of the health of the liver, i.e., hepatocyte integrity (AST & ALT), synthesis and secretion of bile (Bilirubin, ALP), cholestasis (ALP, GGT), protein synthesis (Albumin) Common patterns seen:

1. Hepatocellular Injury:

*AST – Elevated levels can be seen. However, it is not specific to liver and can be raised in cardiac and skeletal injuries.*ALT – Elevated levels indicate hepatocellular damage. It is considered to be most specific lab test for hepatocellular injury. Values also correlate well with increasing BMI. Disproportionate increase in AST, ALT compared with ALP. AST: ALT (ratio) – In case of hepatocellular injury AST: ALT > 1 In Alcoholic Liver Disease AST: ALT usually >2. This ratio is also seen to be increased in NAFLD, Wilsons’s diseases, Cirrhosis, but the increase is usually not >2.

2. Cholestatic Patten:*ALP – Disproportionate increase in ALP compared with AST, ALT. ALP elevation also seen in pregnancy, impacted by age and sex.*Bilirubin elevated- predominantly direct , To establish the hepatic origin correlation with elevated GGT helps.

3. Synthetic function impairment:*Albumin- Liver disease reduces albumin levels, Correlation with PT (Prothrombin Time) helps.

4. Associated tests for assessment of liver fibrosis - Fibrosis-4 and APRI Index.



Dr. SHWETA GUPTA
MBBS,MD (Pathology)
Consultant Pathology

SIN No:SE04844530



Patient Name : Mrs.SATKAR DEEP KAUR	Collected : 13/Nov/2024 10:00AM
Age/Gender : 54 Y 6 M 8 D/F	Received : 13/Nov/2024 11:06AM
UHID/MR No : SCHI.0000025322	Reported : 13/Nov/2024 01:39PM
Visit ID : SCHIOPV39123	Status : Final Report
Ref Doctor : Dr.SELF	Sponsor Name : ARCOFEMI HEALTHCARE LIMITED
Emp/Auth/TPA ID : 81027	

DEPARTMENT OF BIOCHEMISTRY

ARCOFEMI - MEDIWHEEL - FULL BODY ANNUAL PLUS CHECK ADVANCED - FEMALE - 2D ECHO - PAN INDIA - FY2324

Test Name	Result	Unit	Bio. Ref. Interval	Method
RENAL PROFILE/KIDNEY FUNCTION TEST (RFT/KFT) , SERUM				
CREATININE	0.70	mg/dL	0.5-1.04	Creatinine amidohydrolase
UREA	26.50	mg/dL	15-36	Urease
BLOOD UREA NITROGEN	12.4	mg/dL	8.0 - 23.0	Calculated
URIC ACID	4.30	mg/dL	2.5-6.2	Uricase
CALCIUM	9.30	mg/dL	8.4 - 10.2	Arsenazo-III
PHOSPHORUS, INORGANIC	5.10	mg/dL	2.5-4.5	PMA Phenol
SODIUM	146	mmol/L	135-145	Direct ISE
POTASSIUM	4.8	mmol/L	3.5-5.1	Direct ISE
CHLORIDE	112	mmol/L	98 - 107	Direct ISE
PROTEIN, TOTAL	7.80	g/dL	6.3-8.2	Biuret
ALBUMIN	4.10	g/dL	3.5 - 5	Bromocresol Green
GLOBULIN	3.70	g/dL	2.0-3.5	Calculated
A/G RATIO	1.11		0.9-2.0	Calculated



Dr. SHWETA GUPTA
MBBS,MD (Pathology)
Consultant Pathology
SIN No:SE04844530



Patient Name : Mrs.SATKAR DEEP KAUR	Collected : 13/Nov/2024 10:00AM
Age/Gender : 54 Y 6 M 8 D/F	Received : 13/Nov/2024 11:06AM
UHID/MR No : SCHI.0000025322	Reported : 13/Nov/2024 11:38AM
Visit ID : SCHIOPV39123	Status : Final Report
Ref Doctor : Dr.SELF	Sponsor Name : ARCOFEMI HEALTHCARE LIMITED
Emp/Auth/TPA ID : 81027	

DEPARTMENT OF BIOCHEMISTRY

ARCOFEMI - MEDIWHEEL - FULL BODY ANNUAL PLUS CHECK ADVANCED - FEMALE - 2D ECHO - PAN INDIA - FY2324

Test Name	Result	Unit	Bio. Ref. Interval	Method
GAMMA GLUTAMYL TRANSPEPTIDASE (GGT) , SERUM	14.00	U/L	12-43	Glycylglycine Nitoranalide



Dr. SHWETA GUPTA
MBBS,MD (Pathology)
Consultant Pathology
SIN No:SE04844530



Patient Name : Mrs.SATKAR DEEP KAUR	Collected : 13/Nov/2024 10:00AM
Age/Gender : 54 Y 6 M 8 D/F	Received : 13/Nov/2024 01:23PM
UHID/MR No : SCHI.0000025322	Reported : 13/Nov/2024 03:07PM
Visit ID : SCHIOPV39123	Status : Final Report
Ref Doctor : Dr.SELF	Sponsor Name : ARCOFEMI HEALTHCARE LIMITED
Emp/Auth/TPA ID : 81027	

DEPARTMENT OF IMMUNOLOGY

ARCOFEMI - MEDIWHEEL - FULL BODY ANNUAL PLUS CHECK ADVANCED - FEMALE - 2D ECHO - PAN INDIA - FY2324


Test Name	Result	Unit	Bio. Ref. Interval	Method
THYROID PROFILE TOTAL (T3, T4, TSH) , SERUM				
TRI-iodothyronine (T3, TOTAL)	1.08	ng/mL	0.87-1.78	CLIA
THYROXINE (T4, TOTAL)	15.8	µg/dL	5.48-14.28	CLIA
THYROID STIMULATING HORMONE (TSH)	3.800	µIU/mL	0.38-5.33	CLIA

Comment:

For pregnant females	Bio Ref Range for TSH in uIU/ml (As per American Thyroid Association)
First trimester	0.1 - 2.5
Second trimester	0.2 – 3.0
Third trimester	0.3 – 3.0

- TSH is a glycoprotein hormone secreted by the anterior pituitary. TSH activates production of T3 (Triiodothyronine) and its prohormone T4 (Thyroxine). Increased blood level of T3 and T4 inhibit production of TSH.
- TSH is elevated in primary hypothyroidism and will be low in primary hyperthyroidism. Elevated or low TSH in the context of normal free thyroxine is often referred to as sub-clinical hypo- or hyperthyroidism respectively.
- Both T4 & T3 provides limited clinical information as both are highly bound to proteins in circulation and reflects mostly inactive hormone. Only a very small fraction of circulating hormone is free and biologically active.
- Significant variations in TSH can occur with circadian rhythm, hormonal status, stress, sleep deprivation, medication & circulating antibodies.

TSH	T3	T4	FT4	Conditions
High	Low	Low	Low	Primary Hypothyroidism, Post Thyroidectomy, Chronic Autoimmune Thyroiditis
High	N	N	N	Subclinical Hypothyroidism, Autoimmune Thyroiditis, Insufficient Hormone Treatment.
N/Low	Low	Low	Low	Secondary and Tertiary Hypothyroidism
Low	High	High	High	Primary Hyperthyroidism, Goitre, Thyroiditis, Drug effects, Early Pregnancy
Low	N	N	N	Subclinical Hyperthyroidism
Low	Low	Low	Low	Central Hypothyroidism, Treatment with Hyperthyroidism
Low	N	High	High	Thyroiditis, Interfering Antibodies
N/Low	High	N	N	T3 Thyrotoxicosis, Non thyroidal causes



Dr Nidhi Sachdev
M.B.B.S,MD(Pathology)
Consultant Pathologist

SIN No:SPL24146667



Patient Name : Mrs.SATKAR DEEP KAUR	Collected : 13/Nov/2024 10:00AM
Age/Gender : 54 Y 6 M 8 D/F	Received : 13/Nov/2024 01:23PM
UHID/MR No : SCHI.0000025322	Reported : 13/Nov/2024 03:07PM
Visit ID : SCHIOPV39123	Status : Final Report
Ref Doctor : Dr.SELF	Sponsor Name : ARCOFEMI HEALTHCARE LIMITED
Emp/Auth/TPA ID : 81027	

DEPARTMENT OF IMMUNOLOGY

ARCOFEMI - MEDIWHEEL - FULL BODY ANNUAL PLUS CHECK ADVANCED - FEMALE - 2D ECHO - PAN INDIA - FY2324

High	High	High	High	Pituitary Adenoma; TSHoma/Thyrotropinoma
------	------	------	------	--



Dr Nidhi Sachdev
M.B.B.S,MD(Pathology)
Consultant Pathologist

SIN No:SPL24146667



Patient Name : Mrs.SATKAR DEEP KAUR	Collected : 13/Nov/2024 10:00AM
Age/Gender : 54 Y 6 M 8 D/F	Received : 13/Nov/2024 05:44PM
UHID/MR No : SCHI.0000025322	Reported : 13/Nov/2024 06:11PM
Visit ID : SCHIOPV39123	Status : Final Report
Ref Doctor : Dr.SELF	Sponsor Name : ARCOFEMI HEALTHCARE LIMITED
Emp/Auth/TPA ID : 81027	

DEPARTMENT OF CLINICAL PATHOLOGY

ARCOFEMI - MEDIWHEEL - FULL BODY ANNUAL PLUS CHECK ADVANCED - FEMALE - 2D ECHO - PAN INDIA - FY2324

Test Name	Result	Unit	Bio. Ref. Interval	Method
COMPLETE URINE EXAMINATION (CUE) , URINE				
PHYSICAL EXAMINATION				
COLOUR	PALE YELLOW		PALE YELLOW	Visual
TRANSPARENCY	CLEAR		CLEAR	Physical Measurement
pH	6.0		5-7.5	Double Indicator
SP. GRAVITY	1.030		1.002-1.030	Bromothymol Blue
BIOCHEMICAL EXAMINATION				
URINE PROTEIN	NEGATIVE		NEGATIVE	Protein Error Of Indicator
GLUCOSE	NEGATIVE		NEGATIVE	Glucose Oxidase
URINE BILIRUBIN	NEGATIVE		NEGATIVE	Azo Coupling Reaction
URINE KETONES (RANDOM)	NEGATIVE		NEGATIVE	Sodium Nitro Prusside
UROBILINOGEN	NORMAL		NORMAL	Modified Ehrlich Reaction
NITRITE	NEGATIVE		NEGATIVE	Diazotization
LEUCOCYTE ESTERASE	NEGATIVE		NEGATIVE	Leucocyte Esterase
CENTRIFUGED SEDIMENT WET MOUNT AND MICROSCOPY				
PUS CELLS	1-2	/hpf	0-5	Microscopy
EPITHELIAL CELLS	2-4	/hpf	<10	Microscopy
RBC	ABSENT	/hpf	0-2	Microscopy
CASTS	ABSENT		0-2 Hyaline Cast	Microscopy
CRYSTALS	ABSENT		ABSENT	Microscopy

Comment:

All urine samples are checked for adequacy and suitability before examination. All abnormal chemical examination are rechecked and verified by manual methods. Microscopy findings are reported as an average of 10 high power fields.



Dr. SHWETA GUPTA
MBBS,MD (Pathology)
Consultant Pathology
SIN No:UR2419750



Patient Name : Mrs.SATKAR DEEP KAUR	Collected : 13/Nov/2024 10:00AM
Age/Gender : 54 Y 6 M 8 D/F	Received : 13/Nov/2024 05:44PM
UHID/MR No : SCHI.0000025322	Reported : 13/Nov/2024 06:11PM
Visit ID : SCHIOPV39123	Status : Final Report
Ref Doctor : Dr.SELF	Sponsor Name : ARCOFEMI HEALTHCARE LIMITED
Emp/Auth/TPA ID : 81027	

DEPARTMENT OF CLINICAL PATHOLOGY

ARCOFEMI - MEDIWHEEL - FULL BODY ANNUAL PLUS CHECK ADVANCED - FEMALE - 2D ECHO - PAN INDIA - FY2324

Test Name	Result	Unit	Bio. Ref. Interval	Method
URINE GLUCOSE(POST PRANDIAL)	NEGATIVE		NEGATIVE	GOD-POD

Test Name	Result	Unit	Bio. Ref. Interval	Method
URINE GLUCOSE(FASTING)	NEGATIVE		NEGATIVE	GOD-POD

***** End Of Report *****

Result/s to Follow:
LBC PAP SMEAR



Dr. SHWETA GUPTA
MBBS,MD (Pathology)
Consultant Pathology
SIN No:UF012163



Patient Name : Mrs.SATKAR DEEP KAUR
Age/Gender : 54 Y 6 M 8 D/F
UHID/MR No : SCHI.0000025322
Visit ID : SCHIOPV39123
Ref Doctor : Dr.SELF
Emp/Auth/TPA ID : 81027

Collected : 13/Nov/2024 10:00AM
Received : 13/Nov/2024 05:44PM
Reported : 13/Nov/2024 06:11PM
Status : Final Report
Sponsor Name : ARCOFEMI HEALTHCARE LIMITED

TERMS AND CONDITIONS GOVERNING THIS REPORT

1. Reported results are for information and interpretation of the referring doctor or such other medical professionals, who understand reporting units, reference ranges and limitation of technologies. Laboratories not be responsible for any interpretation whatsoever.
2. It is presumed that the tests performed are, on the specimen / sample being to the patient named or identified and the verifications of particulars have been confirmed by the patient or his / her representative at the point of generation of said specimen.
3. The reported results are restricted to the given specimen only. Results may vary from lab to lab and from time to time for the same parameter for the same patient (within subject biological variation).
4. The patient details along with their results in certain cases like notifiable diseases and as per local regulatory requirements will be communicated to the assigned regulatory bodies.
5. The patient samples can be used as part of internal quality control, test verification, data analysis purposes within the testing scope of the laboratory.
6. This report is not valid for medico legal purposes. It is performed to facilitate medical diagnosis only.



Dr. SHWETA GUPTA
MBBS,MD (Pathology)
Consultant Pathology
SIN No:UF012163

