


MER- MEDICAL EXAMINATION REPORT

Date of Examination	24-06-2023		
NAME	Mrs. RASHMITA MOHANTY		
AGE	40	Gender	Female
HEIGHT(cm)	158 cm	WEIGHT (kg)	68 kg
B.P.	120/80		
ECCG	NORMAL		
X Ray	NORMAL		
Vision Checkup	-		
Present Ailments	-		
Details of Past ailments (If Any)	-		
Comments / Advice : She / He is Physically Fit	fit		

BMI = 27.2 kg/m² (overweight)



Signature with Stamp of Medical Examiner

Dr. Mukesh Dubey
 (MBBS DCP)
 Registration No.-10632
Panel Medical Examiner
 Triveni Diagnostic & Research Centre
 Agrawal Plaza, B-7, H.I.G Main Road,
 INDORE



भारतीय विशिष्ट पहचान प्राधिकरण
भारत सरकार
 Unique Identification Authority of India
 Government of India


नामांकन क्रम/ Enrolment No.: 0000/00533/95585

Download Date: 18/04/2018

To
 रसमिता मोहंती
 Rasmita Mohanty
 C/O Prasant Kumar Mohanty
 43
 Hanuman Nagar
 Khandwa
 Near Navchandi Mandir
 Khandwa
 Khandwa Madhya Pradesh - 450001
 7587816053

Generation Date: 26/09/2018

Validity: unknown
 Digitally signed by Rasmita Mohanty
 DN: cn=Rasmita Mohanty, o=Unique Identification Authority of India, email=R.Mohanty@uidai.gov.in, c=IN



QR Code with Photograph

आपका आधार क्रमांक / Your Aadhaar No. :

6879 9455 3088

VID : 9169 3555 4839 1932

मेरा आधार, मेरी पहचान



भारत सरकार
 Government of India



रसमिता मोहंती
 Rasmita Mohanty
 जन्म तिथि/DOB: 01/05/1983
 महिला/ FEMALE



6879 9455 3088

VID : 9169 3555 4839 1932

मेरा आधार, मेरी पहचान



Government of India



AADHAAR

सूचना

- आधार पहचान का प्रमाण है, नागरिकता का नहीं |
- पहचान का प्रमाण ऑनलाइन ऑथेंटिकेशन द्वारा प्राप्त करें |
- यह एक इलेक्ट्रॉनिक प्रक्रिया द्वारा बना हुआ पत्र है |

INFORMATION

- Aadhaar is a proof of identity, not of citizenship.
- To establish identity, authenticate online.
- This is electronically generated letter.

- आधार देश भर में मान्य है ।
- आधार भविष्य में सरकारी और गैर-सरकारी सेवाओं का लाभ उठाने में उपयोगी होगा ।
- Aadhaar is valid throughout the country .
- Aadhaar will be helpful in availing Government and Non-Government services in future .



भारतीय विशिष्ट पहचान प्राधिकरण
 Unique Identification Authority of India

पता:
 प्रसान्त कुमार मोहंती, 43, हनुमान नगर, नाचंडी मंदिर के पास, खंडवा, खंडवा, खंडवा, मध्य प्रदेश - 450001

Address:
 C/O Prasant Kumar Mohanty, 43, Hanuman Nagar, Near Navchandi Mandir, Khandwa, Khandwa, Khandwa, Madhya Pradesh - 450001



QR Code with Photograph

6879 9455 3088

VID : 9169 3555 4839 1932



UIDAI



UIDAI

UIDAI

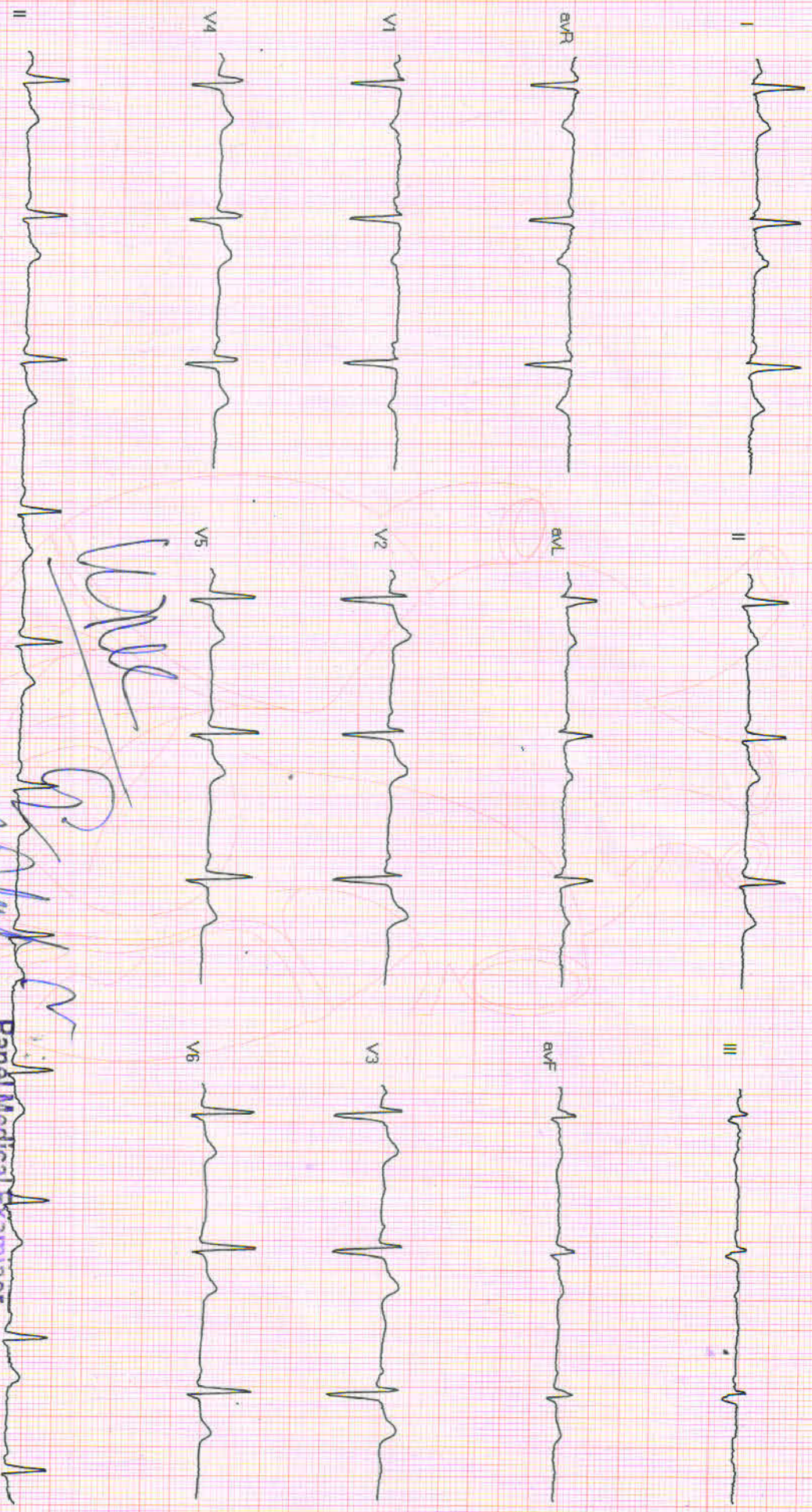
Panel Medical Examiner
 Triveni Diagnostic & Research Centre
 Agrawal Plaza, B-7, H.I.G Main Road,
 INDORE

TRIVENI DIAGNOSTICS & RESEARCH CENTRE

2534 / MRS. RASHMITA MOHANTY / 40 Yrs / F / Non Smoker

Heart Rate : 63 bpm / Tested On : 24-Jun-23 10:51:11 / HF 0.05 Hz - LF 20 Hz / Notch 50 Hz / Sn 1.00 Cm/mV / Sw 25 mm/s

ECG



WNL

Panel Medical Examiner

Triveni Diagnostics & Research Centre

Agrawal Plaza, B-7, H.I.O. Main Road,

INDORE

Reported By: HEALTH CHECK UP



Triveni Diagnostic Centre

Reg No. : 73395 VISITID : 0000077704
PATIENT NAME : MRS. RASHMITA MOHANTY SPEC. NO : 1905400971
AGE/SEX : 40 YEARS/FEMALE SAMP. DATE : 24/06/2023 12:03:00
REF. BY : Dr. ARCOFEMI HEALTHCARE LIMITED RESULT DATE : 26/06/2023 09:05:38

HEMATOLOGY

CBC (COMPLETE BLOOD COUNT)

NAME OF TEST	RESULT VALUE	REFERENCE RANGE	UNIT
HAEMOGLOBIN	10.5	12.5 - 16	gm/dl
TOTAL RBC COUNT	4.16	4 - 6.5	mill/cummm
HAEMATOCRIT (PCV)	33.3	35.9 - 44.6	%
MEAN CORPUS VOL(MCV)	80.05	80 - 96	f l
MEAN CORPUS HB (MCH)	25.24	27.5 - 33.2	picograms
MEAN CORPUS HB CONC (MCHC)	31.53	33.4 - 35.5	%
RDW	14.9	11.5 - 15.5	%
PDW	17.5	-	f l
MPV	12.3	-	f l
PCT	0.28	-	%
P-LCR	40.5	-	%
TOTAL WBC	12900	4000 - 11000	/cumm
PLATELET COUNT	2.28	1.5 - 4.0	Lacs/cumm
DIFFERENTIAL COUNT			
NEUTROPHILS	66	40 - 70	%
LYMPHOCYTES	25	20 - 40	%
MONOCYTES	02	1 - 8	%
EOSINOPHILS	07	0 - 6	%
BASOPHILS	00	0 - 1	%
ABSOLUTE NEUTROPHILS	8.62	2 - 7	X1000/cumm
ABSOLUTE LYMPHOCYTES	3.05	1 - 3	X1000/cumm
ABSOLUTE MONOCYTE	0.24	0.2 - 1	X1000/cumm
ABSOLUTE EOSINOPHIL	1.0	0.02 - 0.5	X1000/cumm
ABSOLUTE BASOPHIL	00	0.02 - 0.1	X1000/cumm
ESR	12	0 - 20	mm at end of 1
MP (MALARIA PARASITE)		-	

METHOD:- By five part automated analyzer (sysmex XS1000 i) Japan

DR. MUKESH DUBEY
(MBBS, DCP) (DIRECTOR)

DR. VIJAY BHURIYA
MBBS DMRD

DR. YOGESH PAWDE
M. D. (CONS. PATHOLOGIST)

DR. P.S. TRIPATHI
M.D. (RADIO DIAGNOSIS)

DR. SANJAY YADAV
CON. MICROBIOLOGIST

Report Checked By:

Address : Agrawal Plaza, B-7, HIG Main Road, Indore Ph. : 0731-4289992-3.
Website : www.trivenidiagnostic.com email : trivenidiagnostic@yahoo.co.in

Page 1 of 1



Triveni Diagnostic Centre

Reg No. : 73395 VISITID : 000077704
PATIENT NAME : MRS. RASHMITA MOHANTY SPEC. NO : 1905400971
AGE/SEX : 40 YEARS/FEMALE SAMP. DATE : 24/06/2023 12:03:00
REF. BY : Dr. ARCOFEMI HEALTHCARE LIMITED RESULT DATE : 26/06/2023 09:05:38

HEMATOLOGY

CBC (COMPLETE BLOOD COUNT)

NAME OF TEST	RESULT VALUE	REFERENCE RANGE	UNIT
HAEMOGLOBIN	10.5	12.5 - 16	gm/dl
TOTAL RBC COUNT	4.16	4 - 6.5	mill/cummm
HAEMATOCRIT (PCV)	33.3	35.9 - 44.6	%
MEAN CORPUS VOL(MCV)	80.05	80 - 96	f l
MEAN CORPUS HB (MCH)	25.24	27.5 - 33.2	picograms
MEAN CORPUS HB CONC (MCHC)	31.53	33.4 - 35.5	%
RDW	14.9	11.5 - 15.5	%
PDW	17.5	-	f l
MPV	12.3	-	f l
PCT	0.28	-	%
P-LCR	40.5	-	%
TOTAL WBC	12900	4000 - 11000	/cumm
PLATELET COUNT	2.28	1.5 - 4.0	Lacs/cumm
DIFFERENTIAL COUNT			
NEUTROPHILS	66	40 - 70	%
LYMPHOCYTES	25	20 - 40	%
MONOCYTES	02	1 - 8	%
EOSINOPHILS	07	0 - 6	%
BASOPHILS	00	0 - 1	%
ABSOLUTE NEUTROPHILS	8.62	2 - 7	X1000/cumm
ABSOLUTE LYMPHOCYTES	3.05	1 - 3	X1000/cumm
ABSOLUTE MONOCYTE	0.24	0.2 - 1	X1000/cumm
ABSOLUTE EOSINOPHIL	1.0	0.02 - 0.5	X1000/cumm
ABSOLUTE BASOPHIL	00	0.02 - 0.1	X1000/cumm
ESR	12	0 - 20	mm at end of 1
MP (MALARIA PARASITE)	.	-	

METHOD:- By five part automated analyzer (sysmex XS1000 i) Japan

DR. MUKESH DUBEY
(MBBS, DCP) (DIRECTOR)

DR. VIJAY BHURIYA
MBBS DMRD

DR. YOGESH PAWDE
M. D. (CONS. PATHOLOGIST)

DR. P.S. TRIPATHI
M.D. (RADIO DIAGNOSIS)

DR. SANJAY YADAV
CON. MICROBIOLOGIST

Report Checked By:

Address : Agrawal Plaza, B-7, HIG Main Road, Indore Ph. : 0731-4289992-3
Website : www.trivenidiagnostic.com email : trivenidiagnostic@yahoo.co.in

Page 1 of 1



Triveni Diagnostic Centre

Reg. No. : 73395 VISITID : 0000077704
PATIENT NAME : MRS. RASHMITA MOHANTY SPEC. NO : 1905400967
AGE/SEX : 40 YEARS/FEMALE SAMP. DATE : 24/06/2023 12:03:00
REF. BY : Dr. ARCOFEMI HEALTHCARE LIMITED RESULT DATE : 26/06/2023 09:08:02

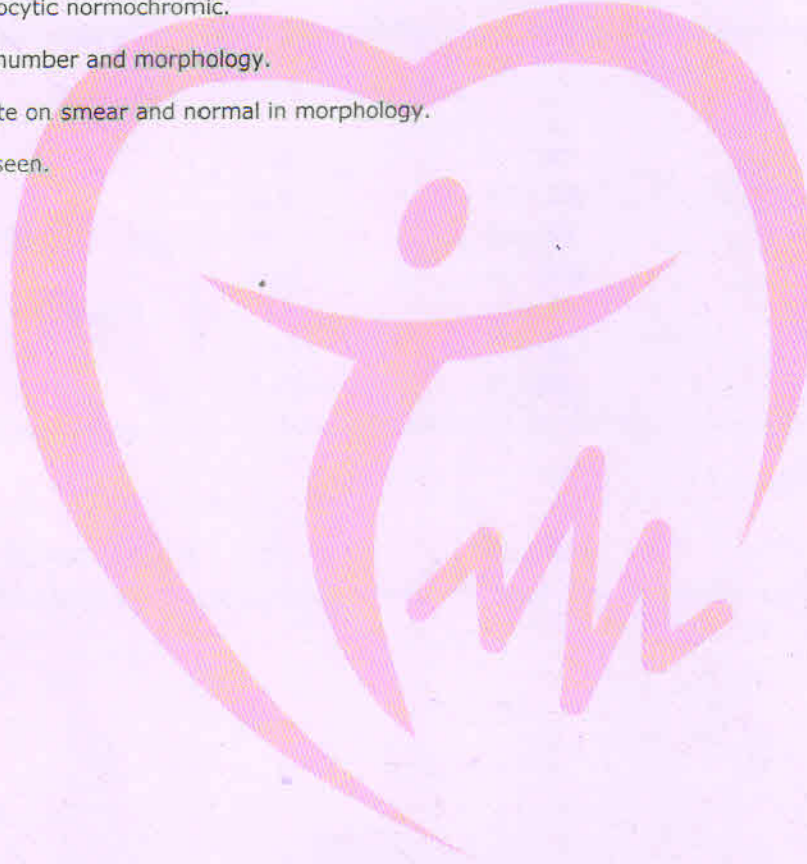
NAME OF TEST	RESULT VALUE		REFERENCE RANGE	UNIT
	IN RANGE	OUT RANGE		

PERIPHERAL SMEAR EXAMINATION

PERIPHERAL SMEAR

REMARKS :

Rbcs They are normocytic normochromic.
Wbcs are normal in number and morphology.
Platelets are adequate on smear and normal in morphology.
No hemoparasite is seen.



DR. MUKESH DUBEY
(MBBS, DCP) (DIRECTOR)

DR. VIJAY BHURIYA
MBBS DMRD

DR. YOGESH PAWDE
M. D. (CONS. PATHOLOGIST)

DR. P.S. TRIPATHI
M.D. (RADIO DIAGNOSIS)

DR. SANJAY YADAV
CON. MICROBIOLOGIST

Report Checked By :

Address : Agrawal Plaza, B-7, HIG Main Road, Indore Ph. : 0731-4289992-3
Website : www.trivenidiagnostic.com email : trivenidiagnostic@yahoo.co.in

Page 1 of 1



Triveni Diagnostic Centre

Reg No. : 73395 VISITID : 0000077704
PATIENT NAME : MRS. RASHMITA MOHANTY SPEC. NO : 1905400968
AGE/SEX : 40 YEARS/FEMALE SAMP. DATE : 24/06/2023 12:03:00
REF. BY : Dr. ARCOFEMI HEALTHCARE LIMITED RESULT DATE : 26/06/2023 09:06:24

DEPARTMENT OF PATHOLOGY

NAME OF TEST	RESULT VALUE	REFERENCE RANGE	UNIT
FBS			
FBS	101	70 - 110	mg / dl

RESULT REMARKS : Test done by -"Roche COBAS- ENTEGRA 400 PLUS "fully bichemistry analyser .

LIPID PROFILE

CHOLESTEROL	155	0 - 200	mg / dl
TRIGLYCERIDES	118	50 - 190	mg / dl
HDL(HIGH DENSITY LIPIDS)	42	35 - 65	mg / dl
LDL	89.4	50 - 190	mg / dl
VLDL (VERY LOW DENSITY LIPIDS)	23.6	15 - 30	mg / dl
Cholestrol : HDL	3.69	3.5 - 5.5	
LDL : HDL	2.13	0 - 3.5	mg / dl

RESULT REMARKS : Test done by -"Roche COBAS- ENTEGRA 400 PLUS "fully bichemistry analyser .

P7BS

PPBS (POST PRANDIAL BLOOD SUGAR)	121	70 - 140	mg / dl
----------------------------------	-----	----------	---------

RESULT REMARKS : Test done by -"Roche COBAS- ENTEGRA 400 PLUS "fully bichemistry analyser .

URINE FOR SUGAR

URINE SUGAR Nil

RESULT REMARKS :

DR. MUKESH DUBEY
(MBBS, DCP) (DIRECTOR)

DR. VIJAY BHURIYA
MBBS DMRD

DR. YOGESH PAWDE
M. D. (CONS. PATHOLOGIST)

DR. P.S. TRIPATHI
M.D. (RADIO DIAGNOSIS)

DR. SANJAY YADAV
CON. MICROBIOLOGIST

Report Checked By :

Page 1 of 1



Triveni Diagnostic Centre

Reg No. : 73395 VISITID : 000077704
PATIENT NAME : MRS. RASHMITA MOHANTY SPEC. NO : 1905400972
AGE/SEX : 40 YEARS/FEMALE SAMP. DATE : 24/06/2023 12:04:00
REF. BY : Dr. ARCOFEMI HEALTHCARE LIMITED RESULT DATE : 26/06/2023 09:10:09

BIO-CHEMISTRY

HBA1 C (GLYCOSYLATED HEAMOGLOBIN)

NAME OF TEST	RESULT VALUE	REFERENCE RANGE	UNIT
HBA1 C (GLYCOSYLATED HEAMOGLOBIN)	5.2	Normal: 4-6 Good cntrol:6.1-7.0 Fair control :7.0-8.2 Unsatisfactory control: 8.0-10.2 Poor control: Above 10.0	%
MEAN PLASMA GLUCOSE (MPG)	103	Exelent Control:90-120 Good Control:121-150 Avrege Control:151-180 Action Suggested:181-210 Panic value :>211	mg/dL

Test done by -"Roche COBAS- ENTEGRA 400 PLUS "fully bichemistry analyser .

METHOD BY: Turbidimetric inhibition immunoassay(TINIA)

Average blood glucose value is calculated from HBA1C value and indicates average blood sugar level over past three months.

DR. MUKESH DUBEY
(MBBS DCP) (DIRECTOR)

DR. VIJAY BHURIYA
MBBS DMRD

DR. YOGESH PAWDE
M. D. (CONS. PATHOLOGIST)

DR. P.S. TRIPATHI
M.D.(RADIO DIAGNOSIS)

DR. SANJAY YADAV
CON. MICROBIOLOGIST

Report Checked By:

Address : Agrawal Plaza, B-7, HIG Main Road, Indore Ph. : 0731-4289992-3
Website : www.trivenidiagnostic.com email : trivenidiagnostic@yahoo.co.in

Page 1 of 1




Triveni Diagnostic Centre

Reg No. : 73395 VISITID : 0000077704
PATIENT NAME : MRS. RASHMITA MOHANTY SPEC. NO : 1905400968
AGE/SEX : 40 YEARS/FEMALE SAMP. DATE : 24/06/2023 12:03:00
REF. BY : Dr. ARCOFEMI HEALTHCARE LIMITED RESULT DATE : 26/06/2023 09:08:32

BIO-CHEMISTRY

RENAL PROFILE

NAME OF TEST	RESULT VALUE	REFERENCE RANGE	UNIT
UREA	22	10 - 40	mg / dl
CREATININE	0.72	0.6 - 1.2	mg / dl
SERUM SODIUM	140.2	135 - 155	mmol/L
SERUM POTASIUUM	4.8	3.5 - 5.5	mmol/L



DR. MUKESH DUBEY
(MBBS. DCP) (DIRECTOR)

DR. VIJAY BHURIYA
MBBS DMRD

DR. YOGESH PAWDE
M. D. (CONS. PATHOLOGIST)

DR. P.S. TRIPATHI
M.D. (RADIO DIAGNOSIS)

DR. SANJAY YADAV
CON. MICROBIOLOGIST

Report Checked By:

Address : Agrawal Plaza, B-7, HIG Main Road, Indore Ph. : 0731-4289992-3
Website : www.trivenidiagnostic.com email : trivenidiagnostic@yahoo.co.in

Page 1 of 1



Triveni Diagnostic Centre

Reg No. : 73395
PATIENT NAME : MRS. RASHMITA MOHANTY
AGE/SEX : 40 YEARS/FEMALE
REF. BY : Dr. ARCOFEMI HEALTHCARE LIMITED
VISITID : 0000077704
SPEC. NO : 1905400968
SAMP. DATE : 24/06/2023 12:03:00
RESULT DATE : 26/06/2023 09:07:39

NAME OF TEST	RESULT VALUE		REFERENCE RANGE	UNIT
	IN RANGE	OUT RANGE		
LFT (LIVER FUNCTION TEST)				
TOTAL BILIRUBIN	0.85		0.2 - 1.3	mg/dL
DIRECT BILIRUBIN	0.51		0.2 - 0.65	mg / dl
INDIRECT BILIRUBIN	0.34		0.2 - 0.8	mg / dl
SGOT(AST)	29		0 - 40	U / L
SGPT(ALT)	24		0 - 40	U / L
ALKALINE PHOSPHATASE	102		37 - 143	U / L
PROTEINS	6.82		6 - 8.3	g / dl
ALBUMIN	4.12		3.5 - 5	gm/dl
GLOBULIN	2.7		1.9 - 3.5	g / dl
A.G.RATIO	1.52		0.5 - 2	mg / dl
PT (PROTHROMBIN TIME)		15	-	seconds
CONTROL		14	-	seconds
(INR) INTERNATIONALNARMLISED RATIO		1.07	-	seconds

REMARKS :

METHOD: BY COBAS INTEGRA 400 PLUS.

DR. MUKESH DUBEY
(MBBS. DCP) (DIRECTOR)

DR. VIJAY BHURIYA
MBBS DMRD

DR. YOGESH PAWDE
M. D. (CONS. PATHOLOGIST)

DR. P.S. TRIPATHI
M.D. (RADIO DIAGNOSIS)

DR. SANJAY YADAV
CON. MICROBIOLOGIST

Report Checked By :

Address : Agrawal Plaza, B-7, HIG Main Road, Indore Ph. : 0731-4289992-3
Website : www.trivenidiagnostic.com email : trivenidiagnostic@yahoo.co.in



Triveni Diagnostic Centre

Reg No. : 73395 VISITID : 0000077704
PATIENT NAME : MRS. RASHMITA MOHANTY SPEC. NO : 1905400971
AGE/SEX : 40 YEARS/FEMALE SAMP. DATE : 24/06/2023 12:03:00
REF. BY : Dr. ARCOFEMI HEALTHCARE LIMITED RESULT DATE : 26/06/2023 09:07:22

DEPARTMENT OF PATHOLOGY

NAME OF TEST	RESULT VALUE	REFERENCE RANGE	UNIT
BLOOD GROUP			
BLOOD GROUP	"O"	-	
RH FACTOR	Positive	-	
RESULT REMARKS :			
GAMA GT			
GGT (GAMMA GLUTAMYL TRANSFERASE)	34	5 - 36	U / L
RESULT REMARKS :			

DR. MUKESH DUBEY
(MBBS, DCP) (DIRECTOR)

DR. VIJAY BHURIYA
MBBS DMRD

DR. YOGESH PAWDE
M. D. (CONS. PATHOLOGIST)

DR. P.S. TRIPATHI
M.D. (RADIO DIAGNOSIS)

DR. SANJAY YADAV
CON. MICROBIOLOGIST

Report Checked By :

Page 1 of 1



Triveni Diagnostic Centre

Reg No. : 73395 VISITID : O000077704
PATIENT NAME : MRS. RASHMITA MOHANTY SPEC. NO : 1905400968
AGE/SEX : 40 YEARS/FEMALE SAMP. DATE : 24/06/2023 12:03:00
REF. BY : Dr. ARCOFEMI HEALTHCARE LIMITED RESULT DATE : 26/06/2023 09:08:52

IMMUNO ASSAY

T3, T4 TSH

NAME OF TEST	RESULT VALUE	REFERENCE RANGE	UNIT
T3 (TRIIODOTHYRONINE)	0.95	Adults:- 0.60-1.58 Children:- 0-3 days:- 0.96- 2.92 1-11 months 0.81-2.81 1-5 years 0.83-2.52 6-10 years 0.92-2.19 11-15years 0.83-2.15	ng/ml
T4 (THYROXINE)	6.7	Adults:- 5.01-11.0 Children:- 0-3 days 11.80-22.60 4-30 days not Established 1-2 weeks 9.80-16.60 1-4 months 7.20-14.40 4-12 months 7.80-16.50	ug/dl
TSH (THYROID STIMULATING HORMONE)	1.04	Adults:- 0.38-4.31 Children:- 0-3 days:- 1.0-39.0 4-30 days:- 0.43-16.1 2-12 months:- 0.62-8.05 2-6 years:- 0.54-4.53 7-11 years:- 0.66-4.14 12-19 years:- 0.53-3.59	uIU/ml

Method: By AIA-360 (TOSOH) fully automated electro chemiluminescence immunoassay

INTERPRETATION: Suppressed TSH values are seen in hyperthyroid patients with the exception of hyperthyroidism caused by a TSH producing pituitary tumors. In addition TSH is suppressed in individuals treated with the exogenous thyroid hormones. Elevated TSH values are seen in primary hypothyroidism with the exception of hypothyroidisms caused by pituitary disorders. Note: Total T3 and T4 values may also be altered in other conditions due to changes in serum proteins or binding sites pregnancy, drugs (Androgens, Estrogens, O C pills, Phenyton) nephrosis etc. In such cases free T3 and T4 give corrected values.

DR. MUKESH DUBEY
(MBBS, DCP) DIRECTOR

DR. VIJAY BHURIYA
MBBS DMRD

DR. YOGESH PAWDE
M. D. (CONS. PATHOLOGIST)

DR. P.S. TRIPATHI
M.D. (RADIO DIAGNOSIS)

DR. SANJAY YADAV
CON. MICROBIOLOGIST

Report Checked By:

Address : Agrawal Plaza, B-7, HIG Main Road, Indore Ph. : 0731-4289992-3
Website : www.trivenidiagnostic.com email : trivenidiagnostic@yahoo.co.in



Triveni Diagnostic Centre

Reg No. : 73395 VISITID : 000077704
PATIENT NAME : MRS. RASHMITA MOHANTY SPEC. NO : 1905400970
AGE/SEX : 40 YEARS/FEMALE SAMP. DATE : 24/06/2023 12:03:00
REF. BY : Dr. ARCOFEMI HEALTHCARE LIMITED RESULT DATE : 26/06/2023 09:09:46

CLINICAL-PATHOLOGY

URINE EXAMINATION

NAME OF TEST	RESULT VALUE	REFERENCE RANGE	UNIT
PHYSICAL EXAMINATION			
QUANTITY	20	-	ml
COLOUR	Pale Yellow	-	
APPEARANCE	Clear	-	
REACTION	Acidic	-	
Specific Gravity	1.010	-	
CHEMICAL EXAMINATION			
ALBUMIN	Nil	-	
URINE SUGAR	Nil	-	
Ketone Bodies	Nil	-	
BLOOD	Nil	-	
Bile Pigment	Nil	-	
Bile Salts	Nil	-	
MICROSCOPIC EXAMINATION			
Pus Cells	2-3/hpf	2 - 5	/hpf
Epithelial Cells	4-5/hpf	5 - 10	/hpf
RBCs	Nil	-	
Casts	Nil	-	
Crystals	Nil	-	
Spermatozoa	Nil	-	
Bacteria	Nil	-	
Others	.	-	

DR. MUKESH DUBEY
MBBS, DCP (DIRECTOR)

DR. VIJAY BHURIYA
MBBS, DMRD

DR. YOGESH PAWDE
M. D. (CONS. PATHOLOGIST)

DR. P.S. TRIPATHI
M.D. (RADIO DIAGNOSIS)

DR. SANJAY YADAV
CON. MICROBIOLOGIST

Report Checked By:

Address : Agrawal Plaza, B-7, HIG Main Road, Indore Ph. : 0731-4289992-3
Website : www.trivenidiagnostic.com email : trivenidiagnostic@yahoo.co.in

Page 1 of 1



Triveni Diagnostic Centre

PATIENT NAME : MRS. RASHMITA MOHANTY

AGE/SEX : 40 Y/F

REF BY : Dr. ARCOFEMI HEALTHCARE LIMITED

DATE : 24/06/2023

Pap smear

Cellularity-----satisfactory

Endocervical cell-----seen

Clue cell- Not Seen.

Reactive cellular changes --- Seen

Cytological smear show moderate cellularity comprised of benign superficial and intermediate squamous cells with many acute inflammatory cells. No malignant or atypical cell seen in smear examinaed.

Impression - **inflammatory smear**
Negative for intraepithelial lesion or malignancy(NILM)

ADV—kindly correlate clinically and radiologically.

DR. YOGESH PAWDE
MD.PATH



Triveni Diagnostic & Research Centre

Reg. No. : 73395 Visit ID : 0000077704
Patient Name : MRS. RASHMITA MOHANTY
Age / Sex : 40 YEARS / FEMALE Order Date : 24/06/23 11:49AM
Ref. By : Dr. ARCOFEMI HEALTHCARE LIMITED Report Date : 24/06/23 01:08PM

SONOGRAPHY

USG WHOLE ABDOMEN(FEMALE)

Liver is normal in size (12.9 cm) with smooth contour and homogenous echotexture. Intra hepatic biliary radicals are not dilated. Portal & splenic veins are normal in caliber.

Bladder is normal in size with thin walls & lumen is free from calculi/polyp. CHD & CBD are not dilated.

Pancreas is normal shaped with homogenous echotexture.

Spleen is visualized subcostally & normal in size in size.

Kidneys are normal in size (Rt 11.7 X 4.4 Lt. 11.4 X 4.9 cms), contour, position and show normal cortical echogenicity & CMJ. No evidence of calculus or calcification on either sides. Pelvicalyceal systems & ureters are undilated.

No abdominal/ pelvic lymphadenopathy is seen.

Urinary bladder is adequately filled with anechoic contents.

Mucosa is smooth and wall thickness measures normal.

Uterus is mildly bulky in size & antverted.

Approx 1.9 x 1.6 cm size well defined heterogeneously hypochoic soft tissue lesion seen in the posterior submucosal region S/O submucosal fibroid.

Approx. 1.7 x 1.4 cm & 1.4 x 0.8 cm size well defined heterogeneously hypochoic soft tissue lesions are seen in the posterior wall of uterus & 0.7 cm in anterior wall S/O Intramural fibroids.

Cervix appears to be normal.

Uterus Size 9.3 x 4.8 x 5.9 cm.

Endometrium is thickened measuring 13.5 mm.

Ovaries are normal.

Mild free fluid seen in POD.

IMPRESSION: Mild bulky uterus with thickened endometrium.

Uterine fibroids (Submucosal & intramural).

Kindly correlate.

DR. MUKESH DUBEY

(MBBS, DCP)

DR. VIJAY BHURIYA

MBBS DMRD

DR. AMIT SHANKHWAR

M.D. RADIO DIAGNOSIS

DR. P.S. TRIPATHI

M.D. RADIO DIAGNOSIS

DR. SANJAY YADAV

CONSULTANT MICROBIOLOGIST



Triveni Diagnostic Centre

Name :- Mrs. Rashmita Mohanty

Age:- 40 Yrs / Female

Ref. By.:-Dr . Health Check Up

Date: - 24/ 6 /2023

ECHOCARDIOGRAPHYREPORT

INTERPRETATION:- Normal 2-D Echo / Dopplar.

No LV RWMA seen.

LVEF IS 65%.

2 IMAGING M Mode examination revealed normal movement of both mitral leaflets during diastole. No SAM or mitral valve prolapsed is seen. Aortic cups are normal and enclosure line is central. Tricuspid valve is normal. Pulmonary valve is normal. Aortic root is normal in size. Dimension of left atrium and left ventricles are normal.

3. Dimaging in PLAX,SAX and apical views revealed a normal left ventricle. Movement of septum anterior, posterior, inferior and lateral walls is normal. Global LVEF 65%. mitral valve opening is normal. No evidence of mitral valve prolapsed is seen. Aortic valve has three cups and its opening is not restricted. Right atrium & right ventricle are normal sized. Tricuspid valve leaflets move normally. Pulmonary valve is normal. Interatrial and intraventricular septa are intact. No intracardiac mass or thrombus is seen. No pericardial pathology is observed.


Dr. Rahul Talati
MBBS MD
Cardiologist

Valve

Aortic root diameter	3.0cms	2.0-3.7cm<2.2cm/M2
Aortic valve opening	1.8cms	1.5-2.6cm
Right ventricular dimension	2.1cms	0.7-2.5cm<2.2cm/M2
Left atrium dimension	3.3cms	1.9-4.0cm<2.2cm/M2
Left ventricular ED dimension	4.3cms	3.7-5.6cm<3.2cm/M2
Left ventricular ES dimension	2.8cms	2.2-4.0cm
Intraventricular ED septal thickness	0.8cms	0.6-1.2 cm
Left vent ED PW thickness	0.8cms	0.5- 1.0 cm
IVS/LVPW	<N	<1.3

INDICES OF LEFT VENTRICLE FUNCTION:

Mitral E – septal separation	.5	cms <0.9 cm
LV Ejection Fraction	65%	60 %- 80%

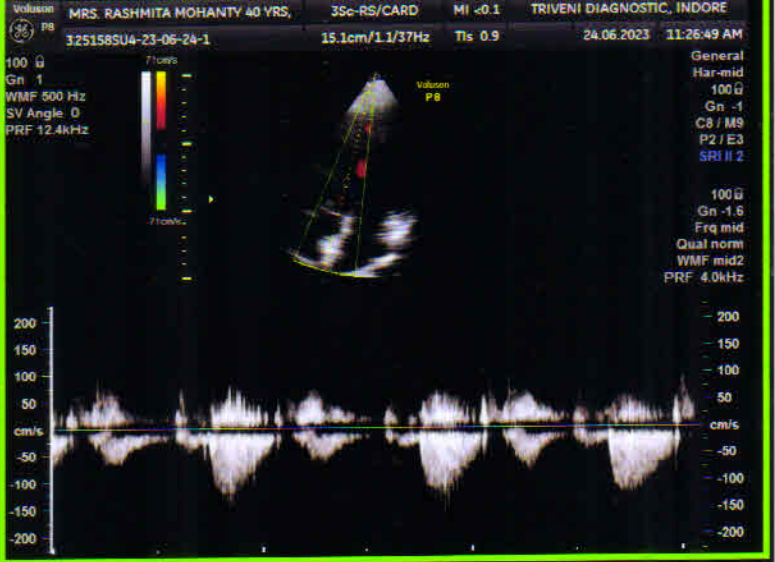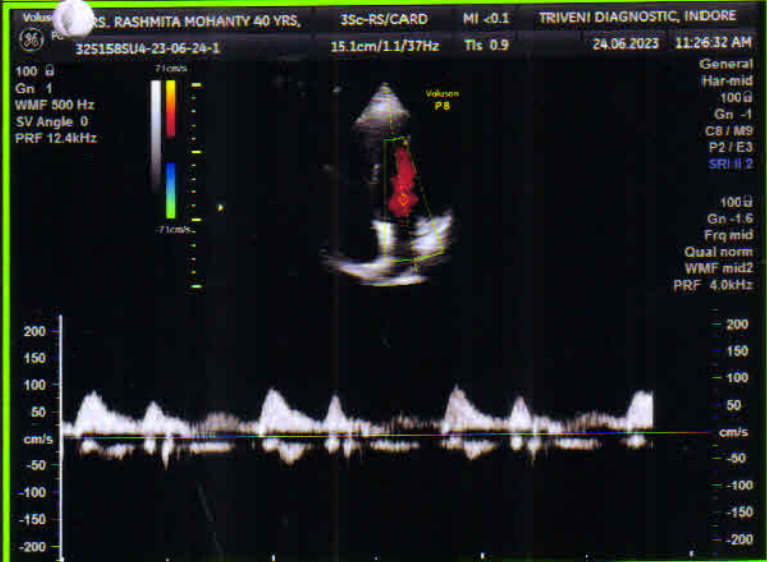
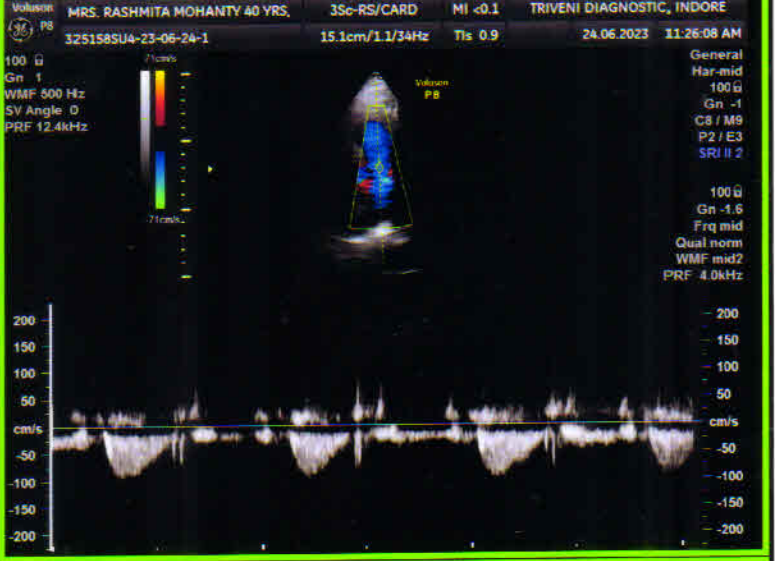
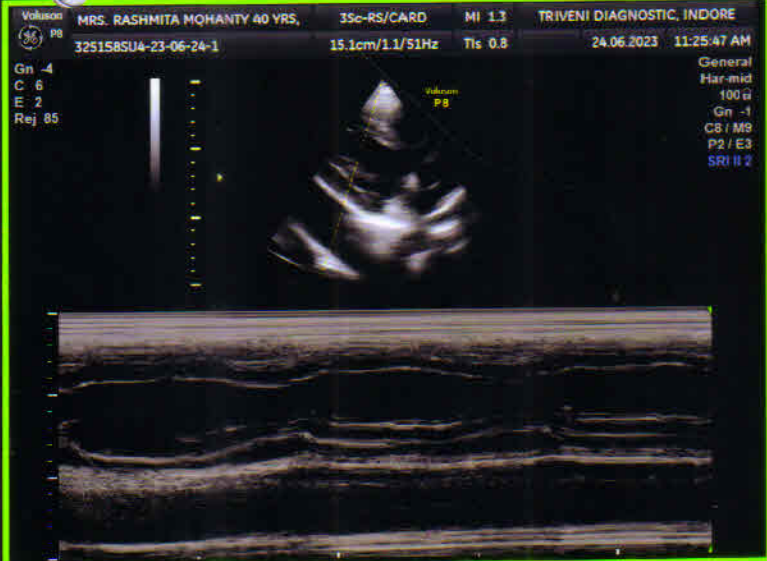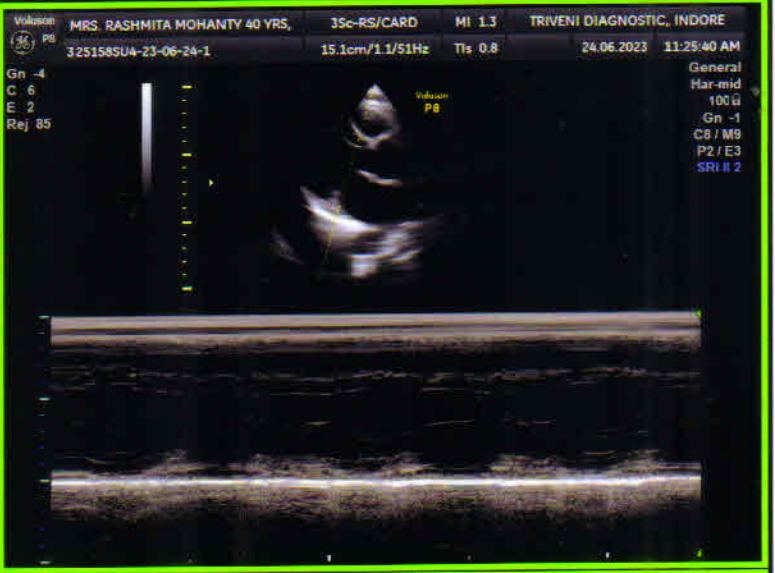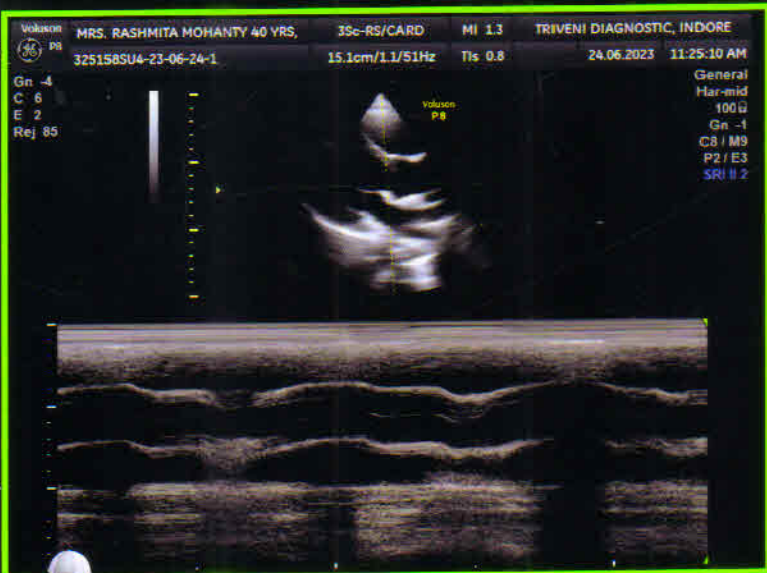
COLOR DOPPER

	PV(m/sec)	PG(mm of Hg)	Regurgitation
AV	1.2	5.8	NIL
MV	0.8	2.75	NIL
TV	N	N	NIL
PV	1.15	5.25	NIL

TRIVENI DIAGNOSTI & RESEARCH CENTER

2023

MRS. RASHMITA MOHANTY 40 YRS / F





Triveni Diagnostic Centre

Reg. No. : 73395 Visit ID : 0000077704
Patient Name : MRS. RASHMITA MOHANTY
Age / Sex : 40 YEARS / FEMALE Order Date : 24/06/23 11:49AM
Ref. By : Dr. ARCOFEMI HEALTHCARE LIMITED Report Date : 24/06/23 12:06PM

X-RAY X-RAY CHEST PA

Trachea is central.

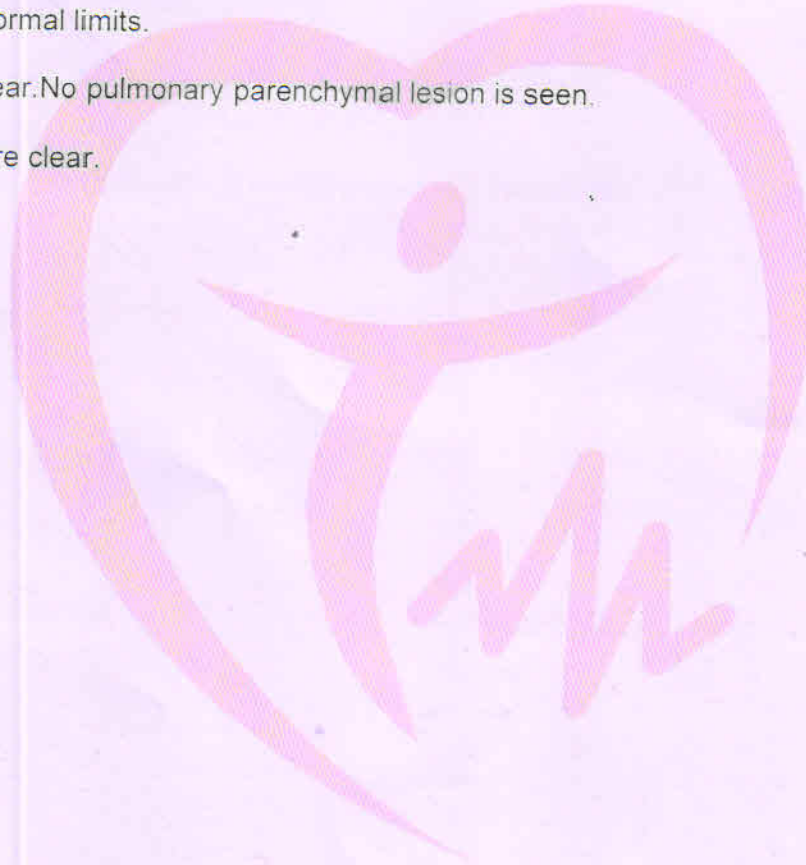
Bony rib cage and soft tissue wall of the thorax are normal.

Cardiac size is within normal limits.

Both lungs fields are clear.No pulmonary parenchymal lesion is seen.

Costo-phrenic angles are clear.

Kindly correlate.



DR. MUKESH DUBEY
(MBBS, DCP)

DR. VIJAY BHURIYA
MBBS DMRD

DR. AMIT SHANKHWAR
M.D. RADIO DIAGNOSIS

DR. P.S. TRIPATHI
M.D.(RADIO DIAGNOSIS)

DR. SANJAY YADAV
CONSULTANT MICROBIOLOGIST

Note: This report is not valid for medico legal purpose.

Page 1 of 1

Address : Agrawal Plaza, B-7, HIG Main Road, Indore Ph. : 0731-4289992-3
Website : www.trivenidiagnostic.com email : trivenidiagnostic@yahoo.co.in