


डॉ. बी. एम. शरणागत  
एम.डी. (मेडिसिन)

रजि.नं. - 4612  
कार्डियो - डायबेटोलॉजिस्ट  
एवं परामर्श चिकित्सक



रजि.क्र. - NHA/REG./BGT/2012/21

क्रिटिकल केयर युनिट I.C.C.U. सुविधायुक्त

आयुष्मान हॉस्पिटल  
एंड डायग्नोस्टिक रिसर्च सेंटर

सर्किट हाउस रोड, बालाघाट 07632-241070 समय-सुबह 10 बजे से संध्या 8.00 बजे तक

Name

R/O

Date 26/03/2022

General Physical Examination

Date of Examination 26/03/2022

Name Mrs. SHRISTY SONEKAR Age 30y. DOB 02/04/1991 Sex FEMALE

Referred by MEDIWHEEL

Photo Id AADHAR CARD ID

Ht 163 (CM)

Wt 45 (kg)

Chest (Expiration): 93 (cm)

Abdomen Circumference 80 (cm)

Blood Pressure 120/80 mm Hg

PR 17 /min

RR 24 /min

Temp 98.6° F BMI 19

Eye Examination

R Eye

L Eye

G/C

G/C

Other:

NO abnormal colouration.

On examination she appears physically and mentally fit: Yes/No

Signature of Examinee: Shristy

Name of Examinee: Mrs. Shristy

Signature Medical Examiner: B. M. Sharnagat

Name Medical Examiner: Dr. B. M. Sharnagat

Dr. B. M. SHARNAGAT  
M.D. (Medicine) Regd No 4612  
AYUSHMAN HOSPITAL  
& Diagnostic Research Center  
BALAGHAT (M.P.) 481001

|| उपलब्ध सुविधाएं ||

- क्रिटिकल केयर यूनिट/आई.सी.सी.यू., सेंट्रल ऑक्सीजन पाइप लाईन युक्त
- फेफड़ों के कार्य क्षमता की कम्प्यूटराईज्ड जाँच (P.F.T.)
- मल्टीपैरा, पल्स ऑक्स, डीफ्रिबीलेटर एवं वैंटीलेटर सुविधाएँ
- फिजियोथिरेपी युनिट एवं डायटिशियन परामर्श।
- कम्प्यूटराईज्ड ई.सी.जी., टी.एम.टी., होल्टर मॉनिटरिंग व अल्ट्रासोनो नेबुलाईजेशन
- डायबीटिज, अस्थमा एवं किडनी क्लिनिक।
- एक्सरे, पैथालॉजी, मेडिकल स्टोर्स व कैंटीन सुविधा
- मनोचिकित्सक, चर्मरोग, कैंसर एवं किडनी विशेषज्ञ द्वारा परामर्श - प्रति रविवार
- सेंट्रली एयर कूल्ड एवं ए.सी.युक्त प्राइवेट एवं जनरल वार्ड
- 24 घंटे इमरजेन्सी सेवा, एम्बुलेन्स एवं विद्युत जनरेटर व्यवस्था।




भारतीय विशिष्ट पहचान प्राधिकरण  
**भारत सरकार**  
 Unique Identification Authority of India  
 Government of India

नामांकन क्रम/ Enrolment No.: 2721/27206/27559

To  
 सुष्टि सोनेकर  
 Shristy Sonekar  
 C/O Akash Sonekar  
 Ward no 33  
 Moti Nagar  
 Near Kumar Furniture  
 Balaghat  
 Balaghat  
 Balaghat, Madhya Pradesh - 481001  
 9993821040

Download Date: 30/08/2013

Generation Date: 02/01/2013



आपका आधार क्रमांक / Your Aadhaar No. :

**9018 1244 6196**

VID : 9100 7030 6807 3448

**मेरा आधार, मेरी पहचान**



भारत सरकार  
 Government of India



सुष्टि सोनेकर  
 Shristy Sonekar  
 जन्म तिथि/DOB: 02/04/1991  
 महिला/ FEMALE

**9018 1244 6196**

VID : 9100 7030 6807 3448

**मेरा आधार, मेरी पहचान**



Government of India



सूचना

- आधार पहचान का प्रमाण है, नागरिकता का नहीं।
- पहचान का प्रमाण ऑनलाइन ऑथेंटिकेशन द्वारा प्राप्त करें।
- यह एक इलेक्ट्रॉनिक प्रक्रिया द्वारा बना हुआ पत्र है।

**INFORMATION**

- Aadhaar is a proof of identity, not of citizenship.
- To establish identity, authenticate online.
- This is electronically generated letter.


- आधार देश भर में मान्य है।
- आधार भविष्य में सरकारी और गैर-सरकारी सेवाओं का लाभ उठाने में उपयोगी होगा।
- Aadhaar is valid throughout the country.
- Aadhaar will be helpful in availing Government and Non-Government services in future.



भारतीय विशिष्ट पहचान प्राधिकरण  
 Unique Identification Authority of India

पता:  
 C/O आकाश सोनेकर, वार्ड नं 33, मोती नगर, कुमार  
 फर्निचर के पास, बलाघात, बलाघात,  
 मध्य प्रदेश - 481001

**Address:**  
 C/O Akash Sonekar, Ward no 33, Moti  
 Nagar, Near Kumar Furniture, Balaghat,  
 Balaghat,  
 Madhya Pradesh - 481001



**9018 1244 6196**

VID : 9100 7030 6807 3448

*Shristy*

*B.M.*

**Dr. B. M. SHARNAGAT**  
 M D (Medicine) Regd No 4612  
 AYUSHMAN HOSPITAL  
 & Diagnostic Research Ceter  
 BALAGHAT (M.P) 481001

NAME MR. MRS. SHRISTY SONEKAR

Age : 30/F

R / By DR. B. M. SHARNAGAT SIR

DATE : 26/ 03/ 2022


**X- RAY CHEST ( PA VIEW)**

- \*Bony cage – Normal.
- \*Trachea – Normal.
- \* Heart – Position --- Normal.  
C-T ratio---Within normal limits.  
Cardiac borders--- Normal.  
Specific chamber enlargement---None.
- \*Aorta- Position---Normal.
- \*Mediastinum- Relative Position ---Normal.  
Any Lesion---None.
- \*Angles- Cardiophrenic angles---Clear.  
Costophrenic angles---Clear.
- \*Pleura- Normal.
- \*Lungs- .Lung apices seen clear.  
.Both lungs seen clear.  
.No evidence of any focal active lesion in lung fields.  
.Broncho-vascular markings appear normal.
- \*Hilar shadows- Normal.
- \*Diaphragms- Relative position---Normal.  
Outline---Normal.


**OPINION**

"X-RAY CHEST APPEARS NORMAL."  
"NO ABNORMALITY DETECTED."

Thanks for referral.

  
Dr. B. M. SHARNAGAT  
M D (Medicine) Regd.No 4812  
AYUSHMAN HOSPITAL  
& Diagnostic Research Ceter  
BALAGHAT (M.P) 481001





# आयुष्मान हॉस्पिटल

एण्ड डायग्नोस्टिक रिसर्च सेन्टर

सर्किट हाऊस रोड, बालाघाट ☎ 07632:241070

## PATHOLOGY REPORT

• Auto Analyzer • Hematology Analyzer • A.B.G. • Computerised Lab

**NAME :** MRS. SHRISTY SONEKAR **AGE :** 30Yrs. **SEX :** F

**REF. BY :** Dr. B. M. SHARNAGAT (M.D.) **DATE :** 26/03/2022

### BIOCHEMISTRY

TESTS	RESULTS	UNITS	REF. RANGE
<b><u>LIPID PROFILE</u></b>			
S. Cholesterol	:146	mg/dl	UP TO <200
S. Triglycerides	:110	mg/dl	UP TO <150
HDL Cholesterol	:34	mg/dl	32 -60
LDL Cholesterol	:86	mg/dl	UP TO <100
VLDL Cholesterol	:21	mg/dl	7 - 35
LDL / HDL Ratio	:3.6	%	2.5 - 5.0
S. Cholesterol / HDL Ratio	:4.3	%	3.5 - 5.0
<b><u>KFT</u></b>			
Serum CREATININE	:0.91	mg/dl	0.8-1.2
BUN	:14	mg/dl	8-20
BUN Creatinine Ratio	:14.9		
<b><u>LFT</u></b>			
Bilirubin-Total	:0.6	mg%	0-1.2
Direct	:0.4	mg%	0-0.6
Indirect	:0.2	mg%	0-0.5
SGPT(ALT)	:14	IU/L	7-35
SGOT(AST)	:15	IU/L	8-40
Alk.Phosphatase	:75	U/L	86-306 Adult
<b>TOTAL PROTEINS</b>	6.5	gm/dl	6.2-8.2
Albumin	4.0	g/dl	3.5-5.5
Globulin	2.5	g/dl	2.5-3.2
A/G Ratio	2.0		1.5-2.5
GGT	20	U/L	9-48
<b>S.URIC ACID</b>	4.4	mg/dl	3.4- 7.2

Dr. B. M. SHARNAGAT  
I/C Pathologist/Technician  
(Ayushman Hospital - Balaghat)  
& Diagnostic Research Center  
BALAGHAT (M.P.) 481001

- This Report is not valid for MLC purpose.
- This Report is only for Physician's help to confirm the diagnosis.

क्रिटिकल केयर युनिट I.C.C.U. सुविधायुक्त

REGD.No. : NHA/REG/BGT/2012/21

**आयुष्मान हॉस्पिटल**

एण्ड डायग्नोस्टिक रिसर्च सेंटर

सर्कट हाऊस रोड, बालाघाट ☎ 07632:241070

## PATHOLOGY REPORT

• Auto Analyzer • Hematology Analyzer • A.B.G. • Computerised Lab

**NAME :** MRS. SHRISTY SONEKAR **AGE :** 30Yrs. **SEX :** F  
**REF. BY :** Dr. B. M. SHARNAGAT (M.D.) **DATE :** 26/03/2022

### URINE ANALYSIS REPORT (By urometer120 analyzer)

#### PHYSICAL EXAMINATION


Colour : pale Yellow  
Quantity : 10ml  
Apperance : clear

#### CHEMICAL EXAMINATION

Sugar : nil  
Bile Pigment : nil  
Nitrite : nil  
Protein : nil  
Bilirubin : nil  
Ketone : nil  
Albumin : nil  
Urobilinogen : Normal 0.01 mg/ml  
Specific gravity : 1.015 1.010-1.030  
Reaction(pH) : 6.5 (Acidic3-6, Alkaline8-10)

#### MICROSOPIC EXAMINATION

Pus(WBCs) Cells : NIL/ hpf  
RBC : nil/hpf  
Crystals : Absent  
Spermatozoa : Absent  
Epithelial Cells : Absent  
Bactria : Absent

  
**Dr. B.M. SHARNAGAT**  
M.D. (Pathology) Regd. No. 4612  
AYUSHMAN HOSPITAL  
(Ayushman Hospital Balaghat)  
& Diagnostic Research Center  
BALAGHAT (M.P.) 481001

- This Report is not valid for MLC purpose.
- This Report is only for Physician's help to confirm the diagnosis.



**आयुष्मान हॉस्पिटल**

एण्ड डॉयग्नोस्टिक रिसर्च सेन्टर

सर्किट हाऊस रोड, बालाघाट ☎ 07632:241070

**PATHOLOGY REPORT**

• Auto Analyzer • Hematology Analyzer • A.B.G. • Computerised Lab

NAME : MRS. SHRISTY SONEKAR

AGE : 30Yrs.

SEX : F

REF. BY : Dr. B. M. SHARNAGAT (M.D.)

DATE : 26/03/2022

BIOCHEMISTRY

TESTS	RESULTS	UNITS	REF. RANGE
-------	---------	-------	------------

BLOOD SUGAR

B.SUGAR (f)	:86	mg/ dl	60-100
(p.p)	:125	mg/dl	120-160

METHOD : GOD-POD

HbA1C

5.2 %

Nondiabetic :4.5 -6.2

Good Control:6.0 -7.0%

Fair Control: 7.0 -8%

Poor Control: >8%

(Action Suggested)

Blood group

O

Rh Type

Positive

ESR

:10 1st Hr 0-20

Method

westerangreen

STOOL EXAMINATION

Stool for Routine & Microscopic Examination : Normal

Stool for Occult blood : Negative

THYROID HORMONE

TSH	4.2	uIU/ml	0.3 - 5.0
T3	0.71	ng/ml	0.6-1.8
T4	5.2	ug/dl	5.0-12.5

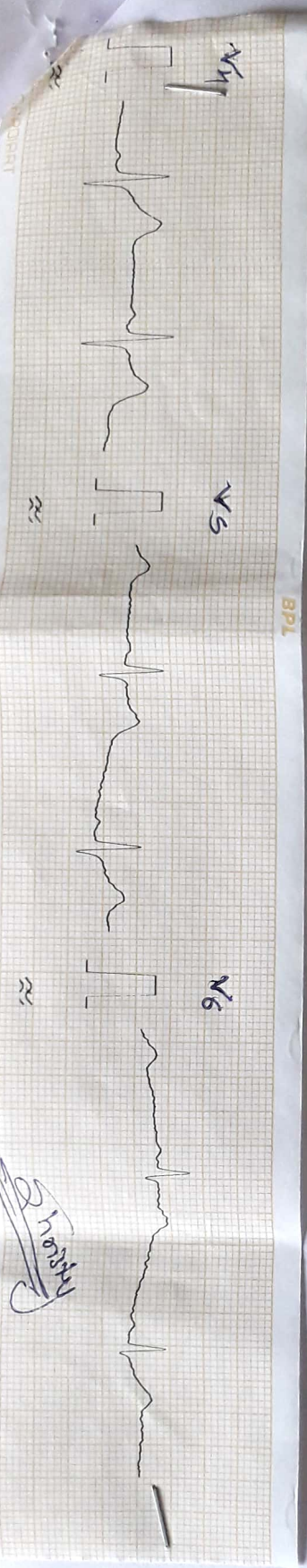
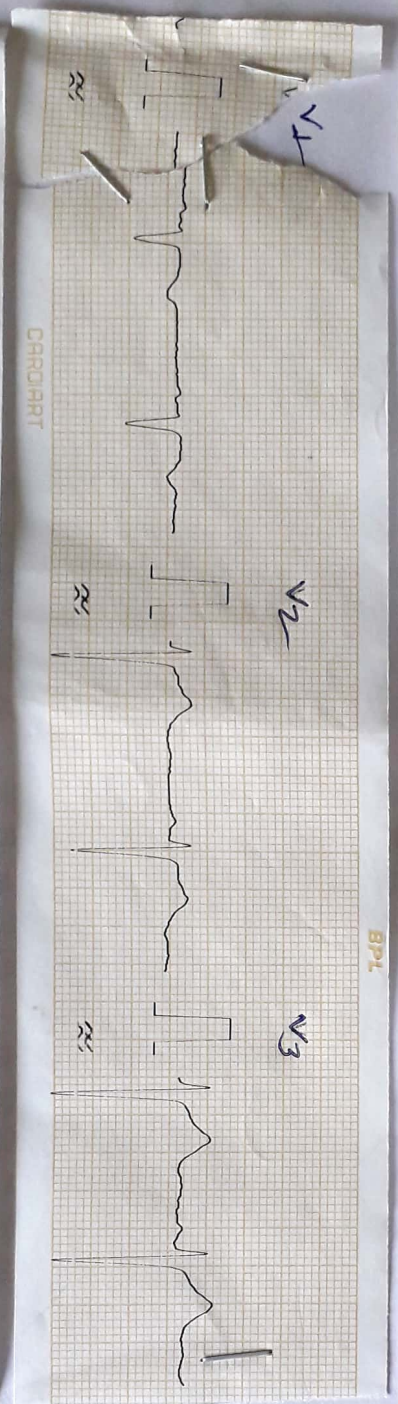
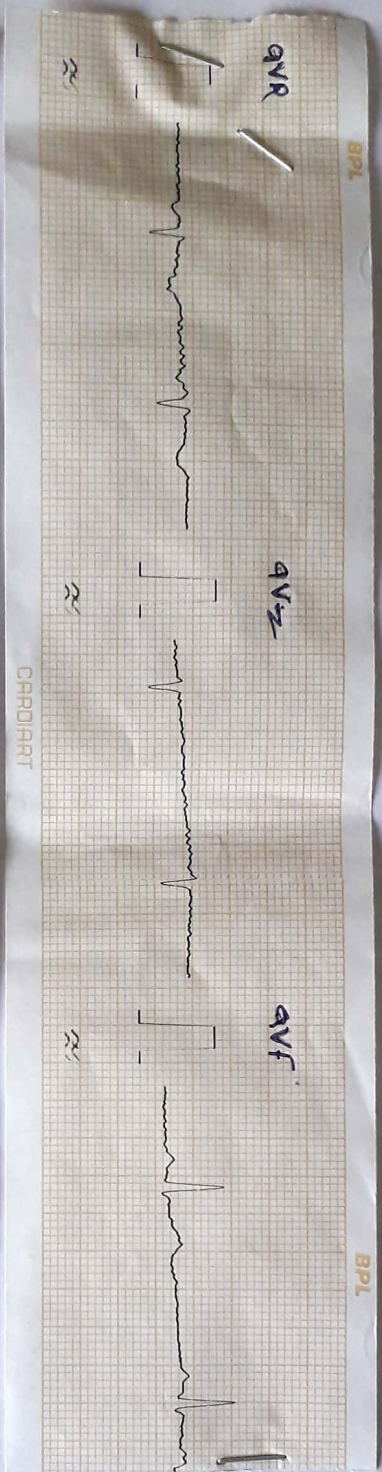
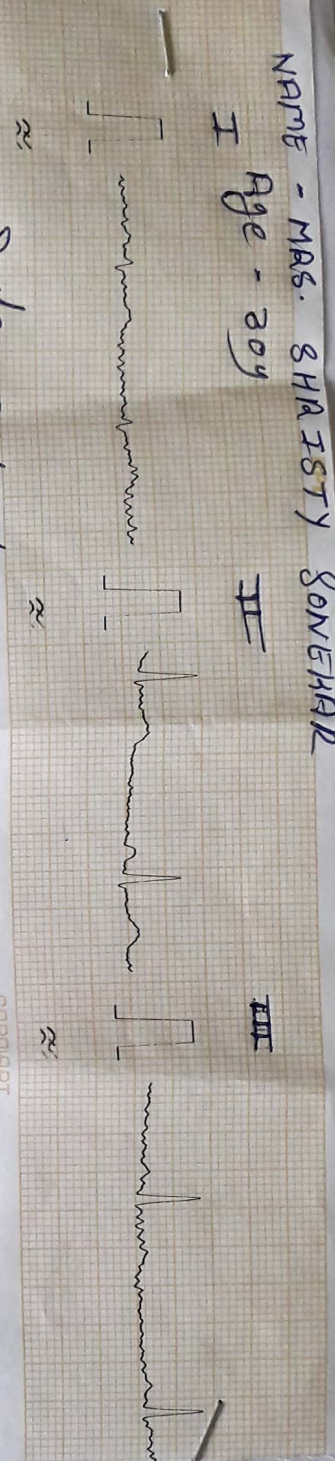
REPOT ON SEROLOGY

V.D.R.L : NON-REACTIVE

Dr. B. M. SHARNAGAT  
M.D. Pathologist/Technician  
(Ayushman Hospital, Balaghat)  
& Diagnostic Research Center  
BALAGHAT (M.P.) 481001

NAME - MAS. SHARISTY SONENHAR  
Age - 20y

Date - 26/03/2022



Repor: Normal

Dr. B. M. SHARNAGAT  
M.D. (Med) Regd. No. 4612  
AYUSH HOSPITAL  
& Diagnostic Research Center  
BALAGHAT, 481001



**CRITICAL CARE UNIT I.C.C.U.**  
**AYUSHMAN HOSPITAL**  
 AND DIAGNOSTIC RESEARCH CENTER

**2D ECHOCARDIOGRAPHY & DOPPLER REPORT**

NAME - MRS SRISHTI SONEKAR

AGE - 30 YRS/F

REFD. BY - MEDIWHEEL

DATE - 26/03/2022

**M-Mode & Essential Measurements-**

Pulse : 78 Bpm	LVID(D) : 43 mm	MV Annulus : 25 mm	RVID(d) : 34 mm
Aortic Root : 25 mm	LVID(S) : 24 mm	TV Annulus : 23 mm	IVC : 14 mm
MPA : 21 mm	IVSd (D) : 09 mm	AO Annulus : 17 mm	Mitral-Epss : 08 mm
LVEF : 60%	LVPWd(D) : 08 mm	PV Annulus : 19 mm	TAPSE : 16 mm

**2D Echo Findings-**

SITUS : Solitus  
 LOOP : Levocardia (L - LOOP)  
 AV/ VA CONNECTION : Concordant  
 I/C SHUNT : NIL  
 PV DRAINAGE : Normal (NPVD)  
 I/C CLOT & VEGETATION : Nil  
 GREAT VESSEL RELATIONSHIP : Normal (NRGA)  
 AOV : Trileaflet Valve  
 AORTIC ARCH : Left Ao Arch Without Interruption  
 CORONARY ARTERY ORIGIN : Normal

**Doppler Study-**

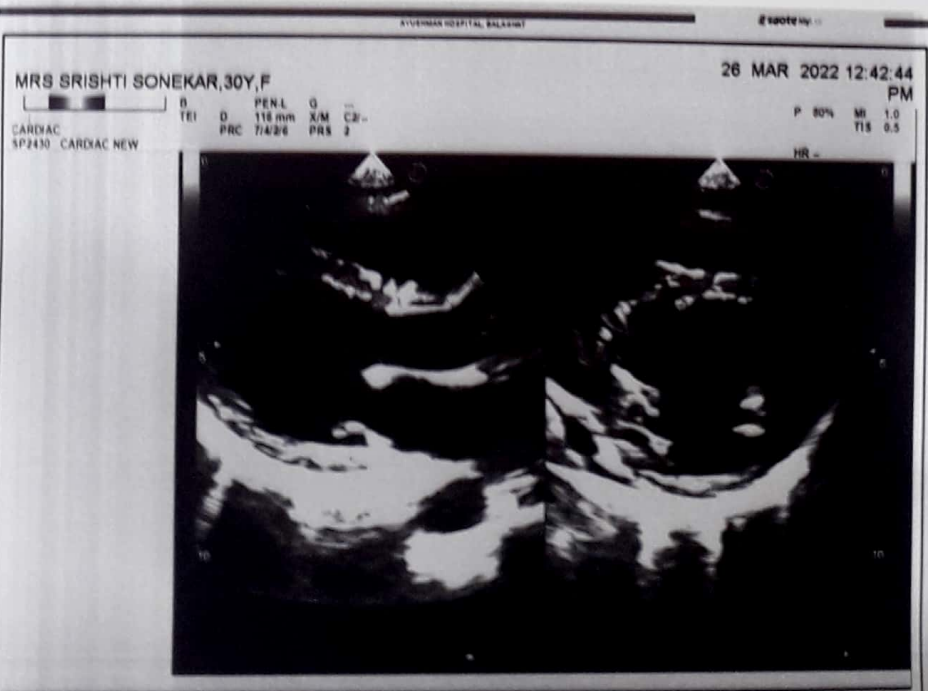
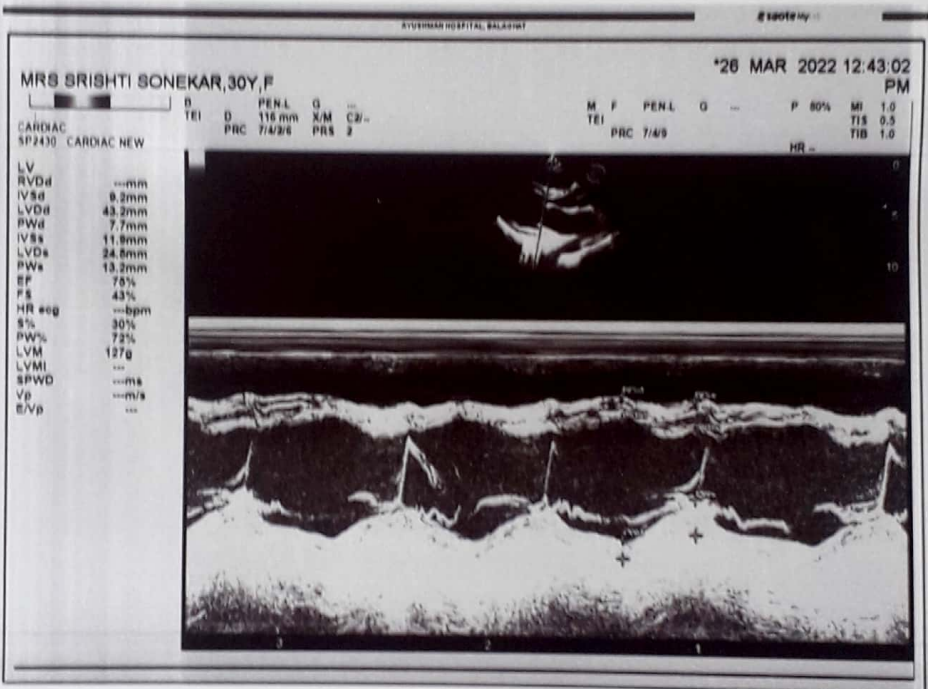
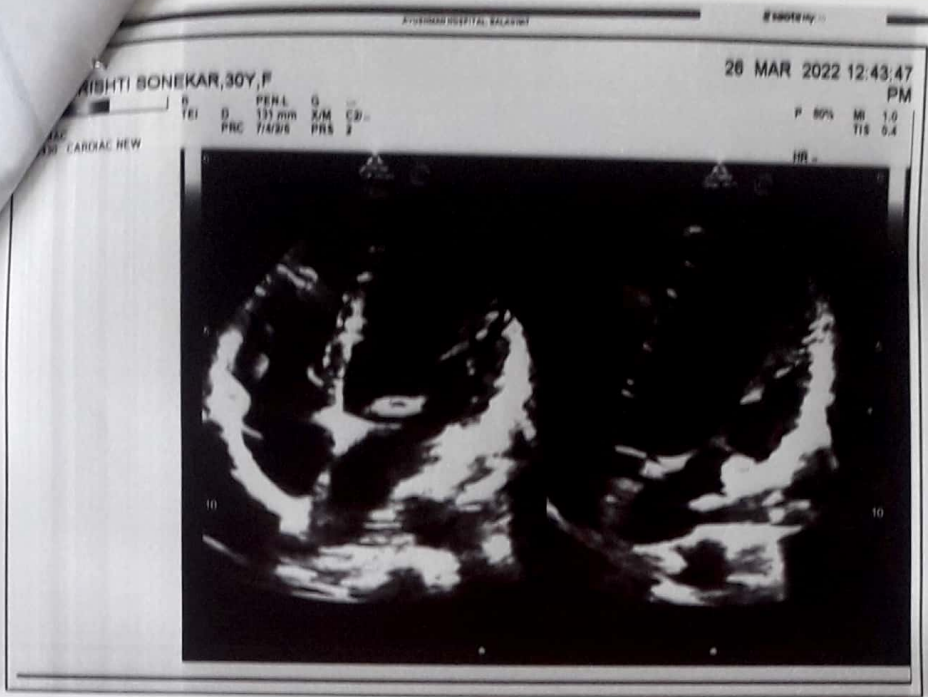Valves	Peak Gradient (mm of Hg)	Mean Gradient (mm of Hg)	Valve area (Normal Range)	Grade of Regurgitation
Mitral Valve	--	--	4.0-6.0	NIL
Aortic Valve	--	--	2.5-4.0	NIL
Tricuspid Valve	--	--	7.0-9.0	NIL
Pulmonary Valve	--	--	2.0-3.0	NIL


Estimated PASP by TR jet = 25 mmHg.

**FINAL IMPRESSION :- NORMAL 2D ECHO & DOPPLER STUDY.**

*Shristy*

*[Signature]*  
**Dr. B.M. Sharnagat (MD Medicine)**  
 M.D. (Medicine) Regd No. 4612  
 AYUSHMAN HOSPITAL  
 & Diagnostic Research Center  
 BALAGHAT (M.P.) 481001





**ULTRASOUND REPORT**

NAME - MRS SRISHTI SONEKAR

AGE - 30 Yrs/F

REFD. BY - MEDIWHEEL

DATE - 26.03.2022

**LIVER** : The liver is normal in size and shape. It shows normal parenchymal echo texture. The IHBR, IHPR and porta hepatis appear normal.

There is no e/o any lesion.

**GALLBLADDER** : Normal. There is no e/o evidence of calculi.

**PANCREAS** : Normal in size and shows normal echo texture.

**SPLEEN** : Spleen is normal in size and shows homogenous echo texture.

**KIDNEYS** : Both Kidneys are normal in size, shape, contour and in position.

There is no renal calculi and no pelvicalyceal dilatation.

LEFT KIDNEY MEASURES : 7.4 X 5.6 CM

RIGHT KIDNEY MEASURES : 7.1 X 5.4 CM

**URINARY BLADDER** : Bladder is normal in shape . There is no intravesical calculi. There is no evidence of any residual urine.

**OVARIES & UTERUS** : Both ovaries & uterus are normal in size , contour & echogenicity.

There is no e/o free fluid in pelvis.

**IMPRESSION** :- NORMAL STUDY OF ABDOMEN.

*Srishti*

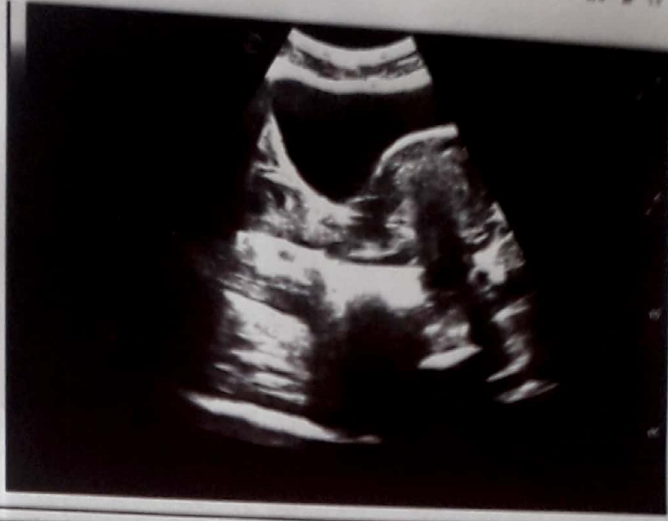*[Signature]*  
Dr. B. M. SHARNAGAT  
M.D. (Medicine) Regd No 4612  
AYUSHMAN HOSPITAL  
& Diagnostic Research Center  
BALAGHAT (M.P.) 481001

MRS SRISHTI SONEKAR, 3Y, F

ABDOMINAL  
AC2541 ABD

TEI 0 RES L 0  
160 mm X/M CV-  
PRC 8/0/24 PRS 3

26 MAR 2022 01:07:24  
PM

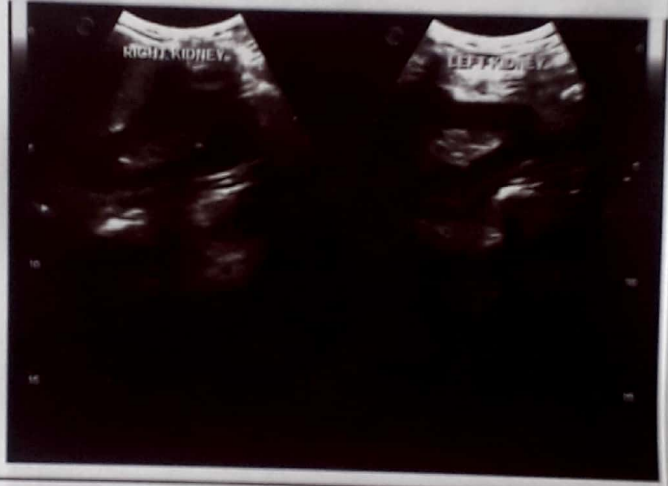

MRS SRISHTI SONEKAR, 3Y, F

ABDOMINAL  
AC2541 ABD

TEI 0 RES L 0  
160 mm X/M CV-  
PRC 8/0/24 PRS 3

26 MAR 2022 01:07:08  
PM



MRS SRISHTI SONEKAR, 3Y, F

ABDOMINAL  
AC2541 ABD

TEI 0 RES L 0  
160 mm X/M CV-  
PRC 8/0/24 PRS 3

26 MAR 2022 01:08:28  
PM



