



भारत सरकार




भारतीय विशिष्ट अंकित मापन प्रणाली  
भारत सरकार  
Unique Identification Authority of India  
Government of India


नोंटिफिकाचा क्रमांक / Enrollment No 120775278/02172

To,  
कविता अशिष व्यास  
Kavita Ash sh Vyas  
W/O Ashish Vyas  
B. 205, Ramesh apartment,  
Narsing lane,  
Opp. N. J. High School, Malad West,  
Mumbai  
Malad West Dey, Mumbai  
Maharashtra 400064  
9819703382

Ref: 120775 - 231 / 326015 / 32F170 - P



SH328748610FT



आपला आधार क्रमांक / Your Aadhaar No. :

**6788 2447 5714**


आधार - सामान्य माणसाचा अधिकार



भारत सरकार  
Government of India



कविता अशिष व्यास  
Kavita Ashish Vyas  
जन्म वर्ष / Year of birth: 1975  
स्त्री / Female



**6788 2447 5714**

आधार - सामान्य माणसाचा अधिकार

*Kavita Vyas*

SUBURBAN DIAGNOSTICS (INDIA) PVT. LTD.  
102-104, Bhoomi Castle,  
Opp. Goregaon Sports Club,  
Link Road, Malad (W), Mumbai - 400 064.

Authenticity Check



Use a QR Code Scanner  
Application To Scan the Code

**CID** : 2200870440  
**Name** : Mrs Kavita Vyas  
**Age / Sex** : 46 Years/Female  
**Ref. Dr** :  
**Reg. Location** : Malad West Main Centre

**Reg. Date** : 08-Jan-2022 / 09:29  
**Reported** : 08-Jan-2022 / 13:44

R  
E  
P  
O  
R  
T

**X-RAY CHEST PA VIEW**

Both lung fields are clear.  
Both costo-phrenic angles are clear.  
The cardiac size and shape are within normal limits.  
The domes of diaphragm are normal in position and outlines.  
The skeleton under review appears normal.

**IMPRESSION:**  
**NO SIGNIFICANT ABNORMALITY IS DETECTED.**

**TO BE CORRELATED CLINICALLY.**

Note: Investigations have their limitations. Solitary radiological investigations never confirm the final diagnosis. They only help in diagnosing the disease in correlation to clinical symptoms and other related tests. X-ray is known to have inter-observer variations. Further / Follow-up imaging may be needed in some case for confirmation of findings Please interpret accordingly.


-----End of Report-----

Dr. Akash Chhari  
MBBS, MD, Radio-Diagnosis Mumbai  
MBC REG NO - 2011/08/2362

Click here to view images [http://202.143.96.162/Suburban/Viewer?ViewerType=3&AccessionNo=20220108090\\_1538](http://202.143.96.162/Suburban/Viewer?ViewerType=3&AccessionNo=20220108090_1538)



Authenticity Check



Use a QR Code Scanner  
Application To Scan the Code

**CID** : 2200870440  
**Name** : Mrs Kavita vyas  
**Age / Sex** : 46 Years/Female  
**Ref. Dr** :  
**Reg. Location** : Malad West Main Centre

**Reg. Date** : 08-Jan-2022 / 09:38  
**Reported** : 08-Jan-2022 / 09:48

**IMPRESSION:-**

Fatty infiltration of liver.

Focal hypoechoic lesion of liver as described above, likely to be fat spared area.

**Suggestion :- Clinicopathological correlation.**

Note : Investigations have their limitations. Solitary radiological investigation never confirm the final diagnosis. They only help in diagnosing the disease in correlation to clinical symptoms and other related tests. USG is known to have inter-observer variations. Further / Follow-up imaging may be needed in some case for confirmation of findings. Patient has been explained in detail about the USG findings including its limitations and need for further imaging if clinically indicated. Please interpret accordingly. All the possible precaution have been taken under covid-19 pandemic.

-----End of Report-----

**Dr. Vivek Singh**  
**MD Radiodiagnosis**  
**Reg No: 2013/03/0388**

Click here to view images <http://202.143.96.162/Suburban/Viewer?ViewerType=3&AccessionNo=2022010800141634>

NAME: - *Mr. Anil D. Patil*

AGE / SEX: - *45 / M*

REGN NO: - *2000000000000*

REF DR: - *-*

**GYANECOLOGICAL EXAMINATION REPORT**

**OBSERVED VALUE**

**TEST DONE**

CHIEF COMPLAINTS :-

*nil*

MARITAL STATUS :-

*married*

MENSTRUAL HISTORY :-

- MENARCHE :-
- PRESENT MENSTRUAL HISTORY :- *Irregularity 1yr ago*
- PAST MENSTRUAL HISTORY :-
- OBSTERIC HISTORY: - *P<sub>2</sub> L<sub>2</sub> Ho*
- PAST HISTORY: - *Covid ad Dengue*
- PREVIOUS SURGERIES: - *Hysterectomy 1yr ago*
- ALLERGIES: - *nil*
- FAMILY HISTORY: - *Father - DM  
Mother - DM*

Brief Disease... Suburban...  
© 2020 Suburban Diagnostics. All rights reserved.

- DRUG HISTORY :- *nil*
- BOWEL HABITS :- *1/0*
- BLADDER HABITS :- *1/0*

### PERSONAL HISTORY :-

TEMPERATURE :- *Afebrile*

RS :-

CVS :- *1/0*

PULSE / MIN :- *78/min*

BP (mm of hg) :- *140/90*

BREAST EXAMINATION :- *---*

PER ABDOMEN :- *(0)*

PRE VAGINAL :- *---*

RECOMMENDATION :-

DR. SONALI HONRAO  
MD (G.MED.)  
CONSULTING PHYSICIAN  
REG. NO. 2001704/1882

*[Signature]*

SUBURBAN DIAGNOSTICS PVT. LTD  
102-103, Eastern Gate,  
Opp. Goregaon Sports Club,  
Link Road, Malad (W), Mumbai - 400 064.

ADDRESS: 2<sup>nd</sup> Floor, Aston, Sundervan Complex, Above Mercedes Showroom, Andheri West - 400053

HEALTHLINE - MUMBAI: 022-6170-0000 | OTHER CITIES: 1800-266-4343

For Feedback - customerservice@suburbandiagnosics.com | www.suburbandiagnosics.com

Date:- 08/01/2022

CID: 020 8510440

Name:- Kavitha Vyas

Sex / Age: F / 45yrs

**EYE CHECK UP**

Chief complaints: Nil

Systemic Diseases: Nil

Past history: Nil

Unaided Vision: —

Aided Vision: RE: S/G, BE: N/G

Refraction: —

	(Right Eye)				(Left Eye)			
	Sph	Cyl	Axis	Vn	Sph	Cyl	Axis	Vn
Distance								
Near								

Colour Vision: Normal / Abnormal

Remark:

SUBURBAN DIAGNOSTICS (INDIA) PVT. LTD.  
 102-103, Borewell Building  
 Opp. Goregaon Sports Club,  
 Link Road, Malad (W), Mumbai - 400 064.

ADDRESS: 2<sup>nd</sup> Floor, Aston, Sundervan Complex, Above Mercedes Showroom, Andheri West - 400053

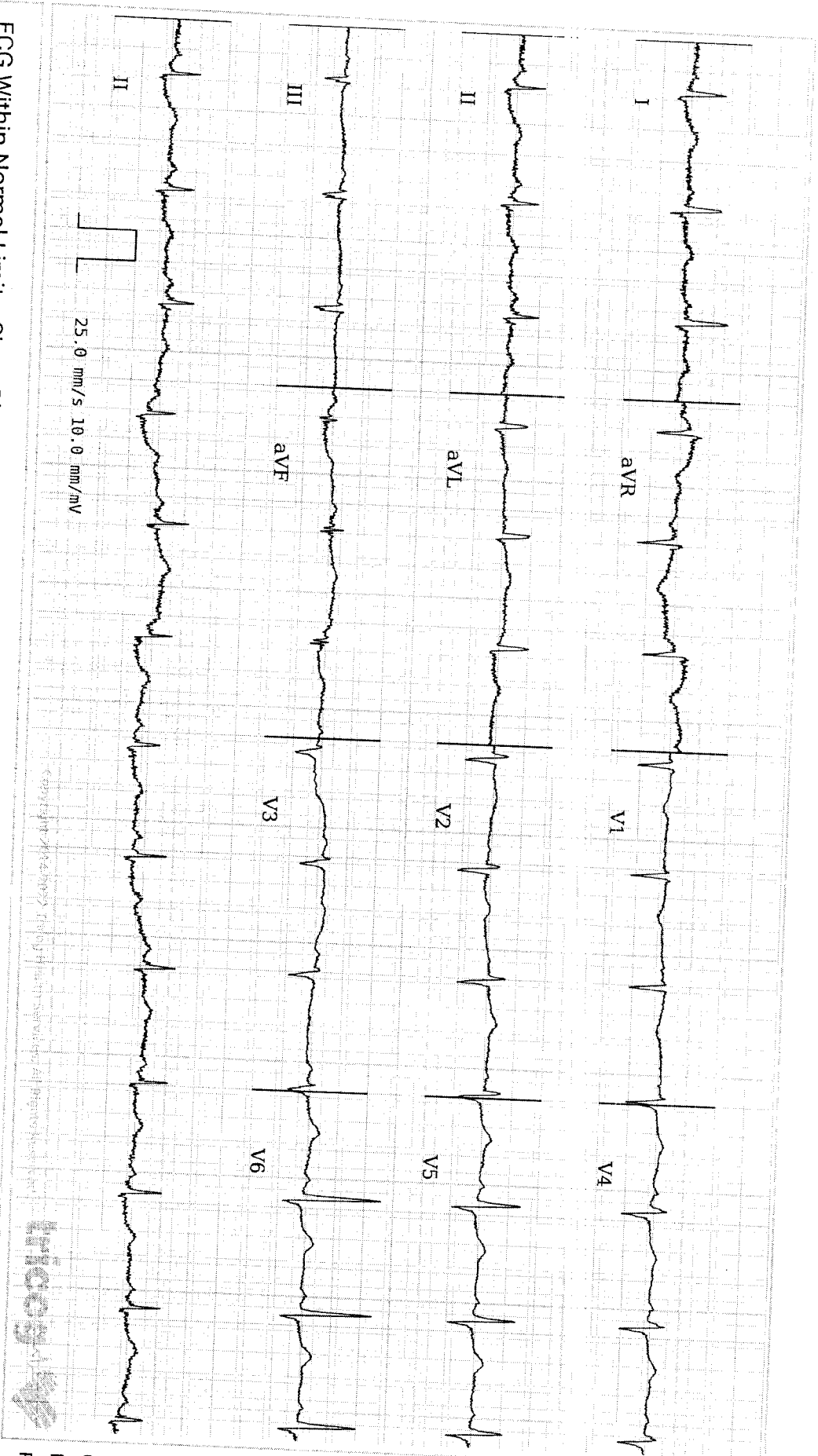
HEALTHLINE - MUMBAI: 022-6170-0000 | OTHER CITIES: 1800-266-4343

For Feedback - customerservice@suburbandiagnostics.com | www.suburbandiagnostics.com

Patient Name: **KAVITA VYAS**

Patient ID: **2200870440**

Date and Time: **8th Jan 22 9:32 AM**



**ECG Within Normal Limits: Sinus Rhythm, Normal Axis. Baseline wandering. Please correlate clinically.**

Age **46** **6** **4**  
years months days

Gender **Female**

Heart Rate **79 bpm**

**Patient vitals**

BP: **140/90 mmHg**

Weight: **69 kg**

Height: **158 cm**

Pulse: **78 bpm**

Spo2: **NA**

Resp: **NA**

Others:

**Measurements**

OSRD: **82 ms**

QT: **424 ms**

QTc: **486 ms**

PR: **132 ms**

P-R-T: **48° 6' 4"**

REPORTED BY

*[Signature]*

**DR SONALI HONRAO**  
MD (General Medicine)  
Physician

2001/04/1882

Disclaimer: 1) Analyses in this report is based on ECG alone and should be used as an adjunct to clinical history, symptoms, and results of other invasive and non-invasive tests and must be interpreted by a qualified physician. 2) Patient vitals are as entered by the clinician and not derived from the ECG.