



# PARKLINE DIAGNOSTICS PVT. LTD.

L.G. 3, 4 & 5, Bhuvana Towers, S.D. Road, Secunderabad - 500 003.

Tel : +91 40-2784 5852, 6649 1787, 7995421787, 7093445852, Fax : +91 40 2784 7864

Email parklinediagnostics@gmail.com www.parklinediagnostics.com



NABL Accredited  
Certificate No.MC-2566

## MEDICAL EXAMINATION REPORT

Name	MS. Meera sharma		Date :	12/01/2022	
Company	CID, Mediwheel		Reg. No. :	1668721	
Contact No.	9966903020		Sex	<input checked="" type="checkbox"/> F	Age : <input type="checkbox"/> 42
Type	Pre-Emp		Emp. No.:	Spouse	
	Overseas		Height	158 cm	
	Annual	<input checked="" type="checkbox"/>	Weight	90 kgs.	
Remarks	<p><u>USG</u> : ① Angiomyolipoma of           Ⓡ kidney. Follow up c Urologist.</p> <p>② fibroid uterus Follow up c Gynaecologist.</p> <p>- Per all parameters within Ⓡ limits.</p>				
			DR. PRIYANKA SANNIDHI	MBBS	
				Regn. No : 11351	
Fitness Status	Medically Fit / Unfit		Physician's Signature		

# COMPREHENSIVE MEDICAL EXAMINATION REPORT

NAME Ms. Meera Sharma  
 AGE 42 yrs / Female  
 MARITAL STATUS Married CHILDREN : M  1  F  1  
 IDENTIFICATION (IF ANY) A mole on the (LH) Hand.

## PAST HISTORY

Any family H/o : High Blood Pressure, Heart Disease, Tuberculosis, Diabetes, Asthma, Cancer

Any personal H/o Major illness like : Typhoid.....NIL.....Jaundice.....NIL.....Etc.

Any H/o STD.....NIL.....Skin infection.....NIL

H/o Blood Transfusion.....NIL.....Recent Vaccination.....COVAXIN 2 Doses ✓

H/o Epilepsy.....NIL.....Giddiness.....NIL

H/o Surgery.....NIL.....Fracture in the past.....NIL

### Any Personal H/O.

High Blood Pressure, Heart Disease Tuberculosis, Diabetes, Asthma, Cancer

Drug Abuse, Drug Allergy, Micturition, Bowels, Alcohol, Smoking, Sleep, MC, Wt. Loss/Wt. Gain

Present illness / Medication On/OFF T. EPTION . Stopped for epilepsy.

## GENERAL EXAMINATION

Conjunctiva :

Skin :

Ears :

Nose :

Throat & Oral Cavity :

}

NPD

Bone, Joints :

(N)

Nutritional Status :

well nourished

Lymph Nodes :

NPD

Edema Feet :

NIL

Varicose Veins :

NIL



**Distant Vision : Near Vision :**

Right Eye: 6/6

With glasses / Without glasses

left Eye : 6/6

with glasses / without glasses

Colour Vision : DE normal

**Right Ear**

Hearing :

Rinee's Test ;

Weber Test :

Discharge :

(N)

NIL

Right Eye: N8 +1.25 sph N6

With glasses / Without glasses

left Eye : N8 +1.25 sph N6

with glasses / without glasses

Ophthalmologist's Signature

Dr. KATTA  
M.B.B.S., D.O., F.R.C.  
1996 (R.M.O.)

**Left Ear**

(N)

NIL

**SYSTEMIC EXAMINATION**

Pulse : 80 bpm

B.P. : 120/80 mmHg

Lungs : A. Shape of Chest DE symmetrical  
B. Breath Sounds R/L - clear ⊕  
C. Adventitious Sounds No

Heart : A. Sounds S<sub>1</sub> S<sub>2</sub> ⊕  
B. Murmurs No murmurs

Abdomen : A. Liver NP  
B. Spleen NP  
C. Piles NO  
D. Any Lump NO

General : A. Hernia ] NAD  
B. Hydrocele ]  
C. Varicocele ]

Breast : Rt (N) Lt. (N)

**Nervous System**

A. Higher Function :  
B. Cranean Nerves :  
C. Sensory System :  
D. Motor System :  
E. Jerks :  
] (N)

# CANDIDATE'S DECLARATION

I hereby solemnly declare that I am not suffering from Asthma, Hypertension, Diabetes, Occult Psychological disorders or any other ailment which can be suppressed without my voluntary declaration.

Date :

Miss Sharma  
Signature

Place :

Note : General Physical Examination and Investigation included in the health check-up Have certain limitations and may not be able to detect all latent and asymptomatic diseases. Any new symptoms developing after the health check-up or persisting thereafter should be brought to the attention of the treating physician.




Name : Meeru Sharma ..... Sex : F ..... Age : 42 .....

Date : 12/1/22 .....

OPD No : 380 .....

*check up done*

  
MULTI SPECIALITY DENTAL CLINIC  
*Smile Confidentially... Not Confidentially...*  
B.D.S, IMPLANTOLOGIST (USA)  
1-3-1, Rajamudaliar Street, Kalasiguda,  
Secunderabad, Cell : 8977910590,






# PARKLINE DIAGNOSTICS PVT. LTD.



NABL Accredited  
Certificate No. MC-2566

Meena Sharma.

42yrs

12-1-22

P2L2  
BWH (FM)

LMP: 25-12-2021 / 21C-20yr

Hypo - 25mcg

- periods regular.

- 3-4 days (N) flow

- Bowel - occ - constipation

- urine (N) + Regular

shelcut 1SD.  
- 0- constipation.

P/A - obesity + NAD

Breast - NAD

Condi: calcium + Vit-D,  
Balanced healthy Diet

Exercise -

Dr. Jamuna Devi G.  
MBBS, DGO, FICOG  
Regd. No. 9202  
Obstetrician & Gynecologist





# PARKLINE DIAGNOSTICS PVT. LTD.

L.G. 3, 4 & 5, Bhuvana Towers, Sarojini Devi Road, Secunderabad - 500 003 Tel. +91 40-2784 5852  
6649 1787 Fax : +91 40 2784 7864 Email : parklinediagnostics@gmail.com www.parklinediagnostics.com



NABL Accredited  
Certificate No. MC-2566

## TEST REPORT

Name : Ms . MEERA SHARMA [SPOUSE]  
Age / Gender : 42 Years / Female  
Ref.By : Medi Wheel  
Req. No : BIL1668721

TID : UMR0661219  
Registered on : 12-Jan-2022 09:17 AM  
Reported On : 12-Jan-2022 10:40 AM

### DEPARTMENT OF ULTRASOUND Ultrasound Whole Abdomen

**LIVER** : Normal in size and echotexture. No focal lesions.  
No IHBD /CBD dilatation. Portal vein is normal.

**SPLEEN** : Normal in size and echotexture. No focal lesion seen.

**GALL BLADDER** : Well distended. No sludge / gall stones / sol.  
Gall bladder - Wall thickness is normal.  
No pericholecystic oedema.

**PANCREAS** : Normal in size and echotexture.No calcification / sol.  
Pancreatic duct is normal. No peripancreatic fluid collection.

**RIGHT KIDNEY** : 10.3 x 4.3 cms.  
Normal in size and echotexture.  
Cortical thickness is normal.  
No evidence of calculi. Non shadowing hyperechoic area measuring 0.72 x 0.66 cms in lower pole calyx.  
Pelvi calyceal system is normal.

**LEFT KIDNEY** : 11.3 x 4.7 cms.  
Normal in size and echotexture.  
Cortical thickness is normal.  
No evidence of calculi / sol.  
Pelvi calyceal system is normal.

**URINARY BLADDER** : Well distended.Normal in contour.  
Wall thickness is normal. No calculus / sol.

**UTERUS** : Anteverted measuring 8.3 x 5.6 x 5.6 cms - Normal in size and echotexture.  
Intramural / subserosal aspect of body of uterus anteriorly and to left measuring APP. 2.8 x 3.52 cms.  
Cervix is normal in size and echopattern.

**ENDOMETRIUM** : 12.4 mm -Normal.

**OVARIES** : Right ovary : 2.5 x 1.3 cms and Left ovary : 3.6 x 3.1 cms.  
Both ovaries normal in size and echotexture. Follicles bilateral ovaries largest in left ovary 3.14 cms.  
No adnexal mass seen.  
No fluid in POD.

**IMPRESSION** : Angiomyolipoma of right kidney.  
Fibroid uterus.

Clinical correlation.

The Test marked with\*are not accredited by NABL

Dr. D.J. MOHAN  
MD DMRD  
(Reg No. 8995)  
Consultant Radiologist

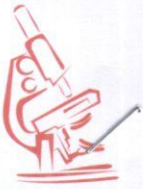Lab Timings (Weekdays) : 7.00 am to 8.30 pm

Sundays & Holidays : 7.00 am to 1.00 pm

Radiologists Timings (Weekdays) : 7.30 am to 1.30 pm

& 5.30 pm to 7.45 pm  
Sundays & Holidays : 7.30 am to 9.30 am






# PARKLINE DIAGNOSTICS PVT. LTD.

L.G. 3, 4 & 5, Bhuvana Towers, Sarojini Devi Road, Secunderabad - 500 003 Tel. +91 40-2784 5852  
6649 1787 Fax :+91 40 2784 7864 Email : parklinediagnostics@gmail.com www.parklinediagnostics.com



NABL Accredited  
Certificate No. MC-2566

## TEST REPORT

Name : MRS. MEERA SHARMA [SPOUSE] TID/SID : UMR0661357/  
Age / Gender : 42 Years / Female Registered on : 12-Jan-2022 / 09:56 AM  
Ref. By : C/O MEDI WHEEL Collected on : 12-Jan-2022 / 09:56 AM  
Req. No.  Reported on : 12-Jan-2022 / 10:10 AM  
BIL1668954


### DEPARTMENT OF CARDIOLOGY

### 2D Echo/Doppler Study

Mitral Valve	Normal
Aortic valve	Normal
Tricuspid valve	Normal
Pulmonary valve	Normal
Aorta	2.7 cm
Left Atrium	3.5 cm
Left Ventricle	LVDd: 4.6 cm IVSd: 1.1 cm EF: 64% LVDs: 3.0 cm LVPwd: 1.1 cm FS: 34%
RWMA	Nil
Right Atrium	Normal
Right Ventricle	Normal
Pulmonary Artery	Normal
IAS	Intact
IVS	Intact
Pericardium	Normal
Svc / Ivc	Normal
Intracardiac Masses	Nil
Doppler Study	Mitral flow: E > A Aortic flow : 1.2 m/sec Pulmonary flow : 0.8 m/sec
Colour Doppler	No MR / AR / TR / PR
Conclusion	No RWMA. Normal valves/ Normal chambers. No MR/ AR/ TR / PR Good LV/ RV function. No PE/ clot/ vegetation.

\* Sample processed at Parkline

--- End Of Report ---

  
Page 1 of 2

**Dr. NAVEEN KUMAR .C**  
M.D., D.M.  
Consultant Cardiologist  
Reg. No. 52291

The Test marked with\*are not accredited by NABL

Lab Timings (Weekdays) : 7.00 am to 8.30 pm

Sundays & Holidays : 7.00 am to 1.00 pm

Radiologists Timings (Weekdays) : 7.30 am to 1.30 pm  
& 5.30 pm to 7.45 pm

Sundays & Holidays : 7.30 am to 9.30 am





# PARKLINE DIAGNOSTICS PVT. LTD.

L.G. 3, 4 & 5, Bhuvana Towers, Sarojini Devi Road, Secunderabad - 500 003 Tel. +91 40-2784 5852  
6649 1787 Fax : +91 40 2784 7864 Email : parklinediagnostics@gmail.com www.parklinediagnostics.com



NABL Accredited  
Certificate No. MC-2566

## TEST REPORT

Name	: Ms . MEERA SHARMA [SPOUSE]	TID	: UMR0661219
Age / Gender	: 42 Years / Female	Registered on	: 12-Jan-2022 09:17 AM
Ref.By	: Medi Wheel	Reported On	: 12-Jan-2022 10:36 AM
Req. No	: BIL1668721		

### DEPARTMENT OF X-RAY X-Ray Chest PA View

Lung fields are clear.

Cardia is normal.

Hila are normal.

C P angles are free.

Bony cage is normal.

Soft tissues are normal.

**IMPRESSION** : NORMAL CHEST XRAY.

  
**Dr. D.J. MOHAN**  
MD DMRD  
(Reg No. 8995)  
Consultant Radiologist

The Test marked with\*are not accredited by NABL

Lab Timings (Weekdays) : 7.00 am to 8.30 pm

Sundays & Holidays : 7.00 am to 1.00 pm

Radiologists Timings (Weekdays) : 7.30 am to 1.30 pm

Sundays & Holidays

Page: 1 of 1  
& 5.30 pm to 7.45 pm

: 7.30 am to 9.30 am



ID: 1668721  
MS.MEERA SHARMA  
Female 42Years

12-01-2022 09:42:02 AM

CARDIART

HR : 65 bpm  
P : 121 ms  
PR : 202 ms  
QRS : 77 ms  
QT/QTc : 392/408 ms  
P/QRS/T : 64/48/31 °  
RV5/SV1 : 1.025/0.997 mV

NSR  
WNL

*CS*

Dr. NAVEEN KUMAR .C  
M.D., D.M.  
Consultant Cardiologist  
Reg. No. 52291

Diagnosis Information:  
Sinus Rhythm  
Poor R Wave Progression(V2)

Report Confirmed by: