



भारत सरकार
Government of India



भारत सरकार
Government of India


भारतीय विशिष्ट पहचान प्राधिकरण
Unique Identification Authority of India

Enrolment No.: 0649/41851/55441

To
Manik Chandra Nayak
C/O: Miranjan Nayak
adupara
ramrajatala hutpukur
Haora (M.Corp)
Howrah West Bengal - 711112
9007937914

Signature valid

Digitally signed by Manik Chandra Nayak
UNIQUE IDENTIFICATION
AUTHORITY OF INDIA 04
Date: 2022.07.17 12:42:42
UTC



आपका आधार क्रमांक / Your Aadhaar No. :

8262 7643 7976
VID : 9154 7049 0099 4174

मेरा आधार, मेरी पहचान



भारत सरकार
Government of India



Issue Date: 07/10/2016



Manik Chandra Nayak
Date of Birth/DOB: 07/04/1962
Male/ MALE

8262 7643 7976
VID : 9154 7049 0099 4174

मेरा आधार, मेरी पहचान

Manik Chandra Nayak



सूचना

- आधार पहचान का प्रमाण है, नागरिकता का नहीं।
- सुरक्षित QR कोड / ऑफलाइन XML / ऑनलाइन ऑथेंटिकेशन से पहचान प्रमाणित करें।
- यह एक इलेक्ट्रॉनिक प्रक्रिया द्वारा बना हुआ पत्र है।

INFORMATION

- **Aadhaar** is a proof of identity, not of citizenship.
- Verify identity using Secure QR Code/ Offline XML/ Online Authentication.
- This is electronically generated letter.

- आधार देश भर में मान्य है।
- आधार कई सरकारी और गैर सरकारी सेवाओं को पाना आसान बनाता है।
- आधार में मोबाइल नंबर और ईमेल ID अपडेट रखें।
- आधार को अपने स्मार्ट फोन पर रखें, **mAadhaar App** के साथ।


- **Aadhaar** is valid throughout the country.
- **Aadhaar** helps you avail various Government and non-Government services easily.
- Keep your mobile number & email ID updated in **Aadhaar**.
- Carry Aadhaar in your smart phone – use **mAadhaar App**.



भारतीय विशिष्ट पहचान प्राधिकरण
Unique Identification Authority of India



Address:
C/O: Niranjan Nayak, adupara, ramrajatala
hutpukur, Haora (M.Corp), Howrah,
West Bengal - 711112



8262 7643 7976

VID : 9154 7049 0099 4174

1947

help@uidai.gov.in

www.uidai.gov.in

Manik Chandrasekhar

Date: 05/04/2022

~~Dear~~
Madam/ Sir,

I, Manik ch. Nayak, employee of Bank of Baroda. My EENO: 54696 and presently working in Howrah main br. A annual health check-up is organized by mediwheel and I select Apollo clinic in Howrah. I our health check-up policy unaware about stool sample collection. So I cannot give stool sample now.

Thanking ~~you~~ you.

Yours faithfully.

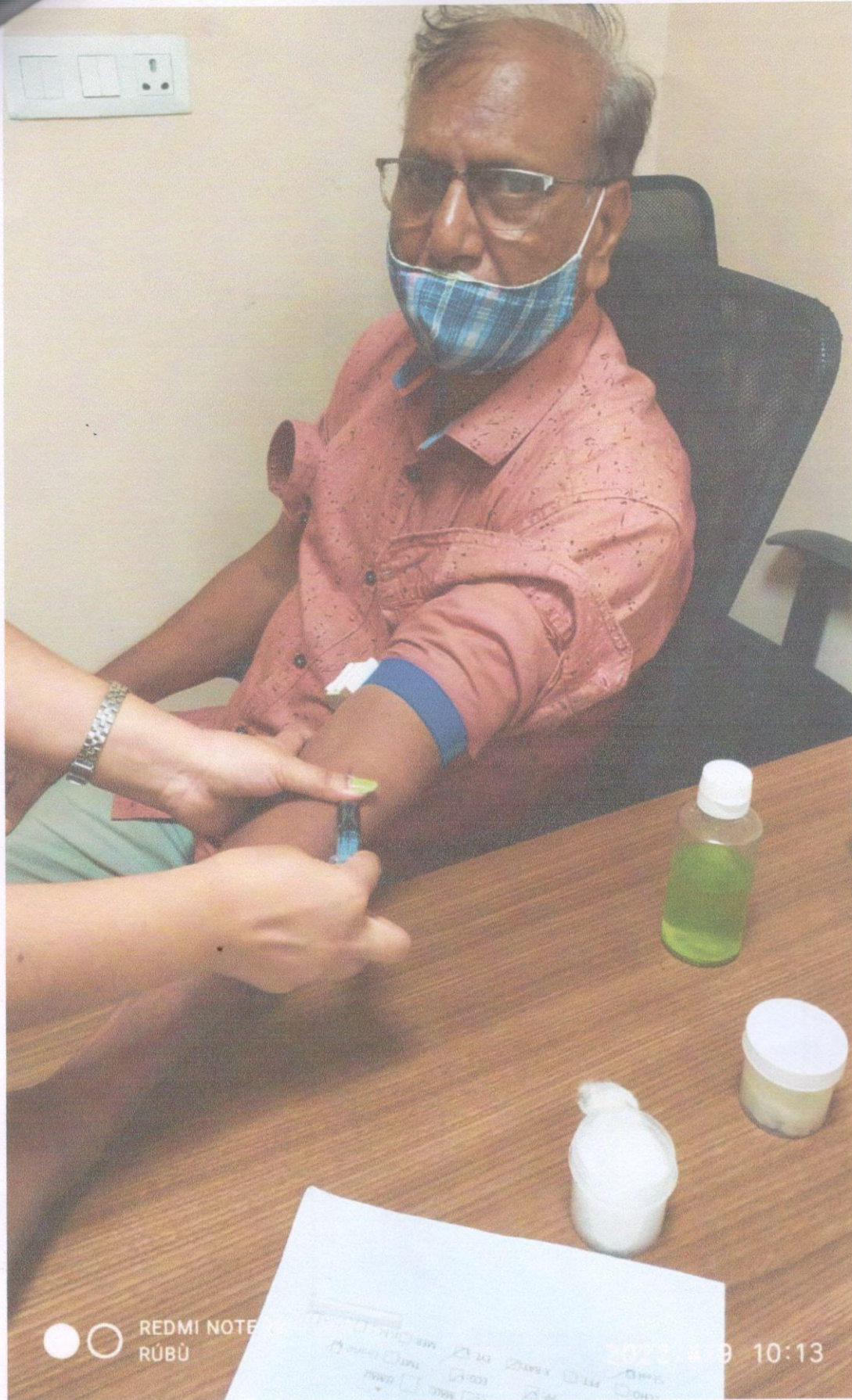✓ Manik Chandra Nayak





REDMI NOTE 7S
RÚBÚ

2022/4/9 09:34



REDMI NOTE
RUBU

2022/09/09 10:13

63

NAME:MR.MANIK CHANDRA NAYAK	MR. NO: FSIN-0000	DATE: 09/04/2022
AGE :60YRS	SEX:MALE	REF. BY: SELF

ULTRASOUND OF WHOLE ABDOMEN

LIVER: Liver is **enlarged** in size(**20.60cm**),shape,outline and echotexture. The intrahepatic tubular structures are normal. The porta hepatis is normal . The common bile duct measures 4mm in diameater. The portal vein measures 9mm at porta .

GALLBLADDER: Gall bladder is normal. Wall is normal. No calculus or mass is seen within the gall bladder.

PANCREAS: It is normal in size, Shape, Outline and echotexture. Pancreatic duct is not dilated.

SPLEEN: It is normal in size **12.40cm**, Shape, Outline and echotexture. No parenchymal lesion is noted.

RIGHT KIDNEYS: It is normal in position, size, shape, outline and echotexture. No calculus or hydronephrosis is seen.

RIGHT KIDNEY measures **10.58cm**.

LEFT KIDNEYS: It is normal in position, size, shape, outline and echotexture.


LEFT KIDNEY measures **11.00cm**.

URINARY BLADDER: It is well distended with normal wall thickness. No calculus or mass is seen within the urinary bladder. The post void residual volume of urine is insignificant.

PROSTATE: It is **enlarge** in size, shape& has a homogenous echotexture. The prostatic outline is smooth. The periprostatic plane is normal. It is normal in size measures **3.94cmX3.01cmX4.73cm** **VOL-56.04gms**.

IMPRESSION:

- HEPATOMEGALY GRADE I FATTY INFILTRATION.
- ENLARGE PROSTATE.



A.K.ROY

M.B.B.S, Dip BMSc, DTM&H (Cal)
Certificate on CEBT Abdomino Pelvic, USG(WBHSU)

DEPARTMENT OF RADIOLOGY X-RAY OF CHEST (PA) VIEW

MR. NO- FSIN.0000000

SEX-MALE

NAME: -MANIK CHANDRA NAYAK

EXAMINATION DATE-09/04/2022

AGE-60YRS

REPORT DATE-09/04/2022

REF DR. SELF

FINDINGS:

- Bilateral lung fields are clear.
- Tracheal shadow is in the midline.
- Bilateral CP angle are clear
- Both hila appear normal .
- CTR appears normal .
- No definite bone fracture is noted.

DR.ARNAB MANDAL

MD, Physician, PGDUS (Delhi) CEPT-USG (WBUHS KOLKATA)
Fellow of Jefferson Ultrasound Radiology and Education Institute
Philadelphia Ex-Radiology Resident (S.E.Railway)
Regd.No:72022(WBMC)



DR. BOUDHAYAN BHATTACHARJEE

MBBS. (MEDICAL COLLEGE, KOLKATA) MD (TROPICAL MEDICINE)
CONSULTANT PHYSICIAN & INTENSIVIST

TO WHOM IT MAY CONCERN

THIS IS TO CERTIFY THAT, **MRS. MANIK CHANDRA NAYAK** ,
AGE- 60Y/MALE, IS PHYSICALLY FIT HE DETECTED WITH HIGH
SGPT, SGOT AND ALKA-PHOS.

DATE: 13.04.22.....

Boudhayan Bhattacharjee.

SIGNATURE

STAMP

APOLLO CLINIC OM TOWER
36C, B.T ROAD OPP "RBU"
KOL 700002
Ph 033 25565555
033 25563333

Dr. BOUDHAYAN BHATTACHARJEE
MBBS, MD (TROPICAL MEDICINE)
66631 of WBMC



DR. RAKTIMA BAKSHI MANDAL

CONSULTANT EYE SURGEON
& OPHTHALMOLOGIST

TO WHOM IT MAY CONCERN

THIS IS TO CERTIFY THAT MR. MANIK CHANDRA NAYAK,

AGE- 60Y/MALE.

HE IS WITH CLEAR VISION, WITH NO COLOR BLINDNESS.

RIGHT EYE	POWER +1
LEFT EYE	POWER +1

DATE: 13.04.2022.....

APOLLO CLINIC OM TOWER
36C, B.T ROAD OPP "RBU"
KOL 700002
Ph 033 25565555
033 25563333

R.B. Mandal.....

SIGNATURE
DC STAMP

DR. RAKTIMA BAKSHI MANDAL
M.B.B.S., M.S. (OPHTHALMOLOGY)
Regn. No.. 69521 of WBMG
Consultant Eye Surgeon



DR. ABHIRUP MUKHERJEE

BDS (WBUHS)
Oral & Dental Surgeon
Regn.No. 3726 Part A (Wbdc)

TO WHOM IT MAY CONCERN

THIS IS TO CERTIFY THAT **MR. MANIK CHANDRA NAYAK , 60Y/MALE,**
HAS NO ORAL PROBLEM.

THERE IS NO CAVITY AND BAD SMELL OBSERVED IN HIS MOUTH.

DATE: 12/4/22

A. Mukherjee
.....

SIGNATURE

DC STAMP

APOLLO CLINIC OM TOWER
36C, B.T ROAD OPP "RBU"
KOL 700002
Ph 033 25565555
033 25563333

Dr. ABHIRUP MUKHERJEE
BDS (WBUHS)
Oral & Dental Surgeon
Regn. No. 3726 Part A (WBDC)



DR. SOURADEEP RAY

MBBS, MS (ENT)
ASSOCIATE PROFESSOR R.G. KAR MEDICAL, KOLKATA.
REGD.NO. 63999 (WBMC)

TO WHOM IT MAY CONCERN

THIS IS TO CERTIFY THAT
MR. MANIK CHANDRA NAYAK, AGE- 60Y/MALE,
HAS NO PROBLEM IN HIS EAR, NOSE AND THROAT.

HIS EAR IS CLEAN, NO HEARING PROBLEM OBSERVED,
NASAL PASAGE IS CLEAR, WITH PROPER SMELLING CAPACITY,
THROAT IS CLEAR, NO INFECTION FOUND IN TONSILS.

DATE: 13-04-22


.....

SIGNATURE
DC STAMP

APOLLO CLINIC OM TOWER
36C, B.T ROAD OPP "RBU"
KOL 700002
Ph 033 25565555
033 25563333

Patient Name: Mr. MANIK CHANDRA NAYAK 60/M

Resting ECG Report

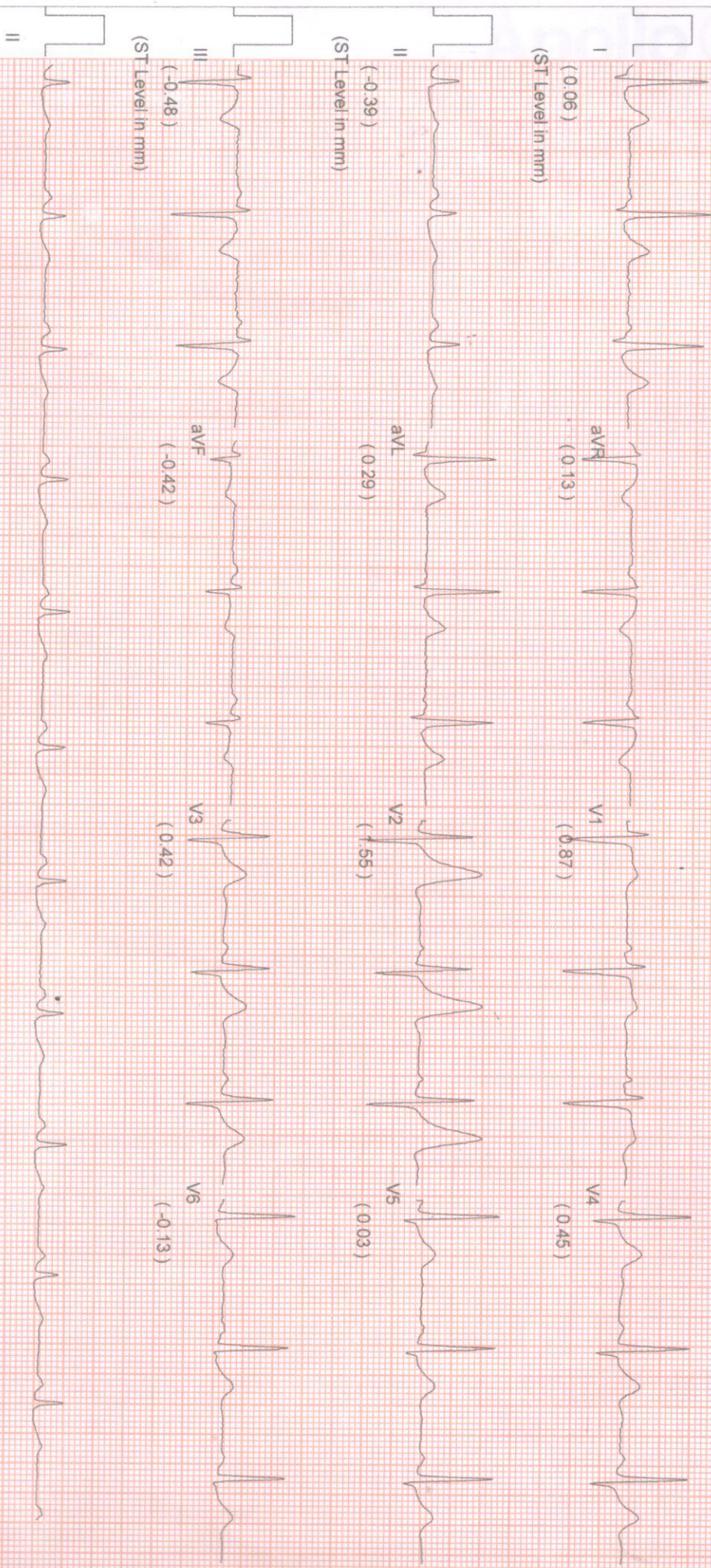
April 09, 2022
Time: 11:18:59

QT / QTc : 0.424 / 0.445 Sec
P-QRS-T Axis (41) (-17) (-14) deg

PR Interval: 0.14 sec
QRS Duration: 0.084 Sec

RR Interval: 0.90 sec

HR : 66 bpm BP : 140 / 70 mmHg



Comments :-

Manik Chandra Nayak
10mm/mv, 25mm/sec. NASAN (C). Simul-G. BE U. 4.3/1.13


NAME: MR.MANIK CHANDRA NAYAK	MR NO: FSIN-0000	DATE : 09.04.2022
AGE: 60YRS.	SEX:MALE	REF BY:SELF

ECG REPORT

HR : 66 b/min
AXIS : NORMAL
RHYTHM : SINUS
PR INTERVAL : 0.14 sec
QT INTERVAL : 0.424 sec
QRS DURATION : 0.084 sec
T-WAVE : NORMAL.

IMPRESSION:

- RESTING ECG IS WITHIN NORMAL LIMITS.


Dr. SIDDHARTHA KUNDU
MBBS (Cal), PGDCC, CCEBDM
Clinical Cardiologist
Ex Sr Resident, Cardiology Dep
B.R Singh Hospital, Eastern Railway

