

To,

The Coordinator,
Mediwheel (Arcofemi Healthcare Limited)
Helpline number: 011- 41195959

Dear Sir / Madam,

Sub: Annual Health Checkup for the employees of Bank of Baroda

This is to inform you that the following spouse of our employee wishes to avail the facility of Cashless Annual Health Checkup provided by you in terms of our agreement.

PARTICULARS OF HEALTH CHECK UP BENEFICIARY	
NAME	USHA .
DATE OF BIRTH	12-09-1992
PROPOSED DATE OF HEALTH CHECKUP FOR EMPLOYEE SPOUSE	21-07-2021
BOOKING REFERENCE NO.	21S93834100001304S
SPOUSE DETAILS	
EMPLOYEE NAME	MR. SINGH KARANBIR
EMPLOYEE EC NO.	93834
EMPLOYEE DESIGNATION	HEAD CASHIER "E" _II
EMPLOYEE PLACE OF WORK	SADHAURA
EMPLOYEE BIRTHDATE	01-01-1982

This letter of approval / recommendation is valid if submitted along with copy of the Bank of Baroda employee id card. This approval is valid from **20-07-2021** till **31-03-2022**. The list of medical tests to be conducted is provided in the annexure to this letter. Please note that the said health checkup is a **cashless facility** as per our tie up arrangement. We request you to attend to the health checkup requirement of our employee's spouse and accord your top priority and best resources in this regard. The EC Number and the booking reference number as given in the above table shall be mentioned in the invoice, invariably.

We solicit your co-operation in this regard.

Yours faithfully,

Sd/-

Chief General Manager
HRM Department
Bank of Baroda

(Note: This is a computer generated letter. No Signature required. For any clarification, please contact Mediwheel (Arcofemi Healthcare Limited))

भारत सरकार
Government of India

उषा
Usha

जन्म तिथि / DOB: 12/09/1992
महिला / Female

7513 8830 6405

आधार - आम आदमी का अधिकार



आधार
Unique Identification Authority of India

पता: W/O: करणबीर सिंह
हाउस नंबर सी-5 705, बसंत नगर, जगाधरी
यमुनानगर, यमुनानगर, हरियाणा, 135001

Address: W/O: Karanbir
Singh, house number C-5
705, basant nagar, Jagadhri,
Yamunanagar, Haryana,
135001

7513 8830 6405

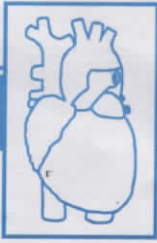1947
1800 300 1947

help@uidai.gov.in

www
www.uidai.gov.in

Auf

DR. J.K. GULATI
MD, DNB
GULATI HOSPITAL
Near Bus Stand, Yamuna Nagar



GULATI HOSPITAL

169, Sarojini Colony, Near Bus Stand,
YAMUNA NAGAR - 135 001

Dr. J.K. Gulati

M.D., D.N.B. (AIIMS, New Delhi)
Consultant Physician & Heart Specialist

Dr. Sarita Gulati

D.G.O., DCH (Gynaecologist)
Ex. SMO, Civil Hospital, YNR.

ULTRASONOGRAPHY (WHOLE ABDOMEN)

NAME MRS USHA AGE & SEX 29 F 21.07.21

LIVER

Liver shows normal echopattern with normal vasculature and normal intrahepatic biliary radical pattern. No mass or abscess is seen

GALL BLADDER

It is not visualized Cholecystectomy. CBD measures within normal limits.

PANCREAS

Pancreas shows normal echo pattern.

KIDNEYS

Both kidneys measure within normal limits with normal echogenic pattern and well maintained corticomedullary distinction. No evidence of hydronephrotic change is seen. No calculus seen

SPLEEN

No abnormal echos detected from the splenic area.


URINARY BLADDER

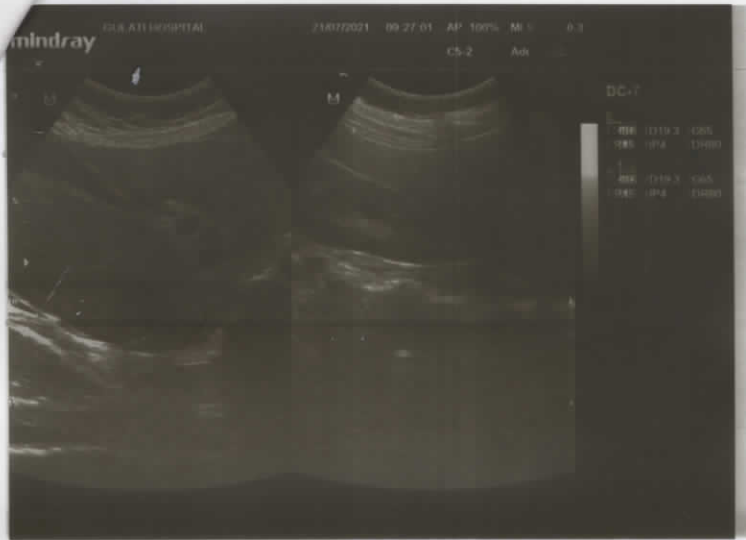Bladder is well distended and has normal smooth wall. No mass or calculus is seen.

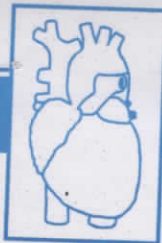
UTERUS AND ADENEXA

Uterus is normal in size. No abnormal echoes seen from these areas
Endometrium is 7.5 mm.
No fluid seen in the POD.

CONCLUSION NO ABNORMALITY


DR. J.K. GULATI
MD, DNB
GULATI HOSPITAL
Near Bus Stand, Yamuna Nagar





GULATI HOSPITAL

169, Sarojini Colony, Near Bus Stand,
YAMUNA NAGAR - 135 001

Dr. J.K. Gulati

M.D., D.N.B. (AIIMS, New Delhi)

Consultant Physician & Heart Specialist

ECHOCARDIOGRAPHY

Dr. Sarita Gulati

D.G.O., DCH (Gynaecologist)

Ex. SMO, Civil Hospital, YNR.

NAME. MRS USHA

AGE & SEX 29 F

DATED 21.07.21

M-MODE PARAMETERS

		Normal Values
Left Ventricular ED Dimension	4.2 cm	(3.7-5.6cm)
Left Ventricular ES Dimension	2.5 cm	(2.2-4.0cm)
Right Ventricular ED Dimension	2.0 cm	(0.7-2.6cm)
Inter Ven. Septum thickness (D)	0.8 cm	(0.6-1.1cm)
LV Posterior Wall thickness (D)	0.8 cm	(0.6-1.1cm)
Aortic root diameter	2.7 cm	(2.0-3.7cm)
Left Atrial Diameter	3.0 cm	(1.9-4.0cm)

INDICES OF LV SYSTOLIC FUNCTIONS (NORMAL VALUES)

Ejection Fraction	65 %	(54-76%)
Fractional Shortening	35 %	(25-46%)

MITRAL VALVE

Thin, and it moves posteriorly during diastole. No subvalvular pathology, no anterior leaflet pathology no prolapsed or flutter or systolic anterior motion

TRICUSPID VALVE

Valve is normal looking, no prolapse is seen

AORTIC VALVE

All three cusps seen, opens fully during systole with central closure

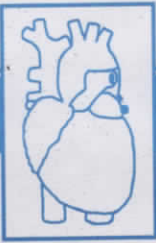
PULMONARY VALVE

Thin opens well, Pulmonary Aartery not dilated

LEFT VENTRICLE

No hypertrophy, Chamber slightly dilated No segmental wall

motion abnormality



GULATI HOSPITAL

169, Sarojini Colony, Near Bus Stand,
YAMUNA NAGAR - 135 001

PULSE, & CONTINUOUS WAVE DOPPLER

Dr. J.K. Gulati

M.D., D.N.B. (AIIMS, New Delhi)
Consultant Physician & Heart Specialist

NO mitral regurgitation.

No aortic regurgitation.

NO Tricuspid regurgitation .

No pulmonary regurgitation.

Predicted PA pressure (S)=25MM of Hg

Dr. Sarita Gulati

D.G.O., DCH (Gynaecologist)
Ex. SMO, Civil Hospital, YNR.

COLOUR FLOW IMAGING

No Mitral regurgitation.

No aortic regurgitation.

No tricuspid regurgitation.

No pulmonary regurgitation.

COMMENTS

No LA, LAA, LV CLOT seen.

No vegetation on any valve

No intra cardiac mass.

Pericardial effusion.

IAS, IVS intact.

IMPRESION:- Echocardiography Findings are suggestive of

Normal Systolic and diastolic Functions

No Evidence of Hypertrophy

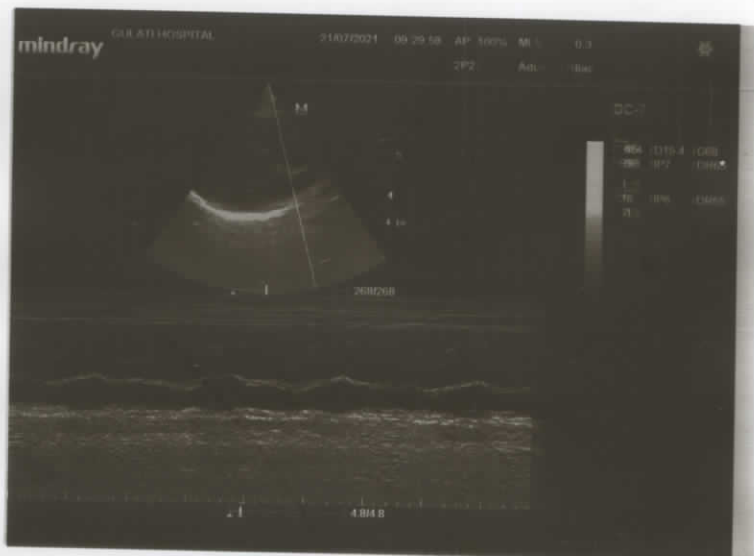
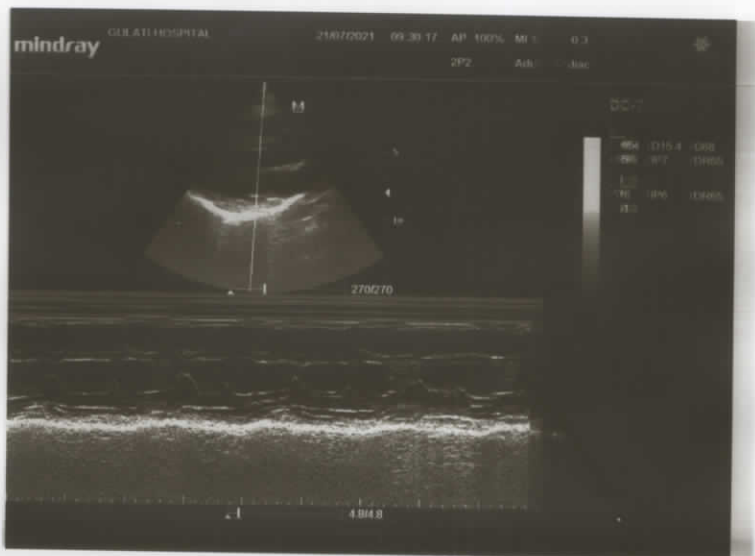
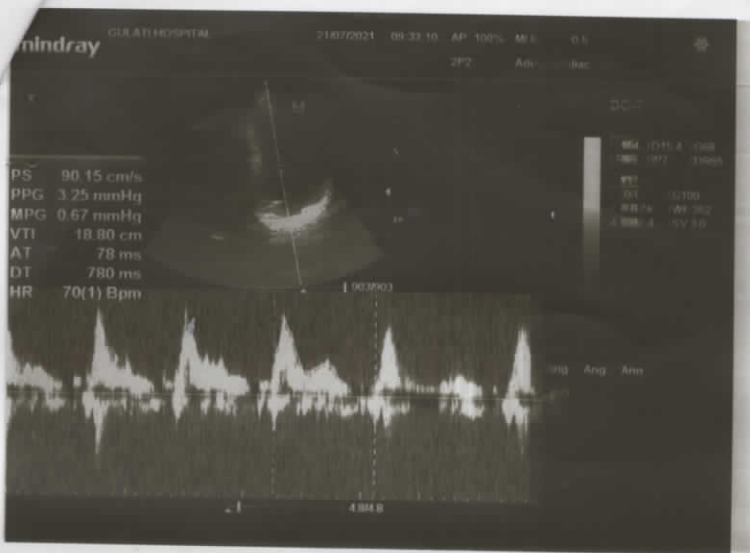
Dr J K Gulati MD, DNB (Medicine)

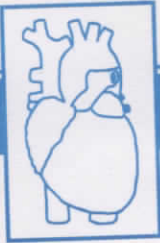DR. J.K. GULATI

MD, DNB

GULATI HOSPITAL

Near Bus Stand, Yamuna Nagar





GULATI HOSPITAL

169, Sarojini Colony, Near Bus Stand,
YAMUNA NAGAR - 135 001

Dr. J.K. Gulati

M.D., D.N.B. (AIIMS, New Delhi)
Consultant Physician & Heart Specialist

Dr. Sarita Gulati

D.G.O., DCH (Gynaecologist)
Ex. SMO, Civil Hospital, YNR.

Lisho

28 yrs F

21.07.21

Asymptomatic

Pulse - 72 mt.

Bp - 110/80

Chk - Clear

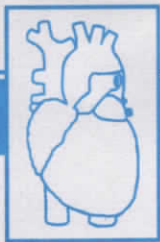
ac - MAD

Abd - MAD

also abnormal

Avery

DR. J.K. GULATI
MD, DNB
GULATI HOSPITAL
Near Bus Stand, Yamuna Nagar



HOS. 260633
RES. 261633

GULATI HOSPITAL

169, Sarojini Colony, Near Bus Stand,
YAMUNA NAGAR - 135 001

Dr. J.K. Gulati

M.D., D.N.B. (AIIMS, New Delhi)
Consultant Physician & Heart Specialist

Dr. Sarita Gulati

D.G.O., DCH (Gynaecologist)
Ex. SMO, Civil Hospital, YNR.

X - RAY Chest PA

Date:-21/7/2021

Name:-Mrs.Usha

Age /Sex:- 29Yrs/F


Skin and soft tissue normal

Bony and skeleton normal

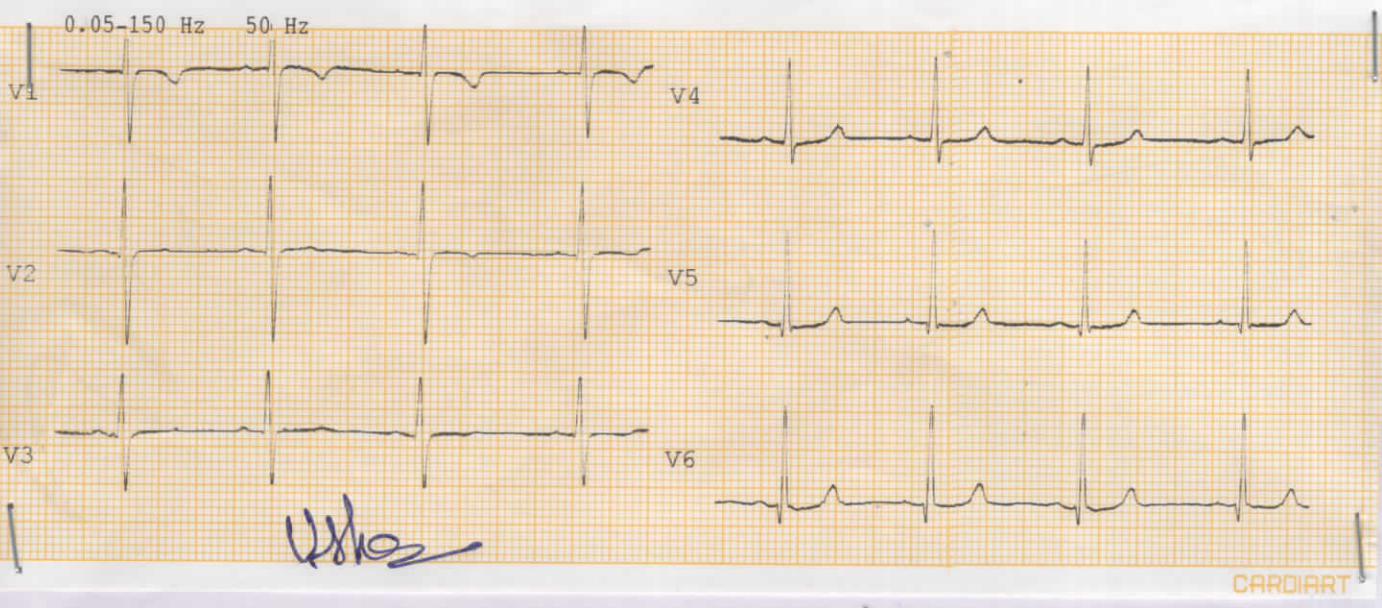
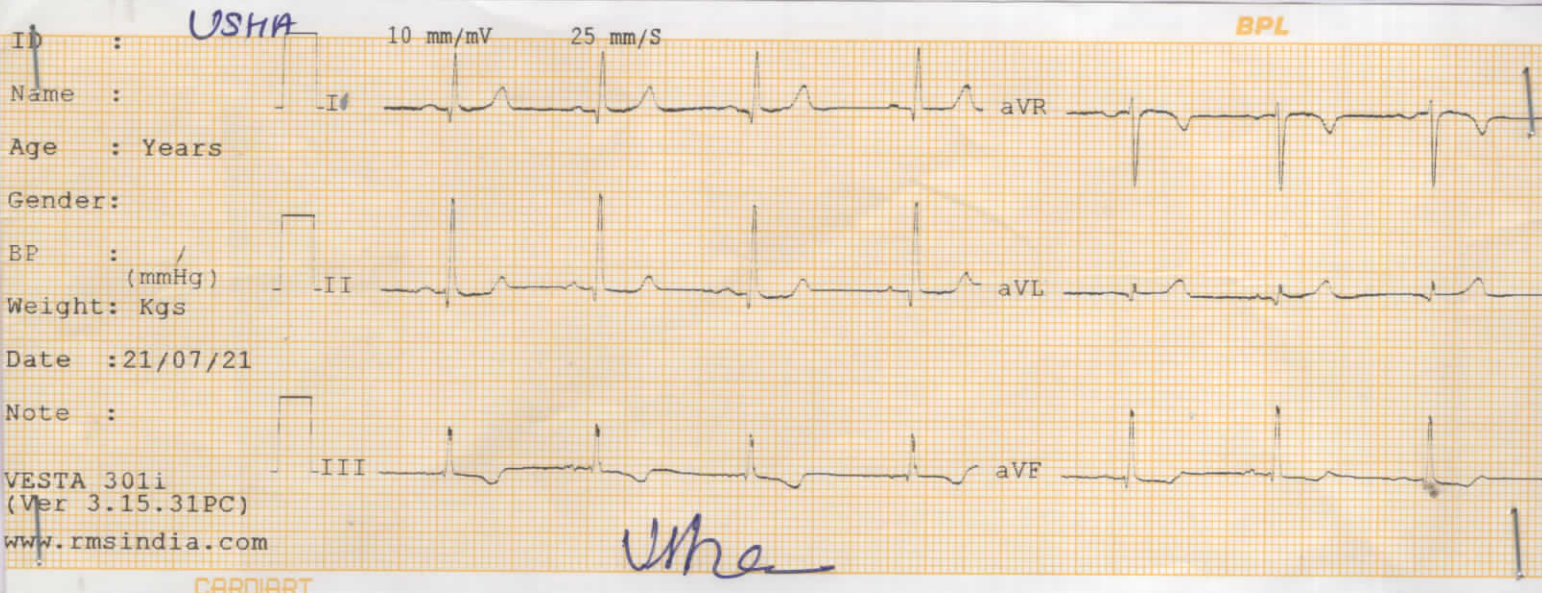
Trachea is central

Mediastinum is normal

Heart size and shape Normal


DR. J.K. GULATI
MD, DNB
GULATI HOSPITAL
Near Bus Stand, Yamuna Nagar

~~Usha~~ USHA



ECG REPORT:-Within Normal Limits

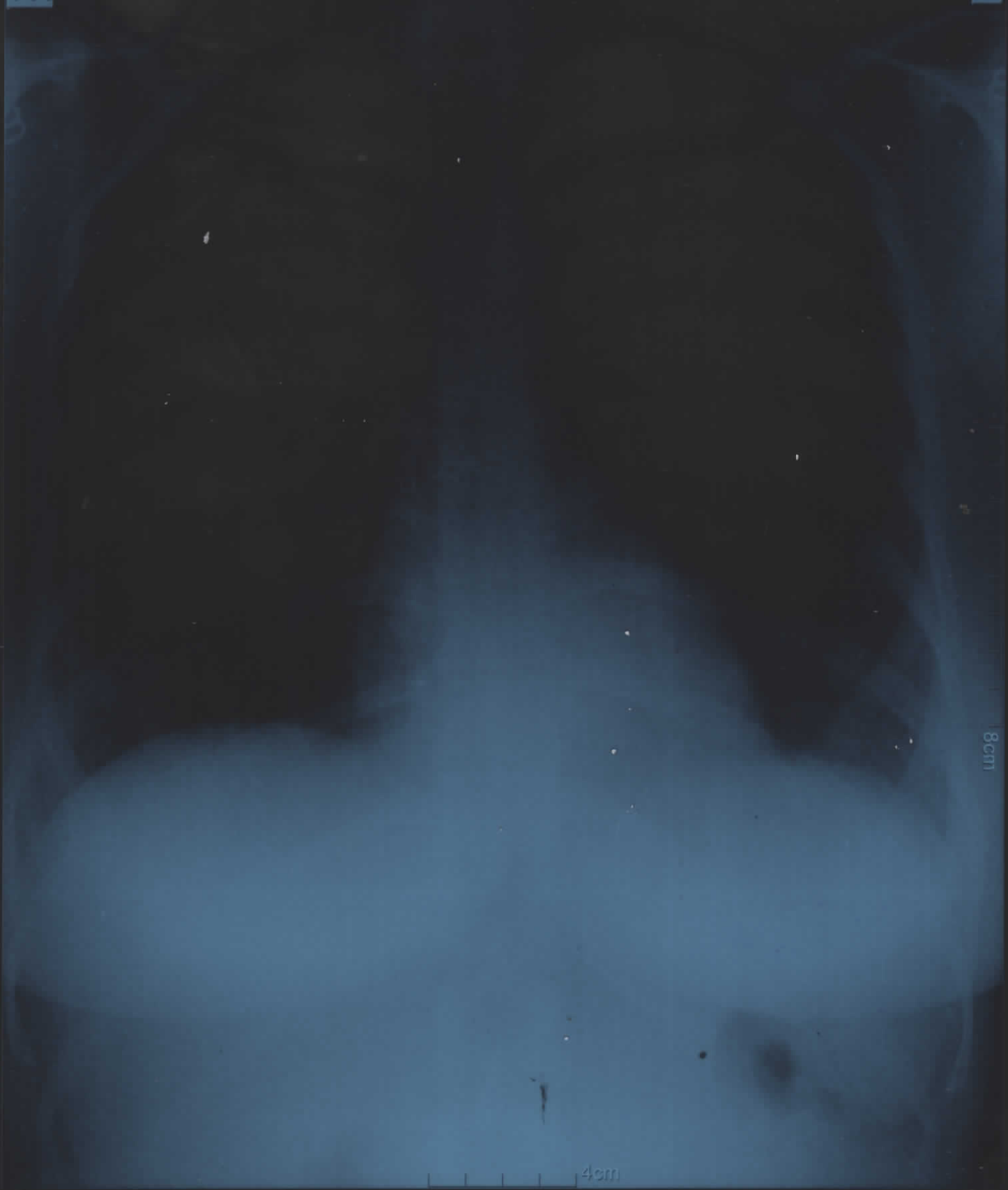
Signature
DR. J.K. GULATI
MD, DNB
GULATI HOSPITAL
Near Bus Stand, Yamuna Nagar

Mrs. Usha 29Y F.

21-07-2021

PA

L



8cm

4cm

Gulati Hospital Near Bus Stand Yamuna Nagar