

Customer Name	MR. PONRAJ. P	Customer ID	MED121758987
Age & Gender	50Y/MALE	Visit Date	22/03/2023
Ref Doctor	MEDIWHEEL,		

Thanks for your reference

DIGITAL X- RAY CHEST PA VIEW

Trachea appears normal.

Cardiothoracic ratio is within normal limits.

Bilateral lung fields appear normal.

Both costophrenic angles appear normal.

Visualised bony structures appear normal.

Extra thoracic soft tissues shadow grossly appears normal.

IMPRESSION:

✓ **NO SIGNIFICANT ABNORMALITY DEMONSTRATED.**



DR. DANIEL STANLEY PETER, M.D.R.D.,
Consultant Radiologist.
Reg. No: 82342.

L

PONRAJ P 50 M MED121758987 TEN88849363844 M RT 3/22/2023

MEDALL DIAGNOSTICS

Customer Name	MR.PONRAJ P	Customer ID	MED121758987
Age & Gender	50Y/MALE	Visit Date	22/03/2023
Ref Doctor	MediWheel		

Thanks for your reference

**REAL - TIME 2D & 4D ULTRASOUND DONE WITH VOLUSON 730 EXPERT .
SONOGRAM REPORT**

WHOLE ABDOMEN

- Liver:** The liver is normal in size and shows uniform echotexture with no focal abnormality. There is no intra or extra hepatic biliary ductal dilatation.
- Gallbladder:** The gall bladder is contracted (post prandial status).
- Pancreas:** The pancreas obscured by bowel gas.
- Spleen:** The spleen is normal.
- Kidneys:** The right kidney measures 9.8 x 4.0 cm. Normal architecture. The collecting system is not dilated.
- The left kidney measures 10.5 x 5.1 cm. Normal architecture. The collecting system is not dilated.
- Urinary bladder:** The urinary bladder is partially filled. No demonstrable internal echoes noted.

Customer Name	MR.PONRAJ P	Customer ID	MED121758987
Age & Gender	50Y/MALE	Visit Date	22/03/2023
Ref Doctor	MediWheel		

Prostate: The prostate measures 3.6 x 3.3 x 3.2 cm and is normal sized.
Corresponds to a weight of about 20.13 gms.
The echotexture is homogeneous.
The seminal vesicles are normal.

RIF: Iliac fossae are normal.
No mass or fluid collection is seen in the right iliac fossa.
The appendix is not visualized.
There is no free or loculated peritoneal fluid.
No para aortic lymphadenopathy is seen.

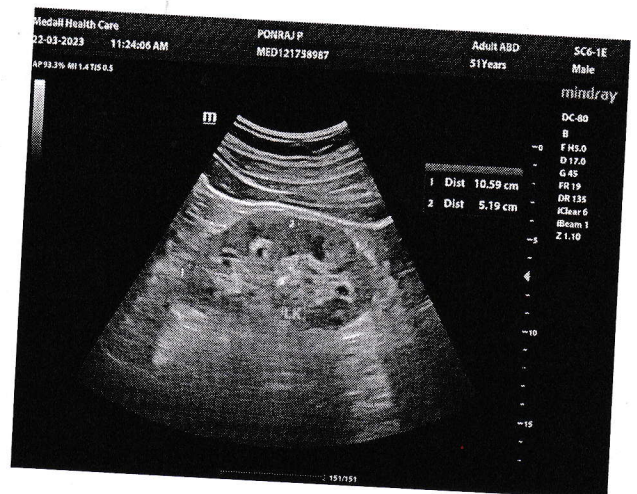
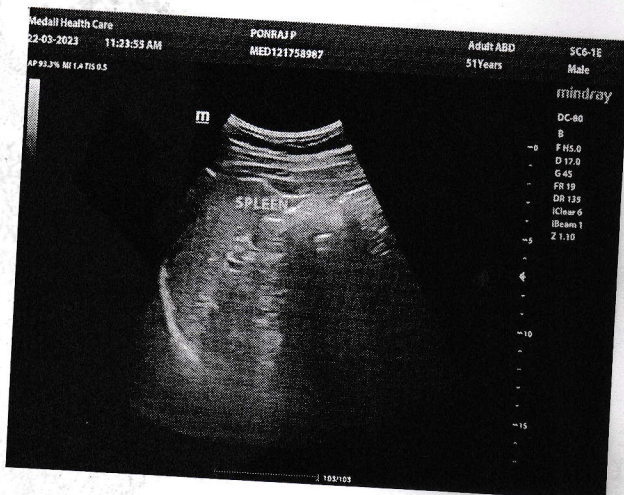
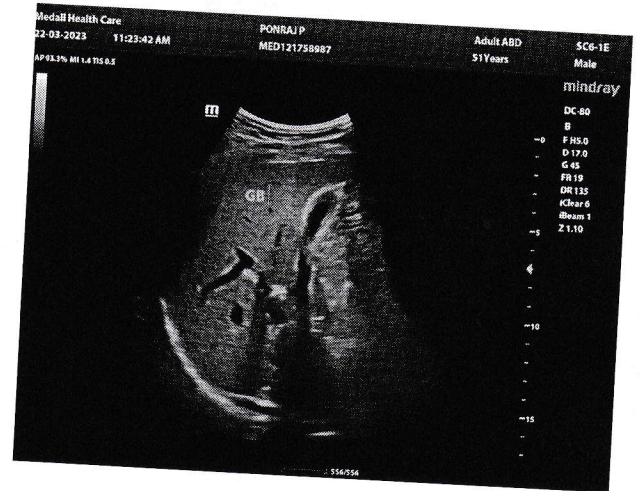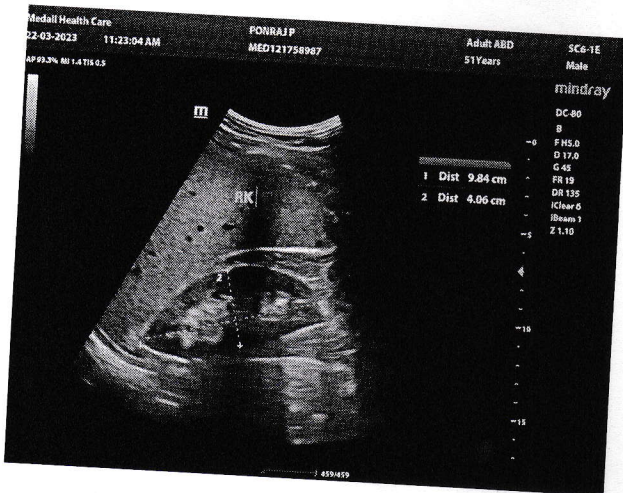
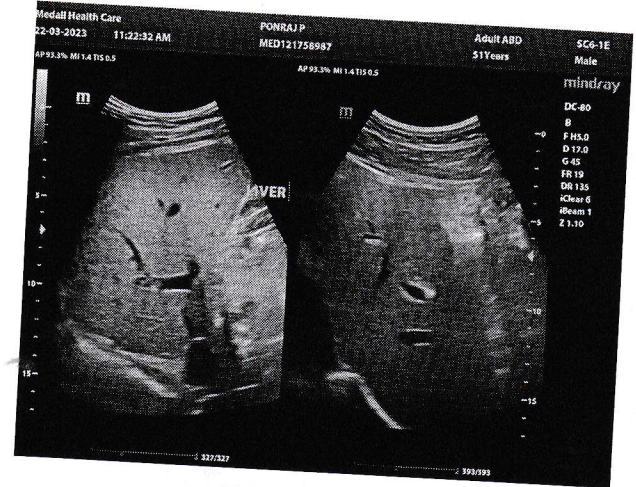
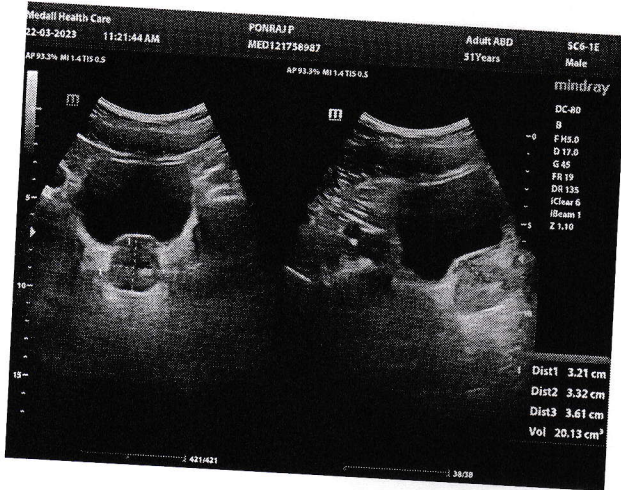
IMPRESSION :

➤ **No significant abnormality.**


**DR. T. ANNIE STALIN MBBS., F.USG.,
SONOLOGIST.
REG. NO: 85764.**



Customer Name	MR.PONRAJ P	Customer ID	MED121758987
Age & Gender	50Y/MALE	Visit Date	22/03/2023
Ref Doctor	MediWheel		



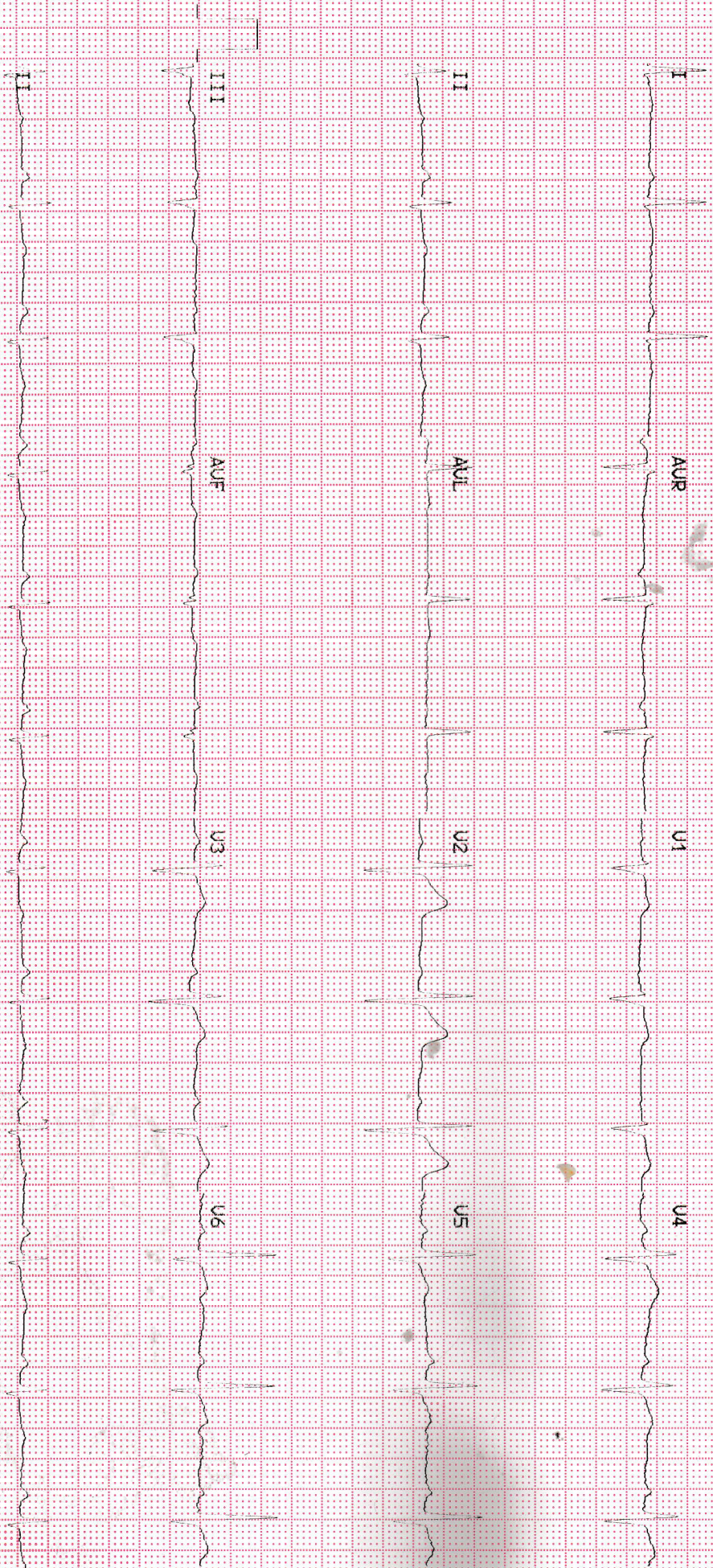
Measurement Results

QRS	104 ms
QT/QTcB	414 / 443 ms
PR	180 ms
P	104 ms
PR/PP	874 / 880 ms
P/ORS/T	40 / -5 / 60 degrees
QTd/QTcBd	40 / 43 ms
STcLow	1.8 mV
SKLow	9

< P
 < T
 < QRS
 -90
 aVR
 aVL
 0 I
 III +90
 aVF II

Interpretation:
 suspected left ventr. hypertrophy
 minor left axis deviation
 S waves up to U6
 probably abnormal ECG

Unconfirmed report



Customer Name	MR.PONRAJ P	Customer ID	MED121758987
Age & Gender	50Y/MALE	Visit Date	22/03/2023
Ref Doctor	MediWheel		

Thanks for your reference

ECHOCARDIOGRAM WITH COLOUR DOPPLER:

LVID d ... 5.0 cm
 LVID s ... 2.8 cm
 EF ... 75 %
 IVS d ... 1.3 cm
 IVS s ... 1.1 cm
 LVPW d ... 0.7 cm
 LVPW s ... 1.3 cm
 LA ... 3.2 cm
 AO ... 3.7 cm
 TAPSE ... 23mm
 IVC ... 0.9cm

Left ventricle : Increased wall thickness.

Left atrium normal.

Right ventricle, Right atrium normal.

No regional wall motion abnormality present.

Mitral valve , Aortic valve, Tricuspid valve & Pulmonary valve normal.

Aorta normal.

Inter atrial septum intact.

Inter ventricular septum intact.

No pericardial effusion .



Customer Name	MR.PONRAJ P	Customer ID	MED121758987
Age & Gender	50Y/MALE	Visit Date	22/03/2023
Ref Doctor	MediWheel		

Doppler:

Mitral valve : E: 0.64 m/s A: 0.53 m/s
E/A Ratio: 1.21 E/E: 9.38

Aortic valve: AV Jet velocity: 1.54 m/s

Tricuspid valve: TV Jet velocity: 2.32 m/s TRPG: 21.62mmHg.

Pulmonary valve: PV Jet velocity: 0.96 m/s

IMPRESSION:


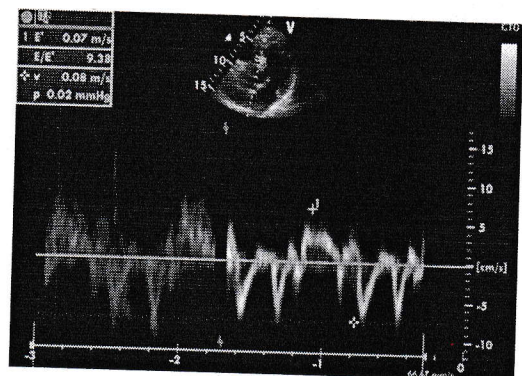
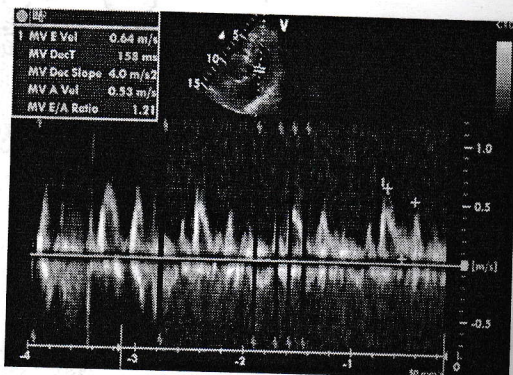
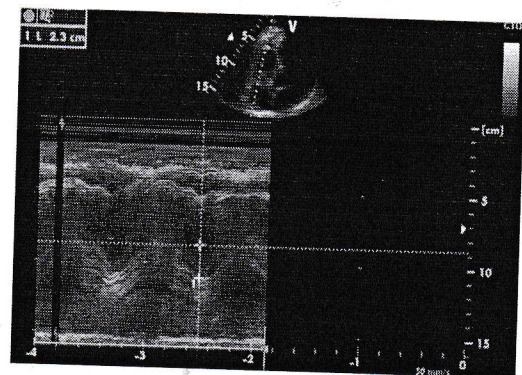
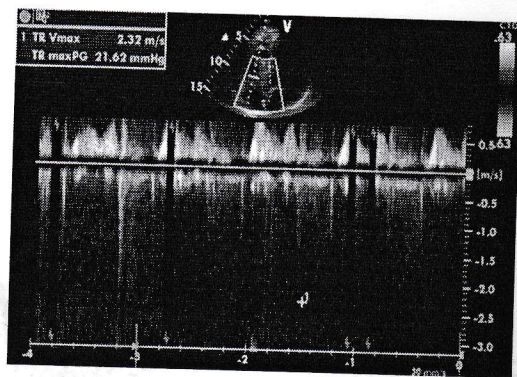
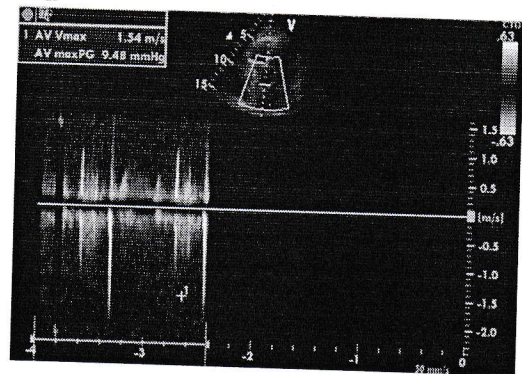
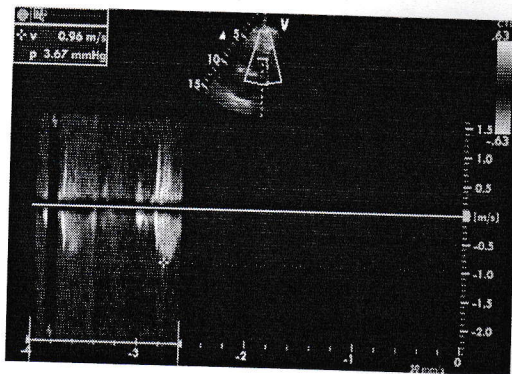
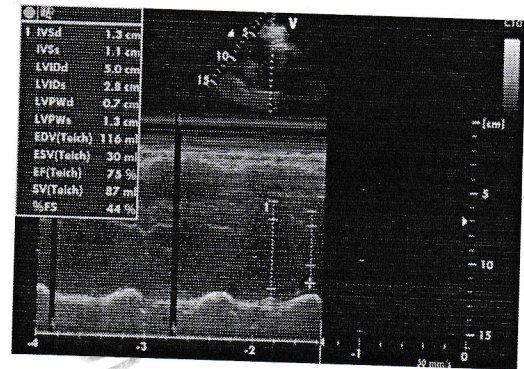
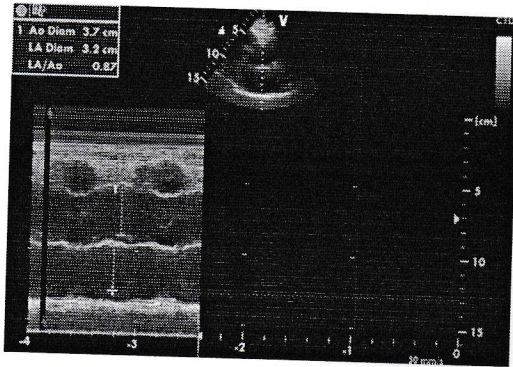
1. Concentric hypertrophy of left ventricle.
2. Normal Valves.
3. No regional wall motion abnormality present.
4. Pericardial effusion - Nil.
5. No pulmonary artery hypertension.



Dr. S. MANIKANDAN. MD.DM.(Cardio)
Cardiologist



Customer Name	MR.PONRAJ P	Customer ID	MED121758987
Age & Gender	50Y/MALE	Visit Date	22/03/2023
Ref Doctor	MediWheel		



10. Function History

- a. Do you have pain or discomfort when lifting or handling heavy objects? Yes No
- b. Do you have knee pain when squatting or kneeling? Yes No
- c. Do you have back pain when forwarding or twisting? Yes No
- d. Do you have pain or difficulty when lifting objects above your shoulder height? Yes No
- e. Do you have pain when doing any of the following for prolonged periods (Please circle appropriate response)
 - Walking : Yes No
 - Kneeling : Yes No
 - Squatting : Yes No
 - Climbing : Yes No
 - Sitting : Yes No
 - Bending : Yes No
 - Standing : Yes No
- f. Do you have pain when working with hand tools? Yes No
- g. Do you experience any difficulty operating machinery? Yes No
- h. Do you have difficulty operating computer instrument? Yes No

B. CLINICAL EXAMINATION :

Chest - Hip - Pulse - 77

a. Height b. Weight Blood Pressure

Chest measurements: a. Normal b. Expanded

Waist Circumference

Skin

Vision

Circulatory System

Gastro-intestinal System

Ear, Nose & Throat

Respiratory System

Nervous System

Genito-urinary System

Colour Vision

Discuss Particulars of Section B :-

C. REMARKS OF PATHOLOGICAL TESTS :

Chest X-ray	<input type="text"/>	ECG	<input type="text"/>
Complete Blood Count	<input type="text"/>	Urine routine	<input type="text"/>
Serum cholesterol	<input type="text"/>	Blood sugar	<input type="text"/>
Blood Group	<input type="text"/>	S.Creatinine	<input type="text"/>

D. CONCLUSION :

Any further investigations required

Any precautions suggested

E. FITNESS CERTIFICATION

Certified that the above named recruit does not appear to be suffering from any disease communicable or otherwise, constitutional weakness or bodily infirmity except _____


. I do not consider this as disqualification for employment in the Company. S

Candidate is free from Contagious/Communicable disease

[Signature]

Signature of Medical Adviser

Date: 22/3/23



THE EYE FOUNDATION

SUPER SPECIALITY EYE HOSPITALS

City Shopping Centre, Kokkirakulam, Trivandrum Road, Tirunelveli - 627 003.

Tel : 0462 435 6655 / 6622

E-mail : tirunelveli@theeyefoundation.com Website : www.theeyefoundation.com

H.O : D.B. Road, Coimbatore - 641 002.



CONSULTANTS :

- Dr. Abiramasundari D
- Dr. Adarsh S Naik
- Dr. Ajay R Kaushik
- Dr. Andrea Jose
- Dr. Ashraya Nayaka T.E
- Dr. Ashwin Segi
- Dr. Aylette Jude Dsilva
- Dr. Chandra Shekar C.S.
- Dr. Chitra Ramamurthy
- Dr. Gautam Kukadia
- Dr. Girish Reddy G.C.
- Dr. Gitansha Shreyas Sachdev
- Dr. Gopal R.
- Dr. Gopinathan G.S
- Dr. Hameed Obedulla
- Dr. Hemanth Murthy
- Dr. Hemamalini
- Dr. Iris
- Dr. Jatinder Singh
- Dr. Jezeela K.
- Dr. Khalid Lateef
- Dr. Krishnan R.
- Dr. Maimunnisa M.
- Dr. Manjula
- Dr. Mohamed Faizal S.
- Dr. Mohd Shahbaaz
- Dr. Mugdha Kumar
- Dr. Muralidhar R.
- Dr. Muralidhar N.S.
- Dr. Nagesh
- Dr. Nikitha
- Dr. Pranesh Ravi
- Dr. Praveen Muraly
- Dr. Preethi
- Dr. Priyanka R.
- Dr. Priyanka Shyam
- Dr. Priyanka Singh
- Dr. Raline Solomon
- Dr. Ramamurthy D.
- Dr. Rashmita Kukadia
- Dr. Rathinasamy V.
- Dr. Ravi J.
- Dr. Romit Sallan
- Dr. Sagar Basu
- Dr. Sahana Manish
- Dr. Sakthi Rajeswari N.
- Dr. Shreesh Kumar K.
- Dr. Shreyas Ramamurthy
- Dr. Shylesh Dabke
- Dr. Soundarya B.
- Dr. Srinivas Rao V.K.
- Dr. Sumanth
- Dr. Sunitha
- Dr. Sushma Poojary
- Dr. Swathi Baliga
- Dr. Tamilarasi S.
- Dr. Thenarasun S.A.
- Dr. Umesh Krishna
- Dr. Vaishnavi M.
- Dr. Vamsi K.
- Dr. Vidhya N.
- Dr. Vijay Kumar S.
- Dr. Visalatchi
- Vishnu Kuppusamy Pounraju

Date: 21/03/23

Eye Fitness Certificate

This is to certify that Mr/Mrs/Ms. Poonraj. P. Age 50 yrs.

Male/Female, our MRNO 13026809

	OD	OS
Visual Acuity	6/6	6/6
Near Vision	N6 C +1.75	N6 C +1.75
Colour Vision	9	9
B.S.V	non	non
Central Fields		
Anterior Segment		
Fundus		

Fit with glasses	✓
Fit without glasses	—
unfit	—

Medical Consultant,
The Eye Foundation,
Tirunelveli.

Dr. PATIL SANDIP DATTA
MBBS, M.S. (OPHTHAL),
REG. NO: G 59864
THE EYE FOUNDATION
TIRUNELVELI.