

Health Check up Booking Request(bobE38914), Beneficiary Code-60454

1 message

Mediwheel <wellness@mediwheel.in>

8 May 2023 at 16:22

To: vidhidiagnostics@gmail.com

Cc: customercare@mediwheel.in



Mediwheel
...Your wellness partner



011-41195959

Email:wellness@mediwheel.in

Dear **VIDHI DIAGNOSTICS,**

City : Ahmedabad . **Address :** L-86 Swatantra - Senani Nagar , Opp- Akhbarnagar Bus Terminals, New Wadaj , Ahmedabad -13,

We have received the confirmation for the following booking .

Name : MRS. VAGADIYA ANITA RAMESHBHAI
Age : 36
Gender : Female
Package Name : Medi-Wheel Metro Full Body Health Checkup Female Below 40
Contact Details : 9737567399
Booking Date : 08-05-2023
Appointment Date : 13-05-2023

Member Information			
Booked Member Name	Age	Gender	Cost(In INR)
MRS. VAGADIYA ANITA RAMESHBHAI	36	Female	Cashless
Total amount to be paid			Cashless

We will get back to you with confirmation update shortly. Please find the package details as attached for your reference.

Package Name : Medi-Wheel Metro Full Body Health Checkup Female Below 40 - Includes (37)Tests

Tests included in this Package : Ecg, TSH, X-ray Chest, Stress Test (tmt)/ 2d Echo, Blood Sugar Postprandial, A:g Ratio, Blood Group, Total Cholesterol, Triglycerides, Fasting Blood Sugar, Ultrasound Whole Abdomen , Glycosylated Haemoglobin (hba1c), Hdl, Vldl, Urine Analysis, LDL, Total Protine, General Consultation, HDL/ LDL ratio, GGT(Gamma-glutamyl Transferase), Eye Check-up consultation, ALP (ALKALINE PHOSPHATASE), Uric Acid, AST/ALT Ratio, Serum Protein, CBC with ESR, Stool Analysis, Urine Sugar Fasting, Urine Sugar PP, T3, T4, Cholesterol Total / HDL Ratio, BUN, BUN/Creatinine Ratio, Bilirubin Total & Direct and Indirect, Albumin, Globulin

LETTER OF APPROVAL / RECOMMENDATION

To,

The Coordinator,
Mediwheel (Arcofemi Healthcare Limited)
Helpline number: 011- 41195959

Dear Sir / Madam,

Sub: Annual Health Checkup for the employees of Bank of Baroda

This is to inform you that the following employee wishes to avail the facility of Cashless Annual Health Checkup provided by you in terms of our agreement.

PARTICULARS	EMPLOYEE DETAILS
NAME	MRS. VAGADIYA ANITA RAMESHBHAI
EC NO.	109667
DESIGNATION	SINGLE WINDOW OPERATOR A
PLACE OF WORK	KALOL, KALOL N G
BIRTHDATE	26-06-1984
PROPOSED DATE OF HEALTH CHECKUP	13-05-2023
BOOKING REFERENCE NO.	23J109667100059204E

This letter of approval / recommendation is valid if submitted along with copy of the Bank of Baroda employee id card. This approval is valid from **08-05-2023** till **31-03-2024**. The list of medical tests to be conducted is provided in the annexure to this letter. Please note that the said health checkup is a **cashless facility** as per our tie up arrangement. We request you to attend to the health checkup requirement of our employee and accord your top priority and best resources in this regard. The EC Number and the booking reference number as given in the above table shall be mentioned in the invoice, invariably.

We solicit your co-operation in this regard.

Yours faithfully,

Sd/-

Chief General Manager
HRM Department
Bank of Baroda



(Note: This is a computer generated letter. No Signature required. For any clarification, please contact Mediwheel (Arcofemi Healthcare Limited))

Medical Examination Report

Date : 13-05-2023

1. Personal Particulars

Name : Anil Sanjay Singh Parmar

Age : 38 years Gender : Male / Female

Marital Status : Married

Past & Present Medical History : H/O LSCS 1st 2007 & 2016

2. Clinical Medical Examination

Height : 150 cm

Weight : 75 kg

Blood Pressure : 114/88 mmHg

Pulse : 70 per p/min

General Condition : Q

Skin : Q

Central Nervous System : Q

Head & Neck : Q

Cardiovascular System : Q

Chest : Q

Abdomen : Q

Limbs : Q

Last menstrual period : -

Vision: : Right: 6/6
N/6

Left: 6/6
N/6

Colour vision : Normal/Colour Blind

Personal Habit : NO

Remarks : Fit / Unfit for employment

Dr. Vidhi D. Madh

Reg. No. 5-74540

Dr's name, signature & chop

Vidhi Diagnostics

L-86, Swatantra-Senani Nagar,
Opp. Akhbarnagar Bus Terminals,
Nr. Akhbarnagar Circle,
New Wada, Ahmedabad 13,

Dr. Dinesh S. Modh

M.D., D.M.R.E. (Radiodiagnosis)

Consultant Radiologist & Sonologist

Ex. Junior Lecturer, B.J. Medical College, Civil Hospital, A'bad.

Panel Doctor of L.I.C.



Patient's name: ANITA SANJAY PARMAR
Reg. ID : R-1671-23
Referred by : Dr. MEDIWHEEL

Age/Sex : 38 Years/Female
Accession : 5414
Date : 13/05/2023

X-RAY CHEST (PA VIEW)

Both lung fields appear normal.
No e/o consolidation or cavitations is seen.
Both costo-phrenic angles appear clear.
Cardiac size is with in normal limits.
Both domes of diaphragm appear normal.
Bony thoracic cage appears normal.

Thanks for reference.

Dr. Dinesh S. Modh
MD DMRE (Radiodiagnosis)

G-23825

DR DINESH S. MODH

M.D. DMRE(RADIODIAGNOSIS)

ISO 9001:2015 Certified Diagnostics Center

Vidhi Imaging Center

L-86, Swatantra Senani Nagar, Opp. Indian Oil Petrol Pump, Akhbarnagar Circle, Nava Vadaj, Ahmedabad - 380 013.

Phone : (Radiology) 079-2762 1406 | M. 98799 29406, 98250 09406 | Time (Radiology) : Mon. to Sat. 9 am to 2 pm, 5 to 9 pm, Sunday 9 am to 12 Noon

E-mail : vidhidiagnostics@gmail.com, Website : www.vidhidiagnostics.com

Multislice CT Scan | CBCT-Dental Scan | Live 3D-4D Sonography | Colour Doppler | Echo Cardiography | Interventional Radiology | Maxillofacial Radiology | Fetal Medicine
Digital X-Ray | Digital Mammography | Digital OPG/TMJ | ECG/TMT/PFT/EEG/EMG | Audiometry | Pathology Laboratory | Health Check Up Plans | Pre Employment Check Up

CT SCAN & CBCT FACILITY NOW AVAILABLE

Dr. Dinesh S. Modh

M.D., D.M.R.E. (Radiodiagnosis)

Consultant Radiologist & Sonologist

Ex. Junior Lecturer, B.J. Medical College, Civil Hospital, A'bad.

Panel Doctor of L.I.C.



Patient's name: ANITA SANJAY PARMAR
Reg. ID : R-1671-23
Referred by : Dr. MEDIWHEEL

Age/Sex : 38 Years/Female
Accession : 5414
Date : 13/05/2023

USG ABDOMEN

LIVER: - Liver appears normal in size & show normal echotexture. No evidence of diffuse or focal lesion is seen. Intrahepatic biliary radicals appear normal. Portal vein and CBD appear normal. No e/o calculus is seen in bile duct.

GALL BLADDER: - Gall bladder is distended & appears normal. No evidence of calculus or cholecystitis is seen. No evidence of pericholecystic fluid is seen.

SPLEEN: - Spleen appears normal in size & shows normal echotexture. No evidence of diffuse or focal lesion is seen.

PANCREAS: - Pancreas appears normal size and echopattern. No e/o diffuse or focal lesion is seen. Main pancreatic duct appears normal.

KIDNEY: - Both Kidneys appear normal in size & echotexture.

No e/o calculus or hydronephrosis or hydroureter is seen in either side.

Cortico-medullary differentiation is maintained on either side.

Both suprarenal regions appear normal.

RIF & BOWEL LOOPS (By high frequency probe): - Normal.

No evidence of pre & para aortic lymphadenopathy is seen.

No evidence of free fluid is seen in abdomen.

No evidence of dilated or thickened bowel loops is seen.

Urinary bladder: - appears normal. No e/o calculus or mass lesion is seen in bladder.

Uterus appears normal in size and echopattern.

No evidence of diffuse or focal lesion is seen.

Cervical region appears normal.

Endometrial thickness is 6.4mm.

Both adnexal regions appear normal.

No e/o free fluid is seen in pouch of Douglas.

Thanks for reference.

Dr. Dinesh S. Modh
MD DMRE (Radiodiagnosis)
G-23825

DR DINESH S. MODH

M.D. DMRE(RADIODIAGNOSIS)

ISO 9001:2015 Certified Diagnostics Center

Vidhi Imaging Center

L-86, Swatantra Senani Nagar, Opp. Indian Oil Petrol Pump, Akharnagar Circle, Nava Vadaj, Ahmedabad - 380 013.

Phone : (Radiology) 079-2762 1406 | M. 98799 29406, 98250 09406 | Time (Radiology) : Mon. to Sat. 9 am to 2 pm, 5 to 9 pm, Sunday 9 am to 12 Noon

E-mail : vidhidiagnostics@gmail.com, Website : www.vidhidiagnostics.com

Multislice CT Scan | CBCT-Dental Scan | Live 3D-4D Sonography | Colour Doppler | Echo Cardiography | Interventional Radiology | Maxillofacial Radiology | Fetal Medicine
Digital X-Ray | Digital Mammography | Digital OPG/TMJ | ECG/TMT/PFT/EEG/EMG | Audiometry | Pathology Laboratory | Health Check Up Plans | Pre Employment Check Up

CT SCAN & CBCT FACILITY NOW AVAILABLE

Dr. Dinesh S. Modh

M.D., D.M.R.E. (Radiodiagnosis)

Consultant Radiologist & Sonologist

Ex. Junior Lecturer, B.J. Medical College, Civil Hospital, A'bad.

Panel Doctor of L.I.C.



Patient's name: ANITA SANJAY PARMAR
Reg. ID : R-1671-23
Referred by : Dr. MEDIWHEEL

Age/Sex : 38 Years/Female
Accession : 5414
Date : 13/05/2023

2D- ECHO REPORT

FINAL CONCLUSION:

LV IS NORMAL SIZE. GOOD LV SYSTOLIC FUNCTION NO RWMA.
LVEF - 60%. NO CONCENTRIC LVH.
NORMAL LV COMPLANCE.
LA IS NORMAL SIZE. NO LA CLOT.
RV IS NORMAL SIZE. GOOD RV SYSTOLIC FUNCTION.
RA IS NORMAL SIZE.
MITRAL VALVE IS NORMAL. NO MS. NO MR. NO MVP.
AORTIC VALVE IS NORMAL. NO AS. NO AR.
TRICUSPID VALVE IS NORMAL. NO TR. RVSP-26 mmHg. NO PAH.

NO CLOT, NO VEGETATION, NO PERICARDIAL EFFUSION.

DIMENSIONS:

AORTA	2.6 C.M
LEFT ATRIUM	2.7 C.M
LVDD	4.1 C.M.
IVSD	1.0 C.M
PWD	1.0 C.M
LVDS	2.6 C.M.

COLOUR DOPPLER FINDING:

STRUCTURE	VELOCITY m/sec
	Max
PULMONARY VALVE	0.7
MITRAL VALVE	E : 0.7 A: 0.4
AORTIC VALVE	1.0


Dr. Avinash Bhaskar
MBBS D-Cardio
G-45946
DR AVINASH BHASKAR

ISO 9001:2015 Certified Diagnostics Center

Vidhi Imaging Center

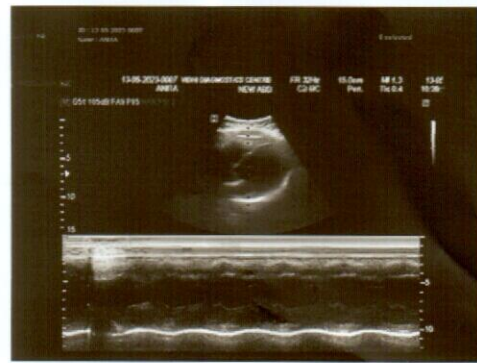
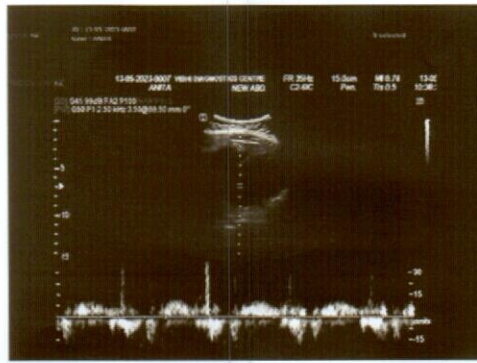
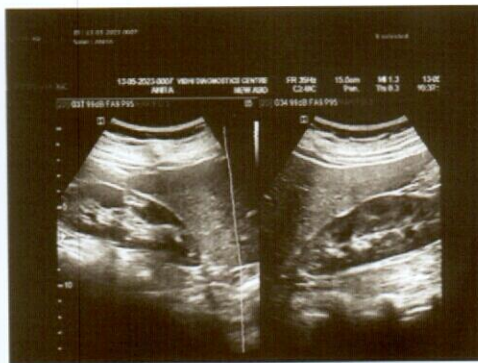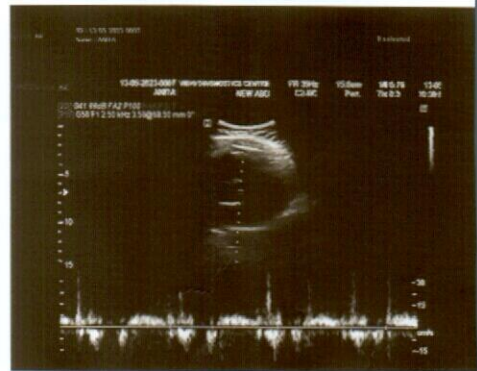
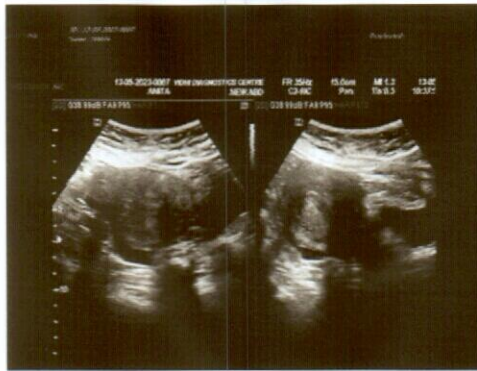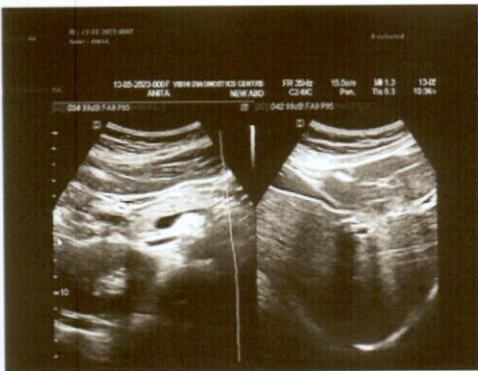
L-86, Swatantra Senani Nagar, Opp. Indian Oil Petrol Pump, Akhbar Nagar Circle, Nava Vadaj, Ahmedabad - 380 013.

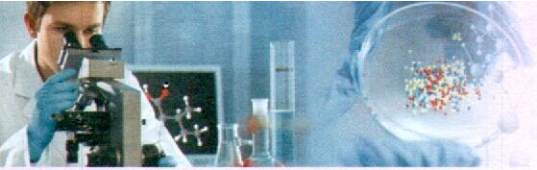Phone : (Radiology) 079-2762 1406 | M. 98799 29406, 98250 09406 | Time (Radiology) : Mon. to Sat. 9 am to 2 pm, 5 to 9 pm, Sunday 9 am to 12 Noon

E-mail : vidhidiagnostics@gmail.com, Website : www.vidhidiagnostics.com

Multislice CT Scan | CBCT-Dental Scan | Live 3D-4D Sonography | Colour Doppler | Echo Cardiography | Interventional Radiology | Maxillofacial Radiology | Fetal Medicine
Digital X-Ray | Digital Mammography | Digital OPG/TMJ | ECG/TMT/PFT/EEG/EMG | Audiometry | Pathology Laboratory | Health Check Up Plans | Pre Employment Check Up

CT SCAN & CBCT FACILITY NOW AVAILABLE





Pathology Department



Patient's name : ANITA SANJAYSINH PARMAR
Age/Sex : 38 Years/Female
Referred by : Dr. MEDIWHEEL
Collection Time : 09:22

Reg. ID : P-770-23
Accession : 5397
Order Dt/time : 13/05/2023 09:22

Blood Glucose

Sample Type: Serum

Test Name	Result	Units	Biological Reference Interval
Fasting Blood Glucose : <i>GOD-POD Method.</i>	100.7	mg/dl	70 - 110

Blood Glucose

Sample Type: Serum

Test Name	Result	Units	Biological Reference Interval
Post Prandial Blood Glucose After 2hr. : <i>GOD-POD Method.</i>	127.2	mg/dl	80 - 140

Dr. Gayatri M. Mehta
M. D. (Patho)
Reg. No. G-32215

DR GAYATRI MEHTA
MD(PATHOLOGY)

DR. ANAND D. PARIKH
MD(PATHOLOGY)

LAB USE ONLY (Entered by :GM Enter Date/Time:13/05/2023 7:50:00 PM) (Verify by :GM Verify Date/Time:13/05/2023 7:50:00 PM)

ISO 9001:2015 Certified Diagnostics Center

Vidhi Imaging Center | Pathology Department

L-86, Swatantra Senani Nagar, Opp. Akhbar Nagar Petrol Pump, Nr. Akhbar Nagar Circle, Nava-Vadaj, Ahmedabad - 380 013.

Ph. (Pathology) : 079-2762 1406, 8849893954 M. 98799 29406, 98250 09406, E-mail : vidhidiagnostics@gmail.com, Web. : www.vidhidiagnostics.com

Time (Pathology) : Mon. to Sat. 8.30 am to 8.00 pm, Sunday 9 am to 12 Noon

Pathology means science behind medicine

CT SCAN & CBCT FACILITY NOW AVAILABLE



Pathology Department

Patient's name : ANITA SANJAYSINH PARMAR
 Age/Sex : 38 Years/Female
 Referred by : Dr. MEDIWHEEL
 Collection Time : 09:22

Reg. ID : P-770-23
 Accession : 5397
 Order Dt/time : 13/05/2023 09:22

HbA1C

Sample Type: Serum

Test Name	Result	Units	Biological Reference Interval
HbA1C :	5.2	%	Non-diabetic: 4.2-6.2 Pre-diabetic : 6.3-7.2 Diabetic : 7.3-8.2
Mean Blood Glucose of Last 03 months.	103	mg/dl	

Comment

*As per the new 2009 update of American Diabetes Association regarding HbA1C & Mean Blood Glucose relationship.
 NOTE: This test is used to monitor diabetic patients compliance with the therapeutic regimen and logo It's level is proportional to both the average blood glucose concentration and the life span of the red blood cells (RBC) in circulation. HbA1c values are free of day to day glucose fluctuations and are unaffected by exercise or recent food intake.

Dr. Gayatri M. Mehta
 M. D. (Patho)

Reg. No. G-22215
 DR GAYATRI MEHTA
 MD(PATHOLOGY)

DR. ANAND D. PARIKH
 MD(PATHOLOGY)

LAB USE ONLY (Entered by :GM Enter Date/Time:13/05/2023 7:49:00 PM) (Verify by :GM Verify Date/Time:13/05/2023 7:49:00 PM)

ISO 9001:2015 Certified Diagnostics Center

Vidhi Imaging Center | Pathology Department

L-86, Swatantra Senani Nagar, Opp. Akhbaragar Petrol Pump, Nr. Akhbaragar Circle, Nava-Vadaj, Ahmedabad - 380 013.

Ph. (Pathology) : 079-2762 1406, 8849893954 M. 98799 29406, 98250 09406, E-mail : vidhidiagnostics@gmail.com, Web. : www.vidhidiagnostics.com

Time (Pathology) : Mon. to Sat. 8.30 am to 8.00 pm, Sunday 9 am to 12 Noon

Pathology means science behind medicine

CT SCAN & CBCT FACILITY NOW AVAILABLE

CT SCAN & CBCT FACILITY NOW AVAILABLE

CT SCAN & CBCT FACILITY NOW AVAILABLE

CT SCAN & CBCT FACILITY NOW AVAILABLE



Creating Life in Science

Pathology Department

Patient's name : ANITA SANJAYSINH PARMAR
Age/Sex : 38 Years/Female
Referred by : Dr. MEDIWHEEL
Collection Time : 09:22

Reg. ID : P-770-23
Accession : 5397
Order Dt/time : 13/05/2023 09:22

Complete Blood Count

Sample Type: EDTA

Test Name	Result	Units	Biological Reference Interval
<u>Blood Counts</u>			
Haemoglobin :	9.3	Gms%	12.5 - 16.0
Total R.B.C. :	4.88	mill/c.mm	4.2 - 5.4
Total W. B. C. :	5110	/cu mm	4000 - 10500
Platelet Count :	315000	/cu.mm	1,50,000 - 4,50,000
<u>Differential Count</u>			
Neutrophils :	60	%	40 - 70
Lymphocytes :	35	%	20 - 40
Eosinophils :	03	%	1 - 4
Monocytes :	02	%	2 - 6
Basophils :	00	%	0 - 01
<u>Blood Indices</u>			
P. C. V :	29.4	%	37 - 47
M. C. V. :	60.2	fl	78 - 100
M.C.H :	19.1	pg	27 - 31
M. C. H. C :	31.6	%	32 - 36
R.D.W :	16.6	%	11.5 - 14.0
<u>E.S.R.(Westergren Method)</u>			
After one hour :	10	mm/hr	3 - 12

TESTS DONE ON FULLY AUTOMATED HEMATOLOGY ANALYZER.

Dr. Gayatri M. Mehta

M. D. (Patho)

Reg. No. G-32215
DR GAYATRI MEHTA
MD(PATHOLOGY)

DR. ANAND D. PARIKH
MD(PATHOLOGY)

LAB USE ONLY (Entered by :GM Enter Date/Time:13/05/2023 7:49:00 PM) (Verify by :GM Verify Date/Time:13/05/2023 7:49:00 PM)

ISO 9001:2015 Certified Diagnostics Center

Vidhi Imaging Center | Pathology Department

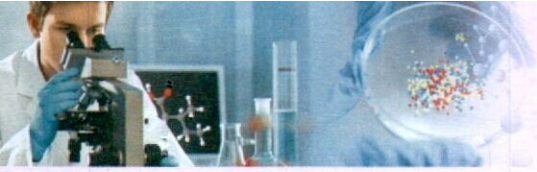L-86, Swatantra Senani Nagar, Opp. Akhbarnagar Petrol Pump, Nr. Akhbarnagar Circle, Nava-Vadaj, Ahmedabad - 380 013.

Ph. (Pathology) : 079-2762 1406, 8849893954 M. 98799 29406, 98250 09406, E-mail : vidhidiagnostics@gmail.com, Web. : www.vidhidiagnostics.com

Time (Pathology) : Mon. to Sat. 8.30 am to 8.00 pm, Sunday 9 am to 12 Noon

Pathology means science behind medicine

CT SCAN & CBCT FACILITY NOW AVAILABLE



Pathology Department



Patient's name : ANITA SANJAYSINH PARMAR
Age/Sex : 38 Years/Female
Referred by : Dr. MEDIWHEEL
Collection Time : 09:22

Reg. ID : P-770-23
Accession : 5397
Order Dt/time : 13/05/2023 09:22

Blood Group

Sample Type: EDTA sample.

Test Name	Result
BG :	" B "
RH :	POSITIVE
Remarks	Done by forward grouping method.

Dr. Gayatri M. Mehta
M. D. (Patho)
Reg. No. G-32215
DR GAYATRI MEHTA
MD(PATHOLOGY)

DR. ANAND D. PARIKH
MD(PATHOLOGY)

LAB USE ONLY (Entered by :GM Enter Date/Time:13/05/2023 7:48:00 PM) (Verify by :GM Verify Date/Time:13/05/2023 7:48:00 PM)

ISO 9001:2015 Certified Diagnostics Center

Vidhi Imaging Center | Pathology Department

L-86, Swatantra Senani Nagar, Opp. Akhbarnagar Petrol Pump, Nr. Akhbarnagar Circle, Nava-Vadaj, Ahmedabad - 380 013.

Ph. (Pathology) : 079-2762 1406, 8849893954 M. 98799 29406, 98250 09406, E-mail : vidhidiagnostics@gmail.com, Web. : www.vidhidiagnostics.com

Time (Pathology) : Mon. to Sat. 8.30 am to 8.00 pm, Sunday 9 am to 12 Noon

Pathology means science behind medicine

CT SCAN & CBCT FACILITY NOW AVAILABLE


Dr. Dinesh S. Modh

M.D., D.M.R.E. (Radiodiagnosis)

Consultant Radiologist & Sonologist

Ex. Junior Lecturer, B.J. Medical College, Civil Hospital, A'bad.

Panel Doctor of L.I.C.



Anita BOD - 109667

9737567399

અનિતા બોડ - ૧૦૯૬૬૭

Dr. Modh

ISO 9001:2015 Certified Diagnostics Center

Vidhi Imaging Center, L-86, Swatantra Senani Nagar, Opp. Akhbarnagar Petrol Pump, Nr. Akhbarnagar Circle, Nava-Vadaj, Ahmedabad - 380 013.

Phone : 079-2762 1406, Mobile : 98799 29406, 98250 09406, E-mail : vidhidiagnostics@gmail.com, Website : www.vidhidiagnostics.com

FACILITIES : Live 3D-4D Sonography | Colour Doppler | Echo Cardiography | Interventional Radiology | Fetal Medicine | Digital X-Ray
Digital Mammography | Digital OPG / TMJ | ECG / TMT / PFT / EEG / EMG | Pathology Laboratory | Health Check Up Plans | Pre Employment Check Up

Handwritten signature



Dr. Vidhi D. Modh
MBBS
Reg. No. G-74540

Vidhi Diagnostics
L-86, Swatantra-Senani Nagar,
Opp. Akhbarnagar Bus Terminals,
Nr. Akhbarnagar Circle,
New Wadaj, Ahmedabad-13,



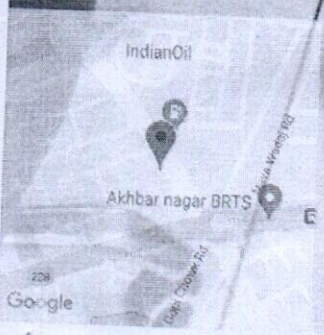Saturday, 13 May 2023 9:28 am

**Akhbar Nagar Circle
Nava Vadaj
Ahmedabad**

Gujarat

Altitude:-66.6ft

Index number: 224



Vidhi Diagnostics
L-86, Swatantra-Senani Nagar,
Opp. Akhbar Nagar Bus Terminals,
Nr. Akhbar Nagar Circle,
New Vadaj, Ahmedabad-13.

Dr. Vidhi D. Modh

MBBS
Reg. No. G-74540

HR : 70 bpm
 PR : 126 ms
 QRS : 90 ms
 QT/QTc : 382/412 ms
 P/QRS/T : 60/7/-16 deg.
 RV5/SV1 : 1.242/-0.983 mv
 RV5+SV1 : 2.225 mv

ID: 9275
 Name: anita sanjaysinh parmar
 Age: 38yrs
 Sex: Female
 Hospital: **Dr. Avinash Bhosrat**
MBBS D-Cardio
G-45946

Vidhi Diagnostics
 L-86, Swatantra-Senani Nagar,
 Opp. Akhbarnagar Bus Terminals,
 Nr. Akhbarnagar Circle,
 New Wadaj, Ahmedabad-13,

Need to be confirmed by doctor. Doctor Name: _____

0.67Hz - 35Hz AC 50Hz 25 mm/s 10 mm/mv

