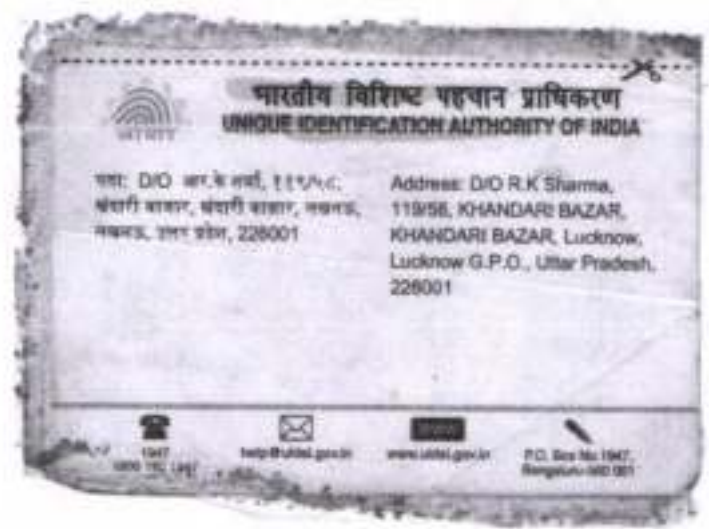



Devanshi Bhatt



MALIK RADIX HEALTH CARE PVT. LTD.
 C-217, C-218, Nirman Vihar,
 Delhi-110092
 Ph.: 011-49287456, 011-61381379
 Regd. No. 607



CONSULTANTS ON PANEL

PAEDIATRICS

Dr. Rav Malik (MBBS, MD)
Dr. Heli Prasad (MBBS, MD, FCF)
Dr. Ritu Jain (MBBS, MD)

GYNAECOLOGY

Dr. Renu Malik (MBBS, MD)
Dr. Meena Mathuria (MBBS, MD)
Dr. Raju (MBBS, MD)

Dr. Manu Gupta (MBBS, MD)
Dr. Vanshika Saini (MBBS, DGO)
Dr. Rupam Arora (MBBS, MD)

DENTAL

Dr. Shrut Malik (BDS, MEd)
Dr. Arnu Saini (BDS, MEd)
Dr. Rishi Thakur (BDS, MEd)
Dr. Mohit Mangla (BDS, MEd)
Dr. Tarun Mittal (BDS, MEd)
Dr. Geetika Sharma (BDS)
Dr. Shilpa Verma (BDS)

CHILD GASTROENTEROLOGY

Dr. T. K. Mittal (MBBS, MD)

MEDICINE

Dr. A. S. Talwar (MBBS, MD)
Dr. Sunny Uppal (MBBS, MD)
Dr. Surendra Rajpal (MBBS, MD)

RESPIRATORY MEDICINE / PULMONOLOGY

Dr. Abhinav Sharma (MBBS, DNB)

LAPAROSCOPIC SURGERY

Dr. Ajay Jain (MBBS, MD)
Dr. Deepak Saran (MBBS, MD)
Dr. Pradeep Saini (MBBS, MD)

ORTHOPAEDICS

Dr. Vikas Shrivastava (MBBS, MS, DOrtho, DNB)
Dr. Prabhat Aggarwal (MBBS, MS, DOrtho)
Dr. M. Tawar (MBBS, MS, DOrtho)
Dr. Deepak Kumar Arora (MBBS, MS, DOrtho)

EYE/OPTHALMOLOGY

Dr. Siddhi Gupta (MBBS, MS, DNB, FRCO)
Dr. Himanshu Singh-Pandey (MBBS, MD)

ENT

Dr. Sharan Kumar Singh (MBBS, MD)
Dr. Praveen Sharma (MBBS, MD)
Dr. Ashok Singh (MBBS, MD)

RADIOLOGY (ULTRASOUND)

Dr. K. K. Sirohi (MBBS, DNB)
Dr. T. K. Verma (MBBS, MD)
Dr. Neesh Mathuria (MBBS, MD)
Dr. Ashok Kumar (MBBS, MD)

PATHOLOGY

Dr. Neema Datta (MBBS, MD, FRCG)
Dr. Meenu Aggarwal (MBBS, MD, FRCG)

ANAESTHESIA

Dr. Rakesh Dhall (MBBS, MD)
Dr. Rajesh Arora (MBBS, MD)
Dr. R. K. Arora (MBBS, MD)

DERMATOLOGY

Dr. Niharika Jha (MBBS, MD)

PLASTIC & COSMETIC SURGERY

Dr. Anshu Jain (MBBS, MCh, MCh)

PAEDIATRIC SURGERY

Dr. Sharmista Singh (MBBS, MCh, MCh)
Dr. Satish Aggarwal (MBBS, MCh, MCh)

PAEDIATRIC NEPHROLOGY

Dr. A. S. Wadhwa (MD, Dip. in Paed)

NEPHROLOGY

Dr. Javed (MBBS, MD, Nephro)

CARDIOLOGY

Dr. Nishant Tyagi (MBBS, MD)

NEUROLOGY

Dr. Anil Bhatia (MBBS, MD)

GASTROENTEROLOGY

Dr. Deepak Leelan (MBBS, MD)
Dr. Naresh Aggarwal (MBBS, MD)
Dr. Ashok Goyal (MBBS, MD)
Dr. Akur Singh (MBBS, MD)

UROLOGY

Dr. Mihir Sharma (MBBS, MCh)
Dr. Akur Singh (MBBS, MD)

PSYCHIATRY

Dr. Manoj Sharma (MBBS, MD)

PHYSIOTHERAPY

Dr. Kirti Dwivedi
Dr. Raj Kumar

NUTRITIONIST

Dr. Deepika Kishor
Dr. Sakshi Rana

CLINICAL PSYCHOLOGIST

Dr. Sarika Singh

Dr. Shruti Malik

BDS, MDS (Endodontics)
(+91-9899561092)

**Timings : 10:00 am. to 2:00 pm.
6:00 pm. to 8:30 pm.**

CLINICAL EXAMINATION:-

1. TMJ:-

Routine dental check up

2. DENTAL STATUS:

- a. Caries Teeth : 0/e.
- b. Fracture Teeth :
- c. Root Stumps :
- d. Gingivitis :
- e. Periodontitis :
- f. Impacted Teeth :
- g. Malaligned Teeth :

Stains ++

Calculus ++

- Reduced mouth opening.

- Blanching present on bilateral buccal mucosa.

3. ORAL LESIONS:-

4. DIAGNOSIS:-

- Palpable fibrous bands present on bilateral buccal.

5. TREATMENT PLANNING:

mucosa.

6. FOLLOW UP:-

1/10 - OSMF

Referral To Other Consultant: Yes/ No

Investigat - Biopsy

If Yes, please mention the Name:

Adv - Oral prophylaxis

Investigat

Doctor's Signature

Shruti

Facilities Available :

- * MULTI-SPECIALITY HOSPITAL * MODULAR FULLY EQUIPPED OT * NURSERY * LAPROSCOPIC SURGERY
- * 24X7 EMERGENCY * OPG * DENTAL * 24X7 DIAGNOSTICS * LABOUR ROOM * ECHO * EEG * DIGITAL X-RAY * CT SCAN
- * ECG * ULTRASOUND * RICU/ICU * ALL SPECIALITY OPD * PLASTIC & COSMETIC SURGERY * DIALYSIS * PHARMACY



Name - Mr. Devanshi Bhatt
Age - 32 yrs / female

14/02/2024

VA 6/6 ✓
GS 6/6 ✓

WSP 8x72y
Last dated 3-week
back

Neck thk 26
28

Color th ! 40L


Dr. Nishi Gupta
MBBS, MS, DNB
Consultant Ophthalmologist
Malik Radix Healthcare Pvt. Ltd.
DMC No. 121661

Facilities Available

Multispecialty Hospital - 24 Hours Emergency - X-Ray/ ECG/ Ultrasound/ CT Scan - Dental - Fully Equipped Operation Theatre
Fully Functional Lab - 24/7 Casualty/ ICU/ Nursery - 24/7 Pharmacy - Labour Room - All Speciality OPD - Laparoscopic Surgery -
ECHO - Plastic Surgery

Devanshi Bhatt

MALIK RADIX HEALTHCARE PVT LTD
UNI-EMC-217/218 NIRMAN VIHAR VIKAS MARG
DELHI 110092

DEVANSHI BHATT

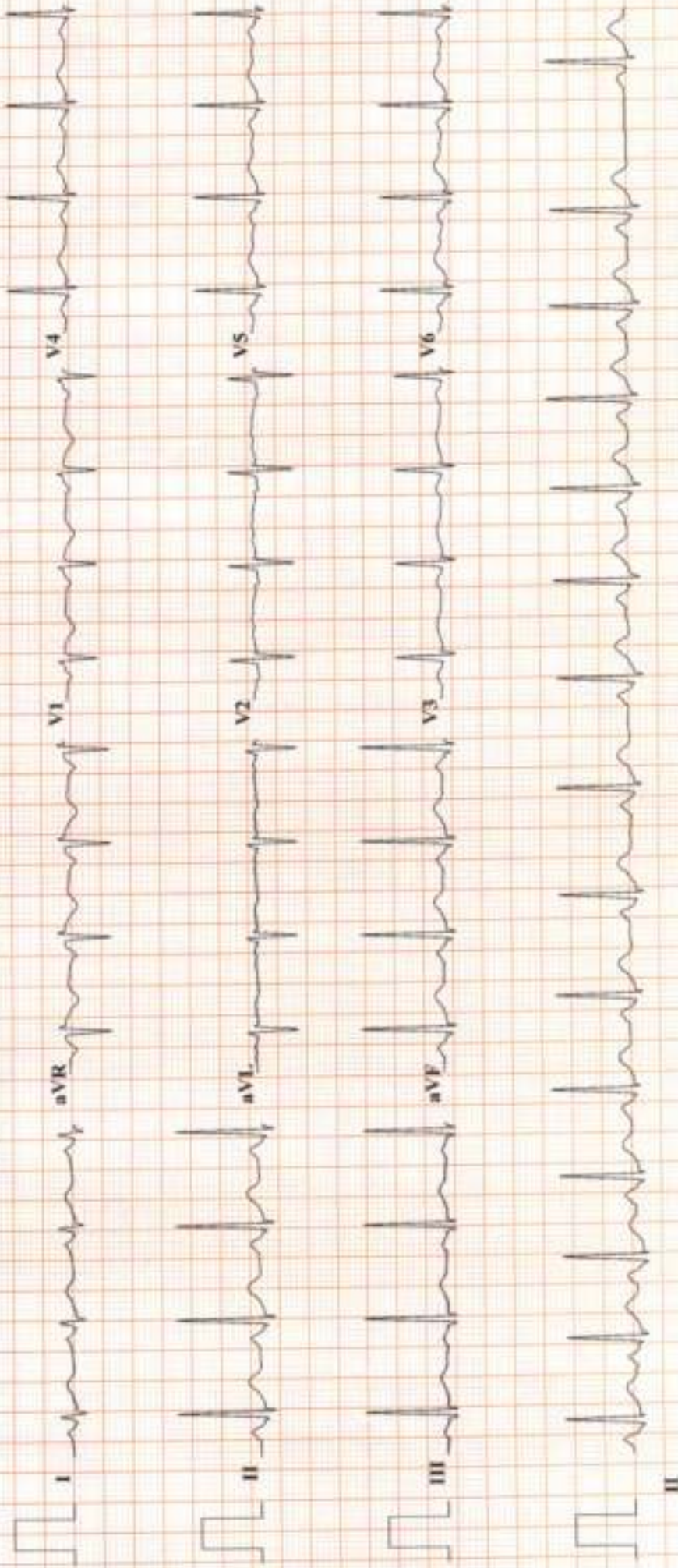
L.D. : 2855
AGE/SEX : 32 Yr - F
HT/WT : / /
DATE : 14-02-2024 03:16:09 PM
REF BY : Dr

MACHINE INTERPRETATION : Normal ECG.

RATE : 97 bpm
BP : N/A
P Axis : -49 deg.
QRS Axis : 85 deg.
T Axis : 57 deg.

P Duration : 119 ms
PR Duration : 135 ms
QRS Duration : 82 ms
QT Interval : 320 ms
QTc Interval : 376 ms

Linked Median
Speed : 25 mm/s
Sensitivity : 10 mm/mV



Devanshi Bhatt

RADIX MALIK HOSPITAL
RADIX MALIK HOSPITAL
NIRMAN VIHAR DELHI 110092

DEVANSHI BHATT

ID : 2398
DATE : 14-02-2024
AGE/SEX : 32 / F
HT/WT : 0 / 0
REF. BY :

TREADMILL TEST REPORT

PROTOCOL : Bruce
HISTORY :
INDICATION :
MEDICATION :

PHASE	TOTAL TIME	STAGE TIME	SPEED Km/Hr	GRADE %	H.R. bpm	B.P. mmHg	RPP x100	ST LEVEL (MM)			METS
								II	V1	V5	
SUPINE					105	110 / 70	115	0	-0.2	0	0
STANDING					104	110 / 70	114	0.1	-0.2	-0.1	-0.1
HYPERTENT					95	110 / 70	104	0.1	-0.1	-0.1	-0.1
Stage 1	2:55	0:10	2.7	10	168	114 / 70	191	-0.2	0.1	-0.2	4.67
Stage 2	5:55	2:55	4	12	175	120 / 70	211	-0.2	-0.1	0	7.04
PK-EXERCISE	6:41	0:41	5.4	14	181	126 / 70	228	0.3	-0.3	-0.1	7.76
RECOVERY	9:44	2:55			111	120 / 70	133	-0.2	0	-0.1	-0.1
RECOVERY	12:44	5:55			105	116 / 70	121	0.2	-0.1	0.1	0.1

RESULTS

EXERCISE DURATION : 6:41
MAX HEART RATE : 185 bpm
MAX BLOOD PRESSURE : 126 / 70 mm Hg
REASON OF TERMINATION :

MAX WORK LOAD : 7.76 METS

BP RESPONSE :
ARRHYTHMIA :
H.R. RESPONSE :

IMPRESSIONS

98 % of target heart rate
-THR Achieved.

None.

TMT is Negative for provokable myocardial ischemia.

Dr SHEKH NAZIR AHMED
M.D. "Physician"
PGDCC
DMC-48499

Technician :

RADIX MALIK HOSPITAL

ST @ 10mm/mV
80ms PostJ

PRETEST
SUPINE

RATE 105bpm
B.P. 110/70

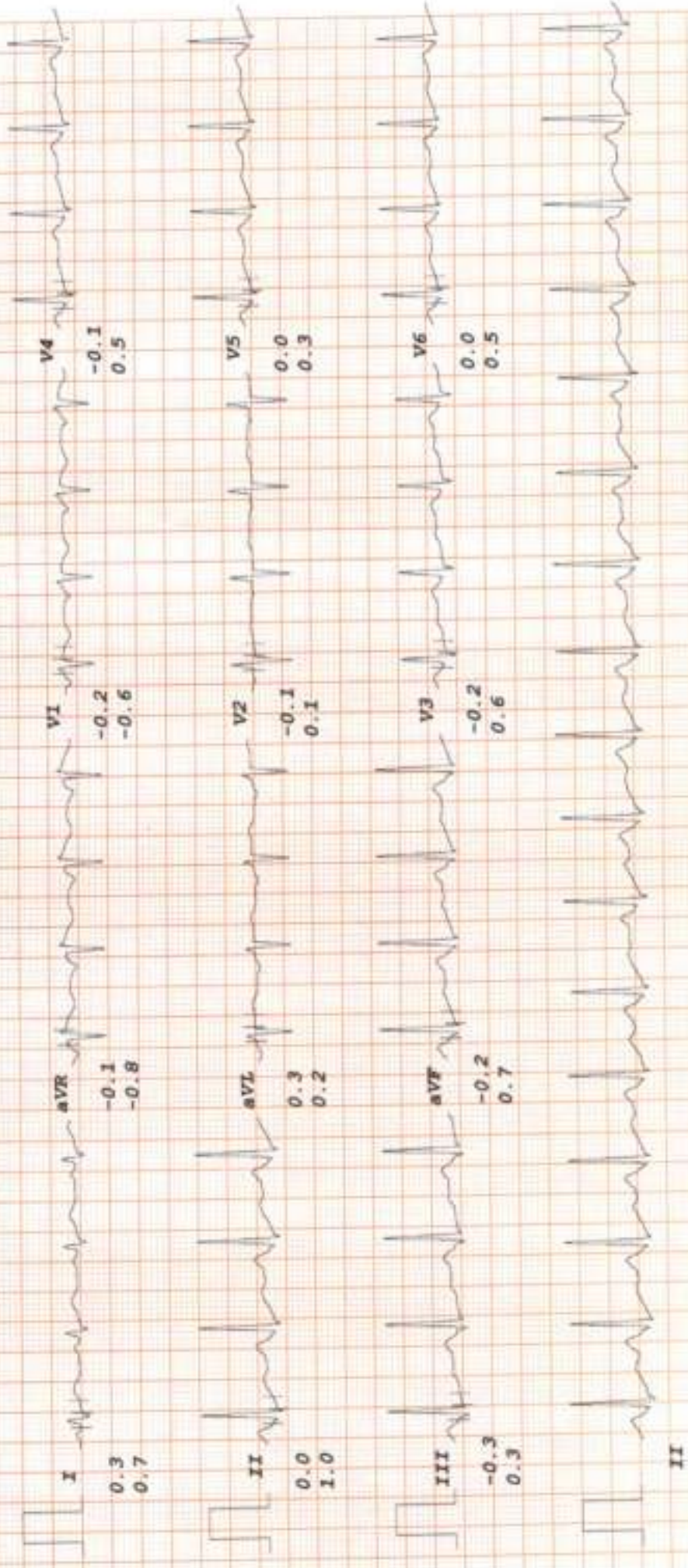
DEVANSHI BHATT

I.D. 2398

Age 32/F

Date 14-02-2024

LINKED MEDIAN



RADIX MALIK HOSPITAL

DEVANSHI BHATT

I.D. 2398

Age 32/F

Date 14-02-2024

RATE 104bpm

H.P. 110/70

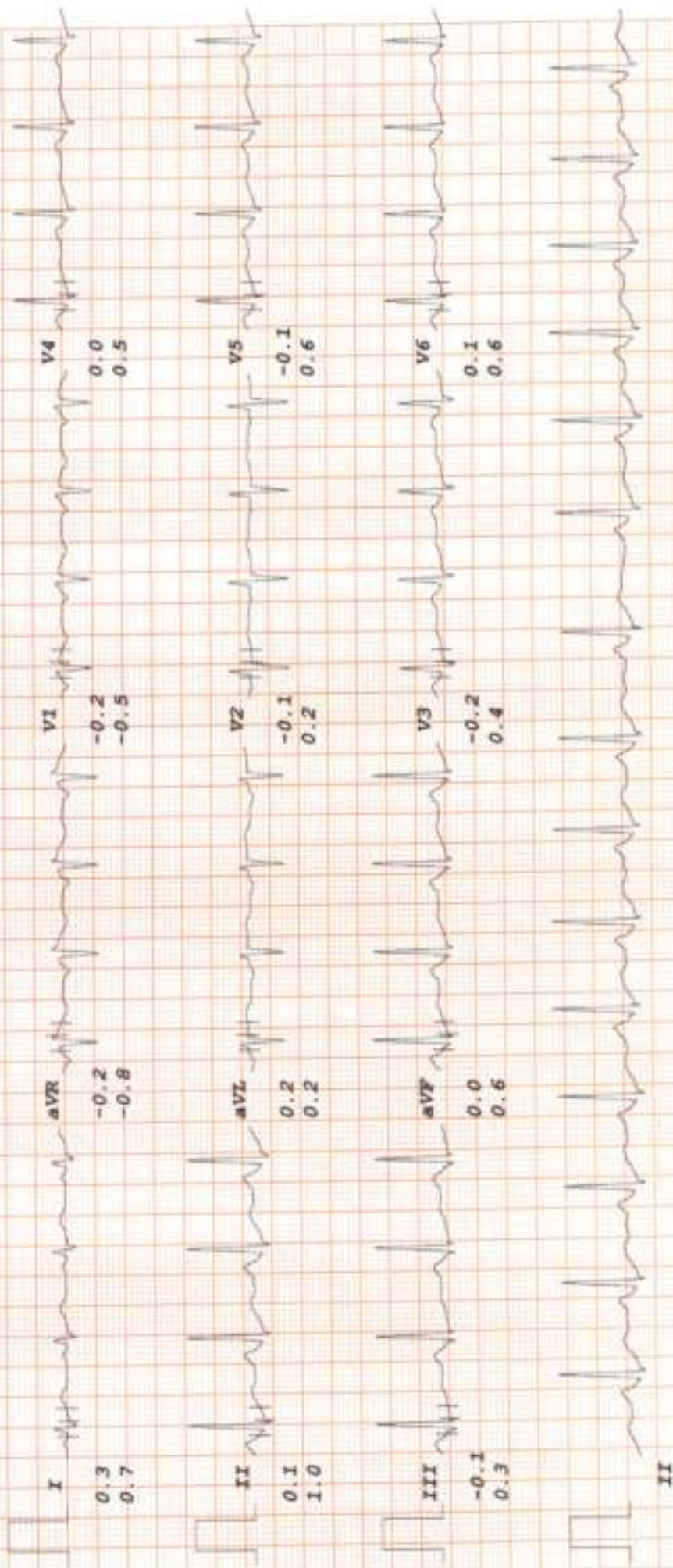
PRETEST

STANDING

ST @ 10mm/mV

80ms PostJ

LINKED MEDIAN



RADIX MALIK HOSPITAL

DEVANSHI BHATT

I.D. 2398

Age 32/F

Date 14-02-2024

RATE 95bpm

B.P. 110/70

PRETEST

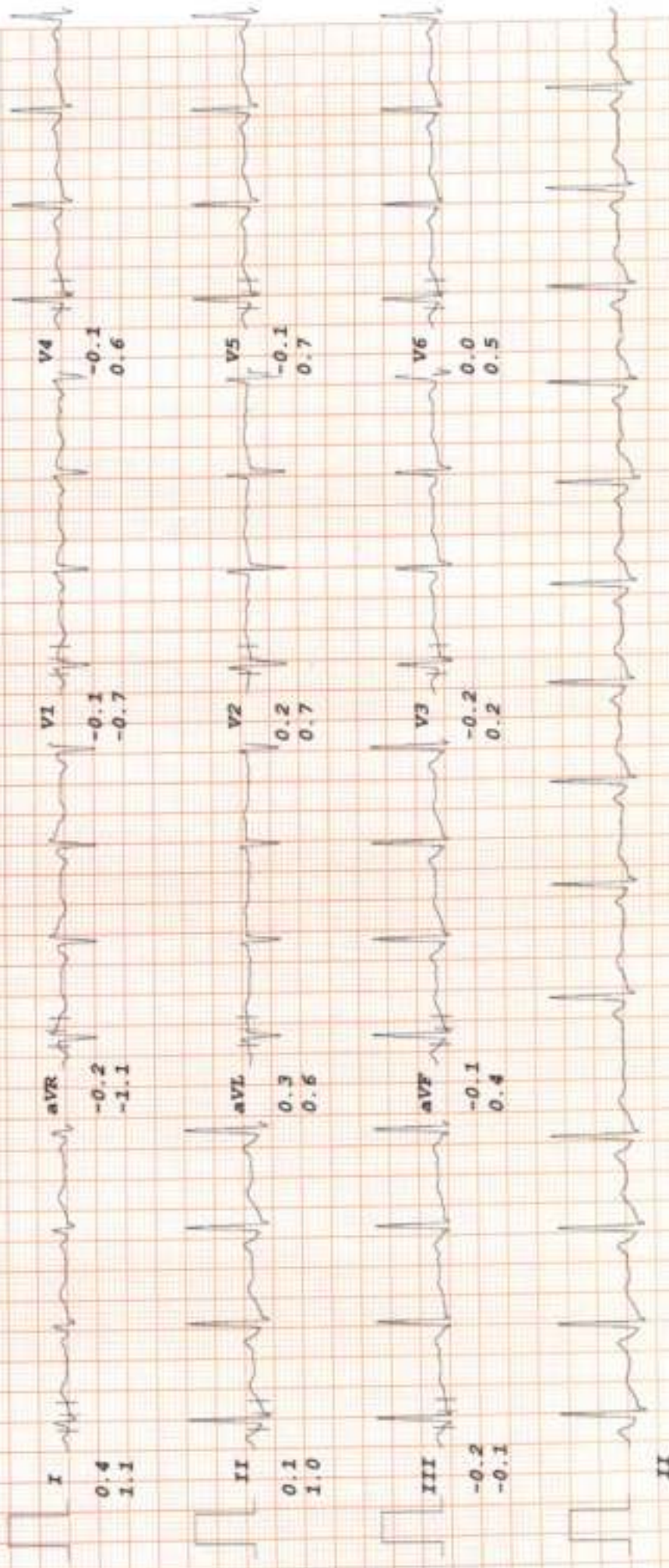
HYPERTENT

PHASE TIME 0:10

ST @ 10mm/mV

80ms PostJ

LINKED MEDIAN



RADIX MALIK HOSPITAL

DEVANSHI BHATT

I.D. 2398

Age 32/F

Date 14-02-2024

Bruce

RATE 181bpm

B.P. 126/70

PK-EXERCISE

TOTAL TIME 6:41

PHASE TIME 0:41

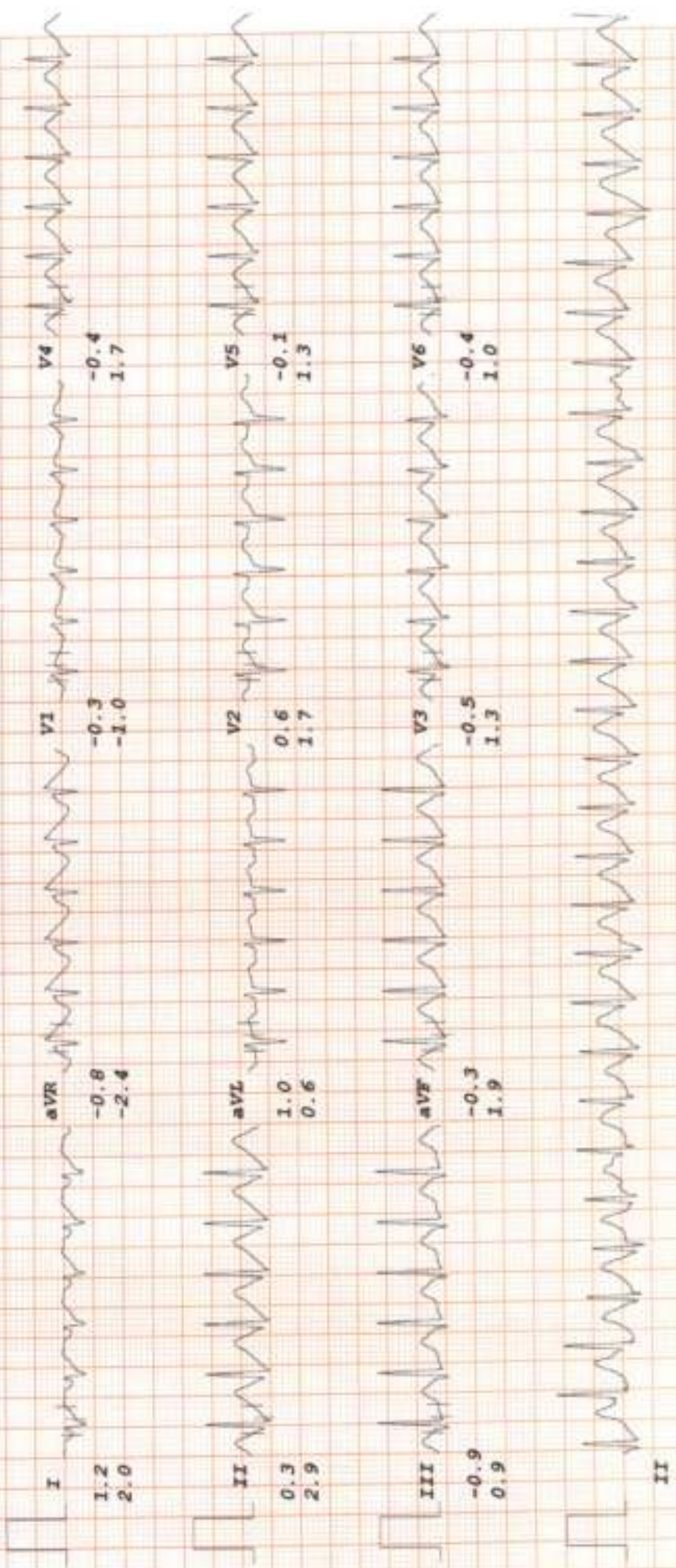
ST @ 10mm/mV

80ms PostJ

Speed 5.4 km/hr

SLOPE 14%

LINKED MEDIAN



RADIX MALIK HOSPITAL

DEVANSHI BHATT

I.D. 2398

Age 32/F

Date 14-02-2024

RATE 111bpm

B.P. 120/70

BRUCE

RECOVERY

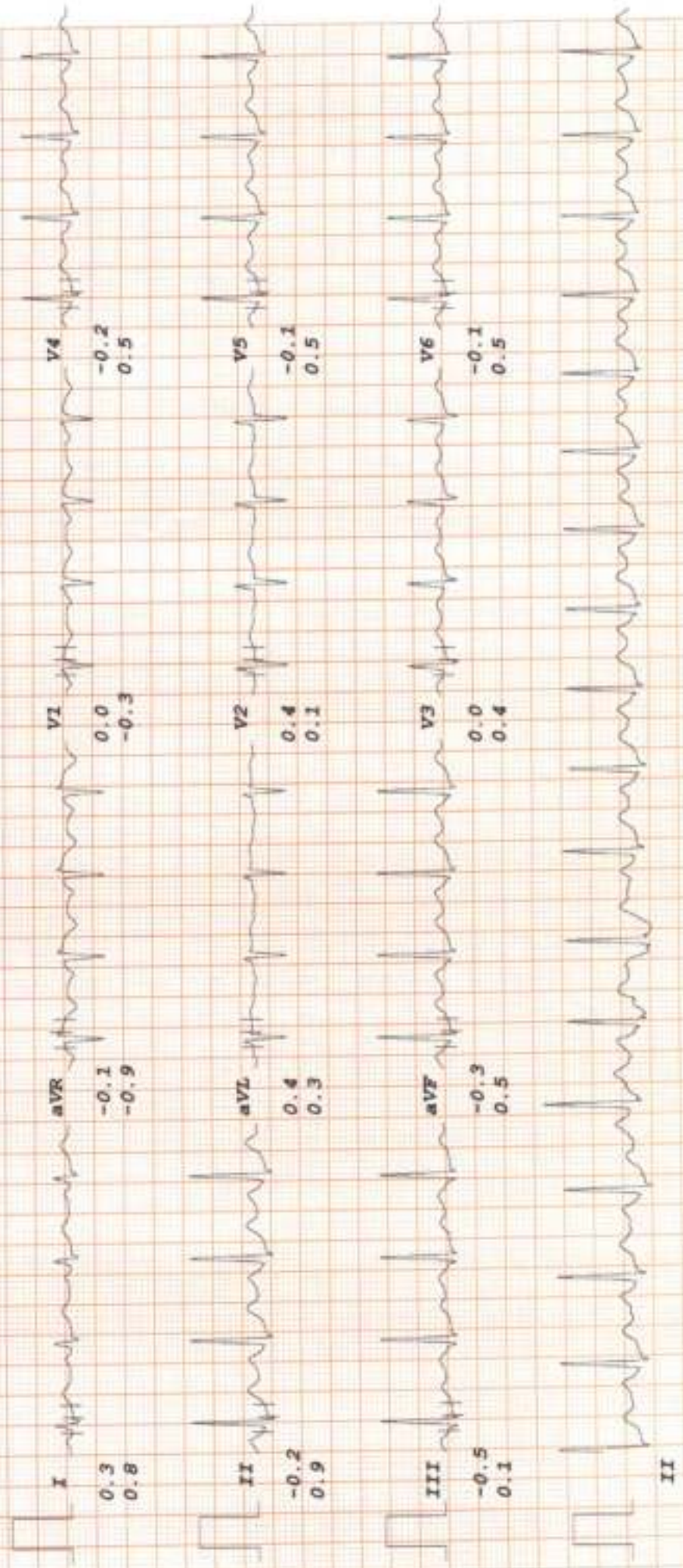
TOTAL TIME 9:44

PHASE TIME 2:55

ST @ 10mm/mV

80ms Post-J

LINKED MEDIAN



RADIX MALIK HOSPITAL

DEVANSHI BHATT

I.D. 2398

Age 32/F

Date 14-02-2024

RATE 105bpm

B.P. 116/70

Bruce

RECOVERY

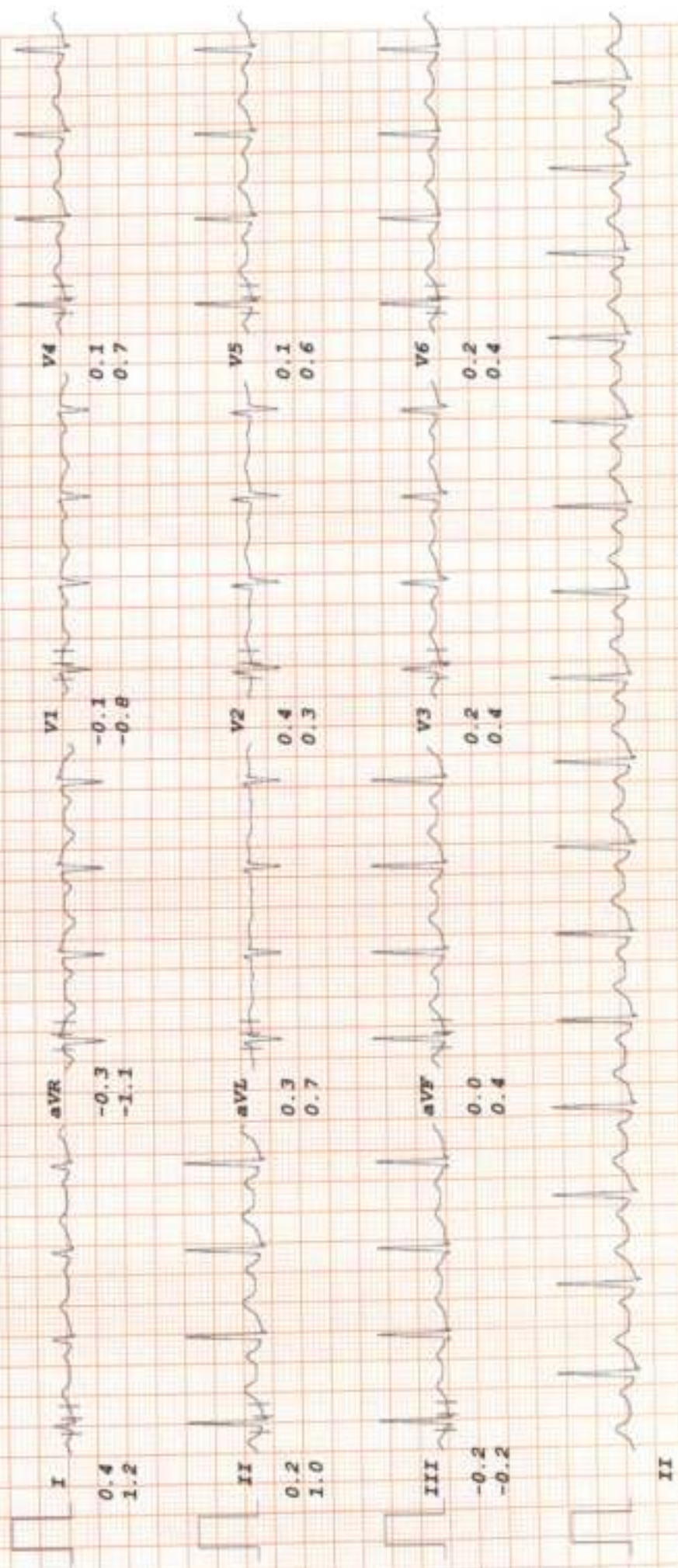
TOTAL TIME 12:44

PHASE TIME 5:55

ST @ 10mm/mV

80ms PostJ

LINKED MEDIAN





LAB REPORT

Reg. Date	14/02/2024	Patient Id	2402140002	DOB.	
Name	MRS. DEVANSHI BHATT	Gender	F	Perm. ID	
Age	32 Yrs.	Panel	MEDIWHEEL	Reported	16/02/2024 16:45:06
Ref. By	MEDIWHEEL				

Test Name	Result	Units	Ref. Range
-----------	--------	-------	------------

MEDIWHEEL ANNUAL PLUS CHECK

HAEMATOLOGYCOMPLETE HAEMOGRAM

HAEMOGLOBIN (HB%)	10.2	gm/dl	12 - 15
TOTAL LEUCOCYTE COUNT (TLC)	5,200	/cumm	4000 - 11000
<u>DIFFERENTIAL LEUCOCYTE COUNT (DLC)</u>			
NEUTROPHIL	72	%	40 - 80
LYMPHOCYTE	22	%	28 - 55
MONOCYTE	06	%	02 - 10
EOSINOPHIL	00	%	01 - 06
BASOPHIL	00	%	0 - 0
ESR (WESTEGREN'S METHOD)	18	mm/1st hr.	0 - 15
R B C COUNT	3.69	Millions/cmm	4.247 - 5.4
P.C.V / HAEMATOCRIT	35.4	%	35 - 45
M C V	95.9	f.	80 - 100
M C H	27.6	Picogram	27.0 - 31.0
M C H C	28.8	gm/dl	33 - 37
PLATELET COUNT	1.81	Lakh/cu mm	1.50 - 4.50
BLOOD GROUP ABO	" O "		
RH TYPING	Positive		
BLOOD SUGAR FASTING	90.2	mg/dl	70 - 100
BLOOD SUGAR PP	119.2	mg/dl	90 - 140
HB A1C	5.6	%	

Interpretation

Checked by : _____

Page 1 Contd...2

If test results are alarming or unexpected, patient is advised to contact the laboratory immediately for possible remedial action.

Facilities Available

- Multispeciality Hospital - 24 Hours Emergency - X-Ray/ ECG/ Ultrasound/ CT Scan - Dental- Fully Equipped Operation Theatre
 - Fully Functional Lab - 24/7 Casualty/ ICU-Nursery 24/7 Pharmacy - Labour Room - All Speciality OPD - Laproscopic Surgery -
 ECHO - Plastic Surgery



LAB REPORT

Reg. Date	14/02/2024	Patient Id	2402140002	DOB.
Name	MRS. DEVANSHI BHATT	Gender	F	Perm. ID
Age	32 Yrs.	Panel	MEDIWHEEL	Reported
Ref. By	MEDIWHEEL			16/02/2024 16:45:06

Test Name	Result	Units	Ref. Range
Non Diabetic	: 4-6%		
Good Diabetic Control	: 6-8%		
Fair Control	: 8-10%		
Poor Control	: >10%		

The Glycosylated haemoglobin assay has been validated as a reliable indicator Of mean blood glucose levels for a period of 8-12 week period. ADA recommended the testing twice a year in patients with stable blood glucose and quarterly. If treatment change, or if blood glucose levels are unstable.

TO BE CORRELATED CLINICALLY.

THYROID PROFILE

Free T3 ELFA	3.01	ng/ml	02 - 04
Free T4 ELFA	1.42	ug/dl	0.8 - 2.7
TSH Serum/ELFA	3.250	uIU/ml	0.25 - 5.50 uIU/ml

Interpretation**Clinical Use**

- Diagnose Hypothyroidism and Hyperthyroidism
- Monitor T4 replacement or T4 suppressive Therapy
- Quantify TSH levels in the subnormal range

Increased Levels : Primary Hypothyroidism Subclinical Hypothyroidism, TSH dependent, Thyroid Hormone Resistance.

Checked by : _____
Page 2 Contd...3

If test results are alarming or unexpected, patient is advised to contact the laboratory immediately for possible remedial action.

Facilities Available

- Multispeciality Hospital - 24 Hours Emergency - X-Ray/ ECG/ Ultrasound/ CT Scan - Dental- Fully Equipped Operation Theatre
- Fully Functional Lab - 24/7 Casualty/ ICU-Nursery 24/7 Pharmacy - Labour Room - All Speciality OPD - Laproscopic Surgery -
ECHO - Plastic Surgery



LAB REPORT

Reg. Date	14/02/2024	Patient Id	2402140002	DOB.	
Name	MRS. DEVANSHI BHATT	Gender	F	Perm. ID	
Age	32 Yrs.	Panel	MEDIWHEEL	Reported	16/02/2024 16:45:06
Ref. By	MEDIWHEEL				

Test Name	Result	Units	Ref. Range
-----------	--------	-------	------------

Decreased Levels : Grave's Disease, Autonomous Thyroid Hormone Secretion, TSH Deficiency

LIPID PROFILE

TOTAL CHOLESTEROL	159.00	mg/dL	130.0 - 200.0 (<200)
TRIGLYCERIDES	53.21	mg/dL	80.5 - 150.0 (<150)
H D L CHOLESTEROL DIRECT	50.14	mg/dL	42.0 - 60.0 (<40>59)
V L D L	10.6	mg/dL	4.0 - 30. (23-45)
L D L CHOLESTEROL	98.3	mg/dL	50.0 - 150.0 (50-150)
TOTAL CHOLESTEROL / HDL RATIO	3.2		3.3 - 5.1
LDL / HDL CHOLESTEROL RATIO	2.0		1.5 - 3.5

LIVER FUNCTION TEST (LFT)

BILIRUBIN TOTAL	0.40	mg/dl	0.2 - 1.2
CONJUGATED (D. BILIRUBIN)	0.25	mg/dl	0.00 - 0.3
UNCONJUGATED (I.D. BILIRUBIN)	0.15	mg/dl	0.2 - 0.9
SGOT / AST	29.00	IU/L	0 - 35
SGPT / ALT	25.2	IU/L	0 - 35
ALKALINE PHOSPHATASE	152.00	U/L	64 - 306
TOTAL PROTEIN	7.86	gm/dl	6.0 - 8.3
ALBUMIN	4.72	gm/dl	3.2 - 5.0
GLOBULIN	3.14	gm/dl	2.5 - 5.6
A/G RATIO	1.50		0.9 - 2.0
GAMMA GT	21.00	IU/L	0.0 - 35.0

Checked by : _____
 Page 3 Contd...4

If test results are alarming or unexpected, patient is advised to contact the laboratory immediately for possible remedial action.

Facilities Available

- Multispeciality Hospital - 24 Hours Emergency - X-Ray/ ECG/ Ultrasound/ CT Scan - Dental- Fully Equipped Operation Theatre
 - Fully Functional Lab - 24/7 Casualty/ ICU-Nursery 24/7 Pharmacy - Labour Room - All Speciality OPD - Laproscopic Surgery -
 ECHO - Plastic Surgery



LAB REPORT

Reg. Date	14/02/2024	Patient Id	2402140002	DOB,
Name	MRS. DEVANSHI BHATT	Gender	F	Perm. ID
Age	32 Yrs.	Panel	MEDIWHEEL	Reported
Ref. By	MEDIWHEEL			16/02/2024 16:45:06

Test Name	Result	Units	Ref. Range
SERUM CREATININE	0.59	mg/dl	0.6 - 1.2
SERUM URIC ACID	4.02	mg/dl	2.4 - 6.0
BLOOD UREA NITROGEN (BUN)	12.00	mg/dl	6.0 - 21.0
BUN/GREAT RATIO	20.3	mg/dl	10 - 20

Urine Routine Examination

PHYSICAL EXAMINATION

QUANTITY	20	ml.	
COLOUR	Pale Yellow		Pale Yellow
TRANSPARENCY	Clear		
SPECIFIC GRAVITY	1.025		
PH	6.0		

CHEMICAL EXAMINATION

ALBUMIN	Nil
SUGAR	Nil

MICROSCOPIC EXAMINATION

PUS CELLS	2-3	/HPF
RBC'S	Nil	/HPF
CASTS	Nil	
CRYSTALS	NIL	
EPITHELIAL CELLS	1-2	/HPF
BACTERIA	Nil	
OTHERS	Nil	

Di. **DR. REKHA BHATTIA**
M.B.B.S., MD (Path.)
Checked by: *[Signature]*
Malik Radix Healthcare Pvt. Ltd.
C-217, C-218, Vikas Marg, Nirman Vihar

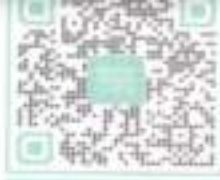DR. MEENU AGGARWAL
M.B.B.S., MD (Path.)

If test results are alarming or unexpected, patient is advised to contact the laboratory immediately for possible remedial action.

Facilities Available

- Multispeciality Hospital - 24 Hours Emergency - X-Ray/ ECG/ Ultrasound/ CT Scan - Dental- Fully Equipped Operation Theatre
- Fully Functional Lab - 24/7 Casualty/ ICU-Nursery 24/7 Pharmacy - Labour Room - All Speciality OPD - Laproscopic Surgery -
ECHO - Plastic Surgery

R



UHID	PT206600	LAB No.	XRY2309714
Name	Mrs. DEVANSHI BHATT	Regn. No.	GEN2338682
Age / Sex	32 Yrs / F	Receiving Dt/Time	14-Feb-2024 10:54
		Reporting Dt/Time	14-Feb-2024 10:54 AM



XRAY

CHEST (PA)

Both lung fields are normal.

Cp angles are clear.

Hila are normal...

Heart size appears within normal limits.

Soft tissue shadows and bony thorax are normal.

Advised... please correlate clinically.

***** END OF REPORT *****

DR. K.K. SINGH
 M.B.B.S. D.M.D.
 SENIOR CONSULTANT
 Reg. No. 2547 (DMC)

DR. RAJESH MALHOTRA
 MBBS, MD (RADIOLOGY)
 CONSULTANT RADIOLOGY
 Reg. No. DMC9299

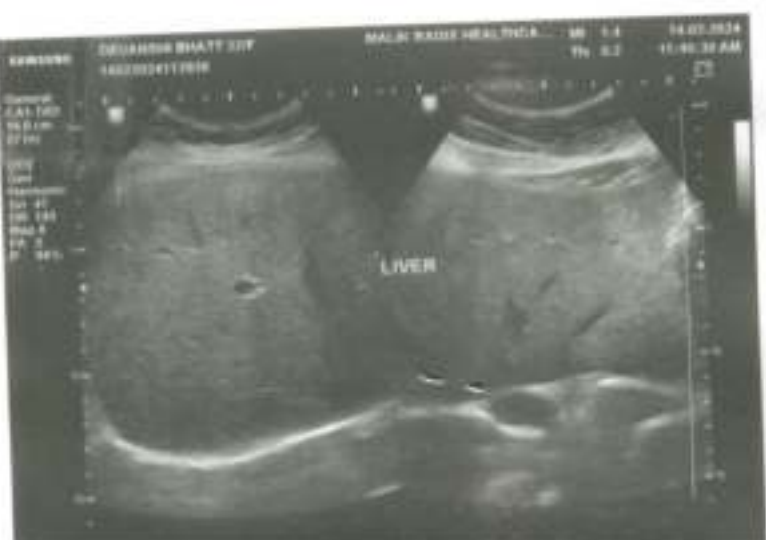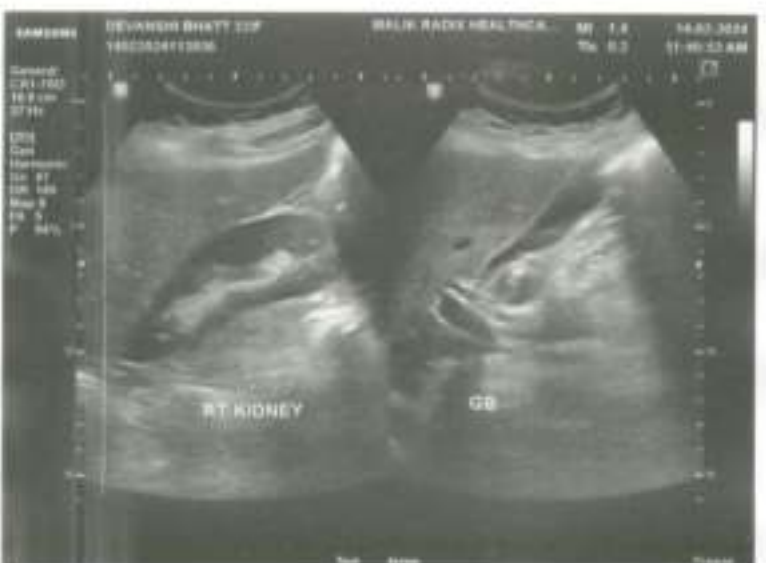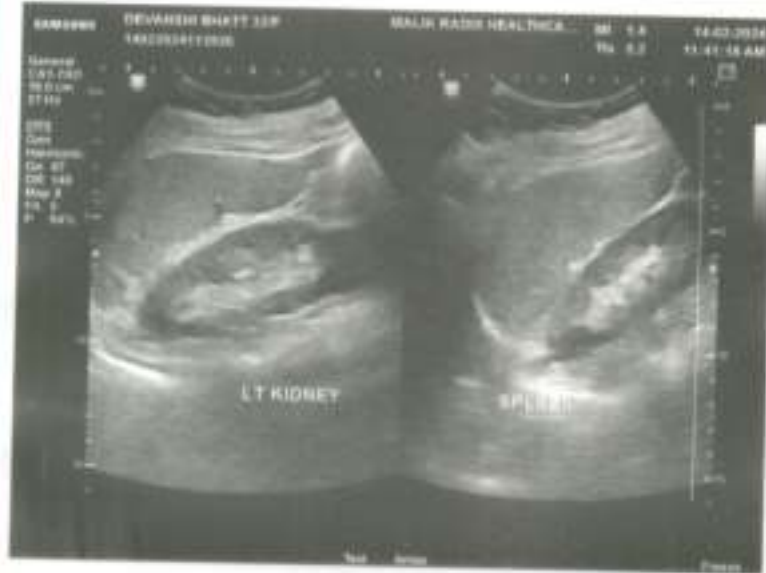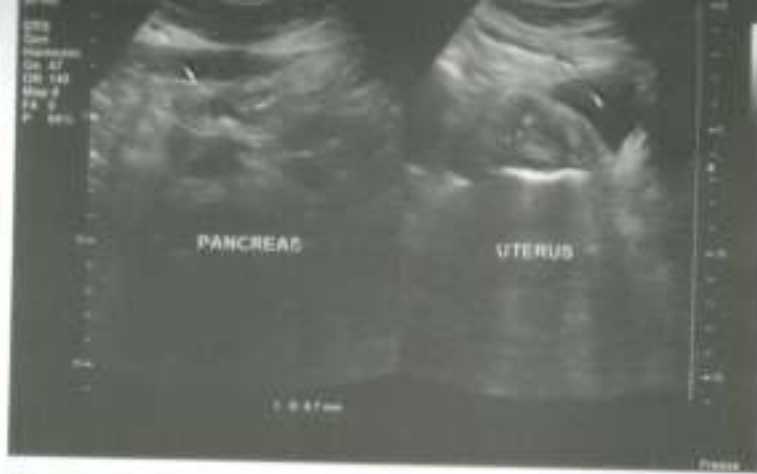DR. T. R. VOHRA
 MD (RADIODIAGNOSIS)
 SENIOR CONSULTANT
 Reg. No. 3272 (DMC)

DR. MUKESH KOSHAL
 MBBS, MD (RADIOLOGY)
 CONSULTANT RADIOLOGY
 Reg. No. DMC10407

DR. SHREYASH TIWARY
 MBBS, MD (RADIOLOGY)
 CONSULTANT RADIOLOGY
 Reg. No. DMC86803

Facilities Available

- Multispecialty Hospital - 24 Hours Emergency - X-Ray/ ECG/ Ultrasound/ CT Scan - Dental - Fully Equipped Operation Theatre
- Fully Functional Lab - 24/7 Casualty/ ICU-Nursery 24/7 Pharmacy - Labour Room - All Speciality OPD - Laproscopic Surgery - ECHO - Plastic Surgery





NAME	MRS DEVANSHI BHATT	AGE	32 Y/F
REFD. BY.	HEALTH CHECK UP	DATE	14.02.24

Ultrasound Examination of Whole Abdomen & Pelvis :

Liver: Liver shows normal parenchymal echotexture. No focal SOL. is seen in liver. IHBR & portal radicles are normal.

Gallbladder: Gallbladder shows normal anechoic pattern . No evidence of cholecystitis or cholelithiasis is seen. Common bile duct is normal in course & caliber.

Pancreas: Pancreas shows normal size & echotexture.

Spleen: Spleen shows normal size, outline & echotexture.

Kidneys: Kidneys show normal size, shape, position & echotexture. No calculus, hydronephrosis or SOL. is seen in kidneys. Cortico- medullary differentiation and cortical thickness is normal on both sides.

No supra- renal mass seen.

Great abdominal vessels are normal.

Domes of diaphragm are seen to move normally & synchronously in respiration. No supra- or infra diaphragmatic collection is seen.

No ascites or pericardial effusion seen.

No para aortic lymph nodes seen.

Urinary bladder: Urinary bladder shows normal anechoic pattern. No calculus, SOL. or diverticulum seen.

Uterus: Uterus is anteverted and normal in size & echotexture. No intrinsic SOL. is seen in uterus. Endometrial thickness is 6.7 mm.

Adnexa: Adnexal regions including the ovaries are sonographically normal.

Regards.

Dr Mukesh Koshal MD (Rad- diag)
 Regn. No. DMC 10407

RADIOLOGIST :

Facilities Available