

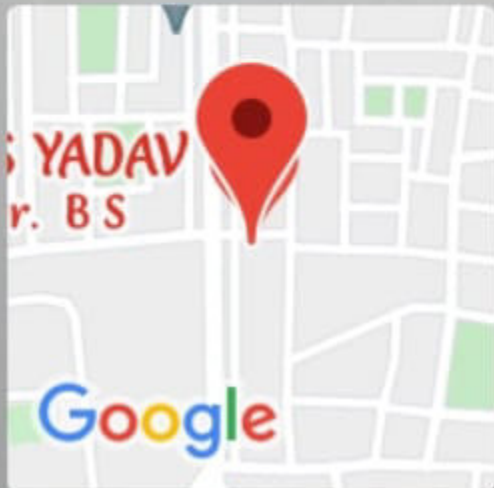


Diwakar Diagnostic Centre

पैथोलोजी | टी.एँम.टी. | एक्स-रे | को कार्डियो ग्राफी | सोनोग्राफी



GPS Map Camera



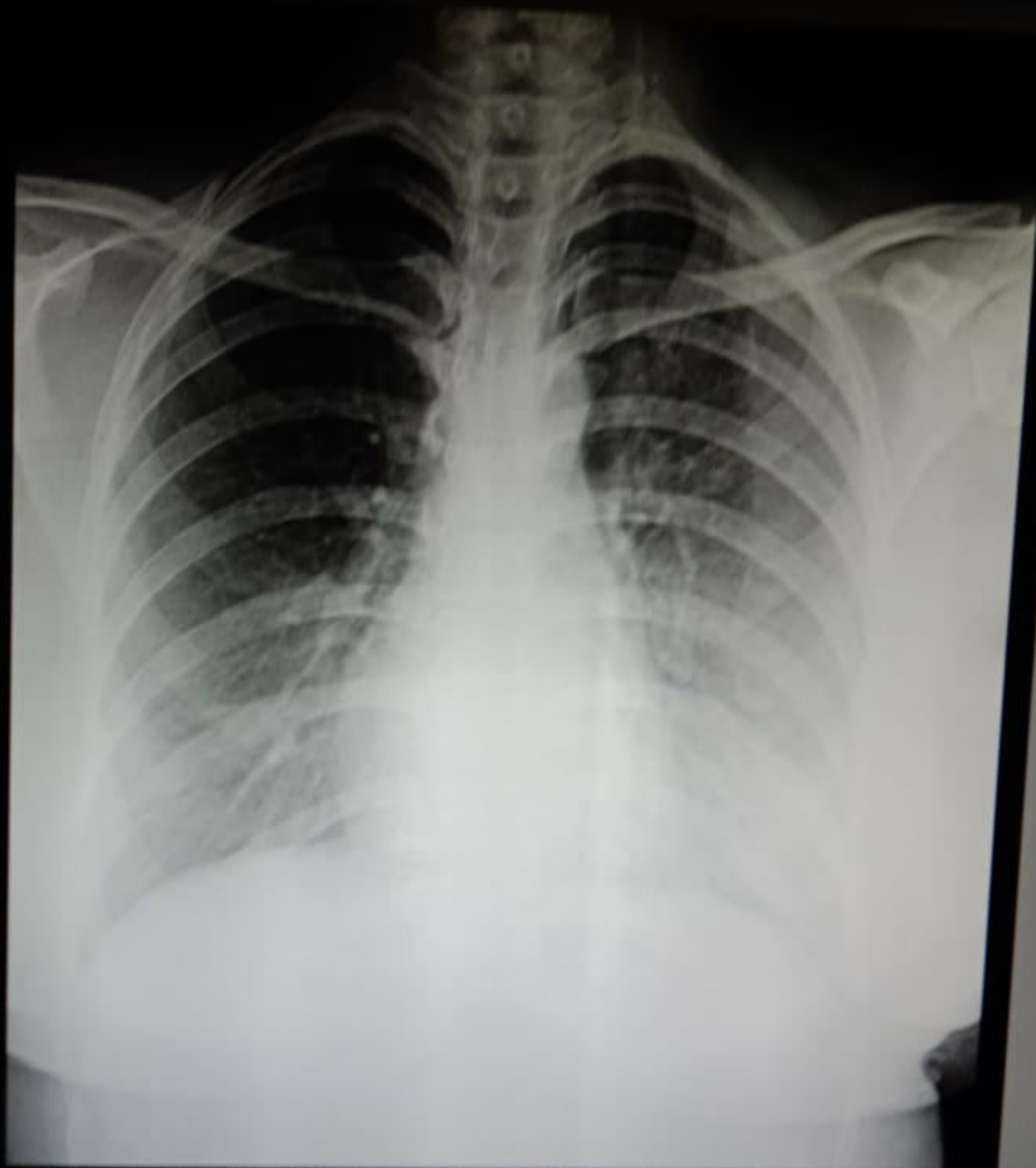
Bhopal, Madhya Pradesh, India

636, Champion School Rd, E-7, Arera Colony, Bhopal, Madhya Pradesh 462016, India

Lat 23.205853°

Long 77.43163°

18/11/21 09:47 AM



**MRS MOHINI PATEL 30Y 781 CHEST,FRN P->A 18-Nov-21
DIWAKAR DIAGNOSTIC CENTRE , ARERA COLONY ,BHOPAL**



भारत सरकार

Government of India




मोहनी पटेल

Mohani Patel

जन्म तिथि / DOB : 01/07/1991

महिला / Female



4574 0009 9713

आधार - आम आदमी का अधिकार

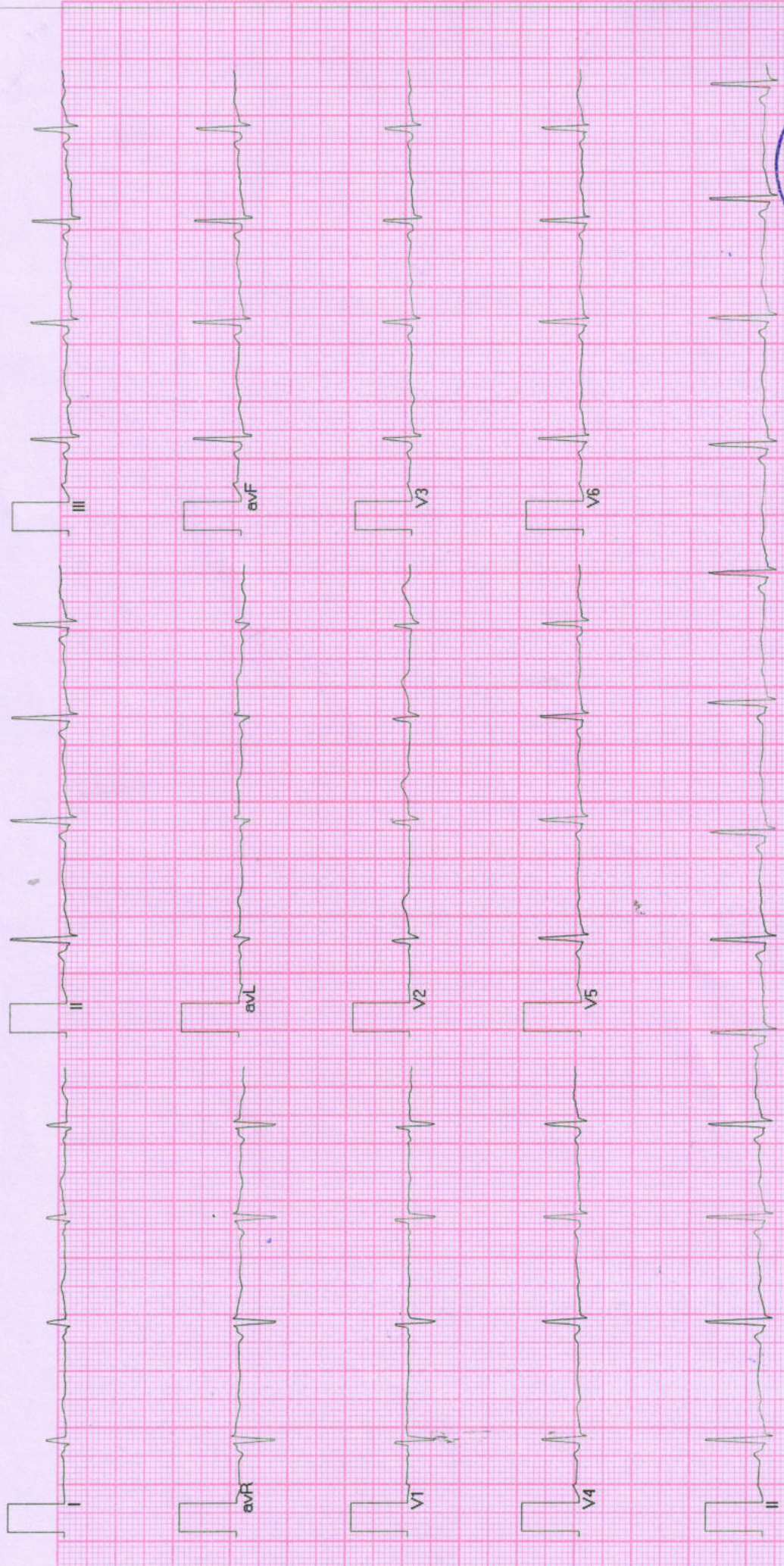
Dr. B. M. Agarwal
MBBS, DCP
Consultant Pathologist




m. Patel

Allengers Global Healthcare Pvt Ltd.
112 / MRS. MOHANI PATEL / 30 Yrs / F / 53Cms. / 165Kgs.
Heart Rate : 88 bpm / Tested On : 18-Nov-21 10:06:16 / HF 0.05 Hz - LF 100 Hz / Notch 50 Hz / Sn 1.00 Cm/mV / Sw 25 mm/s
/ Refd By: BOB

ECG



M. Patel



BPL-DYNATRAC



दिवाकर डायग्नोस्टिक सेंटर

E-7/636, पंजाब नेशनल बैंक के पास, मैन रोड, अरेरा कॉलोनी भोपाल (म.प्र.)


फोन: 0755-2465288, 0755-3520545 मो: 9826340190

Pt.Name :-	Mrs. Mohani Patel
Age :-	30y/F
Refd. By :-	BOB
Lab.pNo.:-	98
Date :-	18/11/2021

URINE ANALYSIS

<u>A. PHYSICALEXAMINATION</u>		<u>C. MICROSCOPIEXAMINATION</u>	
1. Colour	Yellow	Pus Cells	3-4/HPF
2. Appearance	Clear	R.B.C.	Nil
3. Specific Gravity	Q.N.S.	Epithelial Cell	1-2/HPF
<u>B. CHEMICAL EXAMINATION</u>		Cast	Nil
1.Reaction	Acidic	Crystals(Cal.Oxa)	Nil
2.Albumin	Absent	Bacteria	Nil
3.Sugar	Nil	Amorphous	Nil
4.Bile Salts	Absent	T. Vaginitis	Nil

URINE COTININE	Negative	By Card method
----------------	----------	----------------



Dr. B. M. Agarwal
MBBS, DCP
Consultant Pathologist

All test have technical limitation. Collaborative clinic pathological interpretation is mandatory. In case of disparity test may be repeated immediately. Typographic mistakes should be get correct instantly. This report is not valid for medico legal purpose



दिवाकर डायग्नोस्टिक सेंटर

E-7/636, पंजाब नेशनल बैंक के पास, मॉन रोड, अरेरा कॉलोनी भोपाल (म.प्र.)


फोन: 0755-2465288, 0755-3520545 मो: 9826340190

Pt.Name :-	Mrs. Mohani Patel
Age :-	30y/F
Refd. By :-	BOB
Lab.pNo.:-	98
Date :-	18/11/2021

EXAMINATION OF BLOOD

TEST	RESULT	NORMAL VALUE
Haemoglobin	11.8mgs%	Female 12-16gms%, Male 14-18gms%
Red Cell count	4.7	4.5-5.6 million /cumm
Platelet Count	2.36	1.5-5.6 Lac/cumm
Leucocytes per.cu.mm	8200/cumm	5000-11000/cumm
Neutrophils	55%	50-70%
Lymphocytes	32%	20-40%
Eosinophils	08%	0-7%
Monocytes	05%	2-8%
PCV	39.6	37-47
MCV	79.6	76-96
MCH	29.6	27-32
MCHC	32.0	31-35
ESR	13	Male 0-9, Female 0-20mm/FHR
Blood Group	B Positive	By Slide Method
S.Bilirubin(Total)	0.89	0.2-1.0mg/dl
Direct	0.33	0.0-0.25mg/dl
Indirect	0.56	
SGOT	28.0	5-35U/L
SGPT	30.6	8-40U/L
Alk Phosphatase	8.1	3-13 KA units
S. Protein(Total)	6.9	6.0-8.0mg%
Albumin	4.0	3.7-5.3mg%
Globulin	3.1	1.5 to 3.5 mg%
AG Ratio	1.25	1.-2.0
Blood Urea Nitrogen (BUN)	14.0	7-20 mg/dl
S.Creatine	0.87	0.5-1.4mg/dl
S. Uric Acid	5.0	3.5-7.5mg%
Calcium	8.9	8.5-10.5 gm/dl
GGTP	30.6	5-35 UL/dl
HbsAg	Negative	By card method
HIV I&II	Negative	By elisa method
Fasting Blood Sugar	79.6	70 to 110mg/dl
Post Prandial Blood Sugar	130.2	Up to 150mg/dl
Total Serum Cholesterol	158.6	100-250 mg%
Serum Triglyceride	119.3	Up to 160 mg%
Serum Cholesterol HDL	45.0	Up to 65 mg%
Serum Cholesterol LDL	89.7	Up to 125 mg%
VLDL	23.8	Up to 30 mg%
Glycosylated Hemoglobin HBA1c	5.2	Below - 6.0 % -Non Diabetic control 6-7 % -Excellent control Above- 8 % -Poor control

All test have technical limitation. Collaborative clinic pathological interpretation is mandatory. In case of disparity test may be repeated immediately. Typographical mistakes should be get correct instantly. This report is not valid for medico legal purpose



Dr. B. M. Agarwal
Pathologist
MBBS, DCP
Consultant Pathologist



द्विवाकर डायग्नोस्टिक सेंटर

E-7/636, पंजाब नेशनल बैंक के पास, मैन रोड, अरेरा कॉलोनी भोपाल (म.प्र.)

फोन: 0755-2465288, 0755-3520545 मो: 9826340190

Pt.Name :-	Mrs. Mohani Patel
Age :-	30y/F
Refd. By :-	BOB
Lab.pNo.:-	98
Date :-	18/11/2021
Skigram	X Ray Chest PA View
Radiologist	Dr. B.M.Agarwal MD (Radiology)

REPORT

Tricia Central

Thoracic cage normal

Both Lungs Field Clear.

Both hilers normal

Cardiac border normal

Both cp angles clear

Both domes and diaphragm normal

IMPRESSION

-NO CARDIO PULMONARY PATHOLOGY

-COORELATE WITH CLINICAL FINDINGS.



Dr. B. M. Agarwal
MD, Radiology
Consultant Radiologist
Radiologist



दिवाकर डायग्नोस्टिक सेंटर

E-7/636, पंजाब नेशनल बैंक के पास, मैन रोड, अरेरा कॉलोनी भोपाल (म.प्र.)

फोन: 0755-2465288, 0755-3520545 मो: 9826340190

Pt.Name :-	Mrs. Mohani Patel
Age :-	30y/F
Refd. By :-	BOB
Lab.pNo.:-	98
Date :-	18/11/2021

EXAMINATION OF BLOOD

Thyroid profile

<u>TEST</u>	<u>RESULT</u>	<u>NORMAL VALUE</u>
T3 - TOTAL	89.6	82-213 ng/dL
T4 - TOTAL	6.98	6.09-12.23 ug/dL
THYROID STIMULATING HORMONE (TSH)	2.23	0.45-4.25 ul/mL

Interpretation:

TSH Levels will be elevated in primary hypothyroidism. TSH levels will be low in Hyperthyroidism there is decreased production of thyroid hormones by the thyroid hence the person may experience symptoms such as weight gain, constipation, cold intolerance and fatigue. Iodine deficiency and Hashimoto thyroiditis is the most common cause of hypothyroidism It makes Thyroid stimulating hormone. If TSH levels are abnormally high it could mean you have an underactive thyroid or hypothyroidism.

Dr. B. M. Agarwal
Pathologist
MBBS, DCP
Consultant Pathologist

All test have technical limitation. Collaborative clinic pathological interpretation is mandatory. In case of disparity test may be repeated immediately. Typographic mistakes should be get correct instantly. This report is not valid for medico legal purpose



PTO

Right kidney is normal in size, shape and position. Corticomedullary differentiation (CMD) is well maintained. Normal cortical thickness is noted. No E/O hydronephrosis or calculus is noted.

No evidence of free fluid is noted.

No evidence of lymphadenopathy is noted.

IVC and aorta appear to be normal.

Spleen is normal in size and echo texture.

Pancreas appear normal in size, shape and echo texture with smooth contour. No peripancreatic pathology seen. (Not seen due to gases)

Common duct reveals normal course and caliber.

Gall Bladder is physiologically well distended. No. E/O echogenic foci in GB lumen. GB wall is normal / thickened. No E/O pericholecystic collection.

No E/O subdiaphragmatic Collection.

Liver appears normal in size and shape with normal outline. Normal/ increased parenchymal echogenicity is noted. No E/O focal lesion/ IHBR dilatation is seen. Hepatic veins and portal veins appear normal.

Indication: Health check-up

WHOLE ABDOMEN ULTRASOUND REPORT

Name: Mrs. Jyoti Patel R/B No. Date: 18/11/2021

Age: 30 YRS./F


Mob. : 8989649694, 9516333619
Clinic Registration : CL/5392/Jun/2017
PNDT Registration : MPPCPNDT/BPL/2017/206

34, भूतल, माहिती अदिति आर्कड, शाहपुरा मस्जिद के पास
भरत नगर रोड, ई-7/194, अररा कॉलोनी, भीपाल - 462038

श्री. रीम क्लिनिक



Dr. Jayant Yadav, MD
MBBS, MD (Radiologist) Reg. No. 4166
डॉ. जयान्त यादव



Dr. P. Savita, MD
MBBS, MD (O&G) Reg. No. 9974
डॉ. पी. सविता

Advised clinical Correlation.

Impression : Normal study.

Left Ovary appears enlarged / Normal in size, shape and echo texture.

Right Ovary appears enlarged / Normal in size, shape and echo texture.

Uterus is ante / retro verted and normal in size, shape and echotexture with smooth outline. No E/O focal lesion is noted. Endometrial echo appear normal. Cervical and vaginal shadows appear normal.

Prostate is normal in size. Shape and echo texture with smooth outline. No E/O focal lesion is noted.

Urinary Bladder is well distended (physiological). its contents are echo free. No E/O bladder wall thickening is noted. Post-void residue is insignificant.

Left Kidney is normal is size, shape and position. CMD is well maintained. Normal cortical thickness is noted. No E/O hydronephrosis or calculus is noted.

