

A Venture of Apple Cardiac Care

A-3, Ekta Nagar, Stadium Road,
(Opp. Care Hospital),
Bareilly - 243 122 (U.P.) India
Tel. : 07599031977, 09458888448



Reg.NO. : 278
NAME : **Mr. PINKU**
REFERRED BY : Dr.Nitin Agarwal (D M)
SAMPLE : BLOOD

DATE : **08/07/2023**
AGE : 46 Yrs.
SEX : MALE

<u>TEST NAME</u>	<u>RESULTS</u>	<u>UNITS</u>	<u>BIOLOGICAL REF. RANGE</u>
HAEMATOLOGY			
COMPLETE BLOOD COUNT (CBC)			
HAEMOGLOBIN	13.3	gm/dl	12.0-18.0
TOTAL LEUCOCYTE COUNT	10,800	/cumm	4,000-11,000
DIFFERENTIAL LEUCOCYTE COUNT(DLC)			
Neutrophils	70	%	40-75
Lymphocytes	28	%	20-45
Eosinophils	02	%	01-08
TOTAL R.B.C. COUNT	4.43	million/cumm	3.5-6.5
P.C.V./ Haematocrit value	40.8	%	35-54
M C V	92.1	fL	76-96
M C H	30.0	pg	27.00-32.00
M C H C	32.6	g/dl	30.50-34.50
PLATELET COUNT	2.22	lacs/mm ³	1.50 - 4.50
E.S.R (WINTROBE METHOD)			
-in First hour	11	mm	00 - 15
BLOOD GROUP			
Blood Group	O		
Rh	POSITIVE		



enture of Apple Cardiac Care

A-3, Ekta Nagar, Stadium Road,
(Opp. Care Hospital),
Bareilly - 243 122 (U.P.) India
Tel. : 07599031977, 09458888448



APPLE
PATHOLOGY
TRUSTED RESULT

Reg.NO. : 278
NAME : **Mr. PINKU**
REFERRED BY : Dr.Nitin Agarwal (D M)
SAMPLE : BLOOD

DATE : **08/07/2023**
AGE : 46 Yrs.
SEX : MALE

<u>TEST NAME</u>	<u>RESULTS</u>	<u>UNITS</u>	<u>BIOLOGICAL REF. RANGE</u>
GLYCOSYLATED HAEMOGLOBIN	5.4		

EXPECTED RESULTS :

Non diabetic patients	: 4.0% to 6.0%
Good Control	: 6.0% to 7.0%
Fair Control	: 7.0% to -8%
Poor Control	: Above 8%

***ADA: American Diabetes Association**

The glycosylated hemoglobin assay has been validated as a reliable indicator of mean blood glucose levels for a period of 8-12 week period prior to HBA1C determination.ADA recommends the testing twice a year in patients with stable blood glucose, and quarterly, if treatment changes, or if blood glucose levels are unstable.

METHOD : ADVANCED IMMUNO ASSAY.

BIOCHEMISTRY

Gamma Glutamyl Transferase (GGT)	24	U/L	7-32
BLOOD SUGAR F.	81	mg/dl	60-100
BLOOD UREA NITROGEN	17	mg/dL.	5 - 25
SERUM CREATININE	0.8	mg/dL.	0.5-1.4
URIC ACID	7.2	mg/dl	3.5-8.0

CLINICAL SIGNIFICANCE:

Analysis of synovial fluid plays a major role in the diagnosis of joint disease.



Signature of Apple Cardiac Care

A-3, Ekta Nagar, Stadium Road,
(Opp. Care Hospital),
Bareilly - 243 122 (U.P.) India
Tel. : 07599031977, 09458888448



APPLE
PATHOLOGY
TRUSTED RESULT

Reg.NO. : 278
NAME : **Mr. PINKU**
REFERRED BY : Dr.Nitin Agarwal (D.M)
SAMPLE : BLOOD

DATE : **08/07/2023**
AGE : 45 Yrs.
SEX : MALE

<u>TEST NAME</u>	<u>RESULTS</u>	<u>UNITS</u>	<u>BIOLOGICAL REF. RANGE</u>
LIVER PROFILE			
SERUM BILIRUBIN			
TOTAL	0.7	mg/dL	0.3-1.2
DIRECT	0.4	mg/dL	0.2-0.6
INDIRECT	0.3	mg/dL	0.1-0.4
SERUM PROTEINS			
Total Proteins	6.7	Gm/dL	6.4 - 8.3
Albumin	4.3	Gm/dL	3.5 - 5.5
Globulin	2.4	Gm/dL	2.3 - 3.5
A : G Ratio	1.79		0.9-2.0
SGOT	40	IU/L	0-40
SGPT	50	IU/L	0-40
SERUM ALK.PHOSPHATASE	92	IU/L	00-115

NORMAL RANGE : BILIRUBIN TOTAL

Premature infants, 0 to 1 day: ≤ 8 mg/dL. Premature infants, 1 to 2 days: ≤ 12 mg/dL. Adults: 0.3-1 mg/dL.

Premature infants, 3 to 5 days: ≤ 16 mg/dL. Neonates, 0 to 1 day: 1.4-8.7 mg/dL.

Neonates, 1 to 2 days: 3.4-11.5 mg/dL. Neonates, 3 to 5 days: 1.5-12 mg/dL. Children 6 days to 18 years: 0.3-1.2 mg/dL.

COMMENTS-

Total and direct bilirubin determination in serum is used for the diagnosis, differentiation and follow-up of jaundice. Elevation of SGPT is found in liver and kidney diseases such as infectious or toxic hepatitis, IM and cirrhosis. Organs rich in SGOT are heart, liver and skeletal muscles. When any of these organs are damaged, the serum SGOT level rises in proportion to the severity of damage. Elevation of Alkaline Phosphatase in serum or plasma is found in hepatitis, biliary obstructions, hyperparathyroidism, steatorrhea and bone diseases.



Adventure of Apple Cardiac Care

A-3, Ekta Nagar, Stadium Road,
(Opp. Care Hospital),
Bareilly - 243 122 (U.P.) India
Tel. : 07599031977, 09458888448



APPLE
PATHOLOGY
TRUSTED RESULT

Reg.NO. : 278
NAME : **Mr. PINKU**
REFERRED BY : Dr.Nitin Agarwal (D M)
SAMPLE : BLOOD

DATE : **08/07/2023**
AGE : 46 Yrs.
SEX : MALE

<u>TEST NAME</u>	<u>RESULTS</u>	<u>UNITS</u>	<u>BIOLOGICAL REF. RANGE</u>
LIPID PROFILE			
SERUM CHOLESTEROL	174	mg/dL.	130 - 200
SERUM TRIGLYCERIDE	110	mg/dl.	30 - 160
HDL CHOLESTEROL	49	mg/dL.	30-70
VLDL CHOLESTEROL	22	mg/dL.	15 - 40
LDL CHOLESTEROL	103	mg/dL.	00-130
CHOL/HDL CHOLESTEROL RATIO	3.55	mg/dl	
LDL/HDL CHOLESTEROL RATIO	2.10	mg/dl	

INTERPRETATION

TRIGLYCERIDE level > 250mg/dL is associated with an approximately 2-fold greater risk of coronary vascular disease. Elevation of triglycerides can be seen with obesity, medication, fast less than 12 hrs., alcohol intake, diabetes melitus, and pancreatitis. CHOLESTEROL, its fractions and triglycerides are the important plasma lipids in defining cardiovascular risk factors and in the management of cardiovascular disease. Highest acceptable and optimum values of cholesterol values of cholesterol vary with age. Values above 220 mgm/dl are associated with increased risk of CHD regardless of HDL & LDL values. HDL-CHOLESTEROL level <35 mg/dL is associated with an increased risk of coronary vascular disease even in the face of desirable levels of cholesterol and LDL - cholesterol. LDL - CHOLESTEROL & TOTAL CHOLESTEROL levels can be strikingly altered by thyroid, renal and liver disease as well as hereditary factors. Based on total cholesterol, LDL- cholesterol, and total cholesterol/HDL - cholesterol ratio, patients may be divided into the three risk categories.

URINE EXAMINATION



Enterprise of Apple Cardiac Care

A-3, Ekta Nagar, Stadium Road,
(Opp. Care Hospital),
Bareilly - 243 122 (U.P.) India
Tel. : 07599031977, 09458888448



Reg.NO. : 278
NAME : **Mr. PINKU**
REFERRED BY : Dr.Nitin Agarwal (D M)
SAMPLE : BLOOD

DATE : **08/07/2023**
AGE : 46 Yrs.
SEX : MALE

<u>TEST NAME</u>	<u>RESULTS</u>	<u>UNITS</u>	<u>BIOLOGICAL REF. RANGE</u>
URINE EXAMINATION REPORT			
PHYSICAL EXAMINATION			
pH	6.0		
TRANSPARENCY			
Volume	25	ml	
Colour	Light Yellow		
Appearance	Clear		Nil
Sediments	Nil		
Specific Gravity	1.020		1.015-1.025
Reaction	Acidic		
BIOCHEMICAL EXAMINATION			
UROBILINOGEN	Nil		NIL
BILIRUBIN	Nil		NEGATIVE
URINE KETONE	Nil		NEGATIVE
Sugar	Nil		Nil
Albumin	Nil		Nil
Phosphates	Absent		Nil
MICROSCOPIC EXAMINATION			
Red Blood Cells	Nil	/H.P.F.	
Pus Cells	0-1	/H.P.F.	
Epithelial Cells	1-2	/H.P.F.	
Crystals	NIL		NIL
Casts	Nil	/H.P.F.	
DEPOSITS			
Bacteria	NIL		
Other	NIL		

BIOCHEMISTRY

Venture of Apple Cardiac Care

A-3, Ekta Nagar, Stadium Road,
(Opp. Care Hospital),
Bareilly - 243 122 (U.P.) India
Tel. : 07599031977, 09458888448



APPLE
PATHOLOGY
TRUSTED RESULT

Reg.NO. : 278
NAME : **Mr. PINKU**
REFERRED BY : Dr.Nitin Agarwal (D M)
SAMPLE : BLOOD

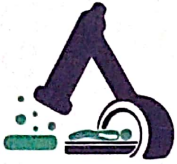DATE : **08/07/2023**
AGE : 46 Yrs.
SEX : MALE

<u>TEST NAME</u>	<u>RESULTS</u>	<u>UNITS</u>	<u>BIOLOGICAL REF. RANGE</u>
BLOOD SUGAR P.P.	120	mg/dl	80-160

--{End of Report}--

Dr. Shweta Agarwal, M.D.
(Pathologist)





Patient ID 10233700
Name Mr. PINKU
Sex/Age Male 46 Yrs
Ref. By Dr. NITIN AGARWAL
Specimen



Reg. Date 08/07/2023 11:26:35
Collected On
Received On
Reported On 08/07/2023 12:04:23
Permanent ID P10100015874

USG WHOLE ABDOMEN

Liver - is enlarged in size (14.1 cm). Homogenous echotexture. No IHBRD / focal SOL is seen. Hepatic vessels are normal. PV - normal. Porta hepatis - normal

Gall bladder - Normal physiological distension. No calculus in lumen. Wall thickness is normal. CBD - normal.

Pancreas - is normal in thickness and echotexture. Pancreatic duct is not dilated. No evidence of pancreatic calcification.

Spleen - is normal in size and normal echotexture.

Both kidneys - normal in size, outline and cortical echotexture. Renal parenchymal width is normal. Corticomedullary definition is normal. No backpressure changes are seen. Perinephric spaces are normal.

Urinary bladder - No calculus is seen in the lumen. Wall is smooth and regular.

Prostate - Size is normal (16 gm), parenchyma is homogeneous.

No free fluid is seen in peritoneal cavity.

IMPRESSION:

- Hepatomegaly with Grade I fatty changes of liver.

ADV - PLEASE CORRELATE CLINICALLY.

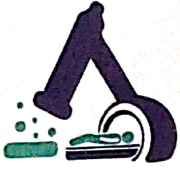*** End of Report ***



Subhajit
DR SUBHAJIT DUTTA
MD (RADIOLOGIST), DNB

Page No 1 of 1





Patient ID 10233701
Name Mr. PINKU
Sex/Age Male 46 Yrs
Ref. By Dr. NITIN AGARWAL
Specimen



Reg. Date 08/07/2023 11:29:51
Collected On
Received On
Reported On 08/07/2023 12:21:08
Permanent ID P10100015874

X-RAY CHEST PA VIEW

Trachea is central in position.
Bony cage is normal.
Both hila are normal.
No definite evidence of pleuro pulmonary pathology
Both CP angles are clear.
Left ventricular hypertrophy seen.
Both diaphragms are normal in position and contour.

IMPRESSION:

NO SIGNIFICANT ABNORMALITY DETECTED.

ADV – PLEASE CORRELATE CLINICALLY.

*** End of Report ***



Subjit
DR SUBHAJIT DUTTA
MD (RADIOLOGY), DNB

Page No 1 of 1

A-3, Ekta Nagar, Stadium Road,
 (Opposite Care Hospital),
 Bareilly - 243 122 (U.P.) India
 Tel. : 07599031977, 09458888448



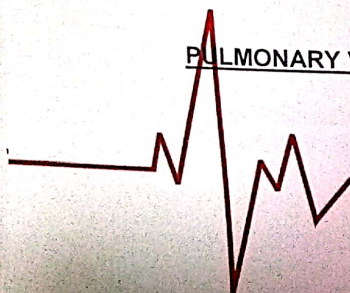
APPLE
CARDIAC CARE
 DR. NITIN AGARWAL'S HEART CLINIC
 A UNIT OF PRIME HEART CARE

NAME	Mr. PINKU	AGE/SEX	46 Y/M
Reff. By	Dr. NITIN AGARWAL (DM)	DATE	08/07/2023

ECHOCARDIOGRAPHY AND COLOUR DOPPLER STUDY

<u>MEASUREMENTS</u>	<u>VALUE</u>	<u>NORMAL DIMENSIONS</u>
LVID (d)	4.6 cm	(3.7 –5.6 cm)
LVID (s)	2.6 cm	(2.2 –3.9 cm)
RVID (d)	2.4 cm	(0.7 –2.5 cm)
IVS (ed)	1.0 cm	(0.6 –1.1 cm)
LVPW (ed)	1.0 cm	(0.6 –1.1 cm)
AO	2.0 cm	(2.2 –3.7 cm)
LA	3.2 cm	(1.9 –4.0 cm)
<u>LV FUNCTION</u>		
EF	60 %	(54 –76 %)
FS	30 %	(25 –44 %)

- LEFT VENTRICLE** : No regional wall motion abnormality
No concentric left Ventricle Hypertrophy
- MITRAL VALVE** : Thin, PML moves posteriorly during Diastole
No SAM, No Subvalvular pathology seen.
No mitral valve prolapse calcification .
- TRICUSPID VALVE** : Thin, opening wells. No calcification, No doming .
No Prolapse.
Tricuspid inflow velocity= 0.7 m/sec
- AORTIC VALVE** : Thin, tricuspid, opening well, central closer,
no flutter.
No calcification
Aortic velocity = 1.3 m/sec
- PULMONARY VALVE** : Thin, opening well, Pulmonary artery is normal
EF slope is normal.
Pulmonary Velocity = 0.9 m /sec



FACILITIES : ECG | COLOUR DOPPLER | ECHO CARDIOGRAPHY
 TMT | HOLTER MONITORING | PATHOLOGY

ON DOPPLER INTERROGATION THERE WAS :

- No mitral regurgitation
- No tricuspid regurgitation
- No aortic regurgitation
- No pulmonary regurgitation

MITRAL FLOW

E= 0.6 m/sec

A= 0.8 m/sec

ON COLOUR FLOW:

- No mitral regurgitation
- No tricuspid regurgitation
- No aortic regurgitation
- No pulmonary regurgitation

COMMENTS:

- No LA /LV clot
- No pericardial effusion
- No intracardiac mass
- IAS/IVS Intact
- Inferior vena cava – normal in size with normal respiratory variation

FINAL IMPRESSION

- NO REGIONAL WALL MOTION ABNORMALITY
- GRADE I LV DIASTOLIC DYSFUNCTION
- NORMAL LV SYSTOLIC FUNCTION (LVEF~60%)
- NORMAL CARDIAC CHAMBER DIMENSIONS
- NORMAL VALVULAR COLOUR FLOW PATTERN



**DR.NITIN AGARWAL
DM (Cardiology)
Consultant Cardiologist**

This opinion is to be correlated with the clinically findings and if required, please re-evaluate / reconfirm with further investigation.



ALPHA DIAGNOSTICS
08/07/23 11:55:51AM

M12 H.04 C16

ABD 1

LOGIO
S8

LOGIO
S8

LIVER

LT KIDNEY

1 L 14.20 cm

R. Pinlay



Dr. Nitin Agarwal

MD, DM (Cardiology)

Consultant Interventional Cardiologist

Cell : +91-94578 33777

Formerly at :

Escorts Heart Institute & Research Centre, Delhi

Dr. Ram Manohar Lohia Hospital, Delhi



APPLE
CARDIAC CARE
DR. NITIN AGARWAL'S HEART CLINIC

Pinkish

D

8/1/23

124/80

86/62

96

Asymptomatic

Sp - Pulsi 70/2

0

e

e

A-3, EKTA NAGAR, (OPP. CARE HOSPITAL) STADIUM ROAD, NEAR DELAPEER CHAURAHA, BAREILLY - 243 122 (U.P.)

OPD Timings : 12.00 Noon to 04.00 pm, **Sunday** : 12.00 Noon to 3.00 pm

नम्बर लगाने के लिए फोन करें : 09458888448, 07599031977

VALID FOR 5 DAYS.

पर्चा पाँच दिन के लिये मान्य



Scanned with OKEN Scanner