

NAME OF PATIENT: MR. BISWAJIT SAHU

AGE: 36YRS/MALE

REFERRED: BOB

DATE: 14/10/2023

CHEST X - RAY PA VIEW


FINDINGS:

- Both the domes of diaphragm and CP angles are normal.
- Both the hila and mediastinum are normal.
- Both the lung fields are clear. No e/o focal parenchymal lesion.
- Cardio-thoracic ratio is normal.
- Soft tissues and bony cage are unremarkable.

IMPRESSION:

- **NO SIGNIFICANT ABNORMALITY SEEN.**

Advised: Clinical correlation and further evaluation if clinically indicated.



DR. ZEESHAN ATEEB DANI
(MD)
CONSULTANT RADIOLOGIST

This report is for perusal of the doctor only not the definitive diagnosis; findings have to be clinically correlated. This report is not for medico-legal purposes.



Mr. Biswasjit Sahy
Age - 36 y/m

13/10/23

B.P - 120/80
Pulse - 76/mnt
H - 173cm
Wt - 70 kg

No fever captured
No H/O DM II) Hry

CBC - 13.6/4.23/4.12/133

HbA1c - 5.4 %

Fasting - 79.0 mg/dl

Creat - 1.0 mg/dl

LFT - 18/25/74 H/L

T₃ - 1.21

T₄ - 7.80

TSH - 4.0

Lipid - 155.0/138.0/42.0/133

Person's fit at time of
examination

Dr. Animesh Choudhary
MD Medicine
Reg. No. CGMC 3583/2011
Apollo Clinic, Raipur



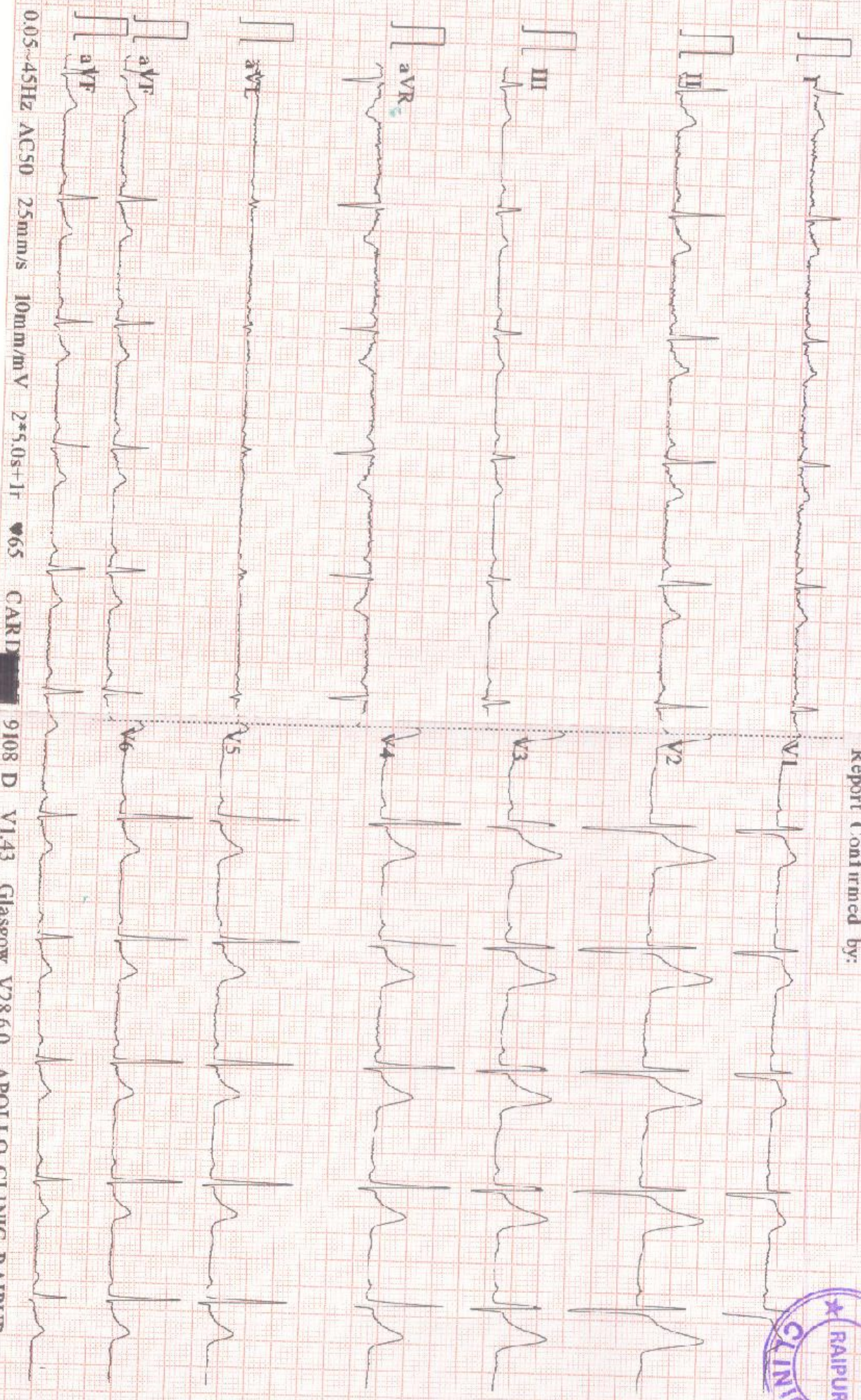MR BISWAJIT SAHU
Male 36 Years

HR : 65 bpm
P : 104 ms
PR : 156 ms
QRS : 86 ms
QT/QTc : 372/387 ms
P/QRS/T : 53/50/55 °
RV5/SV1 : 1.489/0.754 mV

Diagnosis Information:
Sinus rhythm
Normal ECG

Report Confirmed by:

Dr. Animesh Choudhary
MD Medicine
Reg. No. GMC 3583/2011
Apollo Clinic Raipur



ECHOCARDIOGRAPHY REPORT

NAME : MR. BISWAJIT SAHU	Age/Sex: 36Yrs/male	ECG : Sinus Rhythm
OPD/ IPD : OPD	STUDY DATE: 13/10/2023	REGN. NO. : FRAI.00000
Ref.By Dr : BOB		

M-MODE MEASUREMENTS:-

	Patient Value (cm)	Normal Value (cm)		Patient Value (cm)	Normal Value (cm)
AorticRoot Diameter	2.8	2.0 – 3.7	IVS Thickness	ED = 0.9 ES = 1.3	0.6 – 1.1
AorticValve Opening	1.8	1.5 – 2.6	PW Thickness	ED = 0.9 ES = 1.3	0.6 – 1.1
LA Dimension	2.7	1.9 – 4.0	RA Dimension	---	2.6
LVID(D)	4.6	3.7 – 5.5	RV Dimension	---	2.6
LVID(s)	2.9	2.2 – 4.0	TAPSE	---	1.6 – 2.6
LV EJECTION FRACTION	> 60%		(NORMAL VALUE: 55 – 60%)		

2D ECHO, COLOR FLOW & DOPPLER ASSESSMENT

Left Ventricle : LV Size & contractility is Normal, NO RWMA, Calculated EF IS > 60%

Left Atrium : LA Size Is Normal

Right Ventricle : Normal

Right Atrium : Normal

IAS/IVS : Intact

Pericardium : Normal, there is no Pericardial Effusion.

Mitral Valve : E>A, Normal

Tricuspid Valve : Normal

Aortic Valve : Normal


Pulmonary Valve : Pulmonary valve appears normal in morphology.

Systemic venous : IVC normal in size with normal Inspiratory collapse.

Diastolic Function : Normal.

FINAL IMPRESSION : NO RWMA AT REST.
NORMAL LV SYSTOLIC FUNCTION.
NORMAL CARDIAC CEMBER AND NORMAL VALVES.
NO I/C CLOT VEGITATION OR PERICARDIAL EFFUSION.




DR. DEEPAN DAS
 MBBS, DIP. CARDIOLOGY
 CONSULTANT DEPT. OF NIC

*THIS PAPER IS USED FOR CLINICAL REPORTING PURPOSE ONLY

Apollo Clinic

LICENSEE : SAMRIDDI AROGYAM PVT. LTD.

Apollo Clinic @ Tiara Complex A.T. Classic Near Ashoka Ratan, VIP Estate, Shankar Nagar, Raipur (C.G.)

Email : raipur1@apolloclinic.com | Website : www.apolloclinic.com

Online appointments: www.askapollo.com | Online reports: https://pht.apolloclinic.com


+91 96918 26363


0771 4033341/42

