



SHREEJI Multispeciality Hospital

Inspiring better health...

SHREEJI OCCUPATIONAL CENTRE SHREEJI PATHOLOGY LABORATORY

112F, Tower-A, Senate Square, Opp. Gangotri Apartment, Vuda Char rasta, Gotri, Vadodara-390021.

M. : 9157022510, Email : shreejihospital19@yahoo.com, smh31082015@gmail.com

:: PERSONAL HEALTH REPORT ::

NAME	Pavan Kumar Bonula	DATE	28/08/2021.
		SR. NO.	
		SEX.	M
		AGE	28
		HEIGHT	170cm
		WEIGHT	69kg

HISTORY

Present History : NAD
 Past Illness History : NAD Diabetes/Hypertension/Tuberculosis/Asthma/Epilepsy
 Past Occupational History : NAD
 Family History : NAD
 Personal History : NAD
 Addiction : NO Tobacco/Gutkha/Smoking/Alcohol

GENERAL EXAMINATION

T.P.R. : 82/24 B.P. : 122/80 mm Hg :
 Pallor/Icterus/Cyanosis/Varicosity/Lymph Nodes/Thyroid/Oedema/NVE/Other :

SYSTEMIC EXAMINATION

R.S. : NAD
 C.V.S. : NAD
 C.N.S. : NAD
 A.S. : NAD
 Musculo-skelet System :

E.N.T. Ex.	NAD	ACUITY OF VISION		RT EYE	LT EYE
		Without Glass	DISTANT	6/ 6	6/ 6
Dental Ex.	NAD		Near	6/ 6	6/ 6
		Skin Ex.		NAD	With Glass
Psychic Ex.	NAD		Near		
		COLOUR BLINDNESS		ND	

REMARK

ADVICE

The Worker is FIT/UNFIT for the assigned job.




DR. KRISH VAIDYA

MD G-50510, CIH

B **बैंक ऑफ बड़ौदा**
Bank of Baroda


नाम **बोनुला पवनकुमार**
Name **BONULA PAVANKUMAR**


कार्यकारी कूट क्र.
E.C. No. **124976**




[Signature]
आधिकारी प्राधिकारी
Issuing Authority

[Signature]
धारक के हस्ताक्षर
Signature of Holder

 **भारत प्रभुत्व**
Government of India



बोनुला पवन कुमार
Bohula Pavan Kumar
पुष्पक तारी/DOB: 20/08/1993
पुरुष/ MALE



6637 2011 4276
VID: 9178 8607 6484 6402

ना अकार ना सुत्तिंभु





Shreeji Multispeciality Hospital

Inspiring better health...

Shreeji Occupational Centre Shreeji Pathology Laboratory

112F, Tower-A, Senate Square, Opp. Gangotri Apartment, Vuda Char rasta, Gotri, Vadodara-390021.
M. : 9157022510, Email : shreejihospital19@yahoo.com, smh31082015@gmail.com

Name : BONULA PAVANKUMAR
Ref By : DR. SMH

Age/Sex : 28 Yrs./M
Date : 28/08/2021
Report ID. : 14


HAEMOGRAM PROFILE

TEST	RESULT	UNIT	METHOD	REFERENCE INTERVAL
BLOOD COUNTS & INDICES				
Haemoglobin	: 15.90	gm%		13.5 - 17.0 gm%
Total RBC	: 5.70	mill/cmm		4.6 - 6.2 mill/cmm
PCV	: 42.00	%		40 - 54 %
MCV	: 73.68	fL		80 - 96 fL
MCH	: 27.90	pg		27 - 31 pg
MCHC	: 37.86	%		32 - 36 %
Total WBC	: 6,200	/cmm		4,000 - 11,000/cmm
Platelet Count	: 2,74,000	/cmm		1.5 - 4.0 Lac/cmm.
DIFFERENTIAL LEUCOCYTES COUNT				
Band Cells	: 00	%		00 - 06 %
Neutrophils	: 62	%		55 - 70 %
Lymphocytes	: 35	%		20 - 40 %
Eosinophils	: 02	%		01 - 06 %
Monocytes	: 01	%		02 - 08 %
Basophils	: 00	%		00 - 01 %
Platelet In Smear	: ADEQUATE			
ERYTHROCYTES SEDIMENTATION RATE				
ESR After 1st Hour	: 6	mm	Westergren	01 - 07 mm
Blood Group	: *A*			
Rh Factor (Anti D.)	: * POSITIVE *			

(By Fully Automated Cell Counter Sysmex KX-21, Japan)

END OF REPORT




DR KRISH VAIDYA
MD, PGDCC
G-50510



SHREEJI Multispeciality Hospital

Inspiring better health...

SHREEJI OCCUPATIONAL CENTRE SHREEJI PATHOLOGY LABORATORY

112F, Tower-A, Senate Square, Opp. Gangotri Apartment, Vuda Char rasta, Gotri, Vadodara-390021.
M. : 9157022510, Email : shreejihospital19@yahoo.com, smh31082015@gmail.com

Name : BONULA PAVANKUMAR
Ref By : DR. SMH

Age/Sex : 28 Yrs./M
Date : 28/08/2021
Report ID. : 14


BIOCHEMISTRY

TEST	RESULT	UNIT	REFERENCE INTERVAL
Blood Urea Nitrogen - BUN	: 9.00	mg/dL	4.5 - 19.0 mg/dL
Serum Creatinine	: 0.60	mg/dL	0.6 - 1.4 mg/dL
Serum Uric Acid	: 4.40	mg/dL	3.4 - 7.0 mg/dL
SERUM PROTEIN			
Serum Protein Total	: 7.40	g/dL	6.6 - 8.3 g/dL
Albumin	: 5.00	g/dL	3.5 - 5.0 g/dL
Globulin	: 2.40	g/dL	2.3 - 3.5 g/dL
A/G Ratio	: 2.1	: 1	1.5 - 2.5 : 1
Bilirubin - Total	: 0.3	mg/dL	0.00 - 1.00 mg/dL
Bilirubin - Direct	: 0.1	mg/dL	Upto 0.30 mg/dL
Bilirubin - Indirect	: 0.2	mg/dL	0.1 - 1.0 mg/dL
SGPT	: 34.0	IU/L	10 - 40 IU/L
SGOT	: 18.0	IU/L	Upto 40 IU/L
Serum Alkaline Phosphatase	: 118.0	U/L	37 - 147 U/L
FASTING (FBS)			
Blood Glucose	: 95.0	mg/dL	70 - 110 mg/dL
POST-PRANDIAL			
Blood Glucose	: 114.0	mg/dL	80 - 140 mg/dL
SPECIAL TESTS			
GGTP	: 37	U/L	05 - 85 U/L
Gamma Glutamyltransferase			

Done By Fully Auto Analyzer MIURA, A-1004

END OF REPORT




DR KRISH VAIDYA
MD, PGDCC
G-50510



Shreeji Multispeciality Hospital

Inspiring better health...

SHREEJI OCCUPATIONAL CENTRE SHREEJI PATHOLOGY LABORATORY

112F, Tower-A, Senate Square, Opp. Gangolri Apartment, Vuda Char rasta, Gotri, Vadodara-390021.
M. : 9157022510, Email : shreejihospital19@yahoo.com, smh31082015@gmail.com

Name : BONULA PAVANKUMAR
Ref By : DR. SMH

Age/Sex : 28 Yrs./M
Date : 28/08/2021
Report ID. : 14

EXAMINATION OF URINE

Sample : RANDOM
PHYSICAL EXAMINATION

Quantity	: 10	ml
Colour	: PALE YELLOW	
Transparency	: CLEAR	
Specific Gravit	: 1.030	
Reaction	: ACIDIC	
Deposits	: ABSENT	

CHEMICAL EXAMINATION

Sugar	: NIL	Albumin	: NIL
Bile Salts	: ABSENT	Acetone	: ABSENT
Urobilinogen	: NORMAL : - < 1.0 mg/dL	Bile Pigments	: ABSENT
Nitrate	: ABSENT	Occult Blood	: ABSENT

MICROSCOPIC EXAMINATION

RBC	: NIL	Pus Cells	: 0-1 / hpf
Crystals	: NIL	Epithelial Cell	: NIL
Cast	: NIL	Amorphous Phosp	: NIL

THYROID FUNCTIONS

<u>TEST</u>	<u>RESULT</u>	<u>UNIT</u>	<u>REFERENCE INTERVAL</u>
Total Triiodothyronine - T3	: 1.10	ng/mL	0.58 - 1.59 ng/mL
Total Thyroxine - T4	: 10.80	ng/mL	4.87 - 11.72 microgram%
Thyroid Stl. Hormone -TSH	: 3.20	ng/mL	0.35 - 4.94 IU/mL

END OF REPORT




DR KRISH VAIDYA
MD, PGDCC
G-50510



Shreeji Multispeciality Hospital

Inspiring better health...

Shreeji Occupational Centre Shreeji Pathology Laboratory

112F, Tower-A, Senate Square, Opp. Gangotri Apartment, Vada Char rasta, Gotri, Vadodara-390021.
M. 9157022510, Email: shreejihospital19@yahoo.com, smh31082015@gmail.com

Name : BONULA PAVANKUMAR
Ref By : DR. SMH

Age/Sex : 28 Yrs./M
Date : 28/08/2021
Report ID. : 14

LIPID PROFILE

TEST	RESULT	UNIT	REFERENCE INTERVAL
Total Lipid (Calculated)	: 532	mg/dL	350 - 750 mg/dL
Serum Cholesterol	: 167.0	mg/dL	130 - 200 mg/dL
Serum Triglyceride	: 113.0	mg/dL	60 - 165 mg/dL
HDL Cholesterol	: 51.0	mg/dL	30 - 70 mg/dL
LDL Cholesterol	: 93.4	mg/dL	Upto 150 mg/dL
CHOL./HDL Chol. Ratio	: 3.27	: 1	Less than 5
LDL Chol./HDL Chol Ratio	: 1.83	: 1	Less than 3.5
VLDL (Calculated)	: 22.60	mg/dL	Upto 30 mg/dL

Hb A1C REPORT

Hb A1C - Glycated Hb Glycated Haemoglobin	: 5.1	%	Non Diabetic : 4.3 - 6.3 % Good Control : 6.4 - 7.5 % Moderate Control : 7.5 - 9.0 % Poor Control : 9.0 % & Above
Avg. Blood Glucose Level	: 104	mg/dL	
Estimated Average Glucose eAG	: 100	mg%	

END OF REPORT



DR KRISH VAIDYA
MD, PGDCC
G-50510

SHREEJI MULTISPECIALITY HOSPITAL

112/F TOWER A, SENATE SQUARE, VUDA CHOKDI, GOTRI

NAME: PAVANKUMAR BONULA
AGE/GENDER: 28 yrs/MALE

ID: 5
HEIGHT: 170 cm.

PROTOCOL: Bruce
WEIGHT: 69 Kg.

Summary report
DATE/TIME: 28-08-2021 11:20

REF. BY:
SMOKER: Non Smoker

Test Results

Protocol : Bruce Max Work load 5.81 BMI : 24
Target HR : 192(163)bpm Exer. Time : 4:30min Max RPP(1000) : 24.3
Maximum HR : 162(84 %) bpm Recov. Time : 3:24min Max BP : 150/100 mmHg

- (1) Reason for termination : Target test
Rate Achieved
- (2) Functional Capacity : Normal
- (3) HR Response to Exercise : Normal
- (4) BP Response to Exercise : Normal
- (5) Overall Impression : Normal
- (6) Comment : Normal test

- (1) Restring ECG : Normal
- (2) Chest Pain : None
- (3) ST Changes : None
- (4) Arrhythmias : None
- (5) History : None
- (6) Medication : None



Dr. Krish P. Vaidya
MD, PGDCC
Associate Consultant-Cardiology
Reg. No. 6570

DR KRISH VAIDYA (MD- G50510)

SHREEJI MULTISPECIALITY HOSPITAL

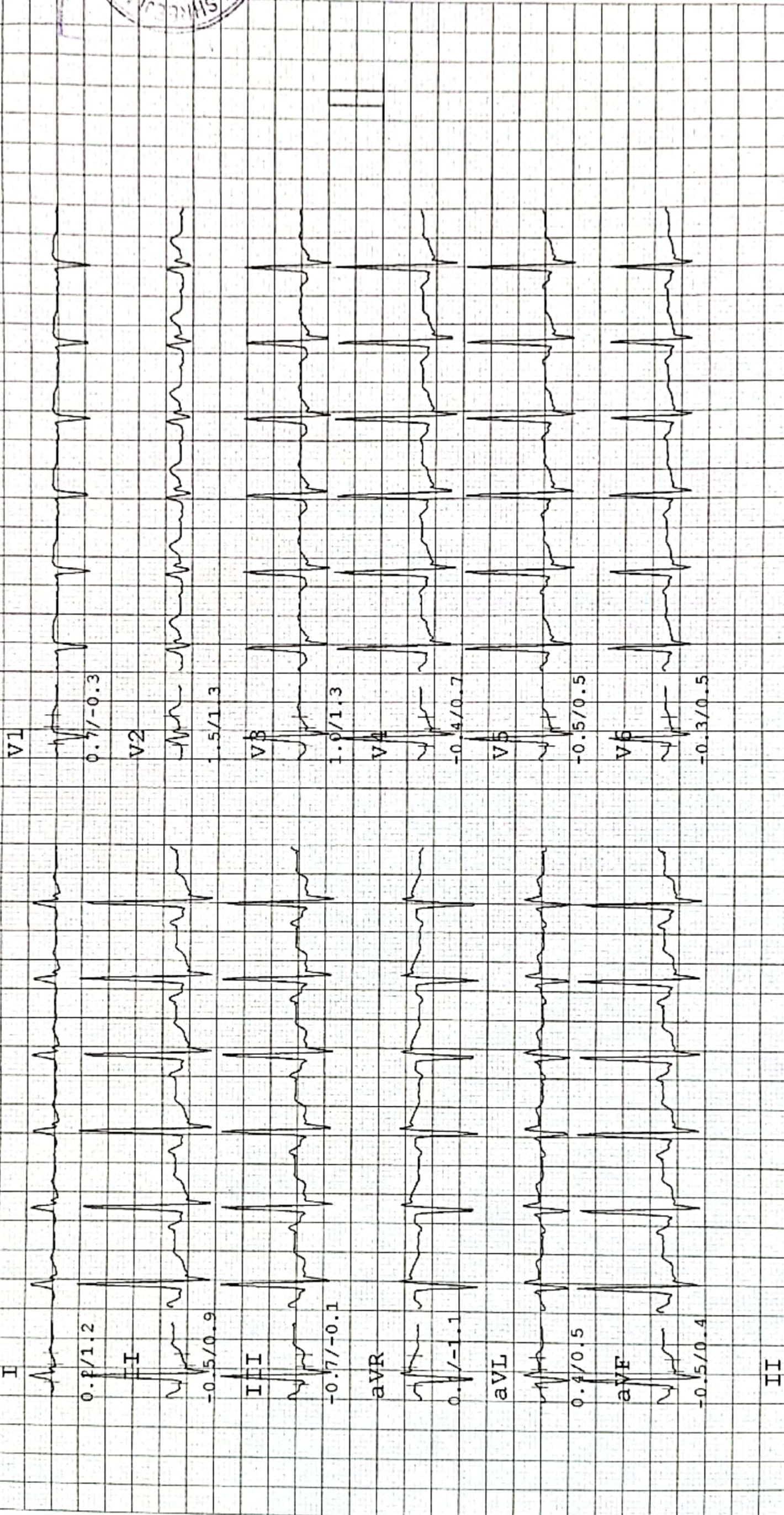
NAME: PAVANKUMAR BONULA 112/F TOWER A, SENATE SQUARE, VUDA CHOKDI, GOTRI REF. BY: Summary report
 AGE/GENDER: 28 yrs/MALE ID: 5 PROTOCOL: Bruce DATE/TIME: 28-08-2021 11:20 SMOKER: Non Smoker
 HEIGHT: 170 cm. WEIGHT: 69 Kg.



Stage	Time Min:Sec	HR bpm	BP mmHg	Speed (mph) / Gr ade (%)	Load METS	RPP	II	V2	V5
Supine	00:12	74	118/78	0.0/0.0	1.0	8.732	0.4/0.9	1.8/1.1	0.0/0.4
Standing	00:12	75	118/78	0.0/0.0	1.0	8.85	0.1/0.8	1.9/1.2	0.5/0.7
HyperV	00:12	81	118/78	0.0/0.0	1.0	9.558	0.2/0.5	1.8/1.1	0.5/0.5
Exer : 1/7	03:00	146	140/90	1.7/10.0	4.8	20.44	-0.5/-1.1	0.2/0.4	-0.4/-1.3
Exer : 2/7	01:30	166	150/100	2.5/12.0	5.8	24.9	-0.3/1.2	-0.6/0.8	-1.0/0.1
Peak	04:30	162	150/100	2.5/12.0	5.8	24.3	-0.4/1.7	1.2/1.7	-1.1/0.9
Recovery	01:00	135	140/90	0.0/0.0	1.0	18.9	1.3/3.1	1.6/2.1	0.7/2.0
Recovery	02:00	116	140/90	0.0/0.0	1.0	16.24	0.3/2.3	1.5/1.5	0.2/1.6
Recovery	03:00	122	128/86	0.0/0.0	1.0	15.616	-1.0/0.7	1.4/1.3	-0.6/0.4
Recovery	03:24	114	128/86	0.0/0.0	1.0	14.592	-0.5/0.9	1.5/1.3	-0.5/0.5

SHREEJI MULTISPECIALTY HOSPITAL

NAME : PAVANKUMAR BONULA
 AGE/GENDER : 28/MALE
 DATE/TIME : 28/Aug/2021(11:20)
 ID: 5
 BP: 128/ 86 mmHg
 HR: 114 bpm
 112/F TOWER A, SENATE SQUARE, VUDA CHOKDI, GOTRI
 PROTOCOL : Bruce
 STAGE NAME: Recovery
 STAGE TIME: 03:24
 PostJ 80
 Linked Median Report
 ST @ 10 mm/mV
 STL in mm
 STS in mm/sec



SHREEJI MULTISPECIALITY HOSPITAL



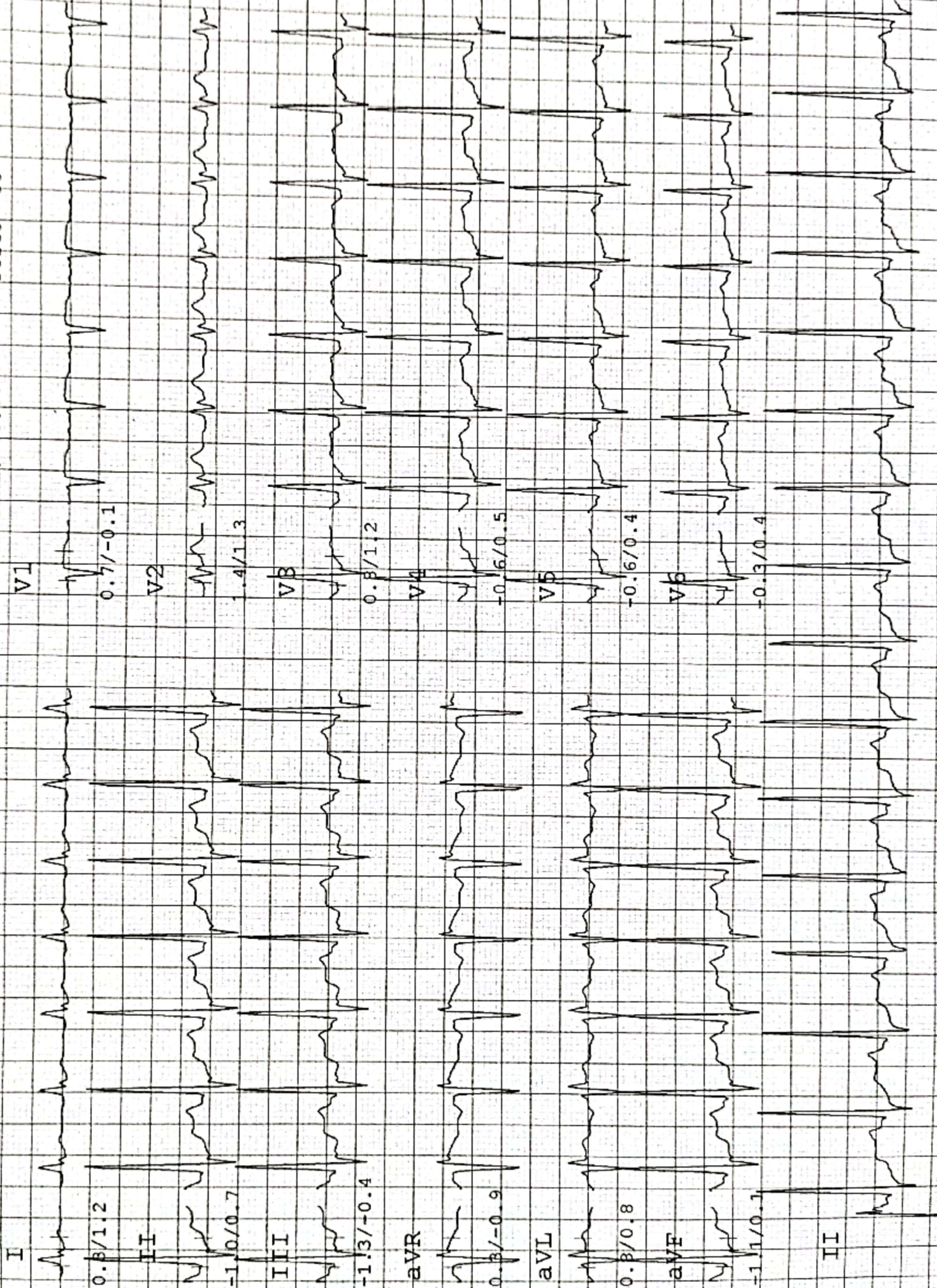
NAME : PAVANKUMAR BONULA
 AGE/GENDER : 28/MALE
 DATE/TIME : 28/Aug/2021(11:20)

ID: 5
 BP: 128/ 86 mmHg
 HR: 122 bpm

PROTOCOL : Bruce
 STAGE NAME: Recovery
 STAGE TIME: 03:00

ST @ 10 mm/mV
 STL in mm
 STS in mm/sec

PostJ 80

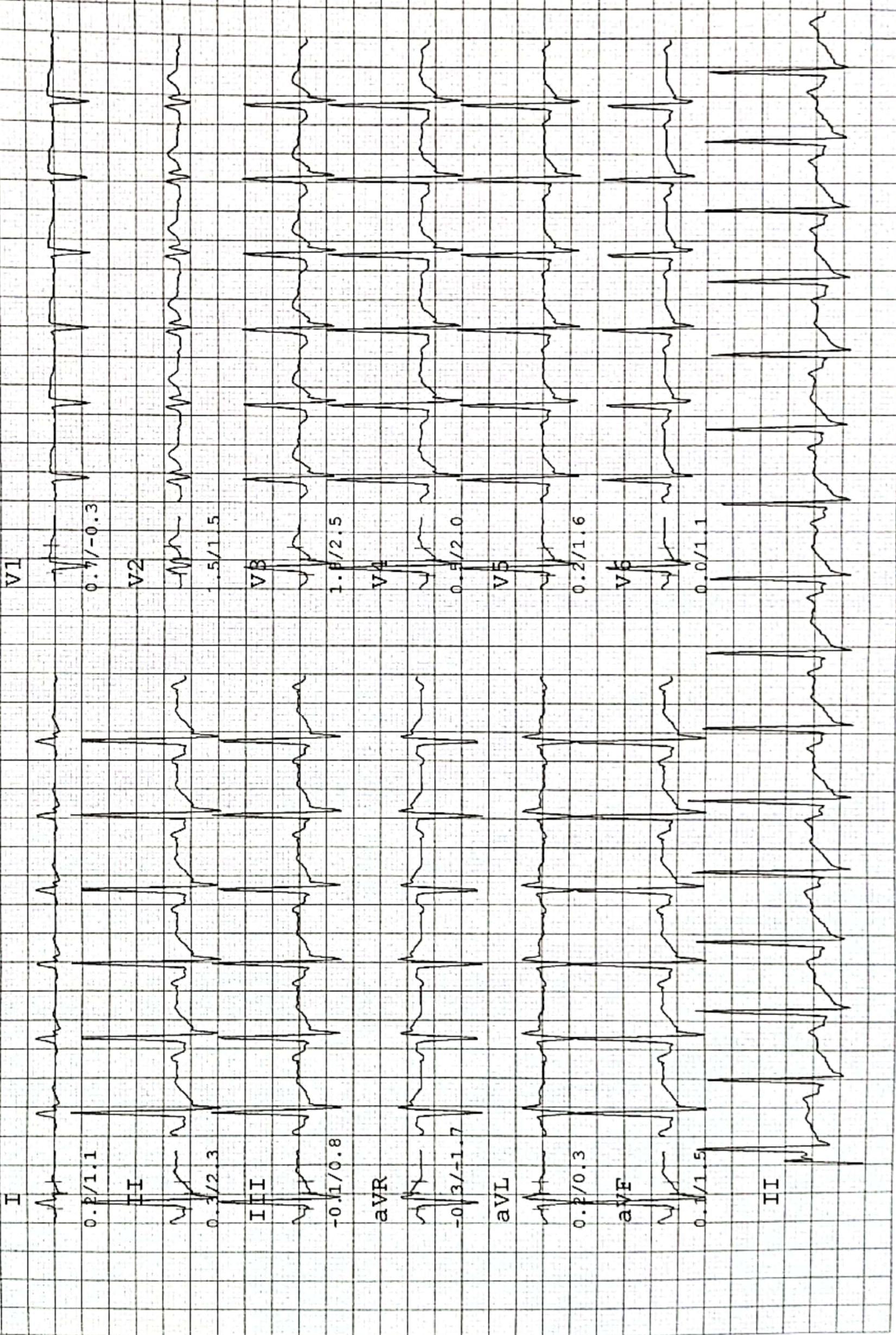



SHREEJI MULTISPECIALITY HOSPITAL

112/F TOWER A, SENATE SQUARE, VUDA CHOKDI, GOTRI

NAME : PAVANKUMAR BONULA ID: 5
 AGE/GENDER: 28/MALE BP: 140/ 90 mmHg
 DATE/TIME : 28/Aug/2021(11:20) HR: 116 bpm
 PROTOCOL : Bruce Linked Median Report
 STAGE NAME: Recovery
 STAGE TIME: 02:00 PostJ 80

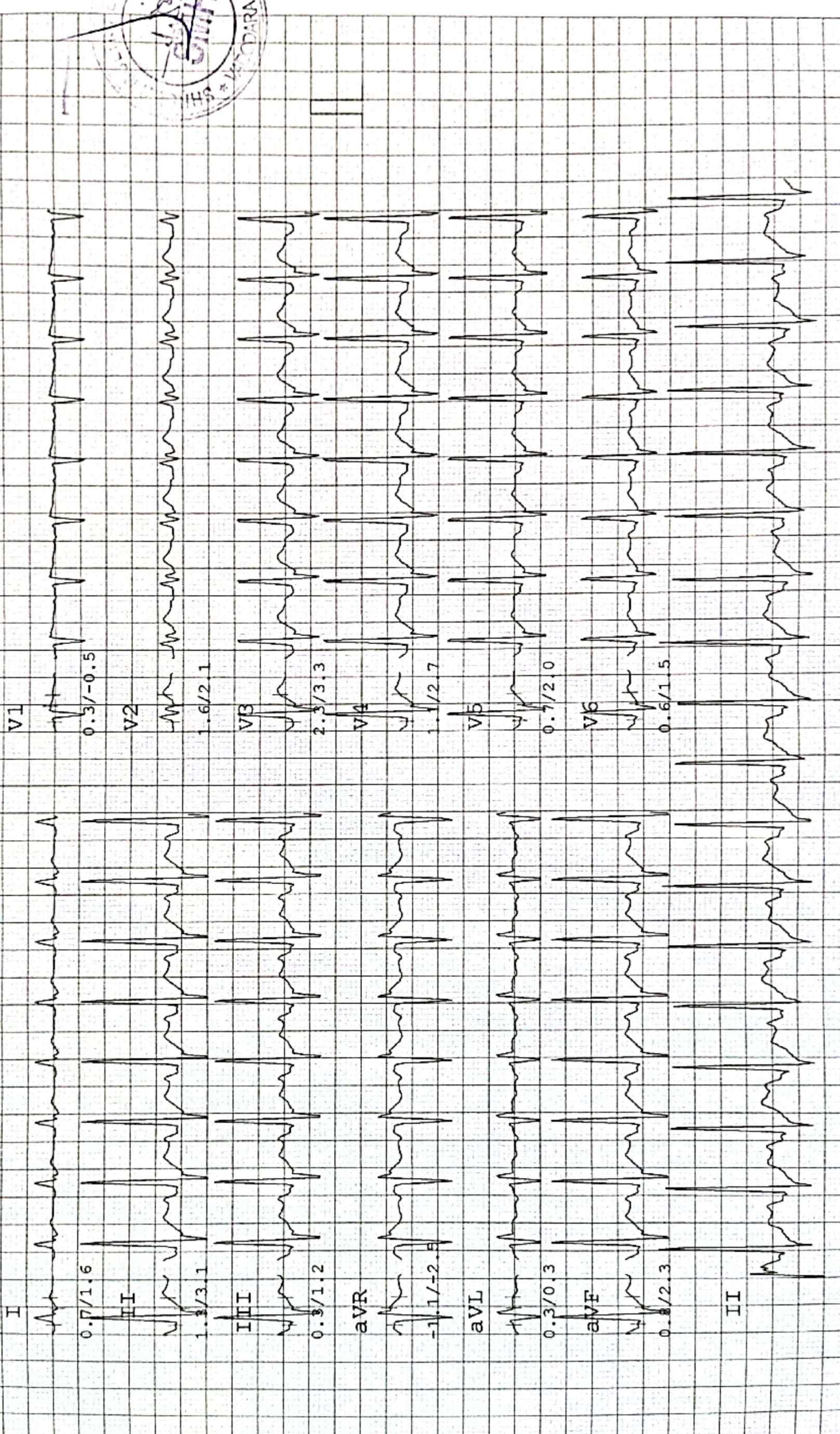
ST @ 10 mm/mV
 STL in mm
 STS in mm/sec



SHREEJI MULTISPECIALITY HOSPITAL

112/F TOWER A, SENATE SQUARE, VUDA CHOKDI, GOTRI

NAME : PAVANKUMAR BONULA	ID: 5	PROTOCOL : Bruce	Linked Median Report
AGE/GENDER: 28/MALE	BP: 140/ 90 mmHg	STAGE NAME: Recovery	STL in mm
DATE/TIME : 28/Aug/2021(11:20)	HR: 135 bpm	STAGE TIME: 01:00	STS in mm/sec



SHREEJI MULTISPECIALITY HOSPITAL

112/F TOWER A, SENATE SQUARE, VUDA CHOKDI, GOTRI

ST @ 10 mm/mV
STL in mm
STS in mm/sec

Linked Median Report

PROTOCOL : Bruce

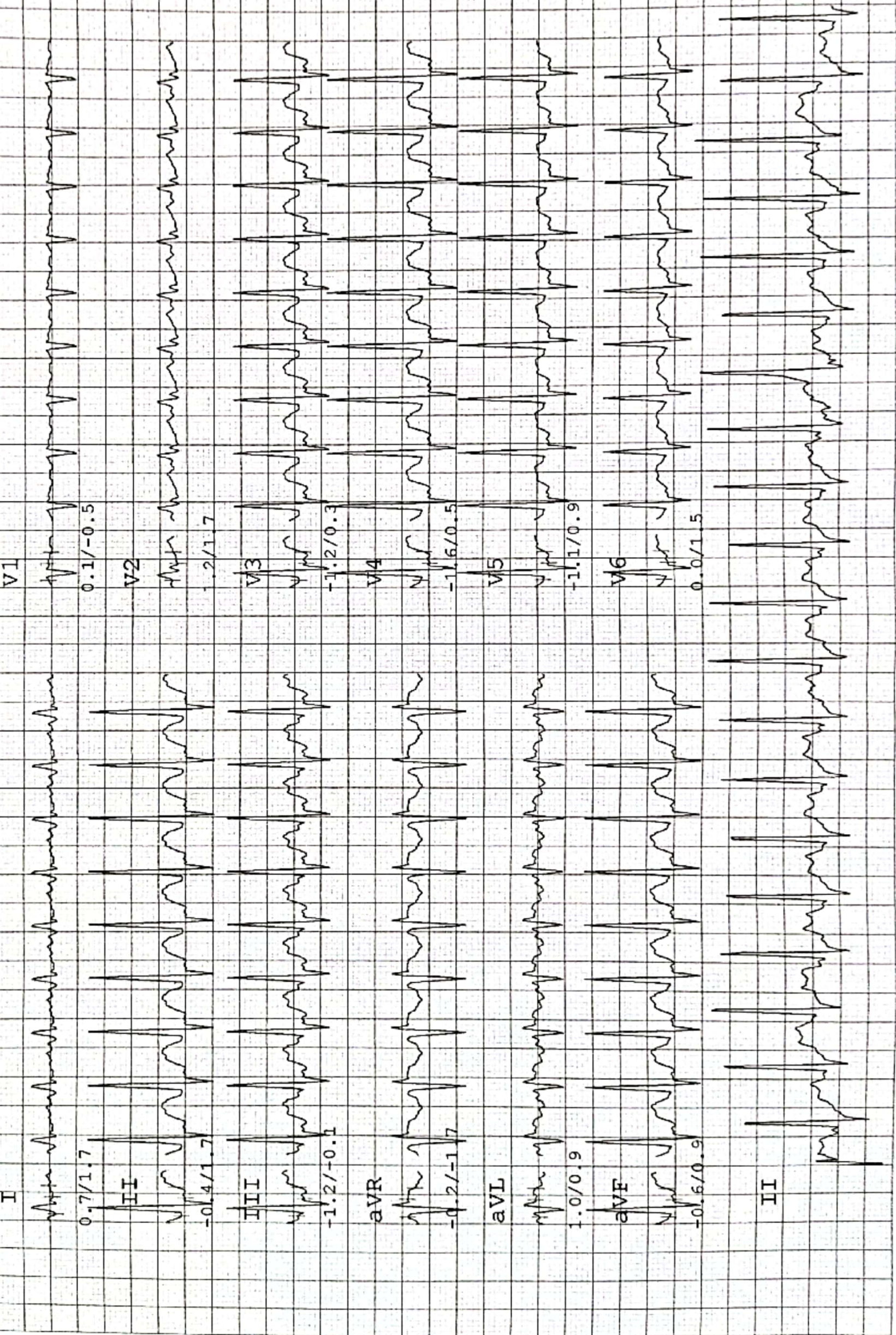
STAGE NAME: Peak

PostJ 80

NAME : PAVANKUMAR BONULA ID: 5

AGE/GENDER: 28/MALE BP: 150/100 mmHg

DATE/TIME : 28/Aug/2021(11:20) HR: 162 bpm

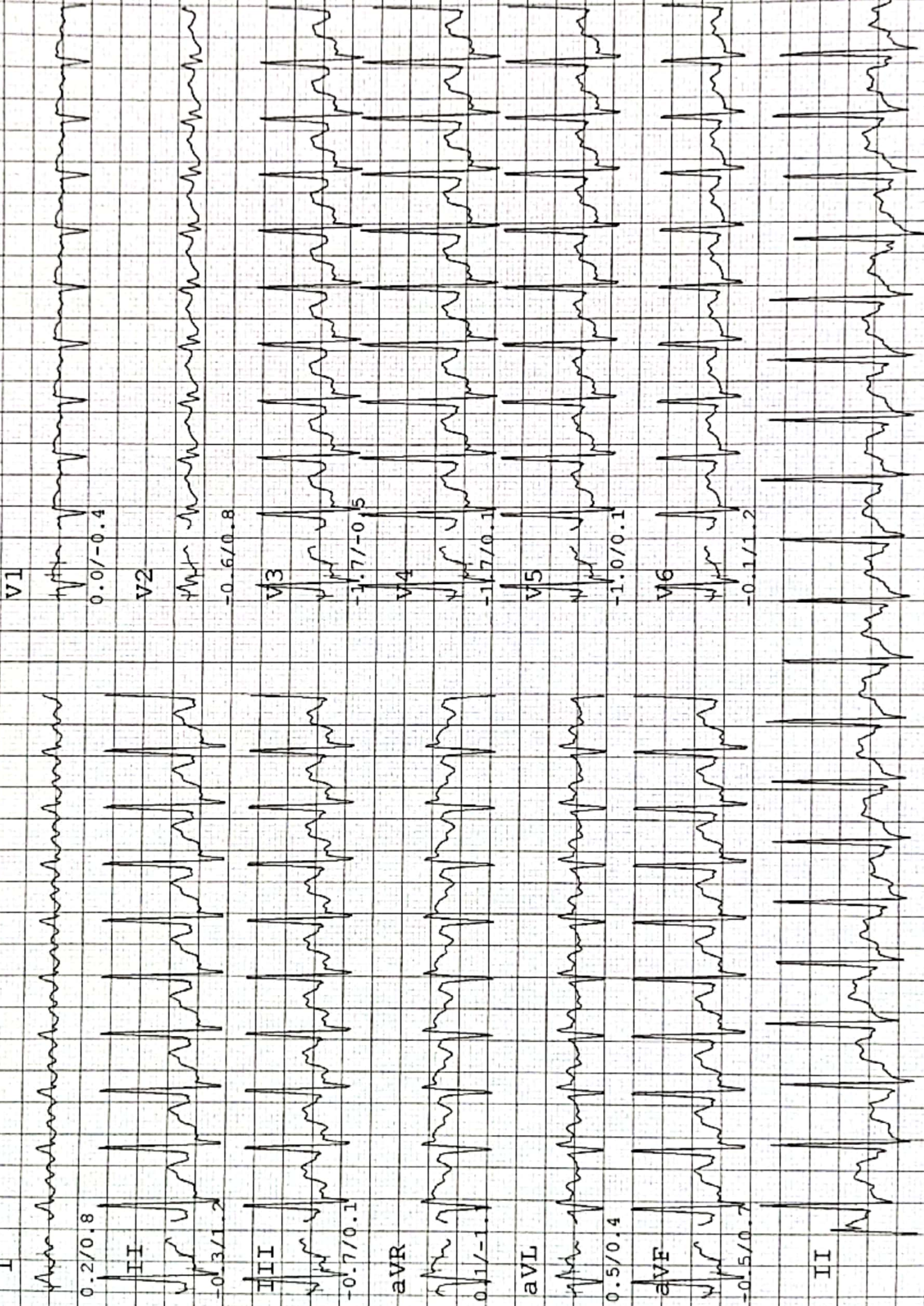


SHREEJI MULTISPECIALITY HOSPITAL

112/F TOWER A, SENATE SQUARE, VUDA CHOKDI, GOTRI

NAME : PAVANKUMAR BONULA ID: 5
AGE/GENDER: 28/MALE BP: 150/100 mmHg
DATE/TIME : 28/Aug/2021 (11:20) HR: 166 bpm
PROTOCOL : Bruce Linked Median Report
STAGE NAME: Exer : 2/7
STAGE TIME: 01:30 PostJ 80

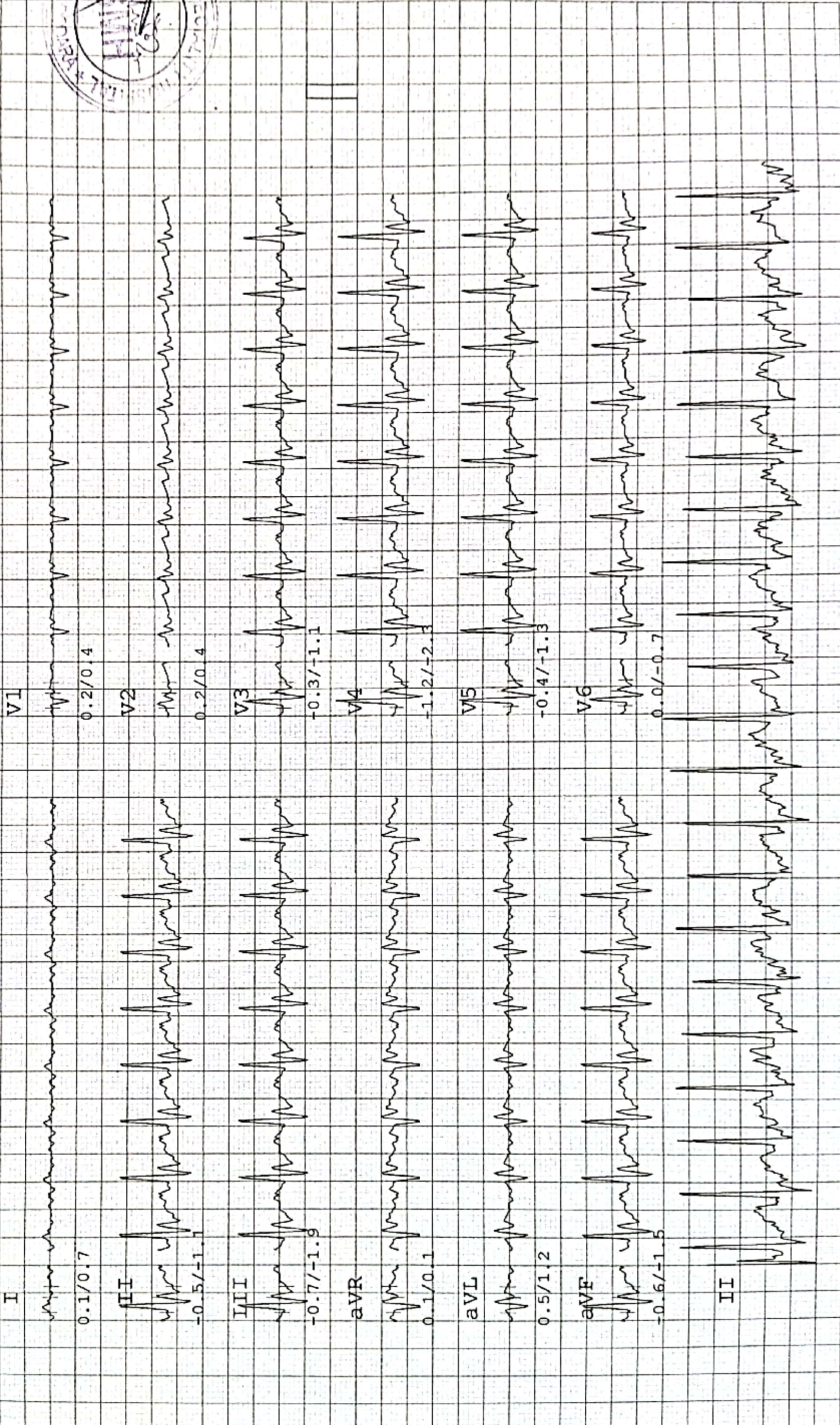
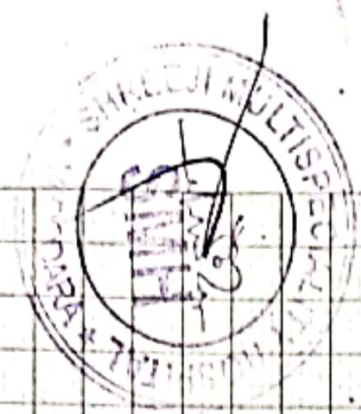ST @ 10 mm/mV
STL in mm
STS in mm/sec



SHREEJI MULTISPECIALITY HOSPITAL

112/F TOWER A, SENATE SQUARE, VUDA CHOKDI, GOTRI

NAME :	PAVANKUMAR BONULA	ID: 5	PROTOCOL :	Bruce	Linked Median Report	ST @ 10 mm/mV
AGE/GENDER:	28/MALE	BP: 140/ 90 mmHg	STAGE NAME:	Exer : 1/7		STL in mm
DATE/TIME :	28/Aug/2021(11:20)	HR: 146 bpm	STAGE TIME:	03:00	PostJ 80	STS in mm/sec



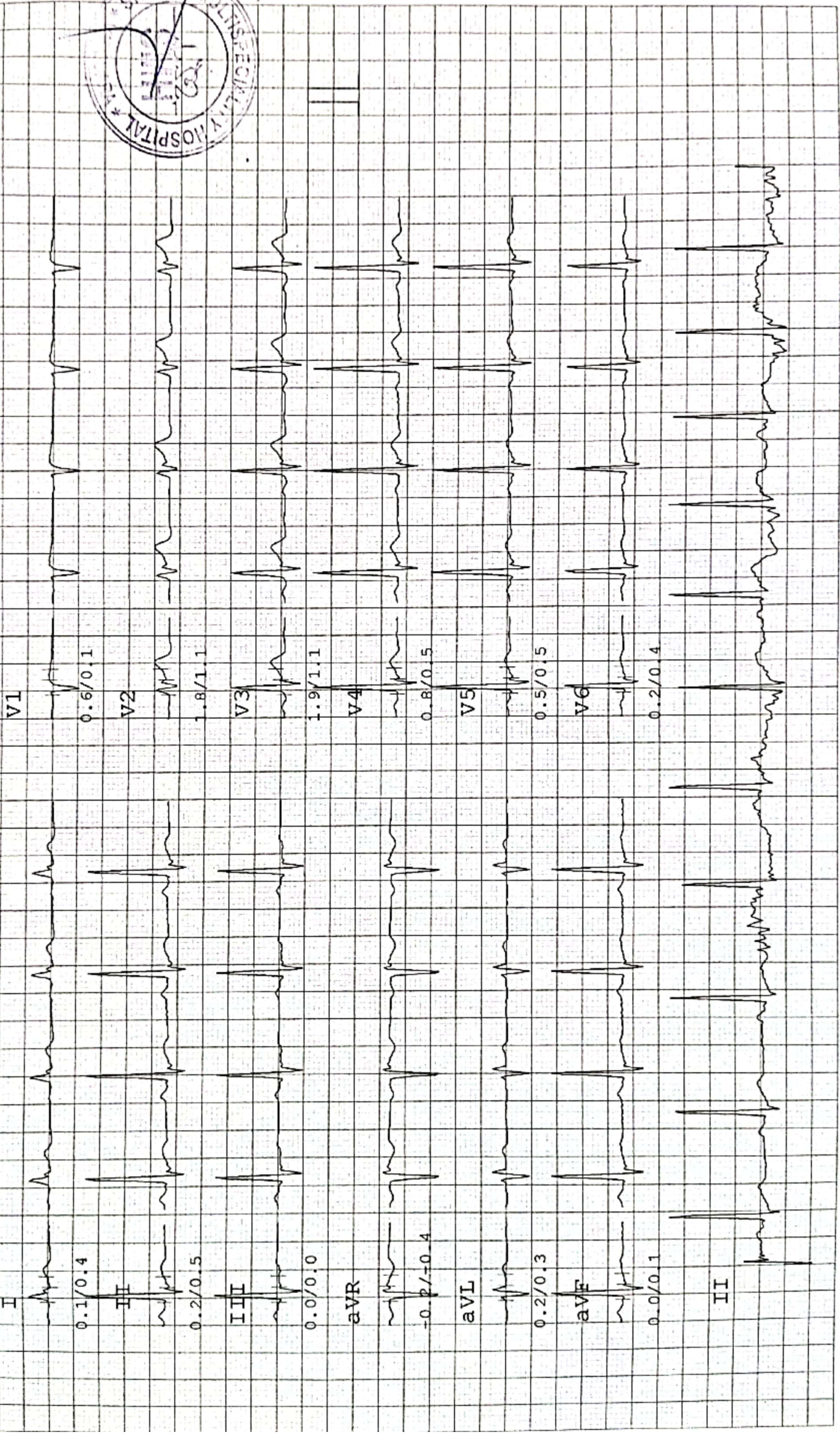
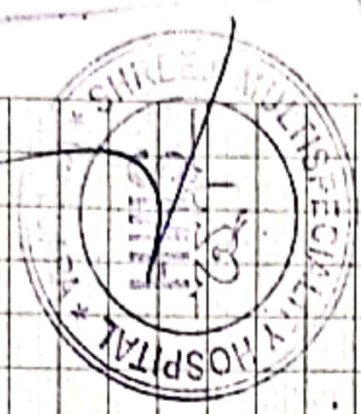
SHREEJI MULTISPECIALITY HOSPITAL

NAME : PAVANKUMAR BONULA
 AGE/GENDER: 28/MALE
 DATE/TIME : 28/AUG/2021(11:20)

ID: 5
 BP: 118/ 78 mmHg
 HR: 81 bpm

SQUARE, VUDA CHOKDI, GOTRI
 PROTOCOL : Bruce
 STAGE NAME: HyperV
 STAGE TIME: 00:12
 PostJ 80

ST @ 10 mm/mV
 STL in mm
 STS in mm/sec



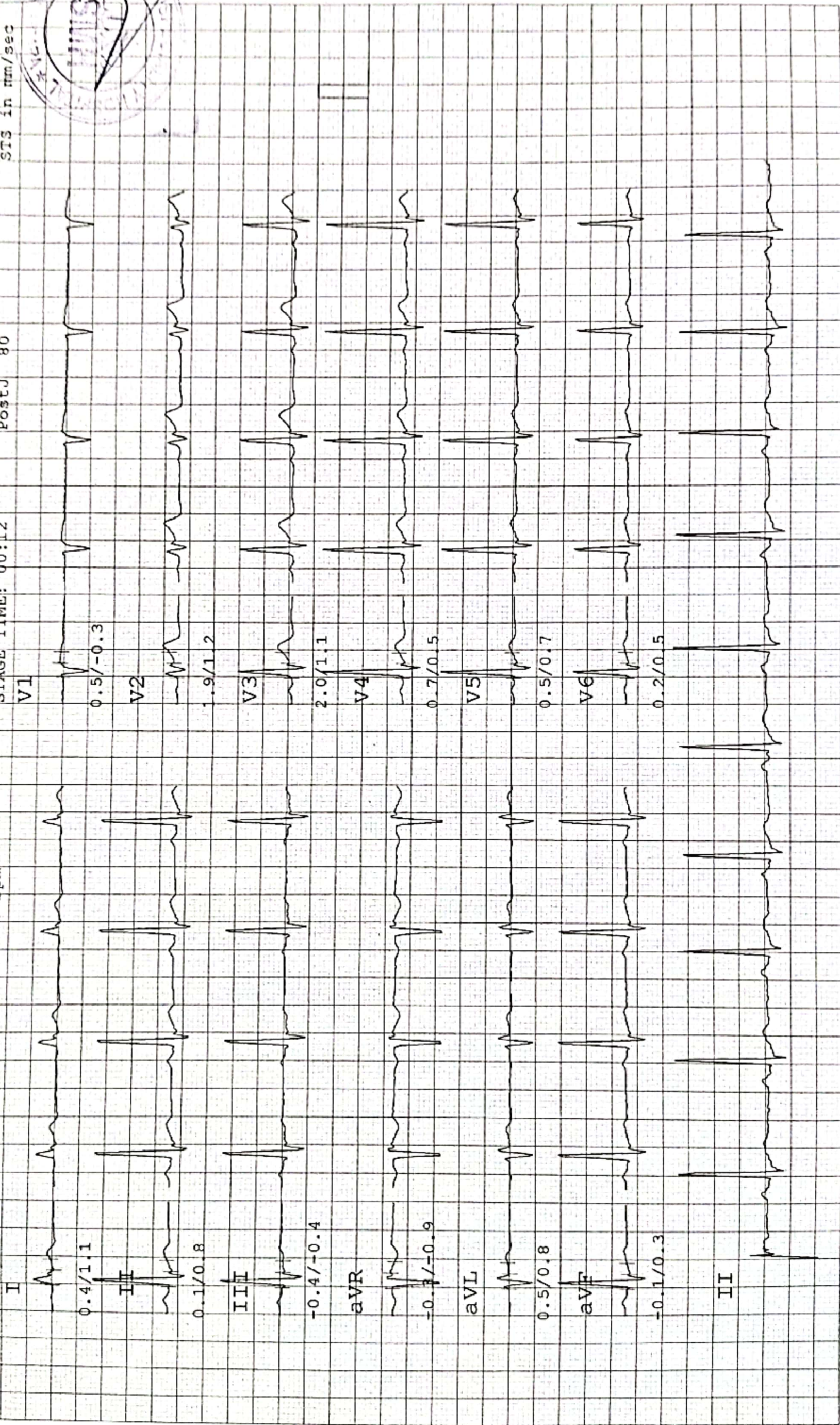SHREEJI MULTISPECIALITY HOSPITAL

NAME : PAVANKUMAR BONULA
AGE/GENDER: 28/MALE
DATE/TIME : 28/Aug/2021(11:20)

112/F TOWER-A, SENATE SQUARE, VUDA CHOKDI, GOTRI
ID: 5
BP: 118/ 78 mmHg
HR: 75 bpm

ST @ 10 mm/mV
STL in mm
STS in mm/sec

PROTOCOL : Bruce
STAGE NAME: Standing
STAGE TIME: 00:12 PostJ 80



SHREEJI MULTISPECIALITY HOSPITAL

112/F TOWER A, SENATE SQUARE, VUDA CHOKDI, GOTRI

NAME : PAVANKUMAR BONULA

AGE/GENDER: 28/MALE

DATE/TIME : 28/Aug/2021(11:20)

ID: 5

BP: 118/ 78 mmHg

HR: 74 bpm

PROTOCOL : Bruce

STAGE NAME: Supine

STAGE TIME: 00:12

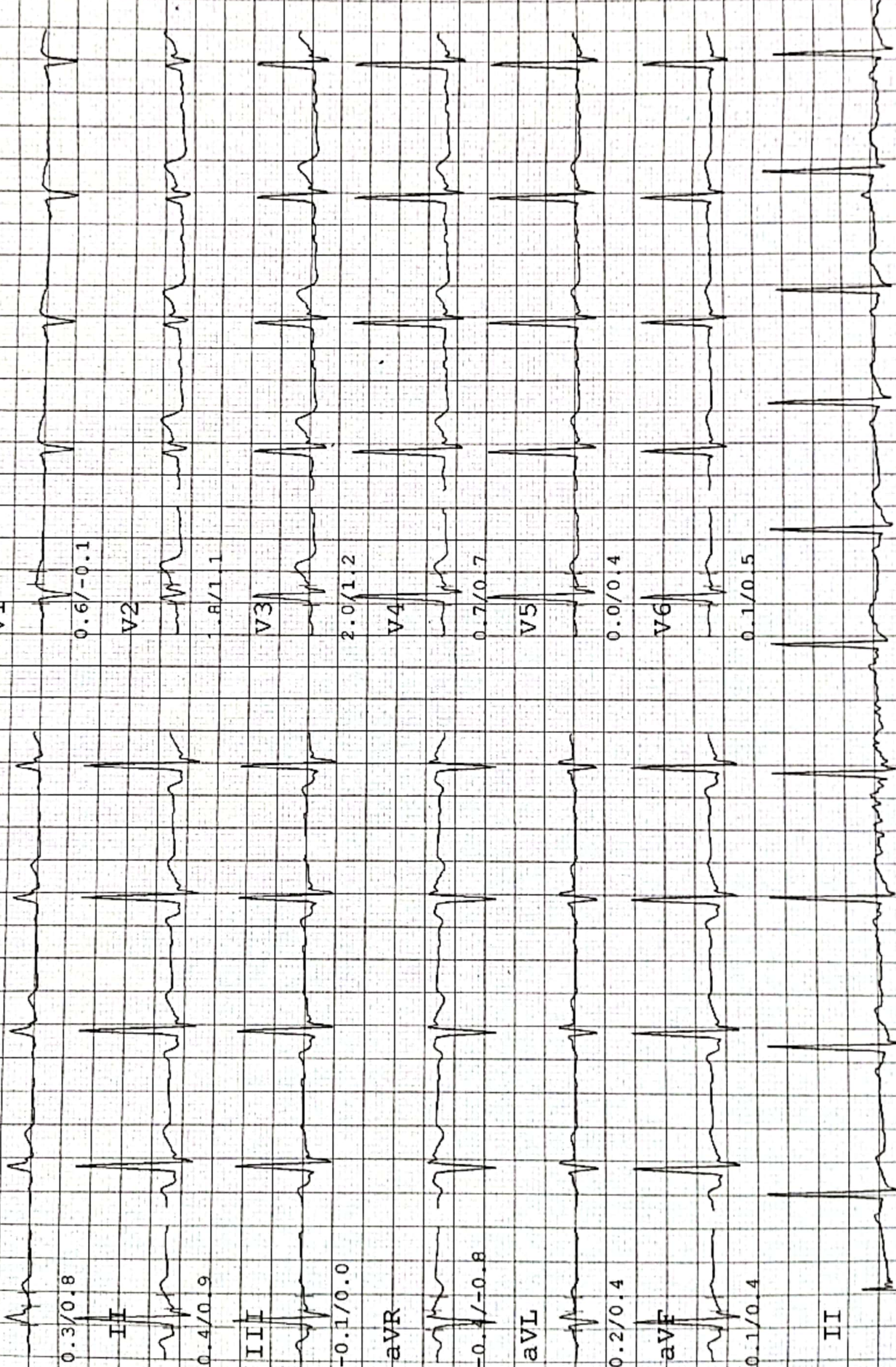
Linked Median Report

PostJ 80

ST @ 10 mm/mV

STL in mm

STS in mm/sec



PARAMOUNT DIAGNOSTIC & RESEARCH CENTRE

(A Unit of Paramount Charity Trust)

Radiology ■ Pathology ■ Histopathology ■ Molecular Biology

NAME : PAVAN KUMAR BONULA

AGE : 28 Y/M

DATE : 28/08/2021

X RAY CHEST (PA)

OBSERVATIONS:

- Both the lung fields and apices appear clear.
- Both the hilar shadow appears normal.
- Cardiac silhouette appears normal.
- Both the costophrenic sinuses are clear.
- Mediastinal and tracheal shadows are normal.
- Both the domes of diaphragm are normal.
- Visualized rib cage and clavicle are normal.

COMMENTS:

No significant abnormality is seen.

DR. HENY GANDHI
CONSULTANT RADIOLOGIST



24 hours Emergency Service Available for CT Scan / MRI / Pathology AMBULANCE SERVICE AVAILABLE

Main Branch : Paramount Complex, Gotri Road, Race Course, Vadodara. Ph.: 0265 - 2395772, 2397438, 6647222, +91 - 6352731483,

Path. Lab : 0265 - 6603900/901/902/903, +91 - 8160225911, +91 - 9099066029

City Branch : Opp. Brahman Sabha Hall, Pratap Road, Dandiabazar, Vadodara. Ph.: 0265 - 2423233, +91 - 6352734810

PARAMOUNT DIAGNOSTIC & RESEARCH CENTRE

(A Unit of Paramount Charity Trust)

Radiology ■ Pathology ■ Histopathology ■ Molecular Biology

NAME : PAVAN KUMAR BONULA	AGE : 28 Y/M	DATE : 28/08/2021
---------------------------	--------------	-------------------

ULTRASOUND WHOLE ABDOMEN

Liver is normal in size and shows normal parenchymal reflectivity. No focal lesion is seen. Hepatic veins appear normal. There is no evidence of any dilated intra hepatic biliary radicals.

Portal Vein appears normal in diameter. **Common Bile Duct** is of normal diameter.

Gallbladder is distended with normal wall thickness. There is no evidence of gallstones. No evidence of peri-cholecystic fluid or probe tenderness.

Pancreas is normal in size and shows homogenous reflectivity. There is no evidence of any calcification or ductal dilatation.

Spleen is normal size and shows a homogenous echotexture. There is no evidence of any focal lesion.

Both Kidneys are normal in position and size. They show normal cortical reflectivity and cortico-medullary distinction. Right kidney measures 104x48mm. Left kidney measures 102x54mm. There is no evidence of renal calculi, hydronephrosis or mass seen.

Bladder is physiologically distended and shows normal wall thickness. No evidence of intraluminal mass or calculi.

Prostate gland is normal in size. It shows smooth walls and homogeneous echotexture. Estimated volume is around 24cc.

There is no evidence of ascites.

No evidence of any gross bowel mass seen.

No evidence of any aorto-caval or mesenteric root lymphadenopathy.

CONCLUSION:

- No significant sonographic abnormality is detected.


DR. HENRY GANDHI
CONSULTANT RADIOLOGIST



24 hours Emergency Service Available for CT Scan / MRI / Pathology **AMBULANCE SERVICE AVAILABLE**
Main Branch : Paramount Complex, Gotri Road, Race Course, Vadodra. Ph.: 0265 - 2395772, 2397438, 6647222, +91 - 6352731483,
Path. Lab : 0265 - 6603900/901/902/903, +91 - 8160225911, +91 - 9099066029
City Branch : Opp. Brahman Sabha Hall, Pratap Road, Dangliabazar, Vadodra. Ph. 0265 - 2401222