




भारतीय विशिष्ट पहचान प्राधिकरण
Unique Identification Authority of India



पता:
S/O: ओम प्रकाश, सा-7/5 आर-1, बेनीपुर, सारनाथ,
वाराणसी, वाराणसी,
उत्तर प्रदेश - 221007

Address:
S/O: Om Prakash, SA-7/5 R-1, BENIPUR,
SARNATH, Varanasi, Varanasi,
Uttar Pradesh - 221007



8434 1690 4857

VID : 9144 1694 9573 3994



1947



help@uidai.gov.in



www.uidai.gov.in



GPS Map Camera

Varanasi, Uttar Pradesh, India

44-B3, Durgakund, Bhelupur, Varanasi, Uttar Pradesh 221001, India

Lat 25.289246°

Long 82.993301°

18/02/23 10:31 AM GMT +05:30



भारत सरकार
Government of India



Download Date: 19/12/2020



अनुराग कुमार
Anurag Kumar
जन्म तिथि/DOB: 24/10/1990
पुरुष/ MALE

Issue Date: 18/07/2018

8434 1690 4857

VID : 9144 1694 9573 3994

मेरा **आधार**, मेरी पहचान



GPS Map Camera

Varanasi, Uttar Pradesh, India

44-B3, Durgakund, Bhelupur, Varanasi, Uttar Pradesh 221001, India

Lat 25.289246°

Long 82.993301°

18/02/23 10:31 AM GMT +05:30

Facilities:

All clinical Biomedical & Hematology Investigations including Bone Marrow Examination VPT, Podiascan & Complete Foot Care (First Time in Purvanchal) All Hormonal Investigation by Chemiluminescent Method Visceral Fat by (AB-140) Ambulatory BP Monitoring CGMS & Insulin Pump Available PFT, 2D-ECHO (Color Doppler), Holter, TMT, Cardiac-3 available VIA, VILI, Colposcopy available Special Endocrinological Investigation Protocols.

ISO 9001:2008 Certified
Mobile: 9389994334, 9554572190, 9453837595



Panacea Pathology

Clinical Reference Lab

Persistence, Preparedness and Precision
EQAS (CMC Vellore Attached) & IQAS System
पूर्वांचल की सर्वोत्तम गुणवत्ता वाली पैथोलॉजी

PATIENT NAME : ANURAG KUMAR	AGE/GENDER : 32YRS/MALE
REFD BY DR. : ARCO FEMI HEALTHCARE LTD.	RECEIVED DATE : 18-02-2023 (10:00 AM)
SAMPLE : BLOOD & URINE	REPORT DATE : 18-02-2023 (07:00 PM)

PATHOLOGY REPORT

COMPLETE BLOOD COUNT (CBC)

TEST	LAB TEST VALUES	NORMAL RANGE
HEMOGRAM		
HEMOGLOBIN (FLOW CYTOMETRY)	13.3	13 – 16 gm/dl
TOTAL LEUCOCYTE COUNT (TLC)	6,200	4000 – 11000
RBC COUNT	5.00	3.5 – 5.5
PCV (HCT)	43.1	37 – 47
MCV	86.3	80 – 95
MCH	26.7	28 – 34
MCHC	30.9	30 – 36
PLATELET COUNT	1,69,000	1,50,000 – 4,00,000
E.S.R. (WINTROBE FIRST HOURS)	11.0	20 mm/1 st hr
DIFFERENTIAL LEUCOCYTE		
NEUTROPHILS	54	40 – 75%
LYMPHOCYTES	37	20 – 45%
EOSINOPHILS	04	1 – 6%
MONOCYTES	05	2 – 8%
BASOPHILS	00	< 2%

RANDOM/FASTING BLOOD SUGAR

TEST	LAB TEST VALUES	NORMAL RANGE
RBS/FBS		
RANDOM BLOOD SUGAR	120.0	125-140 mg/dl
FASTING BLOOD SUGAR	84.4	70-125 mg/dl

GLYCOSYLATED HEMOGLOBIN (HBA1C)

TEST	LAB TEST VALUES	NORMAL RANGE
HBA1C	7.7	Normal : <5.97 % Good Control : 5.97 – 6.81% Fair Control : 6.81 – 7.65% Poor Control : >7.65%

PAGE 1

Lab Technician

PANACEA HOSPITAL
(A UNIT OF AARON HEALTH CARE PVT. LTD)
REG. NO. AL-1500
B.36/44, B-4, KABIR NAGAR
DURGAKUND, VARANASI
M.D. Pathology

Timing : 8.00 a.m. to 9.00 p.m. (Sunday 8.00 a.m. to 3.00 p.m.)

This Report is not valid for medico legal purpose

Note: These tests have technical limitations. Clinico-pathological interpretation is necessary. In case of any disparity test may be repeated immediately.

Address : 36/44 FK Kabir Nagar, Durgakund, Varanasi – 221005

Email: dramishra@gmail.com, drpallaviojha@gmail.com Website: panaceahospital.org

Facilities:
 All clinical Biomedical & Hematology Investigations
 including Bone Marrow Examination
 VPT, Podiascan & Complete Foot Care (First Time in Purvanchal)
 All Hormonal Investigation by Chemiluminescent Method
 Visceral Fat by (AB-140) Ambulatory BP Monitoring
 CGMS & Insulin Pump Available
 PFT, 2D-ECHO (Color Doppler), Holter, TMT, Cardiac-3 available
 VIA, VILI, Colposcopy available
 Special Endocrinological Investigation Protocols.

ISO 9001:2008 Certified
 Mobile: 9389994334, 9554572190, 9453837595



Panacea Pathology

Clinical Reference Lab

Persistence, Preparedness and Precision
 EQAS (CMC Vellore Attached) & IQAS System
 पूर्वांचल की सर्वोत्तम गुणवत्ता वाली पैथोलॉजी

PATIENT NAME : ANURAG KUMAR

AGE/GENDER : 32YRS/MALE

REFD BY DR. : ARCO FEMI HEALTHCARE LTD.

RECEIVED DATE : 18-02-2023 (10:00 AM)

SAMPLE : BLOOD & URINE

REPORT DATE : 18-02-2023 (07:00 PM)

PATHOLOGY REPORT

LIPID PROFILE, SERUM

TEST	LAB TEST VALUES	NORMAL RANGE
BLOOD CHEMISTRY		
TOTAL CHOLESTEROL (SERUM)	173.0	Desirable:- & lt; 200 mg/dl Borderline:- 200 – 239 mg/dl High:- & gt; 240 mg/dl
TRIGLYCERIDES (SERUM)	158.0	35 – 170 mg/dl
HDL CHOLESTEROL (SERUM)	41.0	35.30 – 79.50 mg/dl
LDL CHOLESTEROL (SERUM)	100.4	& lt; 130 mg/dl
VLDL	31.6	& lt; 40 mg/dl
CHOLESTROL/HDL RATIO	4.21	& lt; 3.0 Low Risk Ratio 3.0 – 5.0 Avg Risk & lt; 5.0 High Risk
LDL/HDL RATIO	2.44	& lt; 3 Ratio

BLOOD GROUP

TEST	LAB TEST VALUES
BLOOD GROUP ABO & RH FACTOR	
BLOOD GROUP	"A"
RH FACTOR	POSITIVE

LIVER PROFILE TEST, SERUM

TEST	LAB TEST VALUES	NORMAL RANGE
BIO CHEMISTRY		
TOTAL BILIRUBIN	0.69	0.0 – 1.1 mg/dl
DIRECT BILIRUBIN	0.29	0.0 – 0.2 mg/dl
INDIRECT BILIRUBIN	0.40	< 0.90 mg/dl
SGOT (AST)	28.0	0 – 52 mg/dl
SGPT (ALT)	31.0	0 – 39 mg/dl
GGT (GYT)	24.0	< 55 U/L

THYROID PROFILE (T3, T4, TSH)

TEST	LAB TEST VALUES	NORMAL RANGE
THYROID FUNCTION TEST		
T3	1.06	0.60 – 1.81 ng/ml
T4	7.56	4.50 – 10.90 ug/dl
TSH	1.92	0.39 – 6.10 uIU/mL

PAGE 2

Lab Technician

PANACEA HOSPITAL
 (A UNIT OF AARCO HEALTH CARE PVT. LTD)
 M.D., Pathology
 B-36/44, B-4, KABIR NAGAR

Timing : 8.00 a.m. to 9.00 p.m. (Sunday 8.00 a.m. to 3.00 p.m.)

This Report is not valid for medico legal purpose

Note: These tests have technical limitations. Clinico-pathological interpretation is necessary. In case of any disparity test may be repeated immediately.

Address : 36/44 FK Kabir Nagar, Durgakund, Varanasi – 221005

Email: dramishra@gmail.com, drpallaviojha@gmail.com Website: panaceahospital.org

Facilities:

All clinical Biomedical & Hematology Investigations including Bone Marrow Examination
VPT, Podiascan & Complete Foot Care (First Time in Purvaanchal)
All Hormonal Investigation by Chemiluminescent Method
Visceral Fat by (AB-140) Ambulatory BP Monitoring
CGMS & Insulin Pump Available
PFT, 2D-ECHO (Color Doppler), Holter, TMT, Cardiac-3 available
VIA, VILI, Colposcopy available
Special Endocrinological Investigation Protocols.

ISO 9001:2008 Certified
Mobile: 9389994334, 9554572190, 9453837595



Panacea Pathology

Clinical Reference Lab

Persistence, Preparedness and Precision
EQAS (CMC Vellore Attached) & IQAS System
पूर्वांचल की सर्वोत्तम गुणवत्ता वाली पैथोलॉजी

PATIENT NAME : ANURAG KUMAR

AGE/GENDER : 32YRS/MALE

REFD BY DR. : ARCO FEMI HEALTHCARE LTD.

RECEIVED DATE : 18-02-2023 (10:00 AM)

SAMPLE : BLOOD & URINE

REPORT DATE : 18-02-2023 (07:00 PM)

PATHOLOGY REPORT

RENAL & KIDNEY PROFILE, SERUM

TEST	LAB TEST VALUES	NORMAL RANGE
RENAL FUNCTION TESTS		
BLOOD UREA NITROGEN (BUN)	10.2	10 – 50 mg/dl
SERUM CREATININE	0.76	0.60 – 1.60 mg/dl
URIC ACID	4.16	3.60 – 7.70 mg/dl
ALKALINE PHOSPHATASE (ALP)	72.0	142 – 353 mg/dl
TOTAL PROTIENS	7.52	0 – 39 mg/dl
ALBUMIN	4.20	3.8 – 5.4 mg/dl
SERUM GLOBULIN	3.32	2.1 – 3.5 mg/dl
CALCIUM	9.2	8.80 – 10.20
PHOSPHORUS	3.04	2.50 – 5.00
SERUM SODIUM NA+	140.6	135.00 – 155.00 mEq/Ltr
SERUM POTASIUM K+	4.32	3.60 – 5.50 mEq/Ltr
ICALCIUM	1.24	1.10 – 1.35 mmol/L
SERUM CHLORIDE CL+	105.9	98.00 – 110.00 mEq/Ltr

URINE ROUTINE EXAMINATION

TEST	LAB TEST VALUES	NORMAL RANGE
PHYSICAL EXAMINATION		
QUANTITY	30	ML
COLOUR	STRAW	PALE YELLOW
APPEARANCE	CLEAR	CLEAR
SPECIFIC GRAVITY	1.010	1.01 – 1.03
PH	6.5	4.7 – 7.5
CHEMICAL EXAMINATION		
GLUCOSE	Not Detected	Not Detected
PROTEIN	NIL	Not Detected
MICROSCOPIC EXAMINATION		
PUS CELLS	NIL	0-5
RBC	Not Detected	Not Detected
EPITHELIAL CELLS	01-02	0-5
CASTS	Not Detected	Not Detected
CRYSTALS	Not Detected	Not Detected
BACTERIA	Not Detected	Not Detected

----- End of Report -----

Lab Technician

PANACEA HOSPITAL
(A UNIT OF ARCO FEMI HEALTH CARE PVT
REG. NO. 1500
B.36/44, B-4, KABIR NAGAR
DURGAKUND, VARANASI

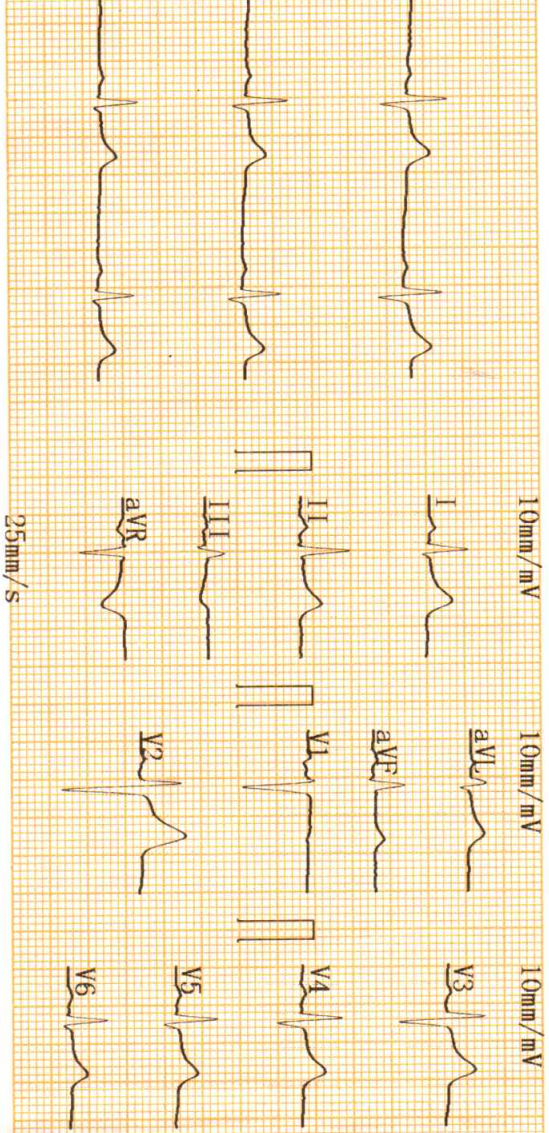
Timing : 8.00 a.m. to 9.00 p.m. (Sunday 8.00 a.m. to 3.00 p.m.)

This Report is not valid for medico legal purpose

Note: These tests have technical limitations. Clinico-pathological interpretation is necessary. In case of any disparity test may be repeated immediately.

Address : 36/44 FK Kabir Nagar, Durgakund, Varanasi – 221005

Email : dramishra@gmail.com, drpallaviojha@gmail.com **Website:** panaceahospital.org



2023-02-18 11:50

ID :
 Name :
 Sex :
 Height :
 SYS :
 DIA :
 Age :
 Weight : kg

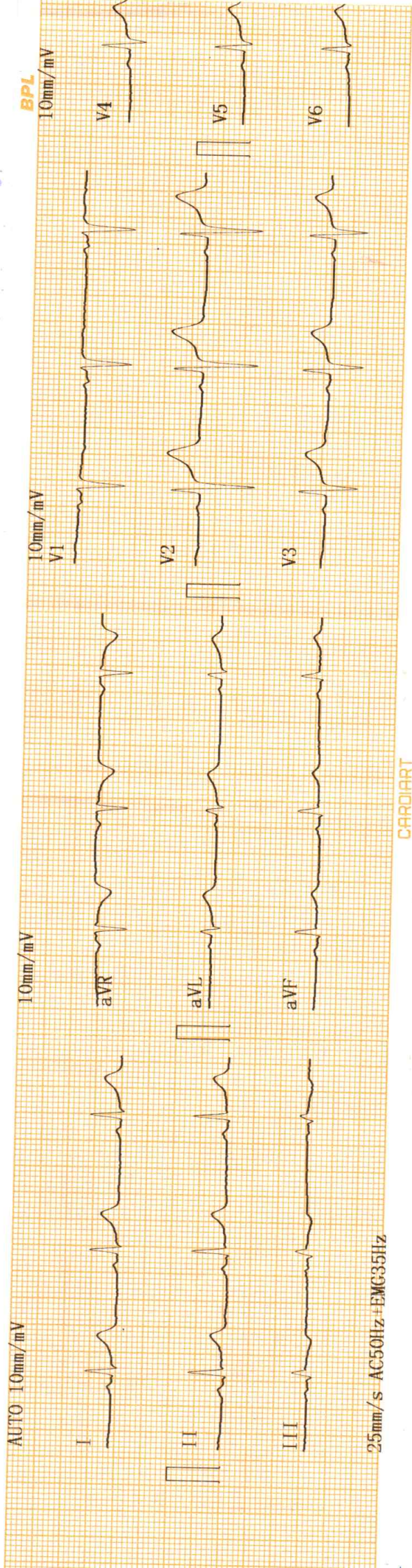
<< Conclusions >>
 Normal Sinus Rhythm;
 Cardiac electric axis normal;
 Report need physician confirm

HR [bpm] : 61
 PR Interval [ms] : 160
 P Duration [ms] : 107
 QRS Duration [ms] : 77
 T Duration [ms] : 201
 QT/QTc [ms] : 389/393
 P/QRS/T Axis [deg] : 40.2/49.2/26.6
 R(V5)/S(V1) [mV] : 0.54/0.85
 R(V5)+S(V1) [mV] : 1.39

CARDIART

Physician

DR. PALLAVI MISRA
 MBBS, MD (GENERAL MEDICINE)
 MCI Reg. No. 52033



AUTO 10mm/mV

10mm/mV

10mm/mV

BPL 10mm/mV

I

II

III

aVR

aVL

aVF

V1

V2

V3

V4

V5

V6

25mm/s AC50Hz+EMG35Hz

CARDIART



Call Now - 1800-123-3070

PANACEA HOSPITAL

A shelter for many hearts A Home for many lives

(An ISO 9001:2008 Certified Organisation)

Lab Attached with CMC Vellore Under EQAS Scheme

Name	MR.ANURAG KUMAR	Sex /Age	32/M	Date	18/02/2023
Ref. by	Dr.Pallavi Mishra(MD)	BSA - m ²		Echo window	fair

Echo - Cardiography

MITRAL VALVE Doppler	AML - normal morphology MV Flow - E - 0.7 A-0.4 E/A=1.79	PML - normal morphology MVA - 3.0 cm ² Mitral Regurgitation - No
TRICUSPID VALVE Doppler	Normal TV Flow -No	Tricuspid Regurgitation - No
PULMONARY VALVE Doppler	Normal PV Flow -No	Pulmonary Regurgitation - No
AORTIC VALVE Doppler	Trileaflet-No AV Flow - no	Aortic Regurgitation - no
MEASUREMENT	Aorta - 29.7 (20-38) mm IVS ed - 14.3 (6 -12) mm LVID ed - 49.7 (35 - 55) mm LVPW ed - 12.0 (6 -12) mm OA - 7 (> 5) mm	LA - 36.6 (24-32) mm IVS es -17.1 (6 - 12) mm LVID es - 31.4 (24 - 40) mm LVPW es - 14.8 (6 -12) mm EPSS - 4 (< 9) mm

CONCLUSION

All cardiac chamber dimensions are WNL
 No valvular abnormalities
 Good LV systolic function present Modified Simpson's method (4C, 2C) (LVEF-66%)
 No diastolic dysfunction present (E/A = 1.79) by tissue Doppler (E/e'=6.2)
 No RWMA
 No pericardial effusion
 Intact IAS / IV
 No PAH
 No intra cardiac mass /thrombus /vegetation

IMPRESSION **Normal Echocardiogram**

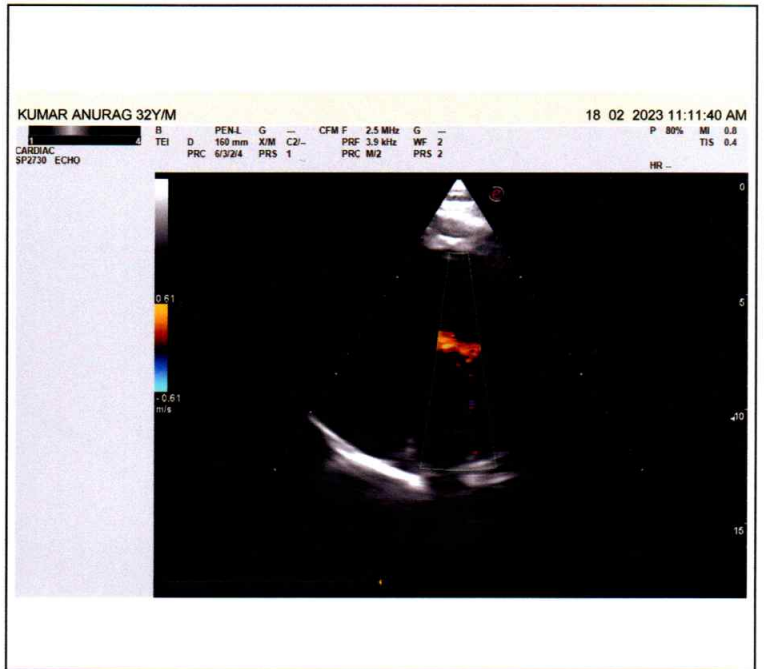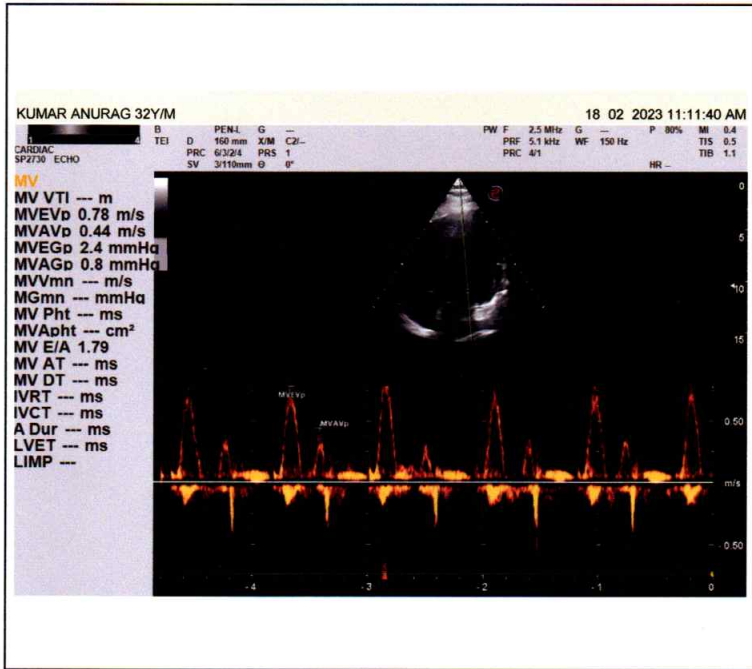
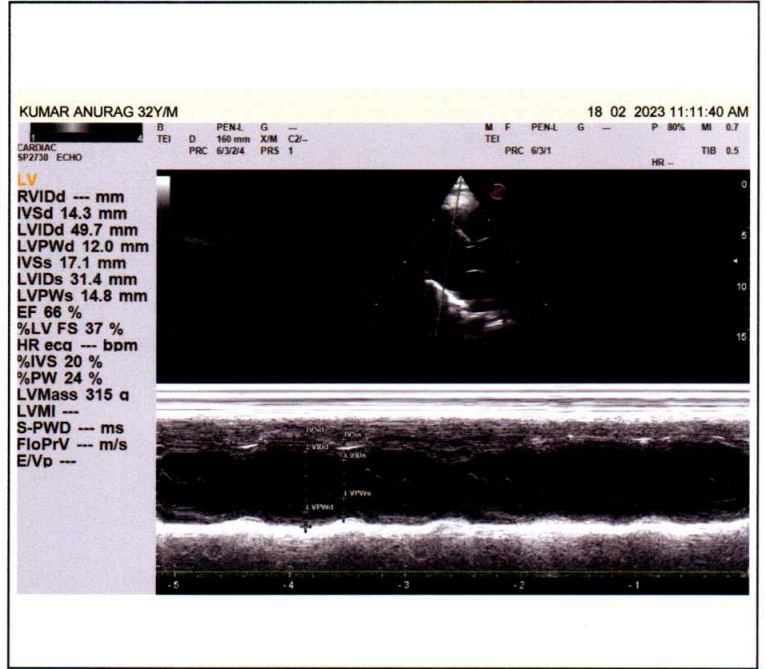
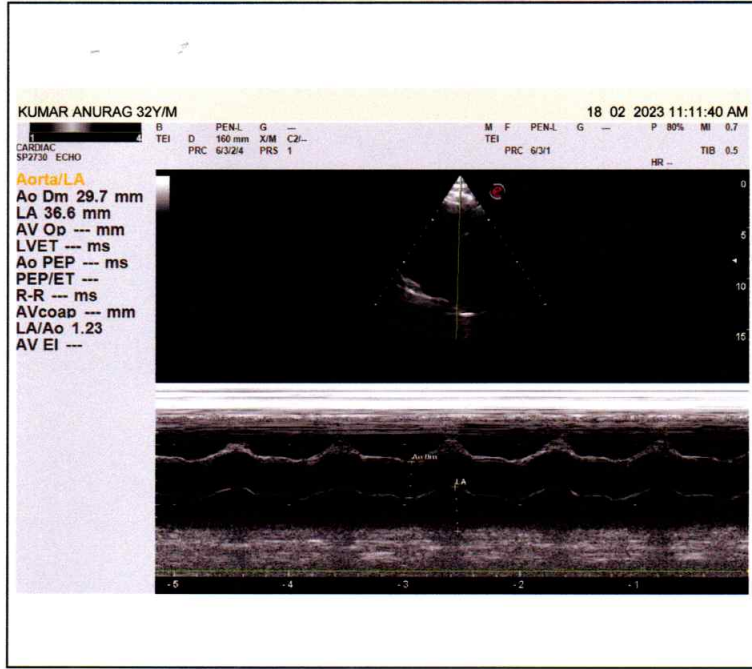

 Niraj Mishra
 Physician Assistant
 (PIRE)

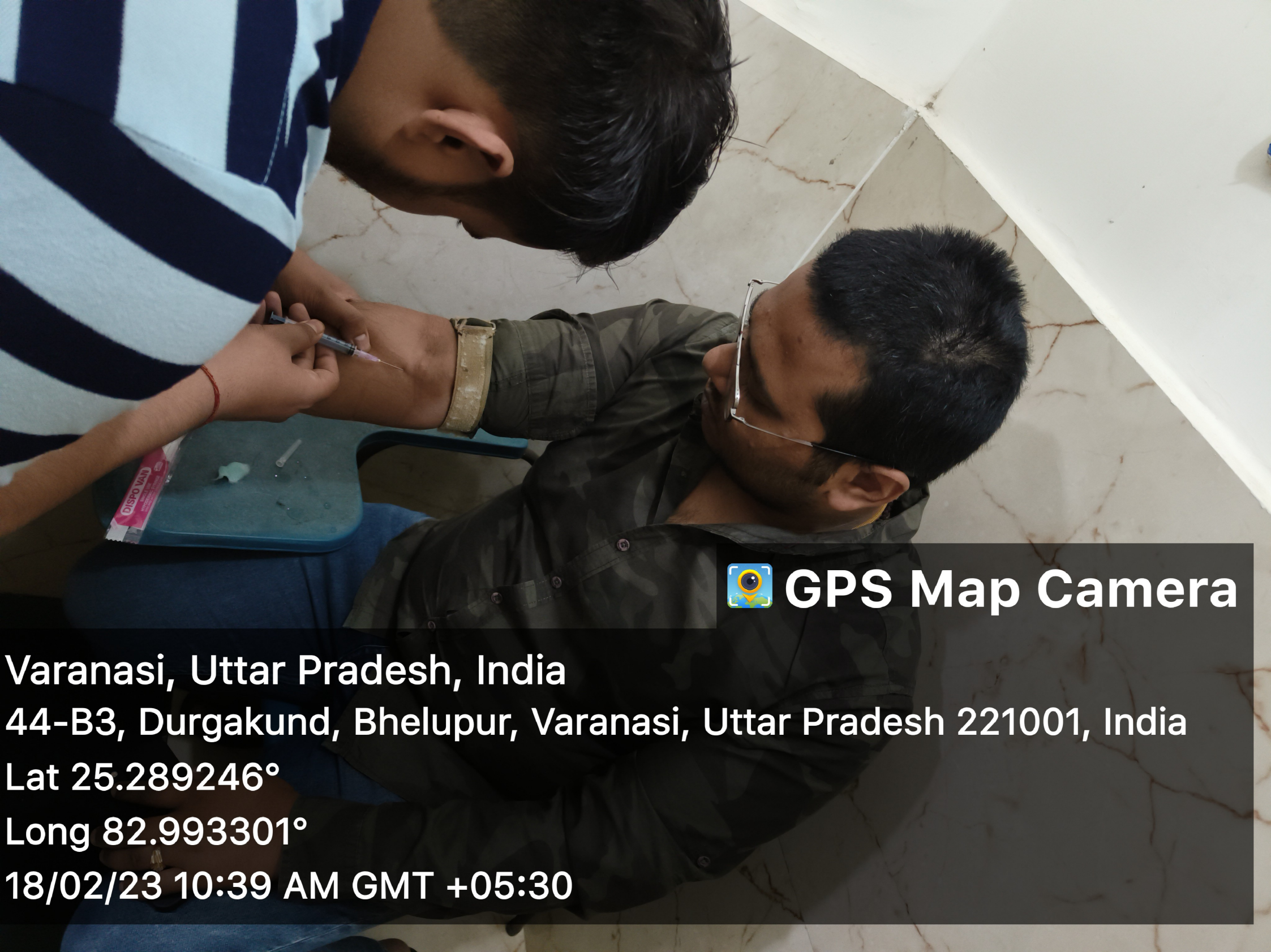

DR. PALLAVI MISHRA
 MBBS, MD (GENERAL MEDICINE)
 MBBS, MD (MED) Lucknow
 MCL Reg No. 52033
 Echocardiography Specialist, MIAE
 Non-invasive cardiologist
 Women Cardiologist
 Diabetocardiologist

Address : Kabir Nagar (Near Sanjay Shiksha Niketan), Durgakund, Varanasi

Mobile : 9554572190 / 9453837595 / Recpn. 9389994334

E-mail : dramishra@gmail.com, drpallaviojha@gmail.com, Website: www.piire.org





GPS Map Camera

Varanasi, Uttar Pradesh, India

44-B3, Durgakund, Bhelupur, Varanasi, Uttar Pradesh 221001, India

Lat 25.289246°

Long 82.993301°

18/02/23 10:39 AM GMT +05:30

Panacea Hospital

Diabetes Care Organisation

Many Hearts
Home For Many Lives



GPS Map Camera

Varanasi, Uttar Pradesh, India

44-B3, Durgakund, Bhelupur, Varanasi, Uttar Pradesh 221001, India

Lat 25.289246°

Long 82.993301°

18/02/23 10:31 AM GMT +05:30



Call Now - 1800-123-3070

PANACEA HOSPITAL

A shelter for many hearts A Home for many lives

(An ISO 9001:2008 Certified Organisation)

Lab Attached with CMC Vellore Under EQAS Scheme

NAME: MR.ANURAG KUMAR

AGE/SEX: 32 YRS / MALE

REF BY: DR. ASHUTOSH MISHRA (MD)

DATE: 18/02/2023

ULTRA SOUND WHOLE ABDOMEN REPORT

Liver: Normal in shape and size (12.9 cm) and shows mildly increased echogenicity. Margins are smooth and regular. No focal lesion seen.

Gall bladder: Partially distended with normal wall thickness and echo-free lumen.

CBD Visualized part normal in course & caliber.

Pancreas: Normal in size, shape & echogenicity. Margins are smooth & regular. No diffuse/ focal lesion seen.

Spleen: Normal in size shape & echogenicity. Margins are smooth & regular. No diffuse / focal lesion seen. Splenic vessels at hilum is normal.

Kidney: Right kidney: 10.6 X 5.8cm Left kidney: 10.2 X 4.7 cm Normal cortical echogenicity with well maintained Cortical-medullary differentiation., Pelvicalyceal system normal. No calculus/mass lesion seen. No hydronephrosis/ hydroureter seen.

Urinary bladder: Normally distended, wall thickness is normal. No echogenic foci lumen or diverticula seen. Both VUJ appears normal. No E.R. calculus / mass lesion seen

Prostate: Normal in size, shape, & echogenicity. No calcification or focal cystic lesion seen. Capsular margins are smooth and regular. Seminal vesicles appear normal in size, shape & echogenicity. No diffuse /focal lesion seen.

Others: No free fluid in peritoneal cavity. No free fluid in bilateral pleural cavity.

Impression:

- **Grade i fatty liver.**

Please correlate clinically and further investigations.


REPORTED BY

DR. R. K. TIWARI

MD RADIODIAGNOSIS (GOLD MEDALIST)

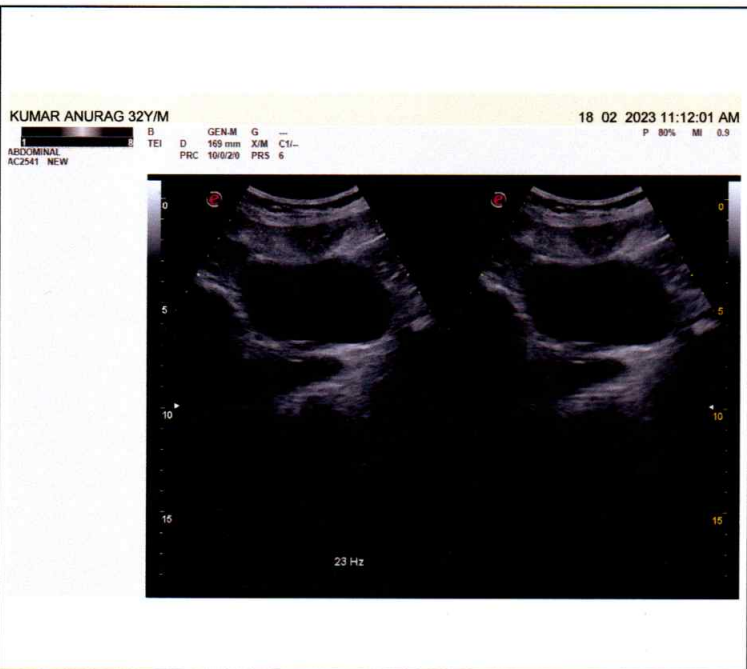
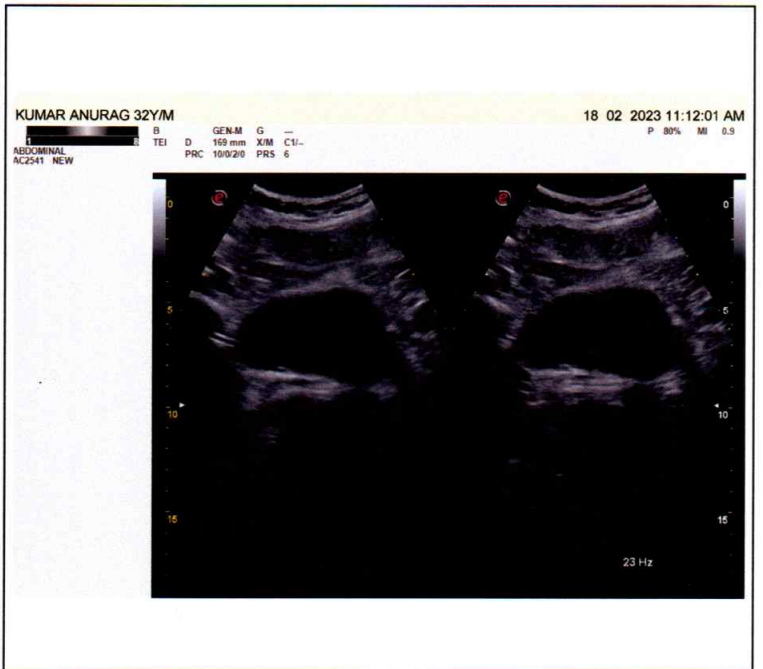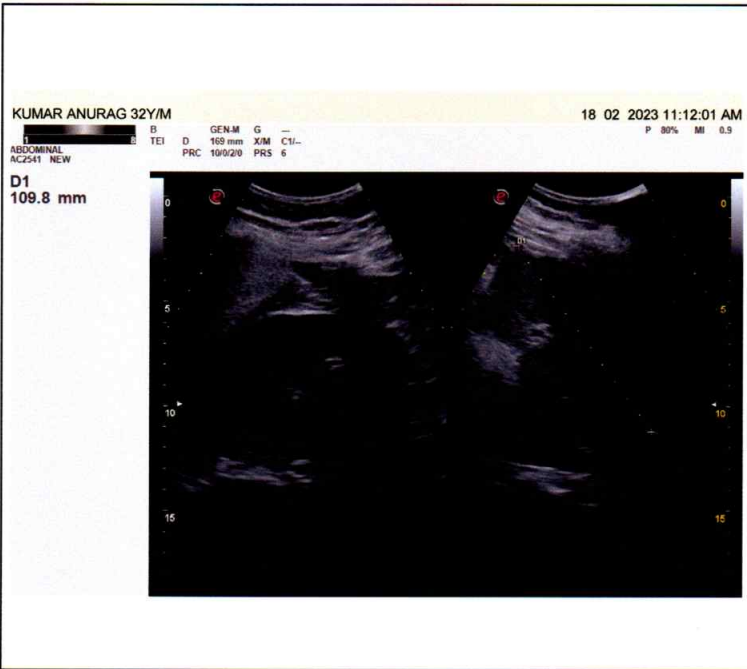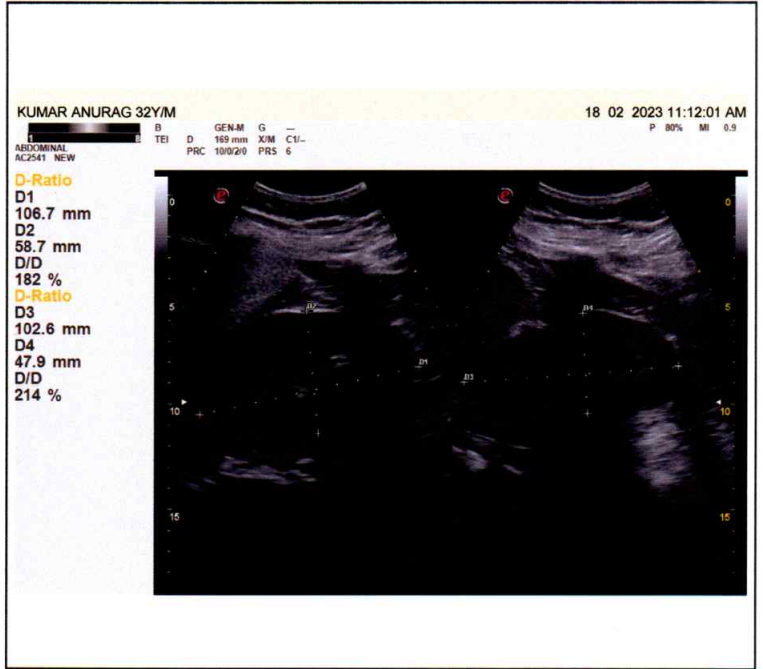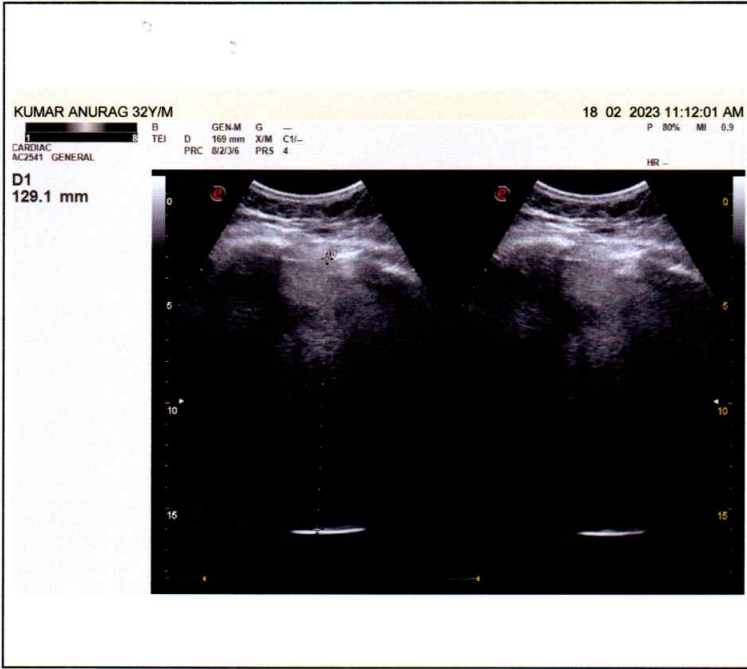KG MU, LUCKNOW

Reg.No. 57557

Address : Kabir Nagar (Near Sanjay Shiksha Niketan), Durgakund, Varanasi

Mobile : 9554572190 / 9453837595 / Recpn. 9389994334

E-mail : dramishra@gmail.com, drpallaviojha@gmail.com, Website: www.piire.org





Call Now - 1800-123-3070

PANACEA HOSPITAL

A shelter for many hearts A Home for many lives

(An ISO 9001:2008 Certified Organisation)

Lab Attached with CMC Vellore Under EQAS Scheme

NAME: MR.ANURAG KUMAR

AGE/SEX: 32 YRS / MALE

REF BY: DR. ASHUTOSH MISHRA (MD)

DATE: 18/02/2023

X-RAY CHEST PA

BOTH LUNG FIELDS AND PLEURAE:

Both lungs show normal bronchovascular pattern.

Right & left hila are normal

No focal mass or calcification is seen

There is no evidence of any fluid in the both the pleural cavities.

Both domes of diaphragms are normal in position.

MEDIASTINUM:

Trachea is central in position.

Cardiac silhouette is of normal size and configuration.

No evidence of pericardial effusion.

No significant lymphadenopathy is seen.

Visualized skeleton is normal.

NO SIGNIFICANT RADIOGRAPHIC ABNORMALITY.

REPORTED BY

DR. Rahul Kumar Tiwari

MBBS, MD (Radio Diagnosis)

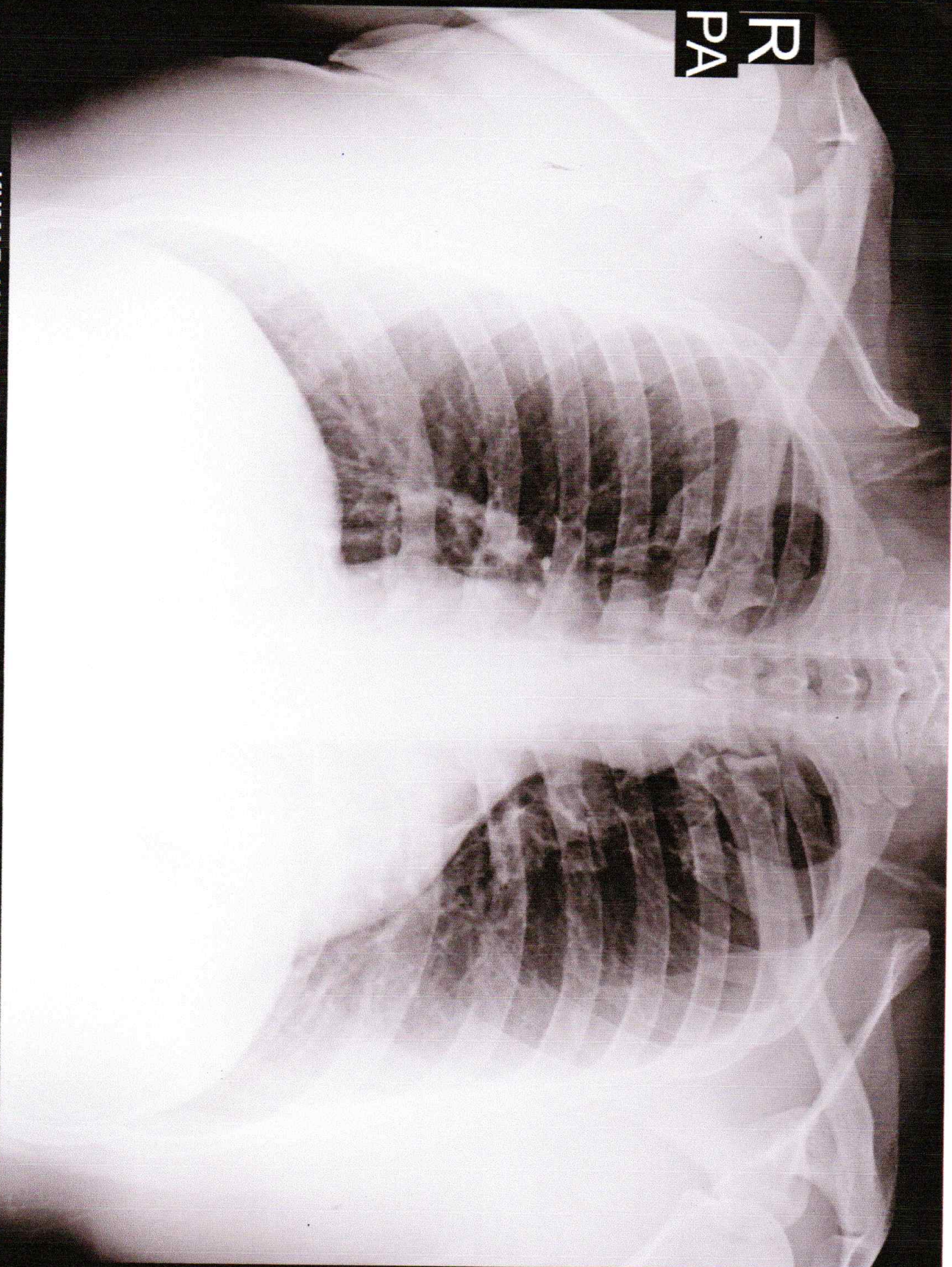
Reg.No. 57557

Address : Kabir Nagar (Near Sanjay Shiksha Niketan), Durgakund, Varanasi

Mobile : 9554572190 / 9453837595 / Recpn. 9389994334

E-mail : dramishra@gmail.com, drpallaviojha@gmail.com, Website: www.piire.org

R
PA



KUMAR ANURAG BOB 32Y/M 3664 O CHEST P.A. 18-Feb-23 10:41 AM

PANACEA HOSPITAL, KABIR NAGAR, DURGAKUND, VARANASI