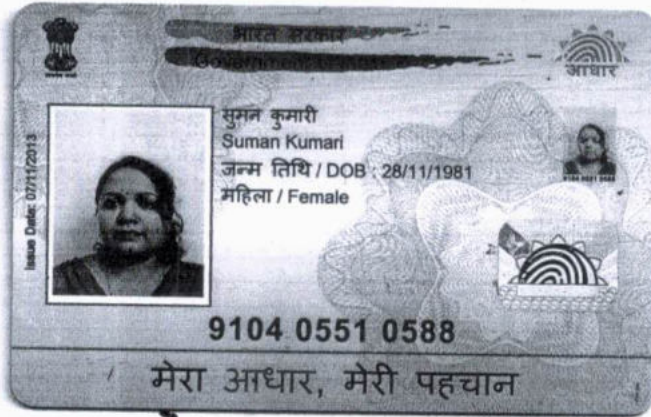
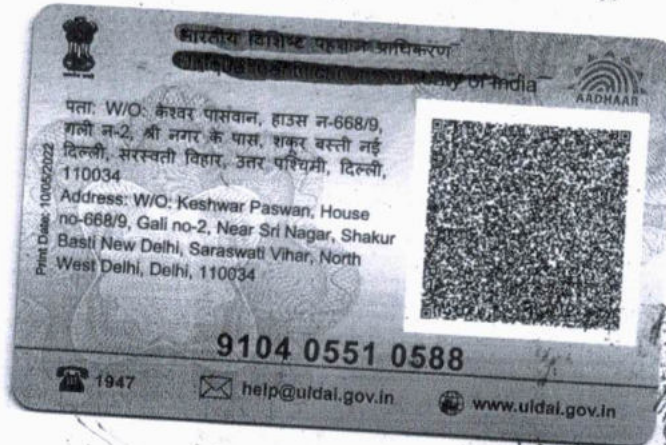


*Suman*



*Dr. Nitin Agarwal*  
**Dr. NITIN AGARWAL**  
MBBS, MD  
Regn. No. DMC-R-1436

**ONEPLUS ULTRASOUND LAB**  
47, Harsh Vihar, Pitam Pura,  
Delhi-110034  
Ph. 011-42480101, 9599913051  
E-mail: oneplusul@gmail.com

THE GOVERNMENT OF  
INDIA  
MINISTRY OF DEFENSE  
NEW DELHI

OFFICE OF THE  
SECRETARY  
DEFENSE  
NEW DELHI



*Auman*

**DR. NITIN AGARWAL**  
MBBS, MD  
▼ Regn. No. DMC-R-1436

**ONEPLUS ULTRASOUND LAB**  
47, Harsh Vihar, Pitam Pura,  
Delhi-110034  
Ph. 011-42480101, 9599913051  
E-mail: [oneplusul@gmail.com](mailto:oneplusul@gmail.com)





**OnePLUS**  
Ultrasound Lab

QUALITY FIRST... ALWAYS!

**Dr. Nitin Agarwal**  
Pathologist & Director  
Ex. Sr. Res. MAMC  
& Lok Nayak Hospital  
Ex. Chief of Lab Dr. Lal Path Labs.

**Dr. Pooja (Garg) Agarwal**  
Radiologist & Director  
MAMC & Lok Nayak Hospital



NAME	:Mrs. SUMAN KUMARI	Barcode No	:10137058
AGE/GENDER	:41 YRS/Female	SPECIMEN DATE	:03/Feb/2023 09:16AM
PATIENT ID	:108621	SPECIMEN RECEIVED	:03/Feb/2023 09:19AM
REFERRED BY	:Dr. MEDIWHEEL	REPORT DATE	:03/Feb/2023 03:09PM
CENTRE NAME	:ONEPLUS ULTRASOUND LAB	LAB NO.	:012302030010

Test Name	Result	Unit	Ref. Range
-----------	--------	------	------------

**HAEMATOLOGY**

**Medi Wheel Health checkup < 40 Female**

<b>Glycosylated Hemoglobin (HbA1c)</b>	6.3	%	Non Diabetic adults <5.7 Prediabetic (at risk) 5.7-6.4 Diabetes >6.4
--	-----	---	--

<b>Estimated average blood glucose (eag)</b>	134
--	-----

Reference range (mg/dl):

90 - 120:Excellent control, 121 - 150:Good Control, 151 - 180:Average Control, 181 - 210:Action Suggested

>211:Panic value

<b>BLOOD GROUP (ABO)</b>	O
<b>Rh typing</b>	POSITIVE

**NOTE :**

- \* Apart from major A,B,H antigens which are used for ABO grouping and Rh typing, many minor blood group antigens exist. Agglutination may also vary according to titre of antigen and antibody.
- \* So before transfusion, reconfirmation of blood group as well as cross-matching is needed.
- \* Presence of maternal antibodies in newborns, may interfere with blood grouping.
- \* Auto agglutination (due to cold antibody, falciparum malaria, sepsis, internal malignancy etc.) may also cause erroneous result.

**CBC**

Haemoglobin	12.9	g/dl	11.5-15.0
Total Leucocyte Count	8300	/cumm	4000-10000
<b>Differential leucocyte count</b>			
Neutrophils	67	%	40-80
Lymphocyte	28.30	%	20-40
Monocytes	2.00	%	2-10
Eosinophils	2.0	%	1-6
Basophils	0.7	%	0-2
RBC Count	4.50	million/cumm	3.8-4.8

Checked By.

DR. NITIN AGARWAL  
MBBS, MD (Path)  
DMC/R/01436

47, Harsh Vihar, Pitampura, New Delhi-110034 | Ph.: 011-42480101, 9599913051

E-mail: [oneplusul@gmail.com](mailto:oneplusul@gmail.com) | Web.: [www.oneplusul.in](http://www.oneplusul.in)

Page 1 of 8  
Page 2 of 3

Clinical correlation is essential for final diagnosis. \* If test results are unsatisfactory please contact personally or on phone. \* This report is for perusal of doctors only. \* All disputes Subject to Delhi Jurisdiction only. \* Not for medicolegal purposes. \* All congenital anomalies in a foetus may not be diagnosed in routine obstetric ultrasound.



# OnePLUS Ultrasound Lab

— QUALITY FIRST... ALWAYS! —

**Dr. Nitin Agarwal**

Pathologist & Director  
Ex. Sr. Res. MAMC  
& Lok Nayak Hospital  
Ex. Chief of Lab Dr. Lal Path Labs.

**Dr. Pooja (Garg) Agarwal**

Radiologist & Director  
MAMC & Lok Nayak Hospital



NAME	:Mrs. SUMAN KUMARI	Barcode No	:10137058
AGE/GENDER	:41 YRS/Female	SPECIMEN DATE	:03/Feb/2023 09:16AM
PATIENT ID	:108621	SPECIMEN RECEIVED	:03/Feb/2023 09:19AM
REFERRED BY	:Dr. MEDIWHEEL	REPORT DATE	:03/Feb/2023 03:09PM
CENTRE NAME	:ONEPLUS ULTRASOUND LAB	LAB NO.	:012302030010

Test Name	Result	Unit	Ref. Range
PCV(Hematocrit)	42.5	%	36-46
MCV	94.4	fL	83-101
MCH	28.8	Pg	27-32
MCHC	30.5	G/dL	32-35
Platelet count	236000	/cumm	150000-450000
RDW-CV	14.3	%	11.4-14.0
ESR(WESTEGRENs METHOD)	15	mm/1hr	<20

Checked By.

  
Dr NITIN AGARWAL  
MBBS, MD (Path)  
DMC/R/01436  
DR. NITIN AGARWAL  
MBBS, MD(PATHOLOGIST)

47, Harsh Vihar, Pitampura, New Delhi-110034 | Ph.: 011-42480101, 9599913051

E-mail: [oneplusul@gmail.com](mailto:oneplusul@gmail.com) | Web.: [www.oneplusul.in](http://www.oneplusul.in)

Page 2 of 8  
Page 3 of 5

Clinical correlation is essential for final diagnosis. • If test results are unsatisfactory please contact personally or on phone. • This report is for perusal of doctors only.  
• All disputes Subject to Delhi Jurisdiction only. • Not for medicolegal purposes. • All congenital anomalies in a foetus may not be diagnosed in routine obstetric ultrasound.



# OnePLUS

## Ultrasound Lab

— QUALITY FIRST... ALWAYS! —

**Dr. Nitin Agarwal**  
 Pathologist & Director  
 Ex. Sr. Res. MAMC  
 & Lok Nayak Hospital  
 Ex. Chief of Lab Dr. Lal Path Labs.

**Dr. Pooja (Garg) Agarwal**  
 Radiologist & Director  
 MAMC & Lok Nayak Hospital



NAME	:Mrs. SUMAN KUMARI	Barcode No	:10137058
AGE/GENDER	:41 YRS/Female	SPECIMEN DATE	:03/Feb/2023 09:16AM
PATIENT ID	:108621	SPECIMEN RECEIVED	:03/Feb/2023 09:19AM
REFERRED BY	:Dr. MEDIWHEEL	REPORT DATE	:03/Feb/2023 12:56PM
CENTRE NAME	:ONEPLUS ULTRASOUND LAB	LAB NO.	:012302030010

Test Name	Result	Unit	Ref. Range
<b><u>BIOCHEMISTRY</u></b>			
<u>Blood sugar fasting</u>	135	mg/dL	70-110

Checked By.

Dr. NITIN AGARWAL  
 M B B S , MD  
 DMC/R/01498  
 DR. NITIN AGARWAL  
 M B B S , MD (PATHOLOGIST)

47, Harsh Vihar, Pitampura, New Delhi-110034 | Ph.: 011-42480101, 9599913051

E-mail: [oneplusul@gmail.com](mailto:oneplusul@gmail.com) | Web.: [www.oneplusul.in](http://www.oneplusul.in)

Page 3 of 8







# OnePLUS Ultrasound Lab

— QUALITY FIRST... ALWAYS! —

**Dr. Nitin Agarwal**

Pathologist & Director  
Ex. Sr. Res. MAMC  
& Lok Nayak Hospital  
Ex. Chief of Lab Dr. Lal Path Labs.

**Dr. Pooja (Garg) Agarwal**

Radiologist & Director  
MAMC & Lok Nayak Hospital



NAME	:Mrs. SUMAN KUMARI	Barcode No	:10137058
AGE/GENDER	:41 YRS/Female	SPECIMEN DATE	:03/Feb/2023 09:16AM
PATIENT ID	:108621	SPECIMEN RECEIVED	:03/Feb/2023 01:11PM
REFERRED BY	:Dr. MEDIWHEEL	REPORT DATE	:03/Feb/2023 03:09PM
CENTRE NAME	:ONEPLUS ULTRASOUND LAB	LAB NO.	:012302030010

Test Name	Result	Unit	Ref. Range
<b><u>BIOCHEMISTRY</u></b>			
<b>Blood sugar pp</b>	222	mg/dL	70.0-140.0

Checked By.

Dr NITIN AGARWAL  
M B B S, MD (Path)  
DMC/R/01436  
M B B S, MD (PATHOLOGIST)

Dr NITIN AGARWAL  
M B B S, MD (Path)

47, Harsh Vihar, Pitampura, New Delhi-110034 | Ph.: 011-42480101, 9599913051

E-mail: [oneplusul@gmail.com](mailto:oneplusul@gmail.com) | Web.: [www.oneplusul.in](http://www.oneplusul.in)

Page 4 of 8

Clinical correlation is essential for final diagnosis. • If test results are unsatisfactory please contact personally or on phone. • This report is for perusal of doctors only.  
• All disputes Subject to Delhi Jurisdiction only. • Not for medicolegal purposes. • All congenital anomalies in a foetus may not be diagnosed in routine obstetric ultrasound.





# OnePLUS Ultrasound Lab

— QUALITY FIRST... ALWAYS! —

**Dr. Nitin Agarwal**

Pathologist & Director  
Ex. Sr. Res. MAMC  
& Lok Nayak Hospital  
Ex. Chief of Lab Dr. Lal Path Labs.

**Dr. Pooja (Garg) Agarwal**

Radiologist & Director  
MAMC & Lok Nayak Hospital



NAME	:Mrs. SUMAN KUMARI	Barcode No	:10137058
AGE/GENDER	:41 YRS/Female	SPECIMEN DATE	:03/Feb/2023 09:16AM
PATIENT ID	:108621	SPECIMEN RECEIVED	:03/Feb/2023 09:19AM
REFERRED BY	:Dr. MEDIWHEEL	REPORT DATE	:03/Feb/2023 12:56PM
CENTRE NAME	:ONEPLUS ULTRASOUND LAB	LAB NO.	:012302030010

Test Name	Result	Unit	Ref. Range
-----------	--------	------	------------

### BIOCHEMISTRY

<u>Bun (blood urea nitrogen )</u>	10.70	mg/dl	7-18.7
<u>Uric acid, serum</u>	4.0	mg/dl	2.6-6.0
<u>Creatinine, serum</u>	0.6	mg/dl	0.50-1.0

### LFT(LIVER FUNCTION TEST)

Bilirubin Total	0.48	mg/dl	0.1-1.2
Bilirubin Conjugated	0.27	mg/dl	0-0.4
Bilirubin Unconjugated	0.21	mg/dl	up to 0.7
SGOT (AST)	92	U/L	0-46
SGPT (ALT)	112	U/L	0-49
Alkaline phosphatase	101	U/L	35-104
Gamma glutamyl transpeptidase	30	U/L	5.0-32.0
Total Protein	7.4	gm/dl	6.60 - 8.70
Albumin serum	4.2	g/dL	3.0-5.2
Globulin	3.20	gm/dl	1.8-3.4
Albumin/Globulin Ratio	1.31		1.10 - 2.50

### LIPID PROFILE

Cholesterol	214	mg/dl	50-200
Triglycerides	255	mg/dL	25-150
HDL Cholesterol	52	mg/dL	40 - 60
LDL cholesterol	111	mg/dL	< 130
VLDL cholesterol	51.0	mg/dL	5-40
Cholesterol/HDL Ratio	4.1		Low Risk 3.3-4.97 Average Risk 4.4-7.1 Moderate Risk 7.1-11.0 High Risk >11.0
LDL/HDL Ratio	2.1		0 - 3.55

According to ATP III and NCEP guidelines

Checked By.

Dr NITIN AGARWAL  
MBBS, MD (Path)  
DMC/R/01436

DR. NITIN AGARWAL  
MBBS,MD(PATHOLOGIST)

47, Harsh Vihar, Pitampura, New Delhi-110034 | Ph.: 011-42480101, 9599913051

E-mail: [oneplusul@gmail.com](mailto:oneplusul@gmail.com) | Web.: [www.oneplusul.in](http://www.oneplusul.in)

Page 5 of 8

Clinical correlation is essential for final diagnosis. • If test results are unsatisfactory please contact personally or on phone. • This report is for perusal of doctors only.  
• All disputes Subject to Delhi Jurisdiction only. • Not for medicolegal purposes. • All congenital anomalies in a foetus may not be diagnosed in routine obstetric ultrasound.





# OnePLUS Ultrasound Lab

— QUALITY FIRST... ALWAYS! —

**Dr. Nitin Agarwal**

Pathologist & Director  
Ex. Sr. Res. MAMC  
& Lok Nayak Hospital  
Ex. Chief of Lab Dr. Lal Path Labs.

**Dr. Pooja (Garg) Agarwal**

Radiologist & Director  
MAMC & Lok Nayak Hospital



NAME	:Mrs. SUMAN KUMARI	Barcode No	:10137058
AGE/GENDER	:41 YRS/Female	SPECIMEN DATE	:03/Feb/2023 09:16AM
PATIENT ID	:108621	SPECIMEN RECEIVED	:03/Feb/2023 09:19AM
REFERRED BY	:Dr. MEDIWHEEL	REPORT DATE	:03/Feb/2023 12:56PM
CENTRE NAME	:ONEPLUS ULTRASOUND LAB	LAB NO.	:012302030010

Test Name	Result	Unit	Ref. Range	
<b>Parameter</b>	<b>Normal</b>	<b>Desirable</b>	<b>Borderline</b>	<b>High</b>
Total cholesterol	<200		200-239	240
Triglycerides	<150	150-199	200-499	500
LDL	Optimal <100 Near Optimal 100-129	130-159	160-180	190
HDL	<40 : LOW 60 : HIGH			
<b>BUN/Creatinine ratio</b>				
Bun (blood urea nitrogen )	10.70	mg/dl	7-18.7	
CREATININE	0.60	mg/dl	0.30-1.10	
BUN/Creatinine ratio	17.83		10.0 - 20.0	

Checked By.

**DR. NITIN AGARWAL**  
MBBS, MD (Path)  
DMC/R/01436  
DR. NITIN AGARWAL  
MBBS, MD (PATHOLOGIST)

47, Harsh Vihar, Pitampura, New Delhi-110034 | Ph.: 011-42480101, 9599913051

E-mail: [oneplusul@gmail.com](mailto:oneplusul@gmail.com) | Web.: [www.oneplusul.in](http://www.oneplusul.in)

Page 6 of 8

Clinical correlation is essential for final diagnosis. • If test results are unsatisfactory please contact personally or on phone. • This report is for perusal of doctors only. • All disputes Subject to Delhi Jurisdiction only. • Not for medicolegal purposes. • All congenital anomalies in a foetus may not be diagnosed in routine obstetric ultrasound.





**OnePLUS**  
Ultrasound Lab  
— QUALITY FIRST... ALWAYS! —

**Dr. Nitin Agarwal**

Pathologist & Director  
Ex. Sr. Res. MAMC  
& Lok Nayak Hospital  
Ex. Chief of Lab Dr. Lal Path Labs.

**Dr. Pooja (Garg) Agarwal**

Radiologist & Director  
MAMC & Lok Nayak Hospital



NAME	:Mrs. SUMAN KUMARI	Barcode No	:10137058
AGE/GENDER	:41 YRS/Female	SPECIMEN DATE	:03/Feb/2023 09:16AM
PATIENT ID	:108621	SPECIMEN RECEIVED	:03/Feb/2023 09:20AM
REFERRED BY	:Dr. MEDIWHEEL	REPORT DATE	:03/Feb/2023 03:09PM
CENTRE NAME	:ONEPLUS ULTRASOUND LAB	LAB NO.	:012302030010

Test Name	Result	Unit	Ref. Range
-----------	--------	------	------------

**ENDOCRINOLOGY**

**THYROID PROFILE(T3,T4,TSH)**

Triiodothyronine total [t3]	0.95	ng/dl	0.52-1.9
Thyroxine total [t4]	7.60	µg/dl	4.8-11.6
TSH (Thyroid Stimulating Hormone)	1.80	µIU/ml	0.25-5.0

**AGE WISE VARIATION IN TSH**

AGE	TSH(µIU/ml)	AGE	TSH(µIU/ml)
1-4 weeks	1.00 - 19.0	16-20 yrs	0.25 - 5.0
1-12 mths	1.70 - 9.1	21 - 80 yrs	0.25 - 5.0
1-5 yrs	0.80 - 8.2	I <sup>st</sup> trimester	0.25 - 5.0
6-10 yrs	0.25 - 5.0	II <sup>nd</sup> trimester	0.50 - 5.0
11-15 yrs	0.25 - 5.0	II <sup>rd</sup> trimester	0.4 - 6.0

**Reference ranges - Interpretation of Diagnostic tests - (Jacques Wallach)**

1. Primary hypothyroidism is accompanied by depressed serum T3 and T4 values and elevated serum TSH level.
2. Primary hyperthyroidism is accompanied by elevated serum T3 and T4 levels along with depressed TSH values.
3. Slightly elevated T3 levels may be found in pregnancy and estrogen therapy, while depressed levels may be encountered in severe illness, renal failure and during therapy with drugs like propranolol and propyl thiouracil.
4. Although elevated TSH levels are nearly always indicative of primary hypothyroidism, and may be seen in secondary thyrotoxicosis

Checked By.

DR. NITIN AGARWAL  
MBBS, MD (Path)  
DMC/R/01436

47, Harsh Vihar, Pitampura, New Delhi-110034 | Ph.: 011-42480101, 9599913051

E-mail: oneplusul@gmail.com | Web.: www.oneplusul.in

Page 7 of 8







# OnePLUS Ultrasound Lab

— QUALITY FIRST... ALWAYS! —

**Dr. Nitin Agarwal**  
Pathologist & Director  
Ex. Sr. Res. MAMC  
& Lok Nayak Hospital  
Ex. Chief of Lab Dr. Lal Path Labs.

**Dr. Pooja (Garg) Agarwal**  
Radiologist & Director  
MAMC & Lok Nayak Hospital



NAME	:Mrs. SUMAN KUMARI	Barcode No	:10137058
AGE/GENDER	:41 YRS/Female	SPECIMEN DATE	:03/Feb/2023 09:16AM
PATIENT ID	:108621	SPECIMEN RECEIVED	:03/Feb/2023 11:05AM
REFERRED BY	:Dr. MEDIWHEEL	REPORT DATE	:03/Feb/2023 12:56PM
CENTRE NAME	:ONEPLUS ULTRASOUND LAB	LAB NO.	:012302030010

Test Name	Result	Unit	Ref. Range
-----------	--------	------	------------

## CLINICAL PATHOLOGY

### URINE ROUTINE

#### Physical examination

Quantity	20		ML
Colour	PALE YELLOW		
Transparency	CLEAR		CLEAR
Sp.gravity	1.020		1.010-1.030
pH	6.00		
Reaction	ACIDIC		ACIDIC

#### Chemical examination

Urine protein	NIL		NIL
Urine sugar	NIL		NIL
Bilirubin, urine	NEGATIVE		NEGATIVE
Urobilinogen	NORMAL		NORMAL
Ketones	NEGATIVE		NEGATIVE


#### Microscopic examination

<b>Pus cells.</b>	1-2	/HPF	1-2
Epithelial cells	2-3	/HPF	0-5
R.B.C.	NIL	/HPF	NIL
Casts	NIL	/HPF	NIL
Crystals	NIL	/HPF	NIL
Bacteria	NIL	/HPF	NIL
Others.	NIL		NIL

\*\*\* End Of Report \*\*\*

Checked By.

Dr NITIN AGARWAL  
M B B S, MD (Path)  
DMC/R/01436

  
DR. NITIN AGARWAL  
MBBS,MD(PATHOLOGIST)

47, Harsh Vihar, Pitampura, New Delhi-110034 | Ph.: 011-42480101, 9599913051  
E-mail: oneplusul@gmail.com | Web.: www.oneplusul.in

Page 8 of 8

Clinical correlation is essential for final diagnosis. • If test results are unsatisfactory please contact personally or on phone. • This report is for perusal of doctors only.  
• All disputes Subject to Delhi Jurisdiction only. • Not for medicolegal purposes. • All congenital anomalies in a foetus may not be diagnosed in routine obstetric ultrasound.

# ONEPLUS ULTRASOUND LAB

47, HARSH VIHAR, PITAMPURA, DELHI- 110034

Ms. SUMAN KUMARI  
 Age : 41/F  
 Ref. by : MEDIWHEEL  
 Indication1 :  
 Indication2 :  
 Indication3 :  
 COMMENTS : Sinus Tachycardia.

ID : 2097  
 H/Wt : 153/84  
 Recorded : 3- 2-2023 10:54  
 Medication1 :  
 Medication2 :  
 Medication3 :

BPM : 113  
 BP : 130/86  
 P Axis : 65 deg  
 QRS Axis : -6 deg  
 T Axis : 5 deg

P duration : 93 msec  
 PR duration : 133 msec  
 QRS duration : 100 msec  
 QT interval : 286 msec  
 QTc interval : 376 msec

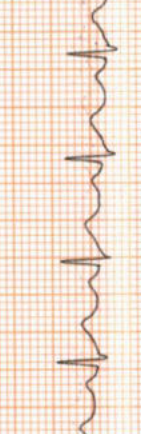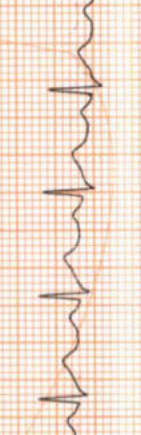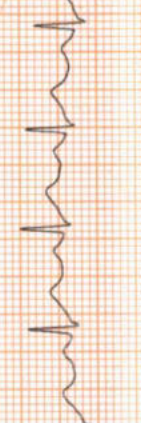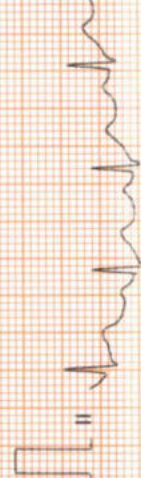
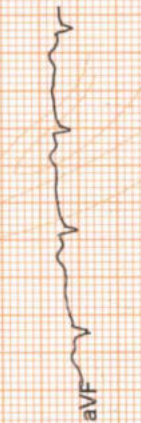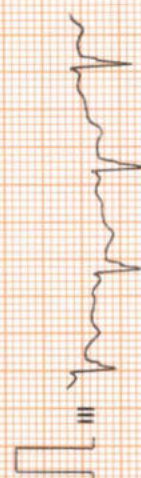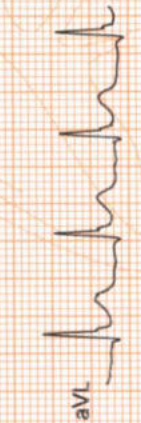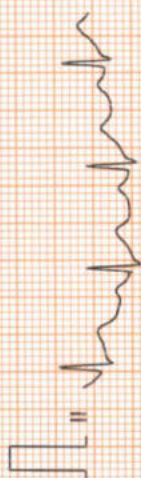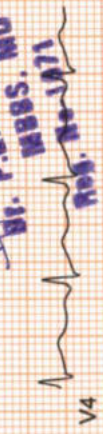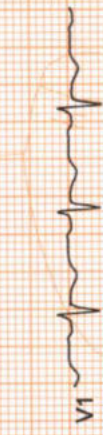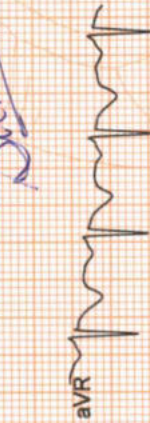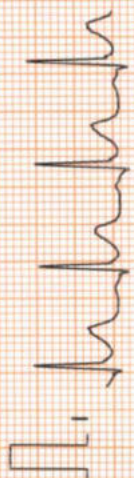Raw E.C.G. (Seq)

Unconfirmed Report Reviewed By:

Cardiologist

*Suman*

*SINUS TACHYCARDIA*  
*Dr. P.S. GUPTA*  
*MBBS, MD*  
*Reg. No. 1271*



ONEPLUS ULTRASOUND LAB  
 Dr. Harsh Vihar, Pitampura,  
 Delhi-110034  
 Ph: 011-42480101, 9539915053  
 Email: oneplusul@gmail.com



# ONEPLUS ULTRASOUND LAB

47, HARSH VIHAR PITAMPURA DELHI 110034

Ms. SUMAN KUMARI  
Age : 41/F  
Ref. by : MEDIWHEEL  
Indication1 :  
Indication2 :  
Indication3 :

ID : 997  
Ht/Wt : 153/84  
Recorded : 3-2-2023 11:07

TREADMILL TEST SUMMARY REPORT  
Protocol: BRUCE  
History:  
Medication1 :  
Medication2 :  
Medication3 :

PHASE	PHASE TIME	STAGE TIME	SPEED (Km./Hr.)	GRADE (%)	H.R. (BPM)	B.P. (mmHg)	RPP X100	II	ST LEVEL (mm) V2	V5	METS
SUPINE STANDING					120 122	130/86 130/86	156 158	1.0 1.0	1.3 1.2	0.6 0.6	
STAGE 1	2:59	2:59	2.70	10.00	156	130/86	202	1.0	0.2	0.1	4.80
STAGE 2	5:59	2:59	4.00	12.00	180	150/90	270	0.3	0.4	0.0	7.10
STAGE 3	6:29	0:29	5.40	14.00	192	160/94	307	0.4	0.0	-0.5	7.57
PEAK EXER	6:29	0:29			193	160/94	308	0.4	0.0	-0.5	7.57
RECOVERY	2:59	2:59	0.00	0.00	132	132/88	174	0.4	0.5	0.3	

## RESULTS

Exercise Duration : 6:29 Minutes  
Max Heart Rate : 193 bpm 107 % of target heart rate 179 bpm  
Max Blood Pressure : 160/94 mmHg  
Max Work Load : 7.57 METS  
Reason of Termination :

Impressions : Negative for ischemic change

## IMPRESSIONS

ONEPLUS ULTRASOUND LAB  
47, Harsh Vihar, Pitam Fura,  
Delhi-110034  
Ph. 011-42480101, 9599913051  
E-mail: oneplusul@gmail.com

*[Signature]*  
Dr. P. K. GUPTA  
MBBS, MD  
Cardiologist No-1071

*[Signature]*



# ONEPLUS ULTRASOUND LAB

Ms. SUMAN KUMARI  
I.D. : 997

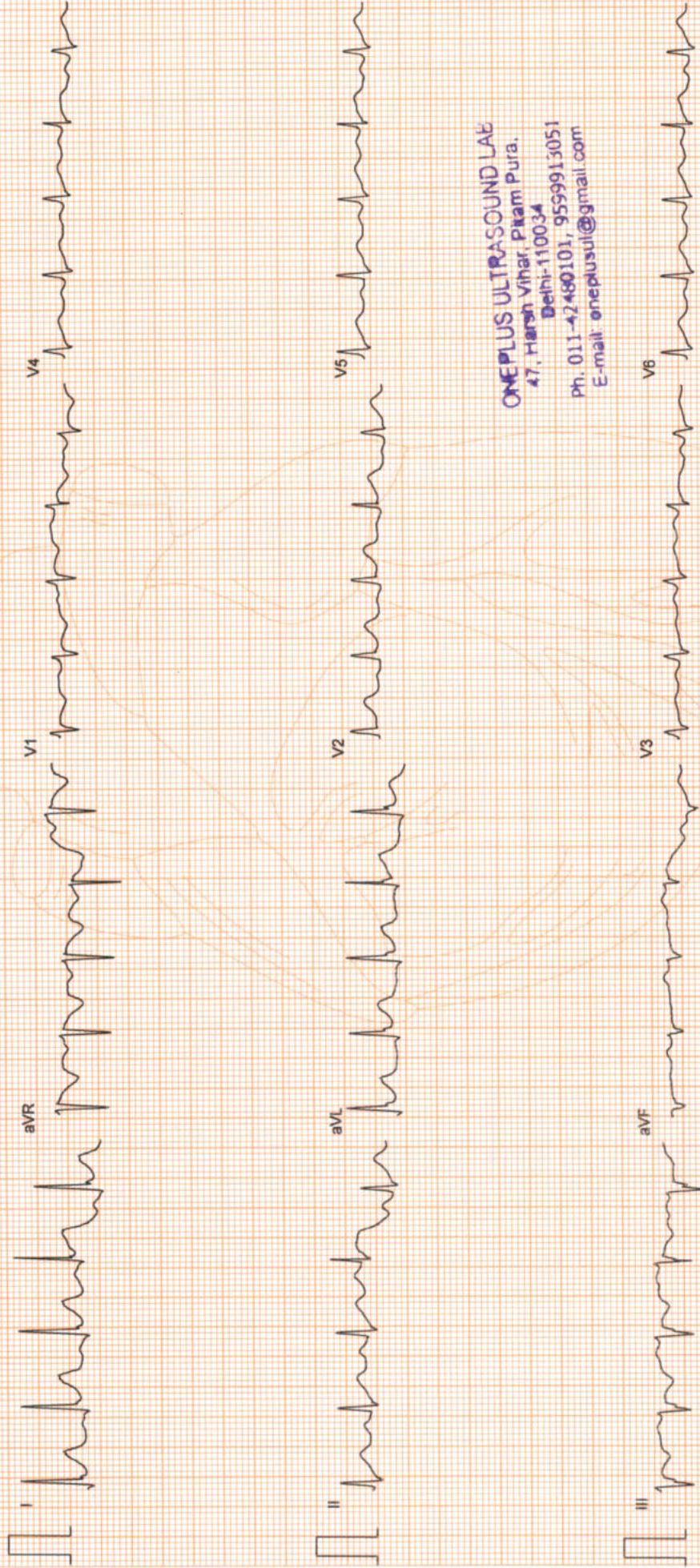
AGE/SEX : 41/F  
RECORDED : 3-2-2023 11:07

RATE : 120 BPM  
B.P. : 130/86 mmHg

ST @ 10mm/mV  
80ms PostJ

SUPINE  
PRETEST

RAW E.C.G.



ONEPLUS ULTRASOUND LAB  
47, Harsh Vihar, Pitam Pura,  
Delhi-110034  
Ph. 011-42460101, 9559913051  
E-mail: oneplusul@gmail.com



# ONEPLUS ULTRASOUND LAB

Ms. SUMAN KUMARI

I.D. : 997

AGE/SEX : 41/F

RECORDED : 3-2-2023 11:07

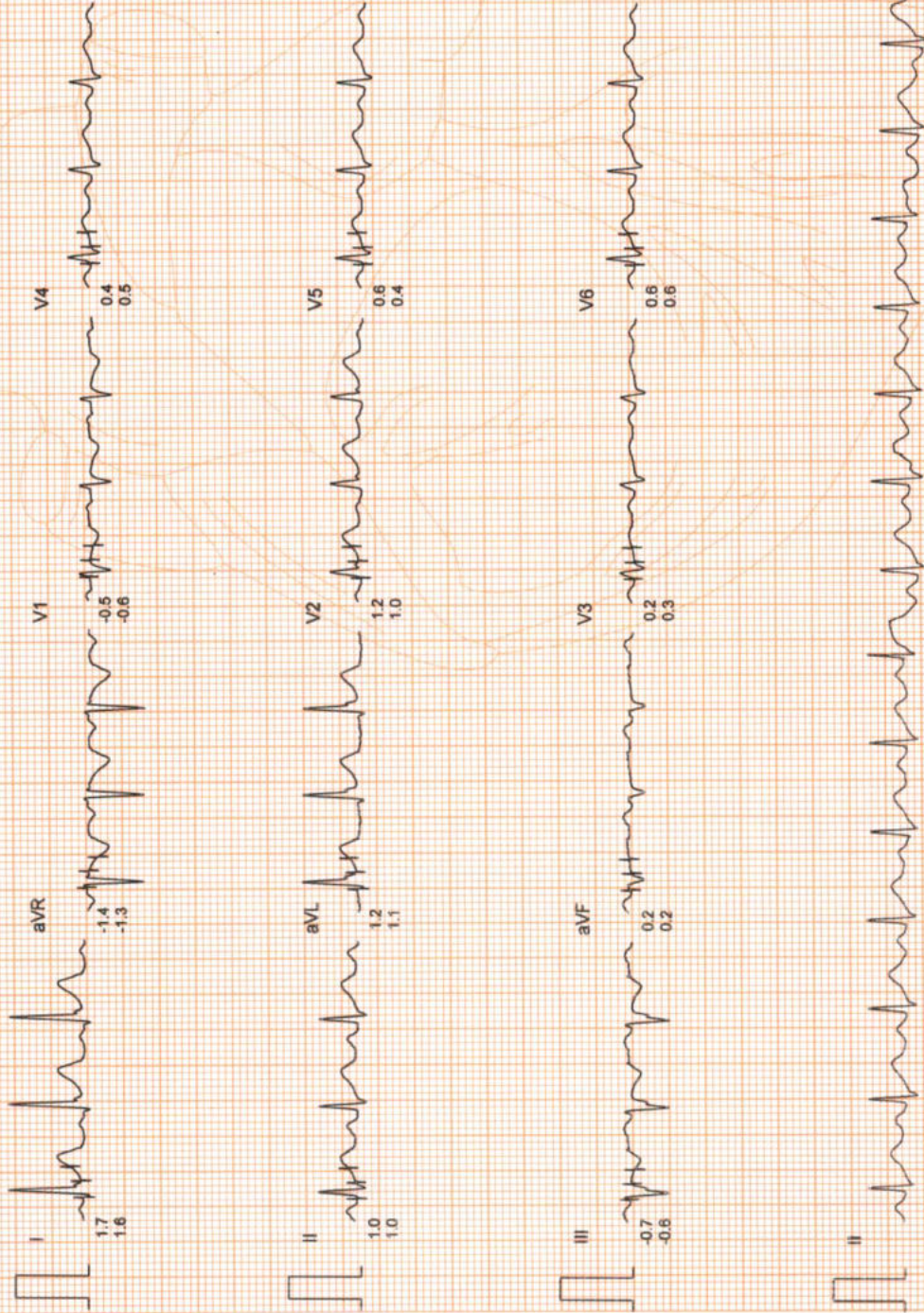
RATE : 122 BPM

B.P. : 130/86 mmHg

ST @ 10mm/mV  
80ms PostJ

STANDING  
PRETEST

LINKED MEDIAN



III

50mm/sec 20mm/mV

-0.7  
-0.6

ONEPLUS ULTRASOUND LAB  
47, Harsh Vihar, Pkham Pura,  
Delhi-110034

Ph. 011-42480101, 9599913051

E-mail: oneplusul@gmail.com



Handwritten text, possibly a signature or date, located in the bottom right corner of the page.

# ONEPLUS ULTRASOUND LAB

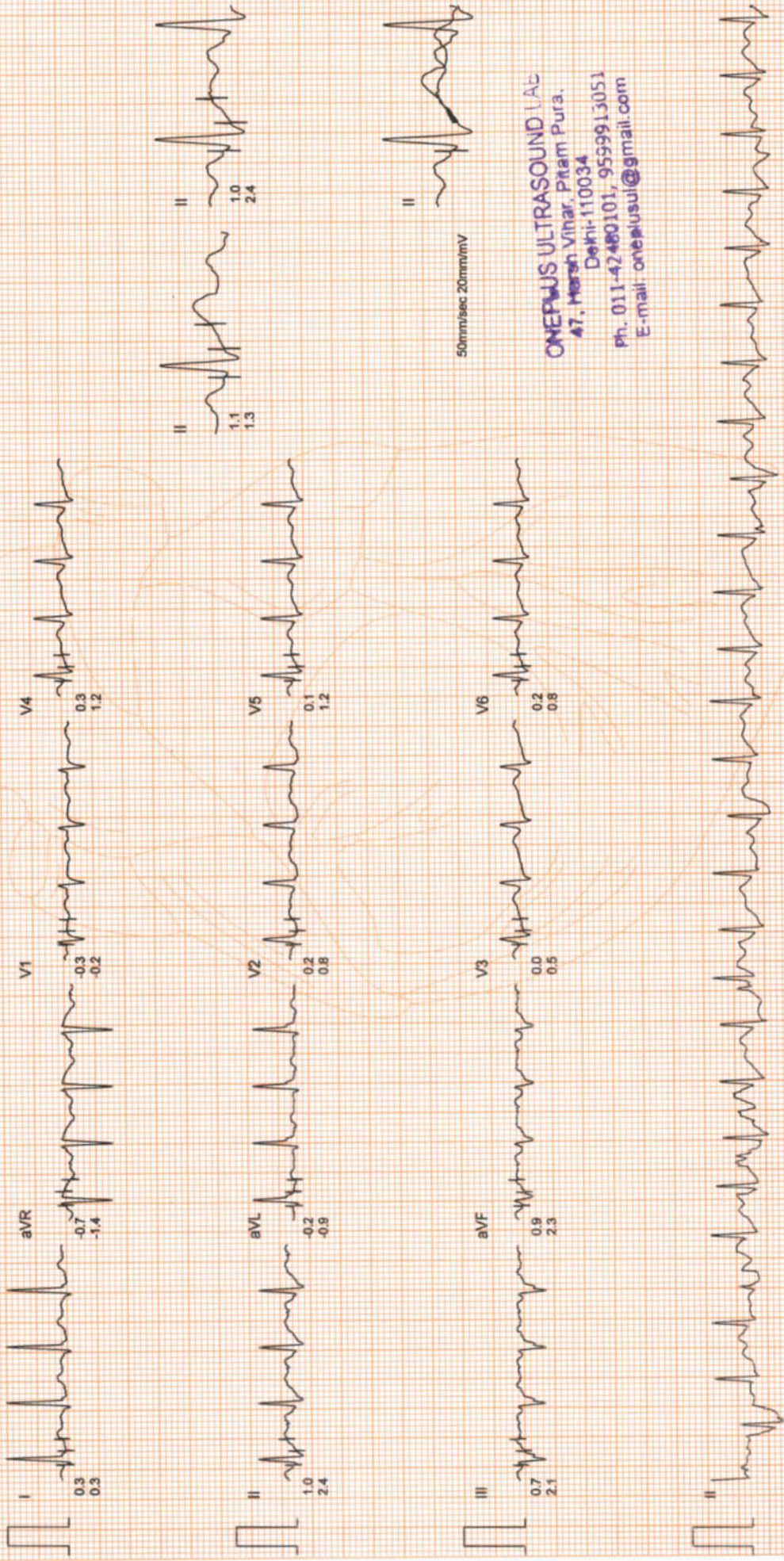
Ms. SUMAN KUMARI  
I.D. : 997

AGE/SEX : 41/F  
RECORDED : 3-2-2023 11:07

BRUCE  
EXERCISE 1  
PHASE TIME : 2:59  
STAGE TIME : 2:59

ST @ 10mm/mV  
80ms PostJ  
SPEED : 2.7 Km./Hr.  
GRADE : 10.0 %

LINKED MEDIAN



ONEPLUS ULTRASOUND LAB  
47, Harsah Vihar, Pitam Pura,  
Delhi-110034  
Ph. 011-42480101, 9599913051  
E-mail: oneplusul@gmail.com

11  
12  
13  
14  
15  
16  
17  
18  
19  
20  
21  
22  
23  
24  
25  
26  
27  
28  
29  
30  
31  
32  
33  
34  
35  
36  
37  
38  
39  
40  
41  
42  
43  
44  
45  
46  
47  
48  
49  
50  
51  
52  
53  
54  
55  
56  
57  
58  
59  
60  
61  
62  
63  
64  
65  
66  
67  
68  
69  
70  
71  
72  
73  
74  
75  
76  
77  
78  
79  
80  
81  
82  
83  
84  
85  
86  
87  
88  
89  
90  
91  
92  
93  
94  
95  
96  
97  
98  
99  
100

# ONEPLUS ULTRASOUND LAB

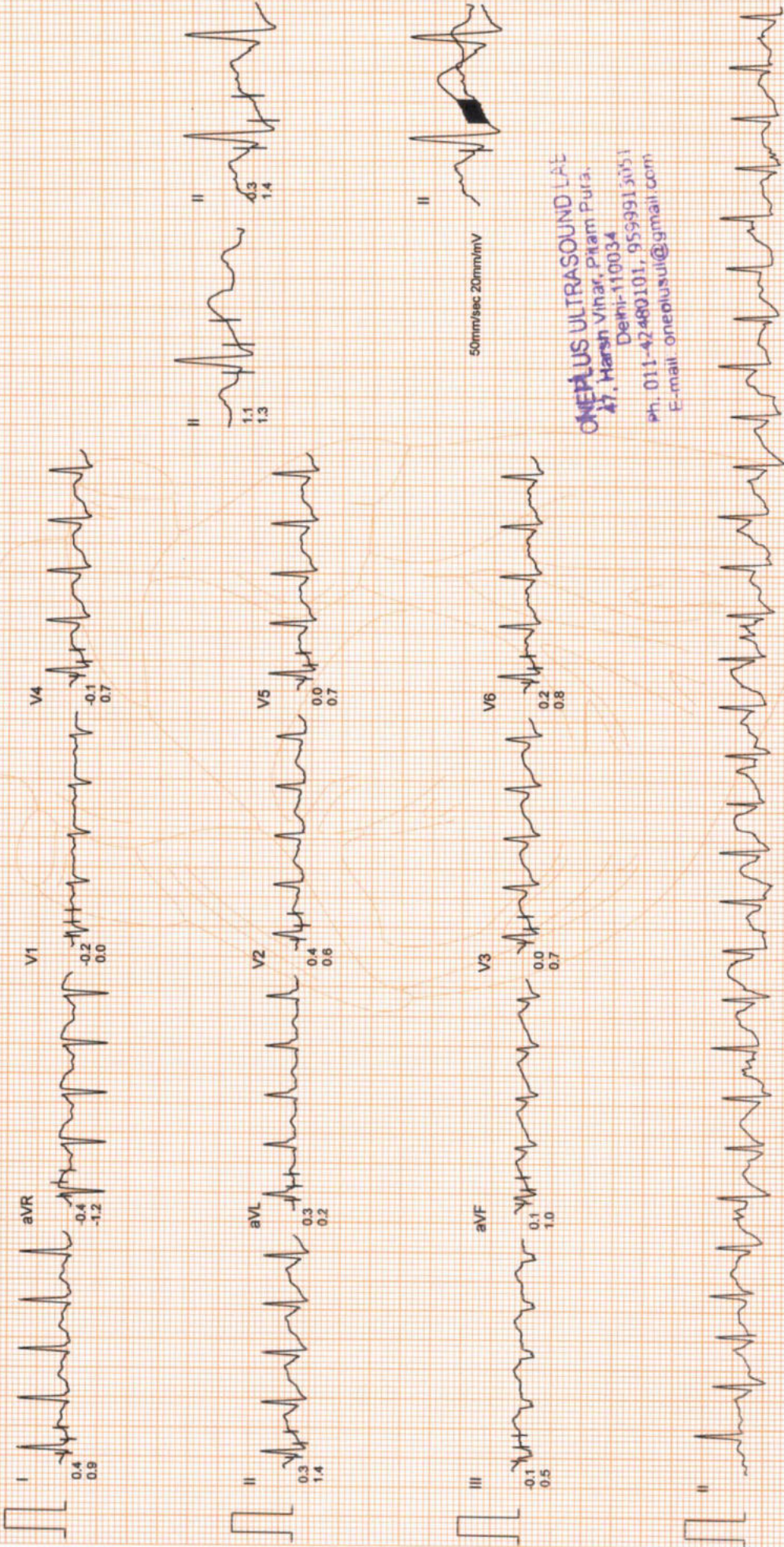
Ms. SUMAN KUMARI  
I.D. : 997

AGE/SEX : 41/F  
RECORDED : 3-2-2023 11:07  
RATE : 180 BPM  
B.P. : 150/90 mmHg

ST @ 10mm/mV  
80ms PostJ  
SPEED : 4.0 Km./Hr.  
GRADE : 12.0 %

BRUCE  
EXERCISE 2  
PHASE TIME : 5:59  
STAGE TIME : 2:59

LINKED MEDIAN



ONEPLUS ULTRASOUND LAB  
A7, Harsh Vihar, Pitam Pura,  
Delhi-110034  
Ph. 011-42480101, 9599913051  
E-mail: oneplusul@gmail.com

Handwritten text, possibly a date or signature, appearing as a dark smudge.

# ONEPLUS ULTRASOUND LAB

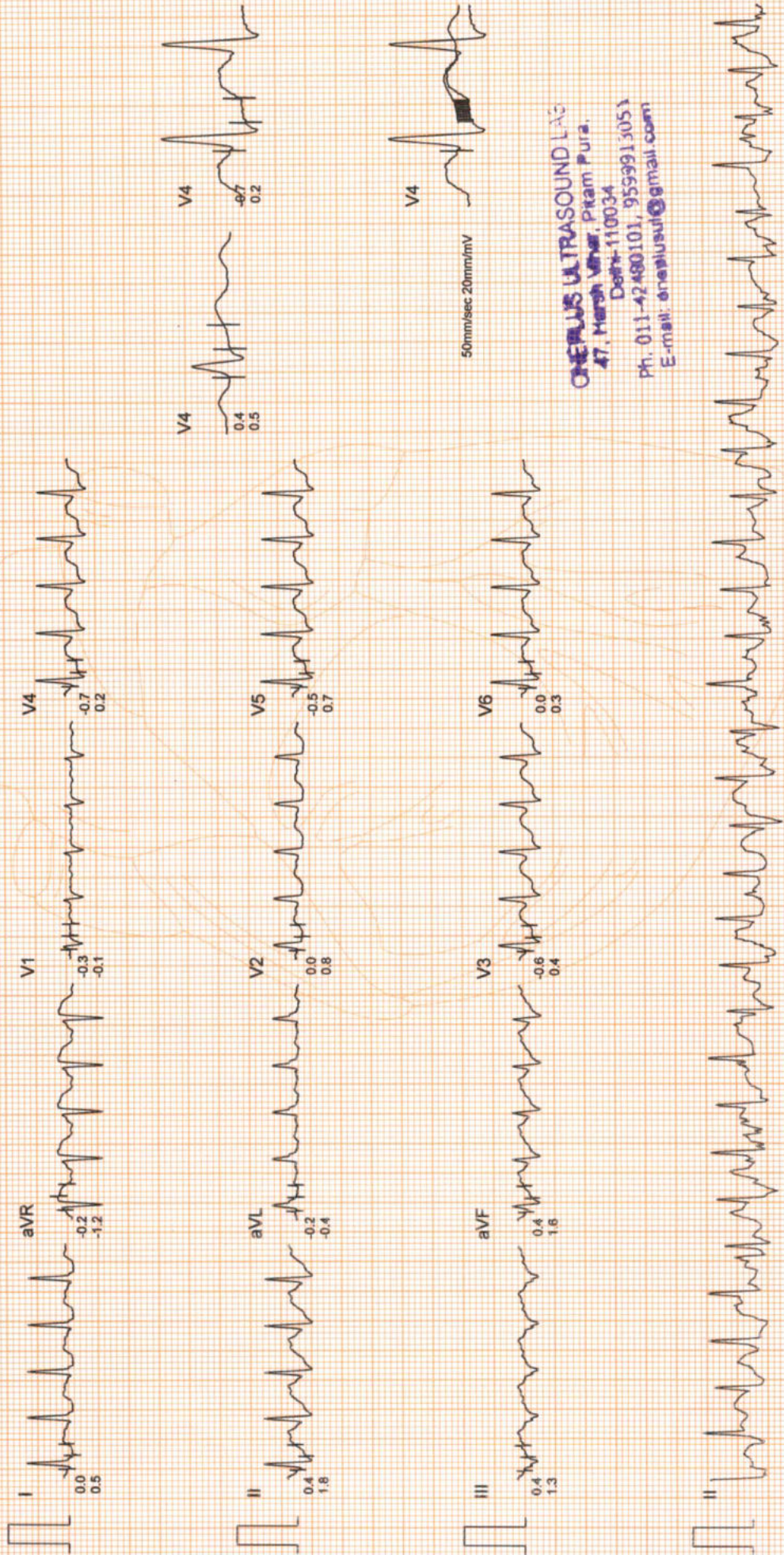
Ms. SUMAN KUMARI  
I.D. : 997

AGE/SEX : 41/F  
RECORDED : 3-2-2023 11:07

BRUCE  
EXERCISE 3  
PHASE TIME : 6:29  
STAGE TIME : 0:29

ST @ 10mm/mV  
80ms PostLJ  
SPEED : 5.4 Km/Hr.  
GRADE : 14.0 %

LINKED MEDIAN



ONEPLUS ULTRASOUND LAB  
47, Marsh Vihar, Pitam Pura,  
Delhi-110034  
Ph: 011-42480101, 9559913051  
E-mail: oneplusul@gmail.com



# ONEPLUS ULTRASOUND LAB

Ms SUMAN KUMARI  
I.D. : 997

AGE/SEX : 41/F  
RECORDED : 3-2-2023 11:07

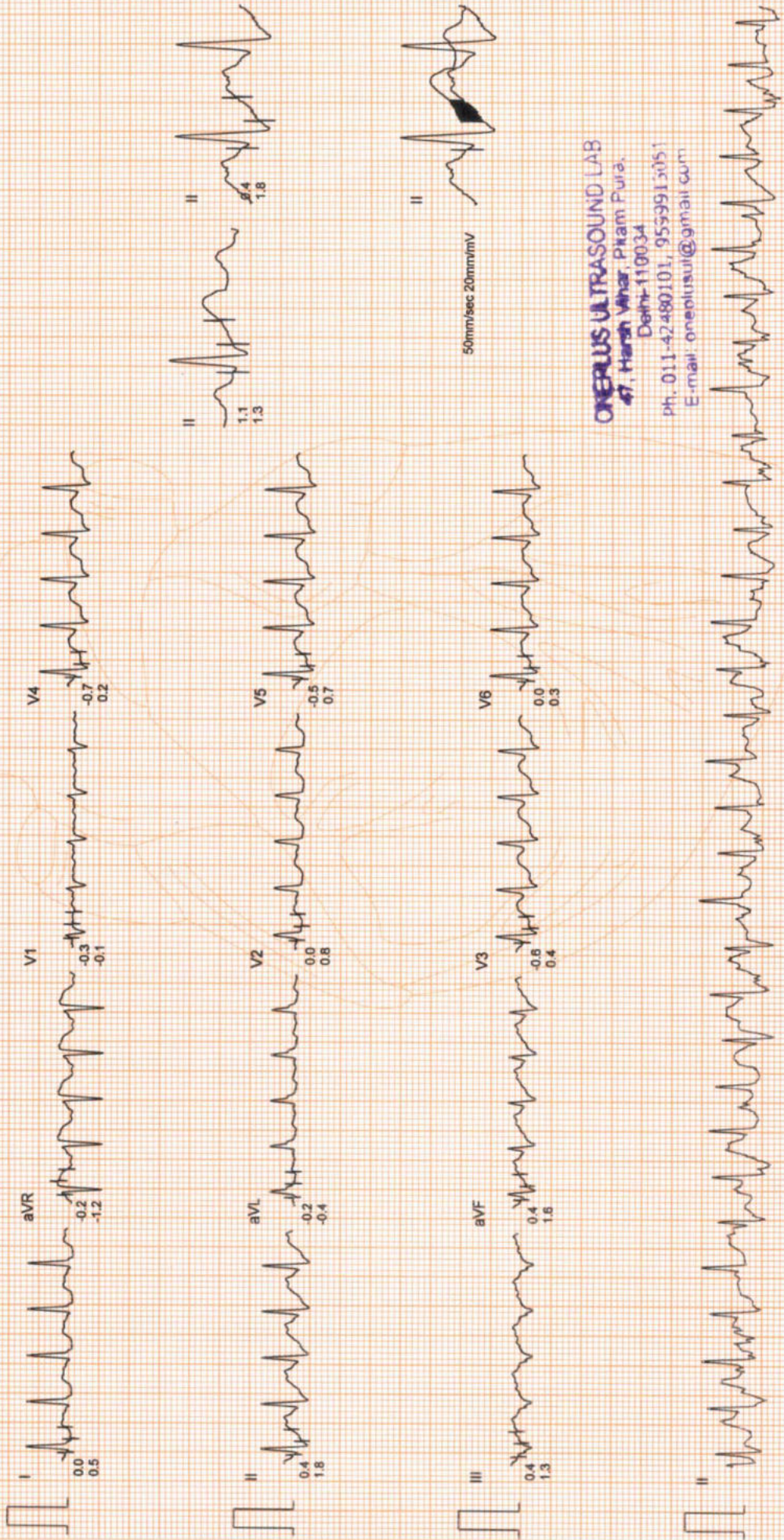
RATE : 193 BPM  
B.P. : 160/94 mmHg

BRUCE  
PEAK EXER

PHASE TIME : 6:29  
STAGE TIME : 0:29

ST @ 10mm/mV  
80ms PostJ  
SPEED : 5.4 Km./Hr.  
GRADE : 14.0 %

LINKED MEDIAN



**ONEPLUS ULTRASOUND LAB**  
47, Harsh Vihar, Pitam Pura,  
Delhi-110034  
Ph. 011-42480101, 9559913051  
E-mail: oneplusul@gmail.com





# ONEPLUS ULTRASOUND LAB

Ms. SUMAN KUMARI

I.D. : 997

AGE/SEX : 41/F

RECORDED : 3- 2-2023 11:07

RATE : 132 BPM

B.P. : 132/88 mmHg

ST @ 10mm/mV

80ms PostJ

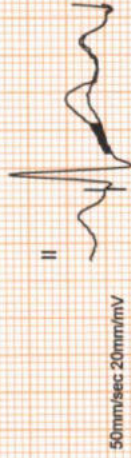
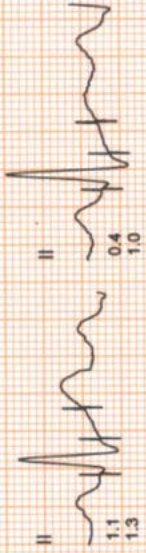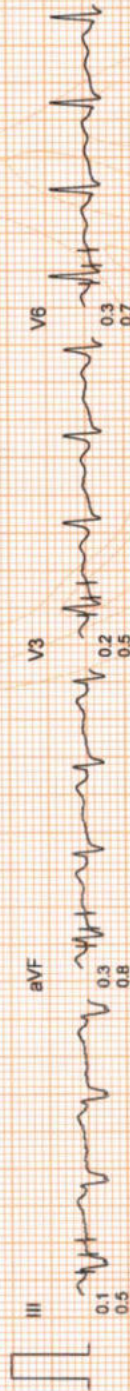
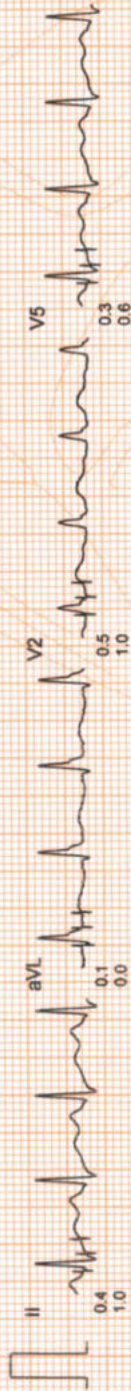
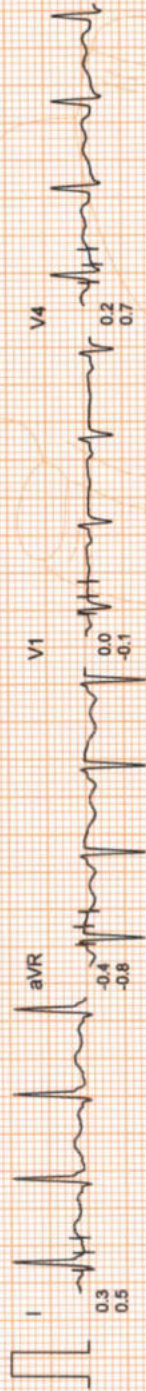
SPEED : 0.0 Km./Hr.

GRADE : 0.0 %

LINKED MEDIAN

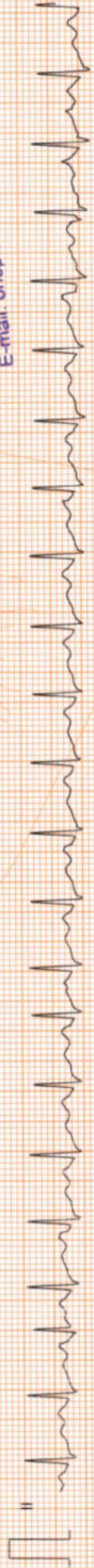PHASE TIME : 2:59

BRUCE  
RECOVERY



50mm/sec 20mm/mV

ONEPLUS ULTRASOUND LAB  
47, Harsh Vihar, Pitam Pura,  
Delhi-110034  
Ph. 011-42480101, 9599913051  
E-mail: oneplusul@gmail.com





# ONEPLUS ULTRASOUND LAB

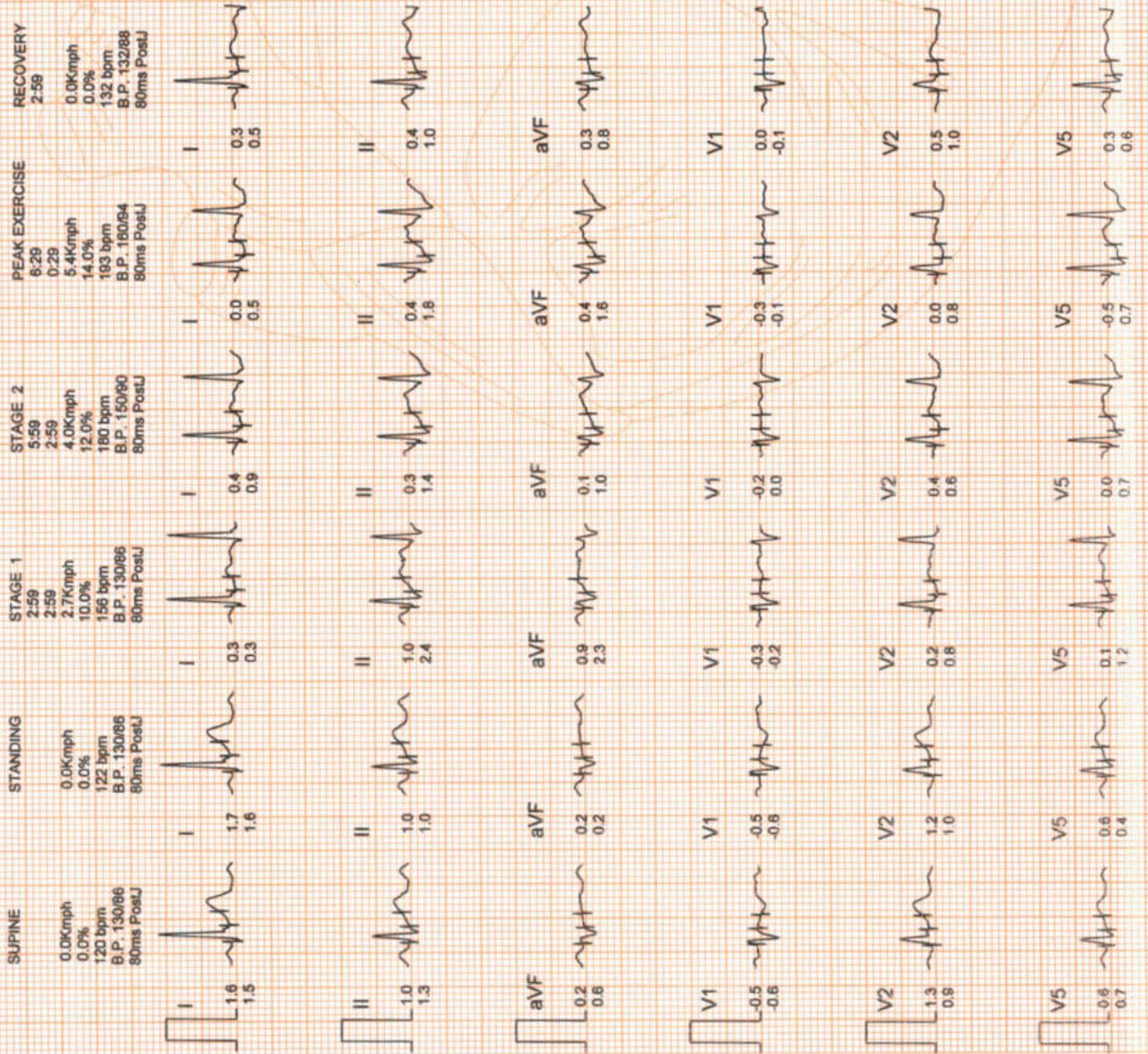I.D. : 997

Ms. SUMAN KUMARI

AGE/SEX : 41/F

RECORDED : 3-2-2023 11:07

AVG E.C.G.



ONEPLUS ULTRASOUND L&E  
47, Harsh Vihar, Pitam Pura,  
Delhi-110034  
ph. 011-42480101, 9599913051  
E-mail: onepplusul@gmail.com

# ONEPLUS ULTRASOUND LAB

AGE/SEX : 41/F

I.D. : 997

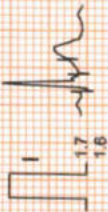
Ms. SUMAN KUMARI

RECORDED : 3-2-2023 11:07

## COMPARISON REPORT

### STANDING


0.0Kmph  
0.0%  
122 bpm  
B.P. 130/66  
80ms PostJ



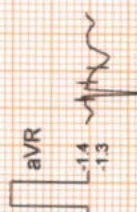
1.7  
1.6



1.0  
1.0



-0.7  
-0.6



aVR  
-1.4  
-1.3



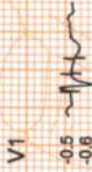aVL  
1.2  
1.1



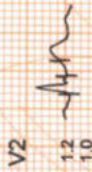aVF  
0.2  
0.2

### STANDING

0.0Kmph  
0.0%  
122 bpm  
B.P. 130/66  
80ms PostJ



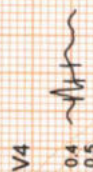V1  
-0.5  
-0.8



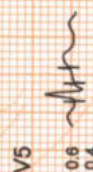V2  
1.2  
1.0



V3  
0.2  
0.3



V4  
0.4  
0.5



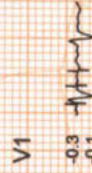V5  
0.6  
0.4



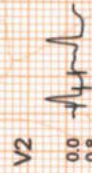V6  
0.6  
0.6

### PEAK EXERCISE

6:29  
0:29  
5.4Kmph  
14.0%  
193 bpm  
B.P. 160/94  
80ms PostJ



V1  
-0.3  
-0.1



V2  
0.0  
0.8



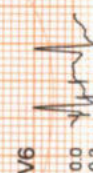V3  
-0.6  
0.4



V4  
-0.7  
0.2



V5  
-0.5  
0.7



V6  
0.0  
0.3

ONEPLUS ULTRASOUND LAB  
47, Harsh Vihar, Pitam Pura,  
Delhi-110034  
Ph. 011-42480201, 9559913011  
E-mail: oneplusul@ymail.com

1000

1000

1000



**OnePLUS**  
Ultrasound Lab  
— QUALITY FIRST... ALWAYS! —

**Dr. Nitin Agarwal**

Pathologist & Director  
Ex. Sr. Res. MAMC  
& Lok Nayak Hospital  
Ex. Chief of Lab Dr. Lal Path Labs.

**Dr. Pooja (Garg) Agarwal**

Radiologist & Director  
MAMC & Lok Nayak Hospital

<b>Name</b>	: Mrs. SUMAN KUMARI	<b>Age/Sex</b>	: 41 YRS/Female
<b>Ref. By</b>	: Dr. MEDIWHEEL	<b>Lab No</b>	: 012302030010
<b>Date</b>	: 03-Feb-2023	<b>Patient ID</b>	: LSHHI108621

### ULTRASOUND EXAMINATION----WHOLE ABDOMEN

**Liver** is mildly enlarged in size (16.6 cm) and normal in outline with altered echopattern. Diffuse increase in echogenicity of liver parenchyma is noted, suggestive of fatty infiltration (grade II). No abscess or mass lesion seen. Hepatic veins, portal vein, IVC and aorta are normal. Intrahepatic biliary radicles are not dilated. CBD is normal in caliber.

**Gall bladder** is well distended with anechoic lumen. Wall thickness is normal.

**Both kidneys** are normal in size, shape, position, outline and echopattern. Corticomedullary differentiation is maintained. No pelvicalyceal dilation or mass lesion is seen.

**Spleen** is normal in size and echotexture. No mass lesion seen.

**Pancreas** is normal in size, outline and echotexture.

**Urinary bladder** is normal in shape and position. No evidence of intravesical stone or mass seen.

**Uterus** is normal in size (measures 8.5 x 4.3 x 3.8 cm), shape, position and echopattern. No mass seen.

**Uterine cavity** is empty. **Endometrial thickness** is 4.3 mm.

**Both ovaries** appear normal in size, shape and echopattern. No tubo-ovarian mass seen.

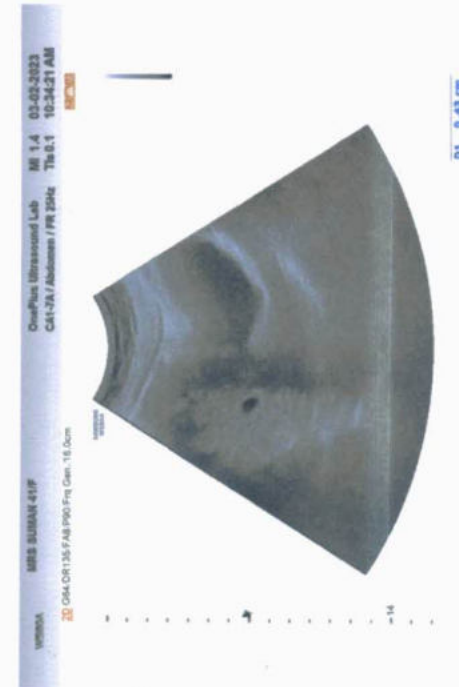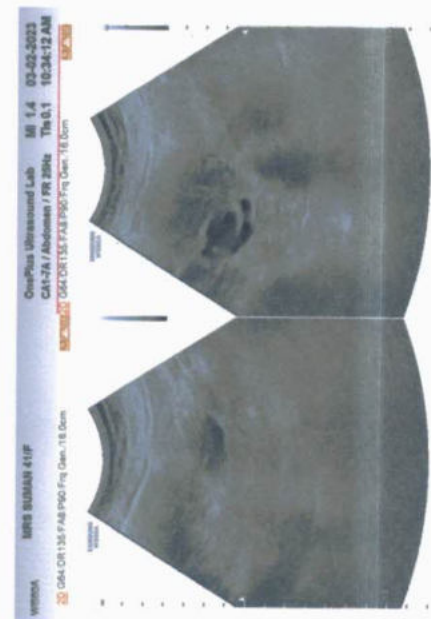
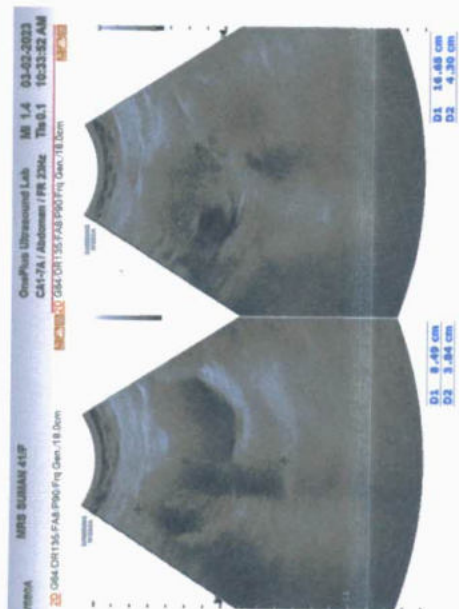
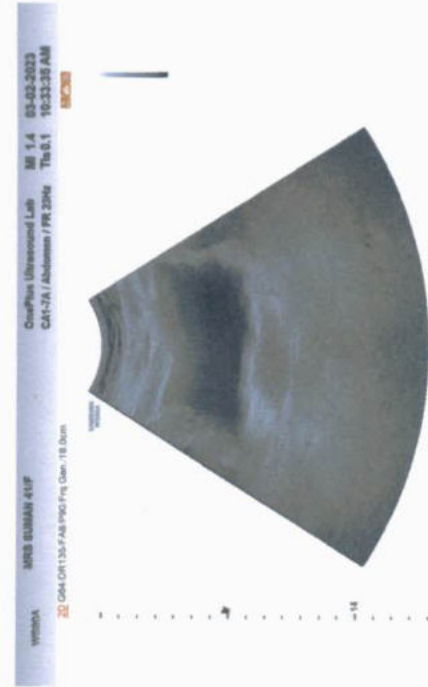
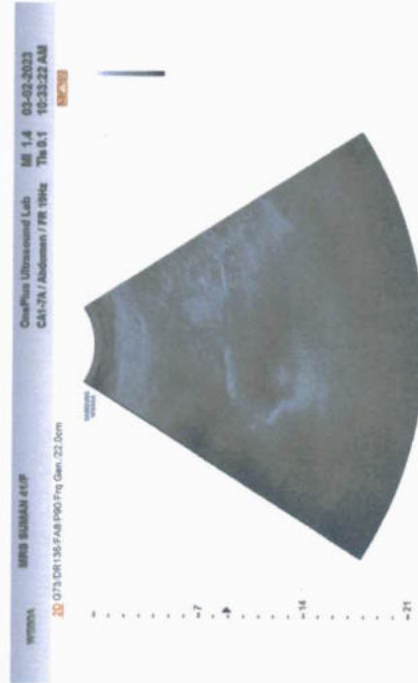
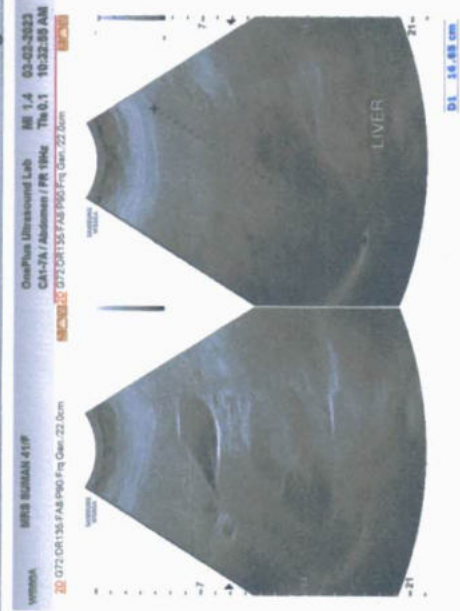

No abnormal bowel wall thickening seen in right iliac fossa.  
No free fluid seen anywhere in abdomen.

**IMPRESSION: Fatty infiltration of liver (grade II) with mild hepatomegaly.**

DR. POOJA GARG  
RADIOLOGIST  
REG NO- DMC/R/03398  
Dr. POOJA GARG  
M.B.B.S., D.M.R.D  
Reg No. DMC/R/03398  
Radiologist

Type By : darshita

47, Harsh Vihar, Pitampura, New Delhi-110034 | Ph.: 011-42480101, 9599913051  
E-mail: oneplusul@gmail.com | Web.: www.oneplusul.in






Ultrasound Image Report

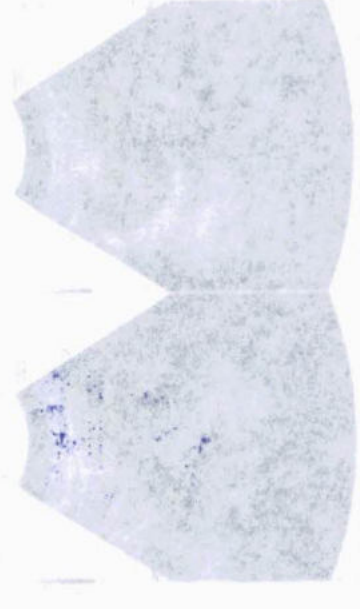DATE: 01/11/2011  
TIME: 10:30 AM  
PATIENT: [illegible]  
EXAM: [illegible]



DATE: 01/11/2011  
TIME: 10:30 AM  
PATIENT: [illegible]  
EXAM: [illegible]



DATE: 01/11/2011  
TIME: 10:30 AM  
PATIENT: [illegible]  
EXAM: [illegible]



DATE: 01/11/2011  
TIME: 10:30 AM  
PATIENT: [illegible]  
EXAM: [illegible]



DATE: 01/11/2011  
TIME: 10:30 AM  
PATIENT: [illegible]  
EXAM: [illegible]



DATE: 01/11/2011  
TIME: 10:30 AM  
PATIENT: [illegible]  
EXAM: [illegible]



DATE: 01/11/2011  
TIME: 10:30 AM  
PATIENT: [illegible]  
EXAM: [illegible]



DATE: 01/11/2011  
TIME: 10:30 AM  
PATIENT: [illegible]  
EXAM: [illegible]



DATE: 01/11/2011  
TIME: 10:30 AM  
PATIENT: [illegible]  
EXAM: [illegible]





**OnePLUS**  
Ultrasound Lab  
— QUALITY FIRST... ALWAYS! —

**Dr. Nitin Agarwal**  
Pathologist & Director  
Ex. Sr. Res. MAMC  
& Lok Nayak Hospital  
Ex. Chief of Lab Dr. Lal Path Labs.


**Dr. Pooja (Garg) Agarwal**  
Radiologist & Director  
MAMC & Lok Nayak Hospital

<b>Name</b>	: Mrs. SUMAN KUMARI	<b>Age/Sex</b>	: 41 YRS/Female
<b>Ref. By</b>	: Dr. MEDIWHEEL	<b>Lab No</b>	: 012302030010
<b>Date</b>	: 03-Feb-2023	<b>Patient ID</b>	: LSHHI108621

### X-ray-Chest PA view

Bony cage and soft tissues are normal.  
Cardiothoracic ratio is normal.  
Mediastinum is normal.  
Both hila are normal.  
Both costophrenic angles are clear.  
Both domes of diaphragm are normal.  
Lung fields are clear. No parenchymal lesion seen.

**IMPRESSION: Normal Study.**

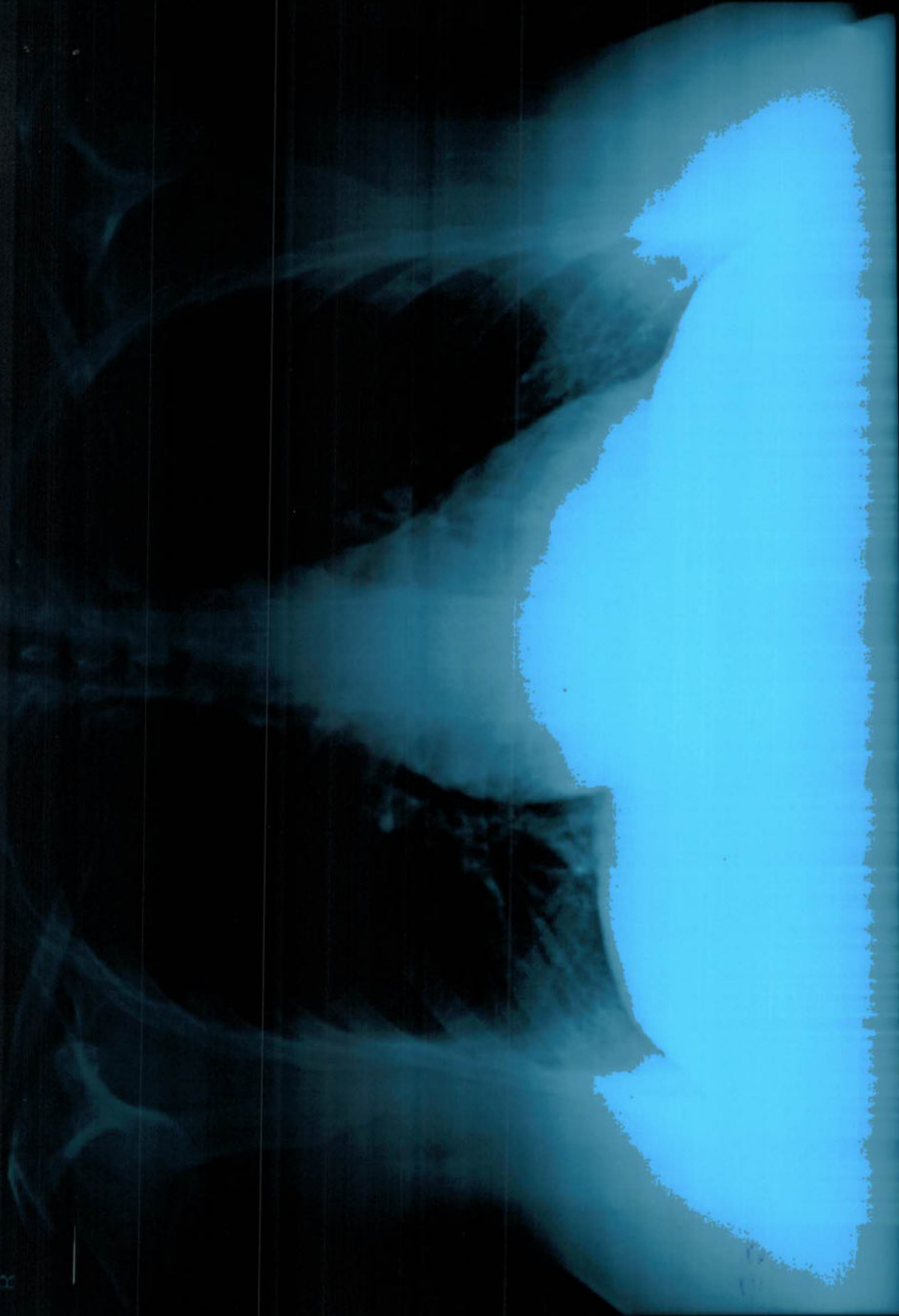
  
DR. POOJA GARG  
RADIOLOGIST  
REG NO- DMC/R/03398  
DR. POOJA GARG  
M.B.B.S. D.M.R.D  
Reg. No. DMC/R/03398  
Radiologist

Type By : darshita

47, Harsh Vihar, Pitampura, New Delhi-110034 | Ph.: 011-42480101, 9599913051  
E-mail: oneplusul@gmail.com | Web.: www.oneplusul.in

Clinical correlation is essential for final diagnosis. • If test results are unsatisfactory please contact personally or on phone. • This report is for perusal of doctors only.  
• All disputes Subject to Delhi Jurisdiction only. • Not for medicolegal purposes. • All congenital anomalies in a foetus may not be diagnosed in routine obstetric ultrasound.

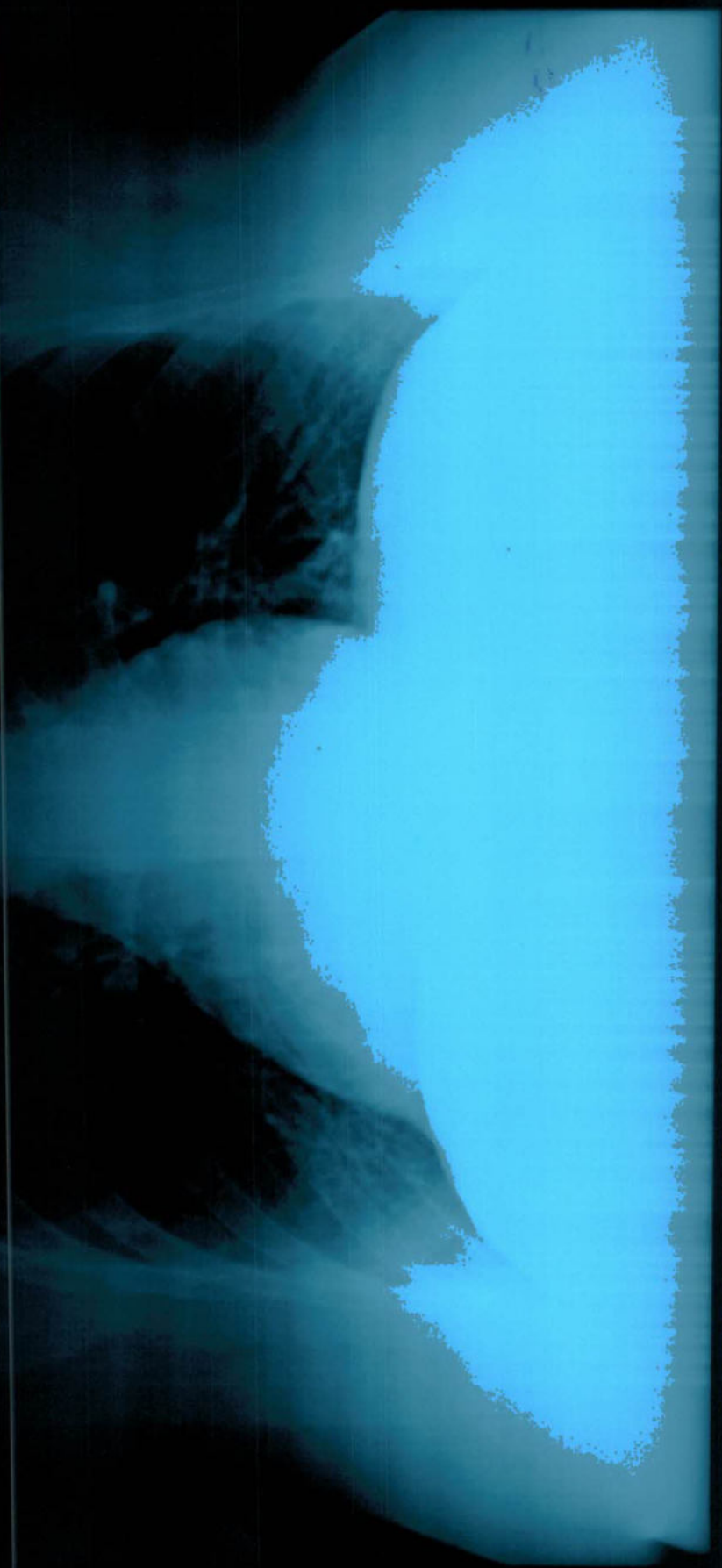
R



MRS SUMAN KUMAR 41 YRS 3/2/2023 F CHEST PA VIEW 2/3/2023

ONEPLUS ULTRASOUND LAB 47 HARSH VIHAR PITAMPURA

ONEPLUS ULTRASOUND LAB 41 HARSH VIHAR PITAMPURA  
MRS SUMAN KUMAR 41 YRS 31/5/053 F CHEST PA VIEW 51315053



R