



भारत सरकार
GOVERNMENT OF INDIA



जमशेद नोशीर ईलावीया
Jamshed Noshir Elavia
जन्म तारीख/DOB: 27/04/1962
पुरुष/ MALE
Mobile No: 8806967292



8167 7081 4889
VID : 9162 4096 7895 7076

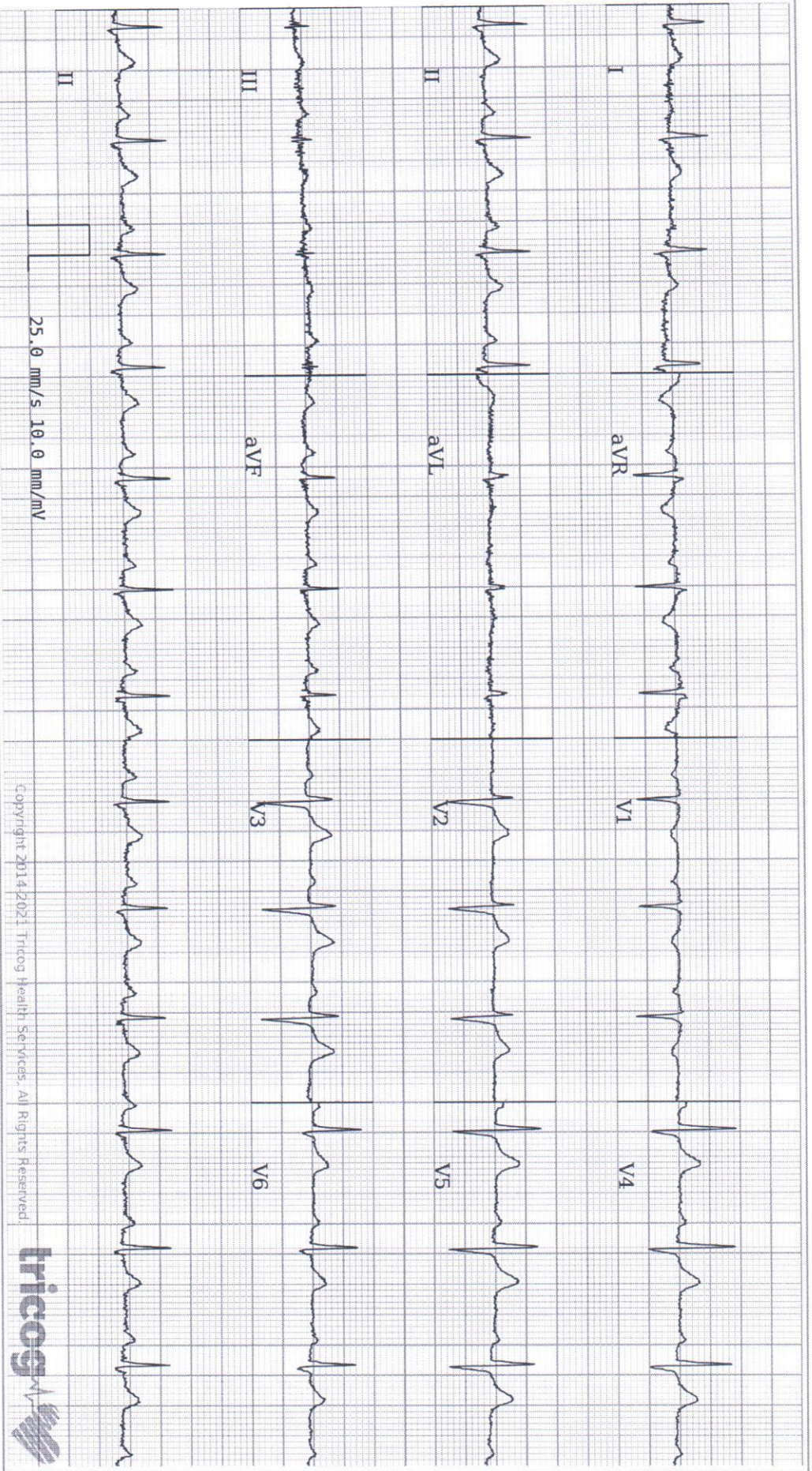
माझे आधार, माझी ओळख

[Handwritten signature]

Patient Name: JAMSHED ELAVIA

Date and Time: 17th Dec 21 9:30 AM

Patient ID: 2135130969



25.0 mm/s 10.0 mm/mV

Copyright 2014-2021 Tricog Health Services. All Rights Reserved.



Age **59** **7** **21**
years months days

Gender **Male**

Heart Rate **82 bpm**

Patient Vitals

BP: NA
Weight: NA
Height: NA
Pulse: NA
SpO2: NA
Resp: NA
Others: _____

Measurements

QS RD: 80 ms
QT: 352 ms
QTc: 411 ms
PR: 184 ms
P-R-T: 65° 41° 51°

ECG Within Normal Limits: Sinus Rhythm, Normal Axis. Within Normal limit. Please correlate clinically.

REPORTED BY

DR. I. U. BAMB
M.B.B.S., M.D. (Medicine)
Reg. No. 39452

DR. ISHWARLAL BAMB
M.B.B.S MD (MEDICINE)
cardiologist
39452

Disclaimer: 1) Analysis in this report is based on ECG alone and should be used as an adjunct to clinical history, symptoms, and results of other invasive and non-invasive tests and must be interpreted by a qualified physician. 2) Patient vitals are as entered by the clinician and not derived from the ECG.



CID : 2135130969
Name : Mr JAMSHED ELAVIA
Age / Sex : 59 Years/Male
Ref. Dr :
Reg.Location : Swargate, Pune Main Centre

Reg. Date : 17-Dec-2021 / 11:06
Reported : 17-Dec-2021 / 11:26

USG WHOLE ABDOMEN

LIVER: Normal in size (measures 13.4 cms) and **shows generalised increased echogenicity**. No IHBR dilatation. Hepatic veins appear normal.Portal vein and common bile duct show normal calibre.

GALL BLADDER : Partially distended. No evidence of any pericholecystic collection.

PANCREAS : Normal in size and echotexture. Pancretic duct is normal.

SPLEEN : Normal in size and echopattern. No focal lesion. Splenic vein is normal.

RIGHT KIDNEY : Measures 9.1 x 4.3 cm. Normal in size and echogenicity. No calculus or hydronephrosis. Corticomedullary differentiation is maintained.

LEFT KIDNEY : Measures 9.5 x 4.5 cm. Normal in size and echogenicity. No calculus or hydronephrosis. Corticomedullary differentiation is maintained.

Retroperitonium and flanks obscured due to bowel gas.

Prominent bowel loops seen in the abdomen.

No evidence of lymphnodes noted.

No free fluid in abdomen.

URINARY BLADDER : Well distended. No calculi. Wall thickness is normal.
Pre void volume :- 262 cc Post void volume :- 24 cc (Not significant)

PROSTATE : Enlarged in size.
It measures 4.0 x 3.6 x 3.5 cm (Weight 26.6 gms)

IMPRESSION :

Normal size liver with fatty changes.

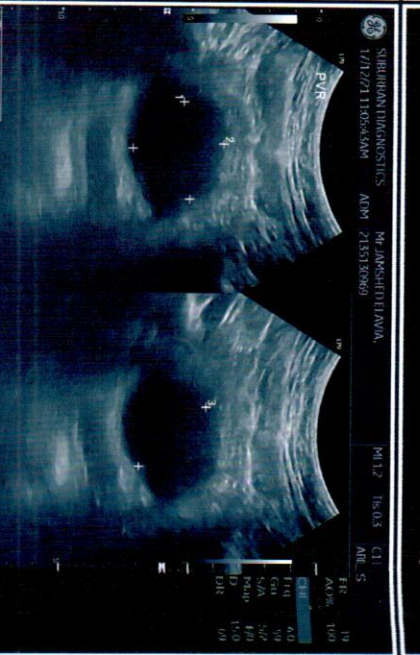
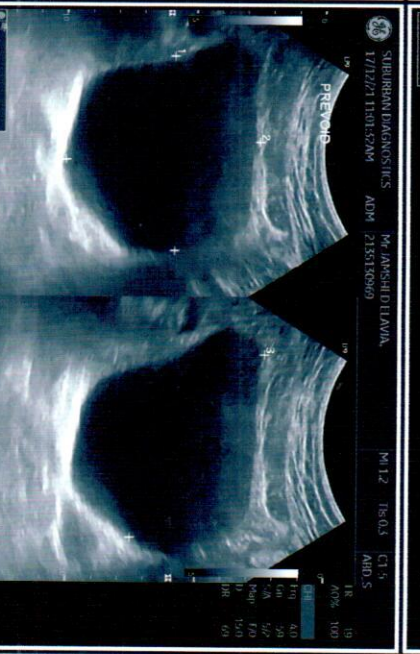
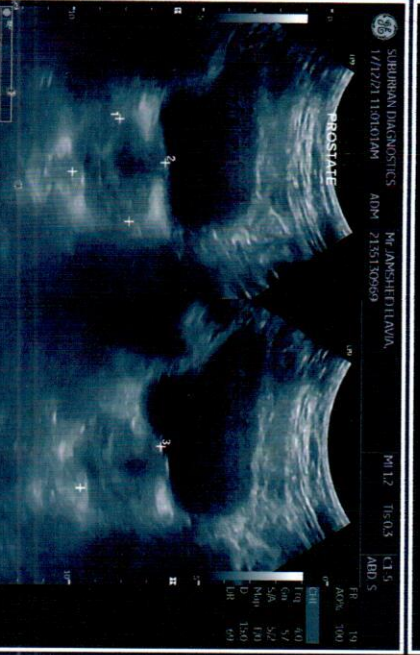
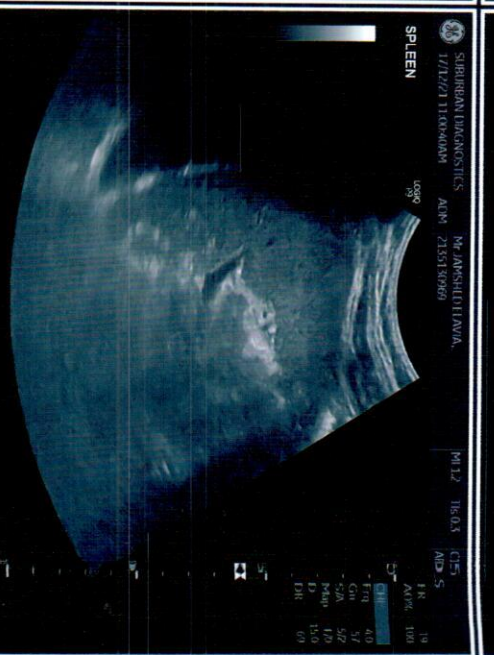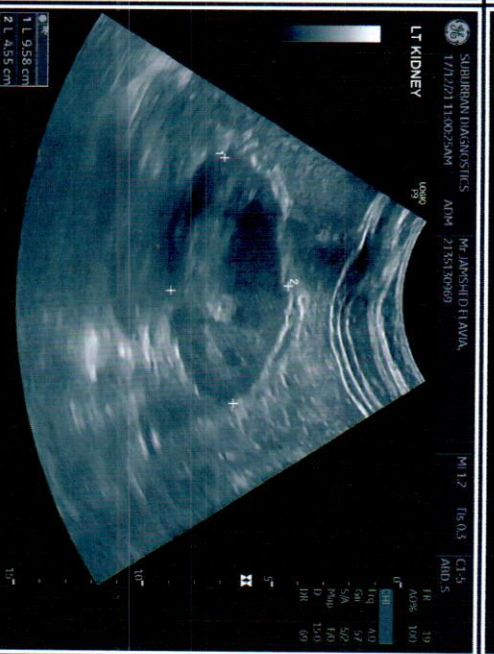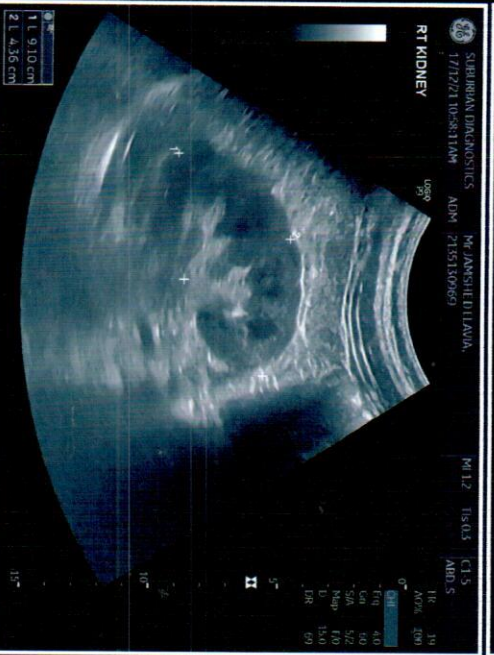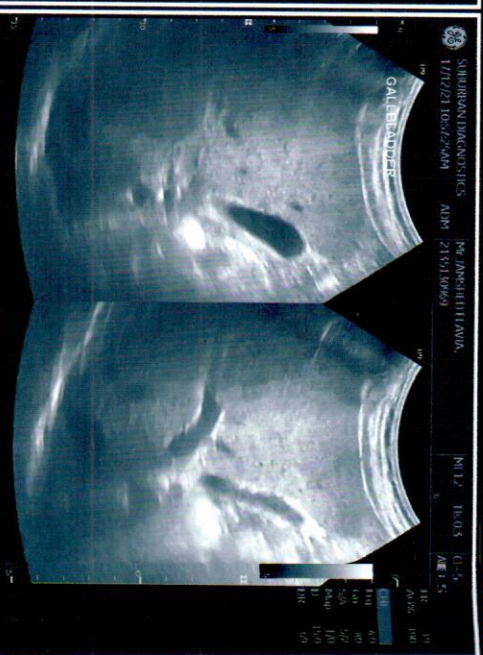
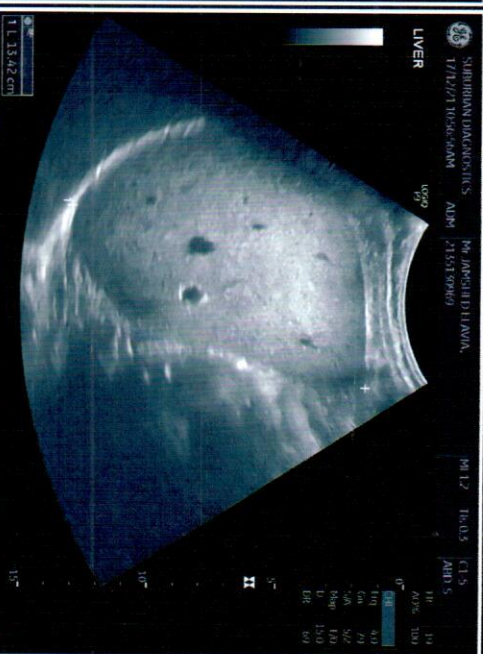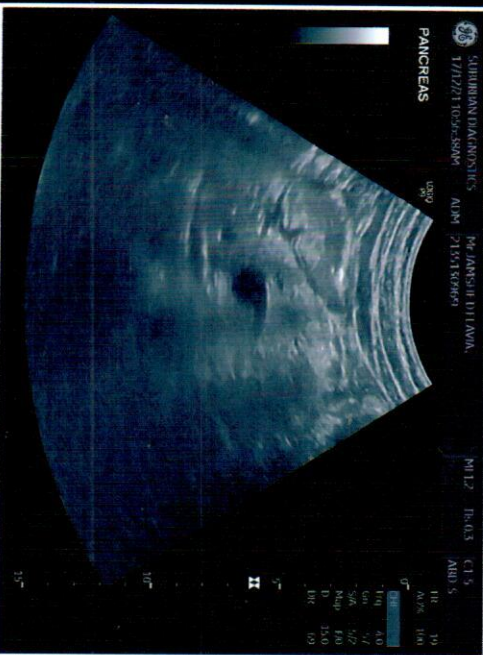Mild prostatic enlargement without significant post void residue.

Clinical correlation is indicated.

-----End of Report-----

DR. NIKHIL G. JOSHI
M.B.B.S., D.M.R.E.
REG. NO. 2001/02/397

Click here to view images <http://202.143.96.162/Suburban/Viewer?ViewerType=3&AccessionNo=2021121708082060>



Patient Name: Mr. Jamshed elavia

Ref :

Age /Sex:59 /M

Date:17/12/2021

2D ECHO REPORT

Findings:-

- Normal chamber dimensions
- Paradoxical septal motion present.
- No concentric LVH
- Good LV systolic function, LVEF-55%
- Normal cardiac valves
- Intact IAS/IVS.
- No LV clot /PE/vegetation.

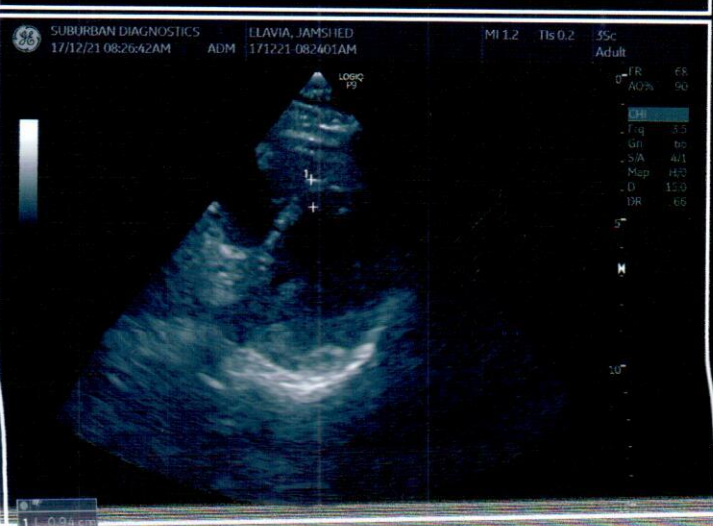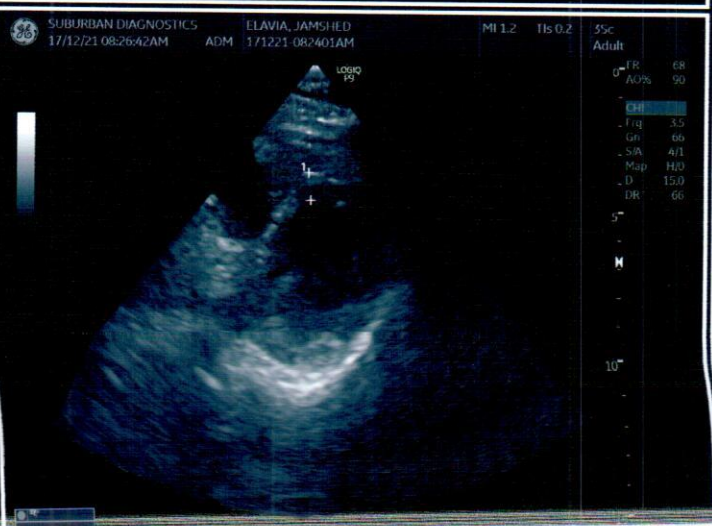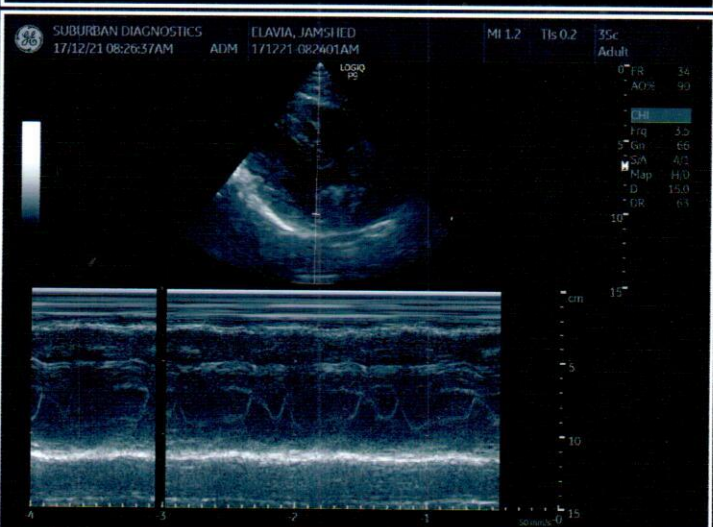
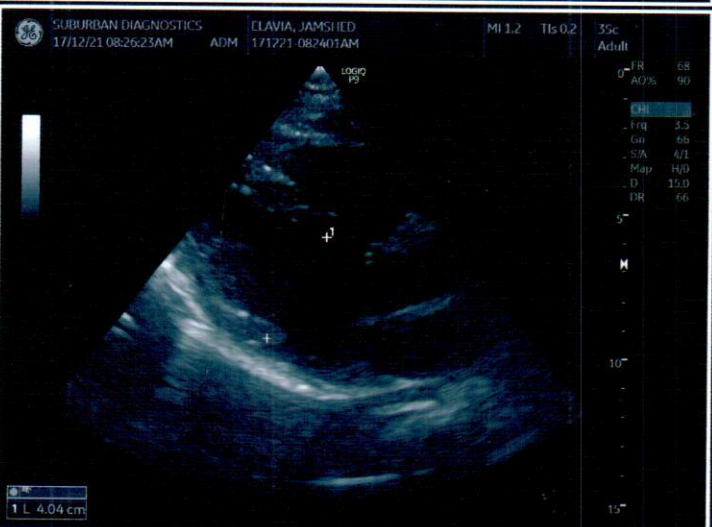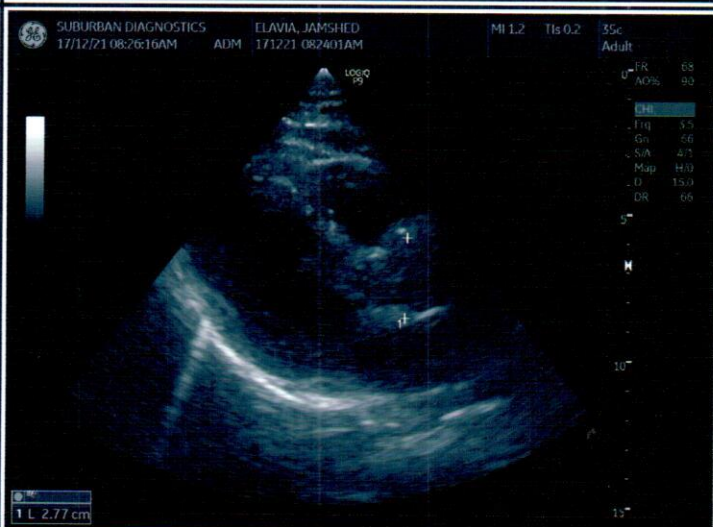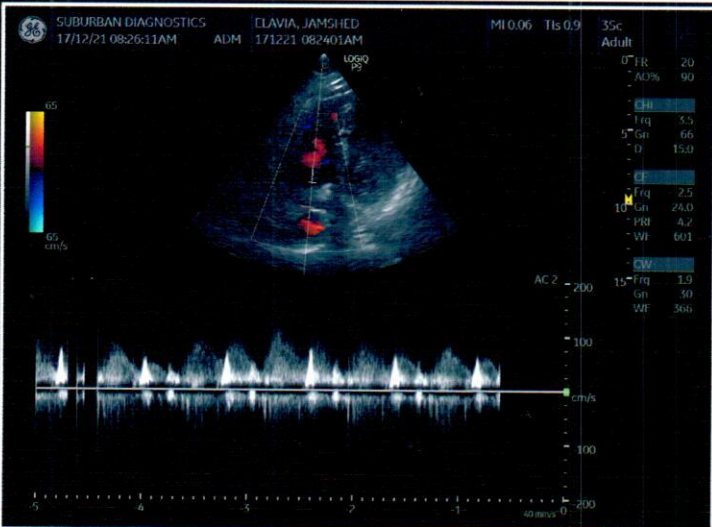
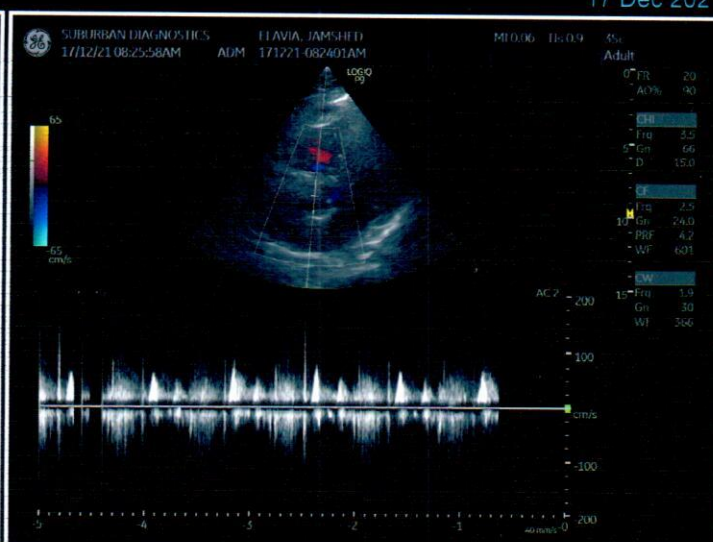
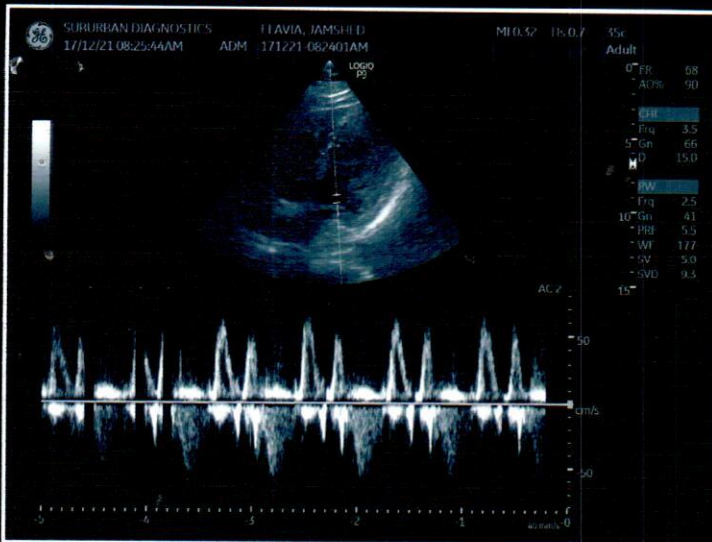
DOPPLER

- No LV DD
- No PH, RVSP- 23 mm HG
- NO AS/AR/Trivial MR

Measurements(mm):-AO-27, LA-25, IVS-9, PW-9, LVIDd-40, LVIDs-28, LVEF-55%

**IMPRESSION:- PARADOXICAL SEPTAL MOTION PRESENT
WITH GOOD LV FUNCTION(LVEF-55%).**


Dr RAJESH WAGH
MD (MEDICINE), DM (CARDIOLOGY).





CID : 2135130969
Name : Mr JAMSHED ELAVIA
Age / Sex : 59 Years/Male
Ref. Dr :
Reg.Location : Swargate, Pune Main Centre

Reg. Date : 17-Dec-2021 / 09:23
Reported : 17-Dec-2021 / 09:35

X-RAY CHEST PA VIEW

The lung fields are clear with no parenchymal lesion.

The cardiothoracic ratio is maintained and the cardiac outline is normal.

The domes of the diaphragm are normal.

The cardio and costophrenic angles are clear.

Bony thorax is normal.

IMPRESSION : Essentially normal X-ray of the chest.

Clinical corelation is indicated.

-----End of Report-----

DR. NIKHIL G. JOSHI
M.B.B.S., D.M.R.E.
REG. NO. 2001/02/397

Click here to view images <http://202.143.96.162/Suburban/Viewer?ViewerType=3&AccessionNo=2021121708082052>

CID# : 2135130969
Name : MR.JAMSHED ELAVIA
Age / Gender : 59 Years/Male
Consulting Dr. :-
Reg.Location : Swargate, Pune (Main Centre)

SID# : 177804610183
Registered : 17-Dec-2021 / 08:07
Collected : 17-Dec-2021 / 08:07
Reported : 17-Dec-2021 / 15:18
Printed : 17-Dec-2021 / 15:27

PHYSICAL EXAMINATION REPORT

History and Complaints:

H/O DM & HTN

EXAMINATION FINDINGS:

Height (cms):	162cm	Weight (kg):	65kg
Temp (0c):	Afebrile	Skin:	Normal
Blood Pressure (mm/hg):	120/80mmHg	Nails:	Healthy
Pulse:	74/min	Lymph Node:	Not Palpable

Systems

Cardiovascular: S1 S2 Normal No Murmurs
Respiratory: Normal
Genitourinary: Normal
GI System: Soft non tender no Organomegaly
CNS: Normal

IMPRESSION:

*old DM & HTN → Hypercreatininemia
fatty liver & BFP*

ADVICE:

*- Consult family doctor (physician)
- Control DM & HTN
- low salt diet
- Ref to urologist*

CHIEF COMPLAINTS:

- | | |
|----------------------|----|
| 1) Hypertension: | NO |
| 2) IHD | NO |
| 3) Arrhythmia | NO |
| 4) Diabetes Mellitus | NO |

Dr. I. U. BAMB
M.B.B.S., M.D. (Medicine)
Reg. No. 39452

PUNE LAB ADDRESS: Seraph Centre, Opp. BSNL Exchange, Shahu College Road, Off Pune-Satara Road, Behind Panchami Hotel, Pune - 411009

CENTRAL PROCESSING LAB: 2nd Floor, Aston, Sundervan Complex, Above Mercedes Showroom, Andheri West, Mumbai - 400053

HEALTHLINE - MUMBAI: 022-6170-0000 | **OTHER CITIES:** 1800-266-4343 | **For Feedback -** customerservice@suburbandiagnosics.com | www.suburbandiagnosics.com

CID# : 2135130969
Name : MR.JAMSHED ELAVIA
Age / Gender : 59 Years/Male
Consulting Dr. : -
Reg.Location : Swargate, Pune (Main Centre)

SID# : 177804610183
Registered : 17-Dec-2021 / 08:07
Collected : 17-Dec-2021 / 08:07
Reported : 17-Dec-2021 / 15:18
Printed : 17-Dec-2021 / 15:27

- | | |
|--|----|
| 5) Tuberculosis | NO |
| 6) Asthama | NO |
| 7) Pulmonary Disease | NO |
| 8) Thyroid/ Endocrine disorders | NO |
| 9) Nervous disorders | NO |
| 10) GI system | NO |
| 11) Genital urinary disorder | NO |
| 12) Rheumatic joint diseases or symptoms | NO |
| 13) Blood disease or disorder | NO |
| 14) Cancer/lump growth/cyst | NO |
| 15) Congenital disease | NO |
| 16) Surgeries | NO |
| 17) Musculoskeletal System | NO |

PERSONAL HISTORY:

- | | |
|---------------|----------|
| 1) Alcohol | NO |
| 2) Smoking | NO |
| 3) Diet | Veg |
| 4) Medication | DM & HTN |

*** End Of Report ***



Dr. I U BAMB

Dr. I. U. BAMB
M.B.B.S., M.D. (Medicine)
Reg. No. 39462

PUNE LAB ADDRESS: Seraph Centre, Opp. BSNL Exchange, Shahu College Road, Off Pune-Satara Road, Behind Panchami Hotel, Pune - 411009

CENTRAL PROCESSING LAB: 2nd Floor, Aston, Sundervan Complex, Above Mercedes Showroom, Andheri West, Mumbai - 400053

HEALTHLINE - MUMBAI: 022-6170-0000 | **OTHER CITIES:** 1800-266-4343 | **For Feedback -** customerservice@suburbandiagnosics.com | www.suburbandiagnosics.com

Brief Disclaimer: (1) Suburban Diagnostics ensures that the tests are conducted with utmost care and safety and are performed on samples received as per the sample collection guide of Suburban Diagnostics. (2) Sample may be rejected if unacceptable for the requested tests. (3) Test results may vary from laboratory to laboratory and also in some parameters from time to time for the same patient. (4) Report must not be copied in part, only in full. (5) This report is not valid for medico-legal purposes. (6) Patient information or data will not be communicated to a third party except in the case of a notifiable disease to a Public Care Unit. (7) Suburban Diagnostics reserves the right to subcontract samples to other laboratories as required. (8) Suburban Diagnostics is not liable for any penalties or liabilities arising out of or relating in any way to these services and/or content or information provided herein. (9) For the elaborated disclaimer, please turn over the page or visit our website.