



भारतीय विशिष्ट पहचान प्राधिकरण

Unique Identification Authority of India

पता:

S/O महेश प्रसाद बरनवाल, रंग महल रोड, गोपाल पट्टी रेलवे  
क्रासिंग, भदोही, सन्त रविदास नगर भदोही,  
उत्तर प्रदेश - 221401

**Address:**

S/O Mahesh Prasad Baranwal, RANG  
MAHAL ROAD, GOPAL PATTI, RAILWAY  
CROSSING, Bhadohi, Sant Ravidas Nagar  
Bhadohi,  
Uttar Pradesh - 221401



QR Code with Photograph

9319 8018 7507

VID : 9163 5939 8822 7597



help@uidai.gov.in

www.uidai.gov.in



GPS Map Camera



Varanasi, Uttar Pradesh, India

44-B3, Durgakund, Bhelupur, Varanasi, Uttar  
Pradesh 221001, India

Lat 25.28925°

Long 82.993361°

25/02/23 09:52 AM GMT +05:30



भारत सरकार

Government of India



शशांक बरनवाल

Shashank Baranwal

जन्म तिथि/DOB: 21/12/1992

पुरुष/ MALE



9319 8018 7507

VID: 9163 5939 8822 7597

मेरा आधार, मेरी पहचान



GPS Map Camera



Varanasi, Uttar Pradesh, India

44-B3, Durgakund, Bhelupur, Varanasi, Uttar Pradesh 221001, India

Lat 25.289251°

Long 82.993356°

25/02/23 09:52 AM GMT +05:30

Google

**Facilities:**

All clinical Biomedical & Hematology Investigations including Bone Marrow Examination  
VPT, Podiascan & Complete Foot Care (First Time in Purvanchal)  
All Hormonal Investigation by Chemiluminescent Method  
Visceral Fat by (AB-140) Ambulatory BP Monitoring  
CGMS & Insulin Pump Available  
PFT, 2D-ECHO (Color Doppler), Holter, TMT, Cardiac-3 available  
VIA, VILI, Colposcopy available  
Special Endocrinological Investigation Protocols.

ISO 9001:2008 Certified  
Mobile: 9389994334, 9554572190, 9453837595



# Panacea Pathology

## Clinical Reference Lab

Persistence, Preparedness and Precision  
EQAS (CMC Vellore Attached) & IQAS System  
पूर्वाचल की सर्वोत्तम गुणवत्ता वाली पैथोलॉजी

PATIENT NAME : SHASHANK BARANWAL

AGE/GENDER : 31YRS/MALE

REFD BY DR. : ARCO FEMI HEALTHCARE LTD.

RECEIVED DATE : 25-02-2023(09:00AM)

SAMPLE : BLOOD & URINE

REPORT DATE : 25-02-2023(07:00PM)

## PATHOLOGY REPORT

### COMPLETE BLOOD COUNT (CBC)

TEST	LAB TEST VALUES	NORMAL RANGE
<b>HEMOGRAM</b>		
HEMOGLOBIN (FLOW CYTOMETRY)	15.0	13 – 16 gm/dl
TOTAL LEUCOCYTE COUNT (TLC)	5,700	4000 – 11000
RBC COUNT	5.07	3.5 – 5.5
PCV (HCT)	46.7	37 – 47
MCV	92.1	80 – 95
MCH	29.5	28 – 34
MCHC	32.1	30 – 36
PLATELET COUNT	1,41,000	1,50,000 – 4,00,000
E.S.R. (WINTROBE FIRST HOURS)	10.0	20 mm/1 <sup>st</sup> hr
<b>DIFFERENTIAL LEUCOCYTE</b>		
NEUTROPHILS	40	40 – 75%
LYMPHOCYTES	52	20 – 45%
EOSINOPHILS	05	1 – 6%
MONOCYTES	03	2 – 8%
BASOPHILS	00	< 2%

### RENAL & KIDNEY PROFILE, SERUM

TEST	LAB TEST VALUES	NORMAL RANGE
<b>RENAL FUNCTION TESTS</b>		
BLOOD UREA NITROGEN (BUN)	9.24	10 – 50 mg/dl
SERUM CREATININE	0.80	0.60 – 1.60 mg/dl
URIC ACID	3.92	3.60 – 7.70 mg/dl
ALKALINE PHOSPHATASE (ALP)	71.0	142 – 353 mg/dl
TOTAL PROTIENS	7.41	0 – 39 mg/dl
ALBUMIN	4.0	3.8 – 5.4 mg/dl
SERUM GLOBULIN	3.41	2.1 – 3.5 mg/dl
CALCIUM	8.0	8.80 – 10.20
PHOSPHORUS	3.14	2.50 – 5.00
SERUM SODIUM NA+	1.015	135.00 – 155.00 mEq/Ltr
SERUM POTASIAM K+	4.12	3.60 – 5.50 mEq/Ltr
ICALCIUM	1.22	1.10 – 1.35 mmol/L
SERUM CHLORIDE CL+	101.3	98.00 – 110.00 mEq/Ltr

PAGE 1

Lab Technician

PANACEA HOSPITAL  
(A UNIT OF AAROA HEALTH CARE PVT. LTD.)  
REG. NO.: 101592  
B.36/44, B-4, KABIR NAGAR  
DURGAKUND, Pathology

Timing : 8.00 a.m. to 9.00 p.m. (Sunday 8.00 a.m. to 3.00 p.m.)

This Report is not valid for medico legal purpose

**Note:** These tests have technical limitations. Clinico-pathological interpretation is necessary. In case of any disparity test may be repeated immediately.

Address : 36/44 FK Kabir Nagar, Durgakund, Varanasi – 221005

Email: [dramishra@gmail.com](mailto:dramishra@gmail.com), [drpallaviojha@gmail.com](mailto:drpallaviojha@gmail.com) Website: [panaceahospital.org](http://panaceahospital.org)

**Facilities:**  
 All clinical Biomedical & Hematology Investigations  
 including Bone Marrow Examination  
 VPT, Podiascan & Complete Foot Care (First Time in Purvanchal)  
 All Hormonal Investigation by Chemiluminescent Method  
 Visceral Fat by (AB-140) Ambulatory BP Monitoring  
 CGMS & Insulin Pump Available  
 PFT, 2D-ECHO (Color Doppler), Holter, TMT, Cardiac-3 available  
 VIA, VILI, Colposcopy available  
 Special Endocrinological Investigation Protocols.

ISO 9001:2008 Certified  
 Mobile: 9389994334, 9554572190, 9453837595



# Panacea Pathology

## Clinical Reference Lab

Persistence, Preparedness and Precision  
 EQAS (CMC Vellore Attached) & IQAS System  
 पूर्वांचल की सर्वोत्तम गुणवत्ता वाली पैथोलॉजी

<b>PATIENT NAME</b> : SHASHANK BARANWAL	<b>AGE/GENDER</b> : 31YRS/MALE
<b>REFD BY DR.</b> : ARCO FEMI HEALTHCARE LTD.	<b>RECEIVED DATE</b> : 25-02-2023(09:00AM)
<b>SAMPLE</b> : BLOOD & URINE	<b>REPORT DATE</b> : 25-02-2023(07:00PM)

### PATHOLOGY REPORT

#### LIPID PROFILE, SERUM

TEST	LAB TEST VALUES	NORMAL RANGE
<b>BLOOD CHEMISTRY</b>		
TOTAL CHOLESTEROL (SERUM)	155.0	Desirable:- < 200 mg/dl Borderline:- 200 – 239 mg/dl High:- > 240 mg/dl
TRIGLYCERIDES (SERUM)	142.0	35 – 170 mg/dl
HDL CHOLESTEROL (SERUM)	40.0	35.30 – 79.50 mg/dl
LDL CHOLESTEROL (SERUM)	86.6	< 130 mg/dl
VLDL	28.4	< 40 mg/dl
CHOLESTROL/HDL RATIO	3.8	< 3.0 Low Risk Ratio 3.0 – 5.0 Avg Risk > 5.0 High Risk
LDL/HDL RATIO	0.71	< 3 Ratio

#### BLOOD GROUP

TEST	LAB TEST VALUES
<b>BLOOD GROUP ABO &amp; RH FACTOR</b>	
BLOOD GROUP	"B"
RH FACTOR	POSITIVE

#### GLYCOSYLATED HEMOGLOBIN (HBA1C)

TEST	LAB TEST VALUES	NORMAL RANGE
HBA1C	5.8	Normal : <5.97 % Good Control : 5.97 – 6.81% Fair Control : 6.81 – 7.65% Poor Control : >7.65%

#### THYROID PROFILE (T3, T4, TSH)

TEST	LAB TEST VALUES	NORMAL RANGE
<b>THYROID FUNCTION TEST</b>		
T3	1.12	0.60 – 1.81 ng/ml
T4	8.56	4.50 – 10.90 ug/dl
TSH	3.23	0.39 – 6.10 uIU/mL

PAGE 2

Lab Technician

PANACEA HOSPITAL  
 (A UNIT OF AAROHA HEALTH CARE PVT. LTD.)  
 REG. NO. AL/1009  
 B.36/44, B-4, KABIR NAGAR  
 DURGAKUND, VARANASI  
 M.D., Pathology

Timing : 8.00 a.m. to 9.00 p.m. (Sunday 8.00 a.m. to 3.00 p.m.)

This Report is not valid for medico legal purpose

**Note:** These tests have technical limitations. Clinico-pathological interpretation is necessary. In case of any disparity test may be repeated immediately.

Address : 36/44 FK Kabir Nagar, Durgakund, Varanasi – 221005

Email: [dramishra@gmail.com](mailto:dramishra@gmail.com), [drpallaviojha@gmail.com](mailto:drpallaviojha@gmail.com) Website: [panaceahospital.org](http://panaceahospital.org)

**Facilities:**  
 All Clinical Biomedical & Hematology Investigations  
 including Bone Marrow Examination  
 VPT, Podiascan & Complete Foot Care (First Time in Purvanchal)  
 All Hormonal Investigation by Chemiluminescent Method  
 Visceral Fat by (AB-140) Ambulatory BP Monitoring  
 CGMS & Insulin Pump Available  
 PFT, 2D-ECHO (Color Doppler), Holter, TMT, Cardiac-3 available  
 VIA, VILI, Colposcopy available  
 Special Endocrinological Investigation Protocols.

ISO 9001:2008 Certified  
 Mobile: 9389994334, 9554572190, 9453837595



# Panacea Pathology

## Clinical Reference Lab

Persistence, Preparedness and Precision  
 EQAS (CMC Vellore Attached) & IQAS System  
 पूर्वांचल की सर्वोत्तम गुणवत्ता वाली पैथोलॉजी

PATIENT NAME : SHASHANK BARANWAL	AGE/GENDER : 31YRS/MALE
REFD BY DR. : ARCO FEMI HEALTHCARE LTD.	RECEIVED DATE : 25-02-2023(09:00AM)
SAMPLE : BLOOD & URINE	REPORT DATE : 25-02-2023(07:00PM)

### PATHOLOGY REPORT

#### LIVER PROFILE TEST, SERUM

TEST	LAB TEST VALUES	NORMAL RANGE
<b>BIO CHEMISTRY</b>		
TOTAL BILIRUBIN	0.66	0.0 – 1.1 mg/dl
DIRECT BILIRUBIN	0.21	0.0 – 0.2 mg/dl
INDIRECT BILIRUBIN	0.45	< 0.90 mg/dl
SGOT (AST)	23.0	0 – 52 mg/dl
SGPT (ALT)	25.0	0 – 39 mg/dl
GGT (GYT)	20.0	< 55 U/L

#### URINE ROUTINE EXAMINATION

TEST	LAB TEST VALUES	NORMAL RANGE
<b>PHYSICAL EXAMINATION</b>		
QUANTITY	30	ML
COLOUR	STRAW	PALE YELLOW
APPEARANCE	CLEAR	CLEAR
SPECIFIC GRAVITY	1.015	1.01 – 1.03
PH	5.5	4.7 – 7.5
<b>CHEMICAL EXAMINATION</b>		
GLUCOSE	Not Detected	Not Detected
PROTEIN	NIL	Not Detected
<b>MICROSCOPIC EXAMINATION</b>		
PUS CELLS	1-2	0-5
RBC	Not Detected	Not Detected
EPITHELIAL CELLS	2-3	0-5
CASTS	Not Detected	Not Detected
CRYSTALS	Not Detected	Not Detected
BACTERIA	Not Detected	Not Detected

#### RANDOM/FASTING BLOOD SUGAR

TEST	LAB TEST VALUES	NORMAL RANGE
<b>RBS/FBS</b>		
RANDOM BLOOD SUGAR	117.0	125-140 mg/dl
FASTING BLOOD SUGAR	77.0	70-110 mg/dl

----- End of Report -----

Lab Technician

PANACEA HOSPITAL  
 (A UNIT OF AAROA HEALTH CARE PVT. LTD.)  
 REG. NO. 101500  
 B.36/44, B-4, KABIR NAGAR  
 DURGAMUDA Pathology

Timing : 8.00 a.m. to 9.00 p.m. (Sunday 8.00 a.m. to 3.00 p.m.)

This Report is not valid for medico legal purpose

**Note:** These tests have technical limitations. Clinico-pathological interpretation is necessary. In case of any disparity test may be repeated immediately.

Address : 36/44 FK Kabir Nagar, Durgakund, Varanasi – 221005

Email: [dramishra@gmail.com](mailto:dramishra@gmail.com), [drpallaviojha@gmail.com](mailto:drpallaviojha@gmail.com) Website: [panaceahospital.org](http://panaceahospital.org)



# PANACEA HOSPITAL

B 36/44 F.K KABIR NAGAR, DURGAKUND  
TOLLFREE NO-18001233070.  
Whatsapp No - 8795832852  
www.piire.org



## OP Slip

Print Date : 25-Feb-2023 12:55PM



UHID No	:- UD-22230003767	OP No	:- OP-22230013970	OP Date	:- 25 Feb 2023 12:55PM
Patient Name	:- Mr SHASHANK BARANWAL	Age/Sex	:- 31 Y/Male	Mobile No	:- 9540047150
Father	:-	Department	:- OPHTHALMOLOGY		
Pay Type	:- Cash	Consultant	:- Dr ANKIT SONI (MBBS,MS)		
Token No	:- NOR. - 1	Paid	:- 0.00		
Patient Type	:- Normal				
Address	:- BHADOHI, BHADOHI				

BP :-  
height :-  
Weight (kg) :-  
BMI :-

**Rx**  
 vitglan  
 VA 6/18  
 6/18  
 VA 6/6x  
 6/6x  
 o/o Radiation Checkup

AR < -1.00 DS - 1.00 DC x 85  
 - 1.25 DS  
 ST < -0.75 DS - 0.50 DC x 85  
 - 0.75

Ant. seg - wnl (BE)

fundus 0.4-0.5  
 0.4-0.5 / Rest (normal)

Opt (macula)  
 Fundus photo

- ① vit glan (same)
- ② Scm eld > 4x 8x 2w  
0000
- ③ Cup Adenni > 0x 10d
- ④ Iobct eld > 00x 2w

Printed By : Mr NITIN YADAV

Created By : Mr NITIN YADAV



# PANACEA HOSPITAL

B 36/44 F.K KABIR NAGAR, DURGAKUND  
TOLLFREE NO-18001233070.  
Whatsapp No - 8795832852  
www.piire.org



## OP Slip

Print Date : 25-Feb-2023 09:53AM



<b>UHID No</b> :- UD-22230003767	<b>OP No</b> :- OP-22230013948	<b>OP Date</b> :- 25 Feb 2023 9:52AM
<b>Patient Name</b> :- Mr SHASHANK BARANWAL	<b>Age/Sex</b> :- 31 Y/Male	<b>Mobile No</b> :- 9540047150
<b>Father</b> :-	<b>Department</b> :- DIABETES, ENDOCRINOLOGY & METABOLIC PHYSICIAN	
<b>Pay Type</b> :- Cash	<b>Consultant</b> :- Dr ASHUTOSH MISHRA (MD(MEDICINE), IMS, BHU)	
<b>Token No</b> :- NOR. - 3	<b>Paid/Bal</b> :- 0.00 /500.00	
<b>Patient Type</b> :- Normal		
<b>Address</b> :- BHADOHI, BHADOHI		

BP :- 110/80 **Rx**  
 height :- 171  
 Weight (kg) :- 74  
 BMI :-

SpO<sub>2</sub> - 96  
 PR - 78  
 RBS - 92  
 PGFR - 150

Aew  
 eye opinion.  
 Lenses + OCP - 1000

Rx.  
 -----  
 o Tab. Berofoplu . TDS x (20)  
 o Atkum (60) MD x (10)  
 ↓  
 SUNITUM  
 -----

Printed By : Mr NITIN YADAV  
 Created By : Mr NITIN YADAV





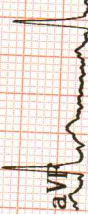
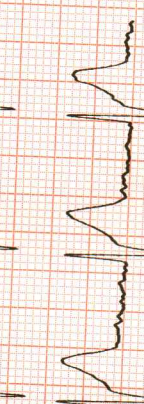
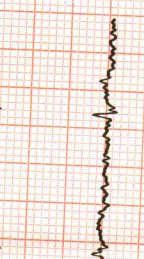
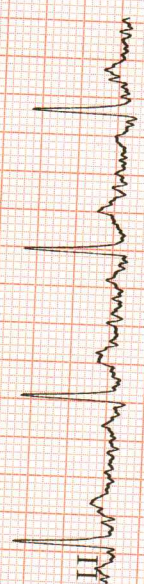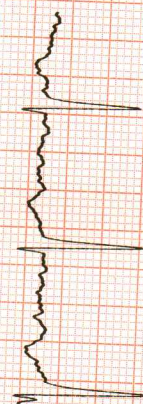
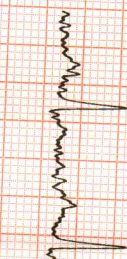
AUTO 10mm/mV

10mm/mV

BPL - 02

10mm/mV

10mm/mV

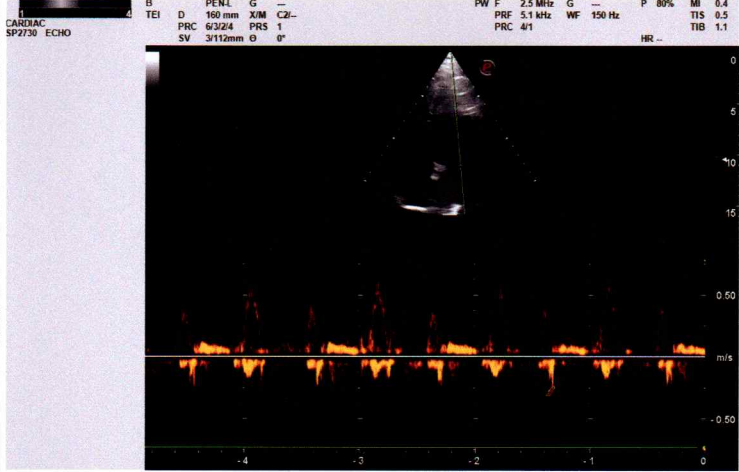

25mm/s AC50Hz+EMG35Hz+DFT

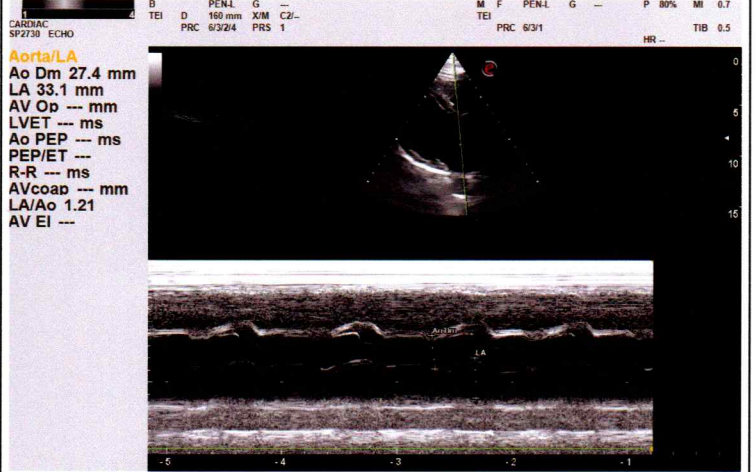
RT

CARD

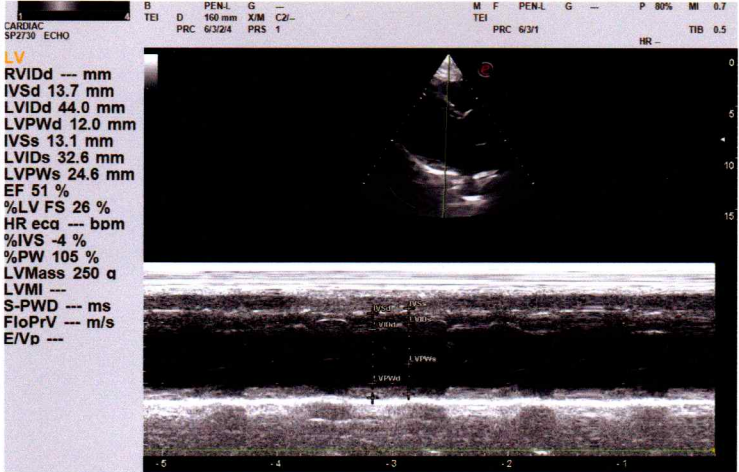
SHASHANK BARNWAL 31Y/M 25 02 2023 10:07:58 AM



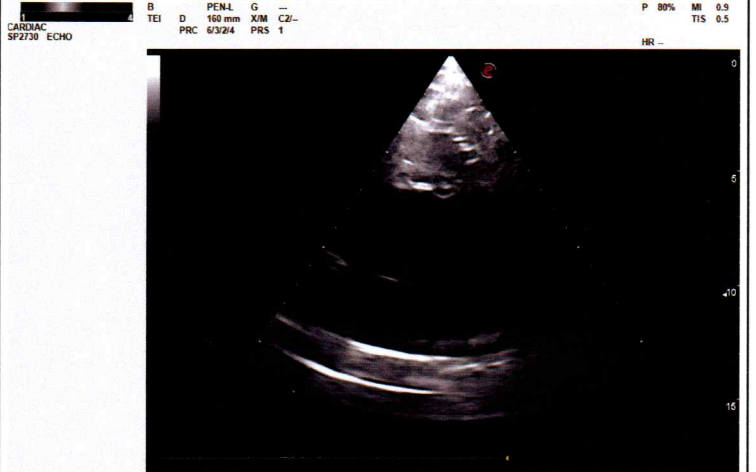SHASHANK BARNWAL 31Y/M 25 02 2023 10:07:58 AM



SHASHANK BARNWAL 31Y/M 25 02 2023 10:07:58 AM



SHASHANK BARNWAL 31Y/M 25 02 2023 10:07:58 AM





Call Now - 1800-123-3070

# PANACEA HOSPITAL

*A shelter for many hearts A Home for many lives*

(An ISO 9001:2008 Certified Organisation)

Lab Attached with CMC Vellore Under EQAS Scheme

Name	MR.SHASHANK BARNWAL	Sex /Age	31/M	Date	25/02/2023
Ref. by	Dr.Pallavi Mishra(MD)	BSA - m <sup>2</sup>		Echo window	fair

## Echo - Cardiography

MITRAL VALVE Doppler	AML - normal morphology MV Flow - E - 0.9 A-0.5 E/A=1.84		PML - normal morphology MVA - 3.0 cm <sup>2</sup> Mitral Regurgitation - <b>No</b>
TRICUSPID VALVE Doppler	Normal TV Flow - <b>No</b>		Tricuspid Regurgitation - <b>No</b>
PULMONARY VALVE Doppler	Normal PV Flow - <b>No</b>		Pulmonary Regurgitation - <b>No</b>
AORTIC VALVE Doppler	Trileaflet-No AV Flow - no		Aortic Regurgitation - <b>no</b>
MEASUREMENT	Aorta - 27.4 IVS ed - 13.7 LVID ed - 44.0 LVPW ed - 12.0 OA - 7	(20-38) mm (6 -12) mm (35 - 55) mm (6 -12) mm (> 5) mm	LA - 33.1 IVS es -13.1 LVID es - 32.6 LVPW es - 12.0 EPSS - 8 (24-32) mm (6 - 12) mm (24 - 40) mm (6 -12) mm (< 9) mm

**CONCLUSION**

All cardiac chamber dimensions are WNL  
No valvular abnormalities  
Good LV systolic function present Modified Simpson's method (4C, 2C) (LVEF-51%)  
No diastolic dysfunction present (E/A = 1.84) by tissue Doppler (E/e'=6.2)  
No RWMA  
No pericardial effusion  
Intact IAS / IV  
No PAH  
No intra cardiac mass /thrombus /vegetation

**IMPRESSION**      **Normal Echocardiogram**

  
Mr. Mishra  
Physician Assistant  
(PIIRE)

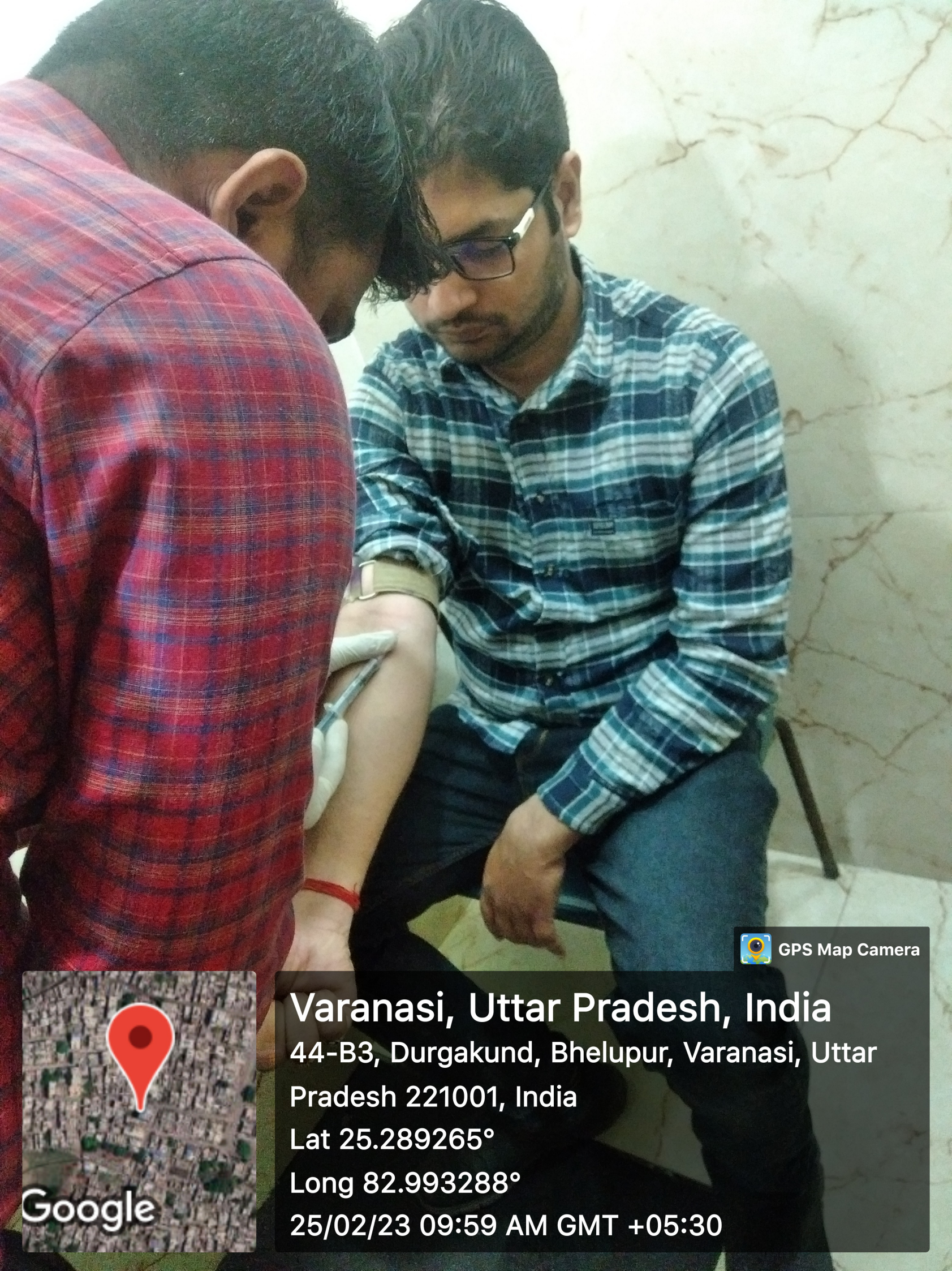  
Dr. Pallavi Mishra  
MBBS, MD (MED) Lucknow  
Echocardiography Specialist, MIAE  
Non-invasive cardiologist  
Women's Cardiologist  
Diabetocardiologist


**DR. PALLAVI MISHRA**  
**MBBS, MD (MED) (MIAE)**  
**25/02/2023**

Address : Kabir Nagar (Near Sanjay Shiksha Niketan), Durgakund, Varanasi

Mobile : 9554572190 / 9453837595 / Recpn. 9389994334

E-mail : dramishra@gmail.com, drpallaviojha@gmail.com, Website: www.piire.org



 GPS Map Camera



**Varanasi, Uttar Pradesh, India**

44-B3, Durgakund, Bhelupur, Varanasi, Uttar Pradesh 221001, India

Lat 25.289265°

Long 82.993288°

25/02/23 09:59 AM GMT +05:30

# Panacea Hospital

Diabetes Care Organisation

Many Hearts  
Home For Many Lives



ओ. पी. डी. पंजीकरण  
O.P.D. REGISTRATION

YOU



IPD BILL



GPS Map Camera



Varanasi, Uttar Pradesh, India

44-B3, Durgakund, Bhelupur, Varanasi, Uttar Pradesh 221001, India

Lat 25.289242°

Long 82.993327°

25/02/23 09:53 AM GMT +05:30



Call Now - 1800-123-3070

# PANACEA HOSPITAL

*A shelter for many hearts A Home for many lives*

(An ISO 9001:2008 Certified Organisation)

Lab Attached with CMC Vellore Under EQAS Scheme

**NAME:** MR.SHASHANK BARNWAL

**AGE/SEX:** 31 YRS / MALE

**REF BY:** DR. ASHUTOSH MISHRA (MD)

**DATE:** 25/02/2023

## ULTRA SOUND WHOLE ABDOMEN REPORT

**Liver:** Normal in shape and size (13.9 cm) and shows mildly increased echogenicity. Margins are smooth and regular. No focal lesion seen.

**Gall bladder:** Partially distended with normal wall thickness and echo-free lumen.

**CBD** Visualized part normal in course & caliber.

**Pancreas:** Normal in size, shape & echogenicity. Margins are smooth & regular. No diffuse/ focal lesion seen.

**Spleen:** Normal in size shape & echogenicity. Margins are smooth & regular. No diffuse / focal lesion seen. Splenic vessels at hilum is normal.

**Kidney:** Right kidney: 10.6 X 4.5cm Left kidney: 10.3 X 5.3 cm Normal cortical echogenicity with well maintained Cortical-medullary differentiation., Pelvicalyceal system normal. No calculus/mass lesion seen. No hydronephrosis/ hydroureter seen.

**Urinary bladder:** Normally distended, wall thickness is normal. No echogenic foci lumen or diverticula seen. Both VUJ appears normal. No E.R. calculus / mass lesion seen

**Prostate:** Normal in size, shape, & echogenicity. No calcification or focal cystic lesion seen. Capsular margins are smooth and regular. Seminal vesicles appear normal in size, shape & echogenicity. No diffuse /focal lesion seen.

**Others:** No free fluid in peritoneal cavity. No free fluid in bilateral pleural cavity.

### Impression:

❖ *Grade i fatty liver.*

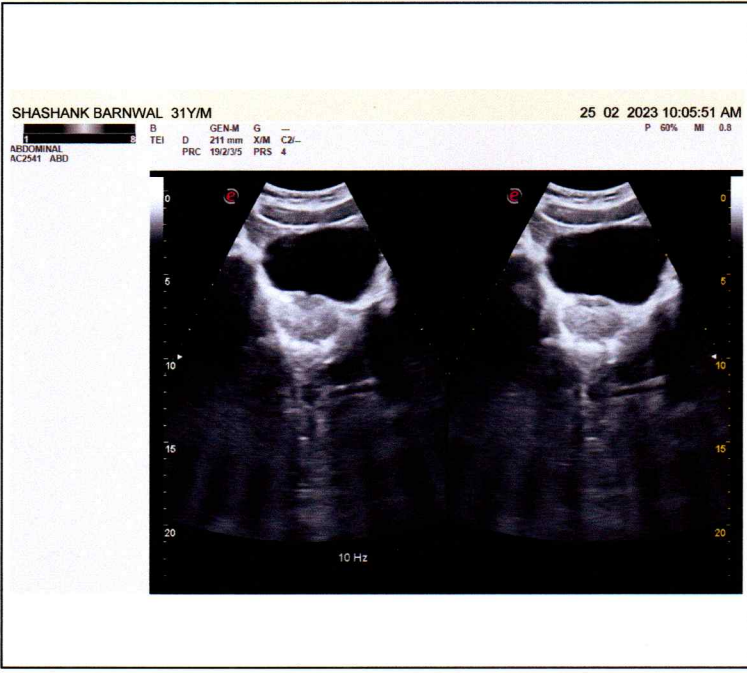
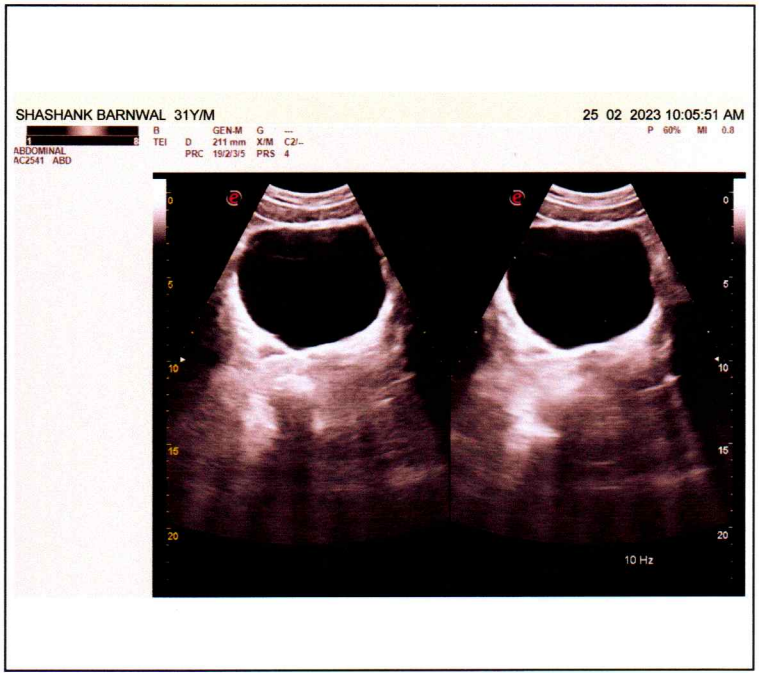
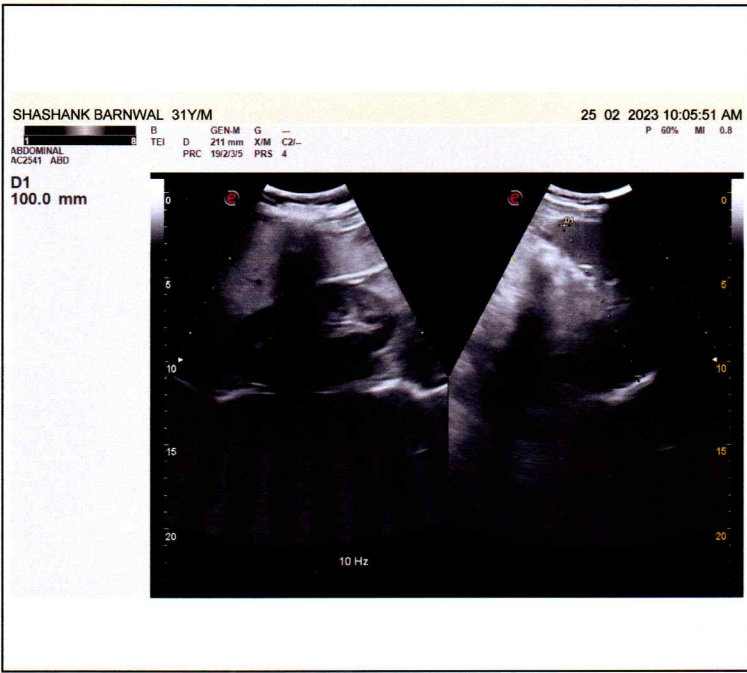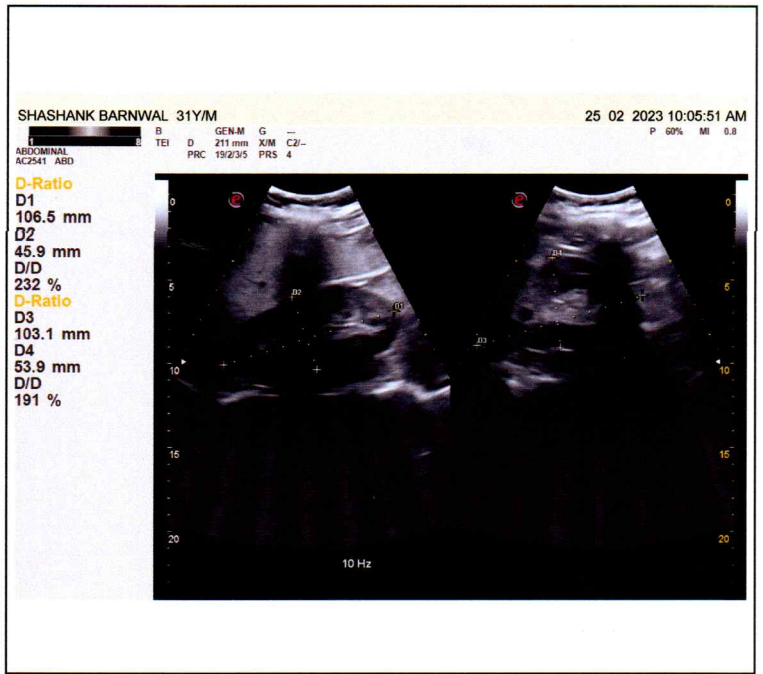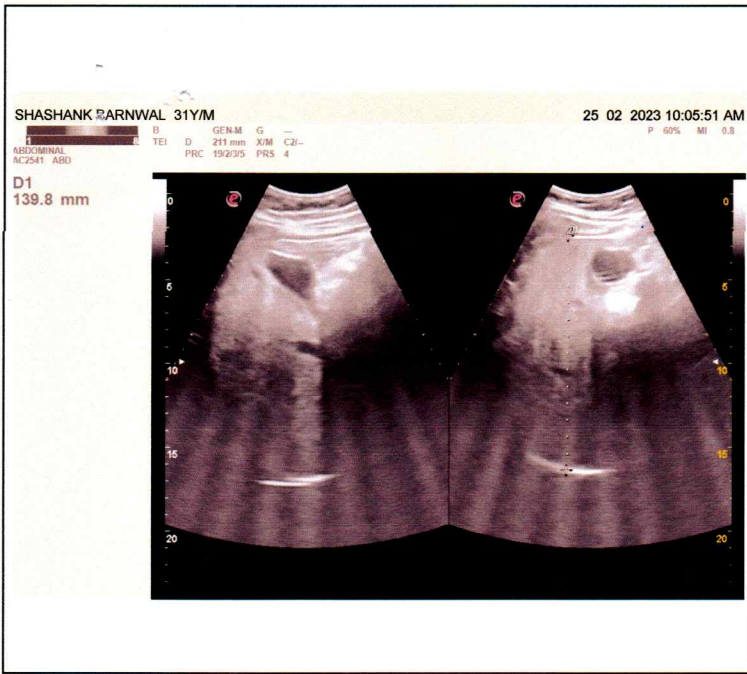
-----  
Please correlate clinically and further investigations.

*DR. R. K. TIWARI*  
REPORTED BY  
**DR. R. K. TIWARI**  
MD RADIODIAGNOSIS (GOLD MEDALIST)  
KGMU, LUCKNOW  
Reg.No. 57557

**Address :** Kabir Nagar (Near Sanjay Shiksha Niketan), Durgakund, Varanasi

**Mobile :** 9554572190 / 9453837595 / Recpn. 9389994334

**E-mail :** dramishra@gmail.com, drpallaviojha@gmail.com, Website: www.paire.org





Call Now - 1800-123-3070

# PANACEA HOSPITAL

*A shelter for many hearts A Home for many lives*

(An ISO 9001:2008 Certified Organisation)

Lab Attached with CMC Vellore Under EQAS Scheme

**NAME:MR.SHASHANK BARNWAL**

**AGE/SEX: 31 YRS / MALE**

**REFBY:DR.ASHUTOSH MISHRA(MD)**

**DATE:25/02/2023**

## X-RAY CHEST PA

### BOTH LUNG FIELDS AND PLEURAE:

Both lungs show normal bronchovascular pattern.

Right & left hila are normal

No focal mass or calcification is seen

There is no evidence of any fluid in the both the pleural cavities.

Both domes of diaphragms are normal in position.

### MEDIASTINUM:

Trachea is central in position.

Cardiac silhouette is of normal size and configuration.

No evidence of pericardial effusion.

No significant lymphadenopathy is seen.

Visualized skeleton is normal.

-----  
NO SIGNIFICANT RADIOGRAPHIC ABNORMALITY.

*DR. Rahul Kumar Tiwari*  
**REPORTED BY**

**DR. Rahul Kumar Tiwari**

MBBS, MD (Radio Diagnosis)

Reg.No. 57557

**Address : Kabir Nagar (Near Sanjay Shiksha Niketan), Durgakund, Varanasi**

**Mobile : 9554572190 / 9453837595 / Recpn. 9389994334**

**E-mail : dramishra@gmail.com, drpallaviojha@gmail.com, Website: www.piire.org**



R  
PA

SHASHANK BARANWAL 31Y/M 3767 O CHEST P.A. 25-Feb-23 10:15 AM

PANACEA HOSPITAL, KABIR NAGAR, DURGAKUND, VARANASI