

Sudip Biswas

भारत सरकार
Government of India



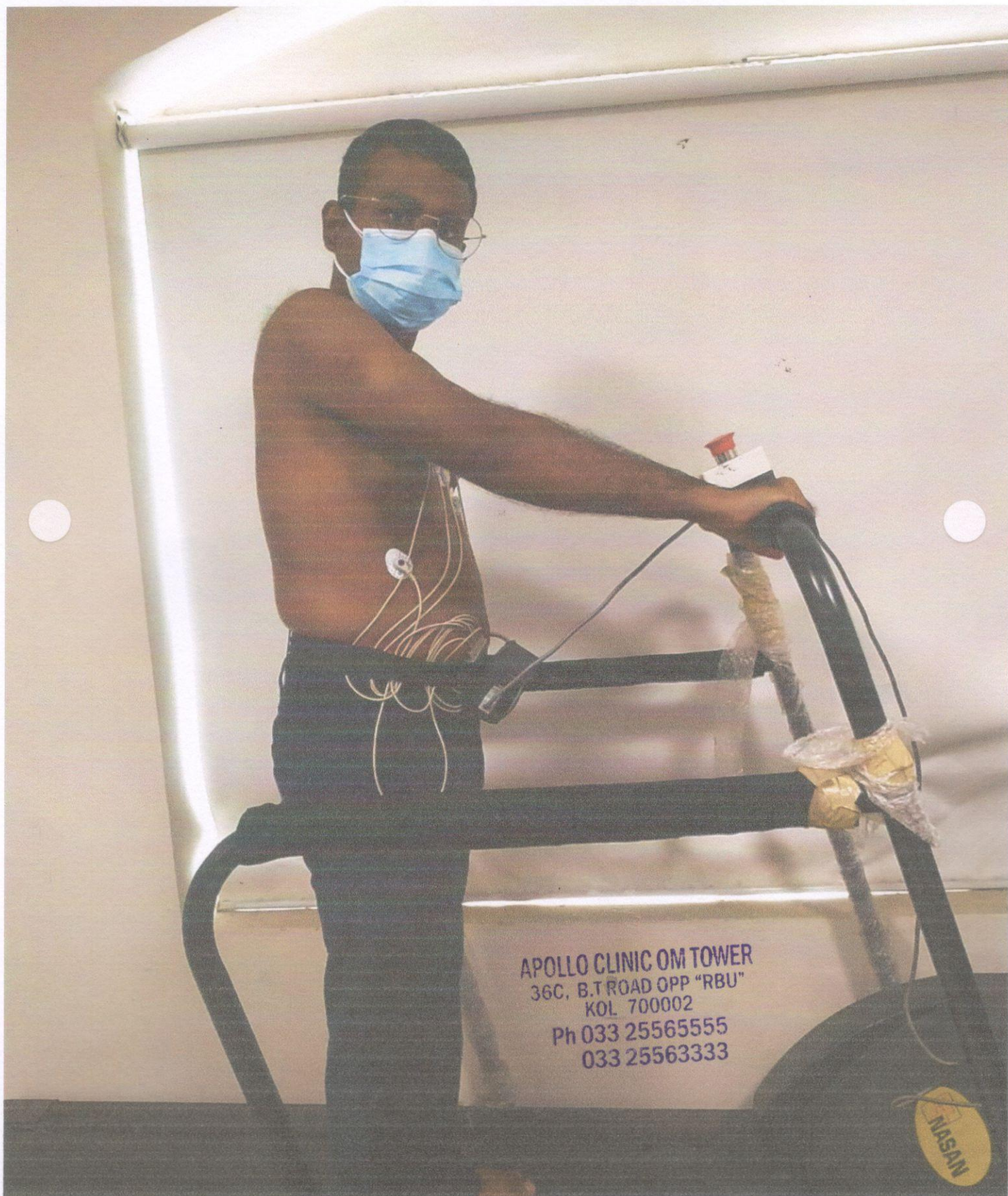
Sudip Biswas
DOB: 12/12/1989
Male
6594 5353 4447

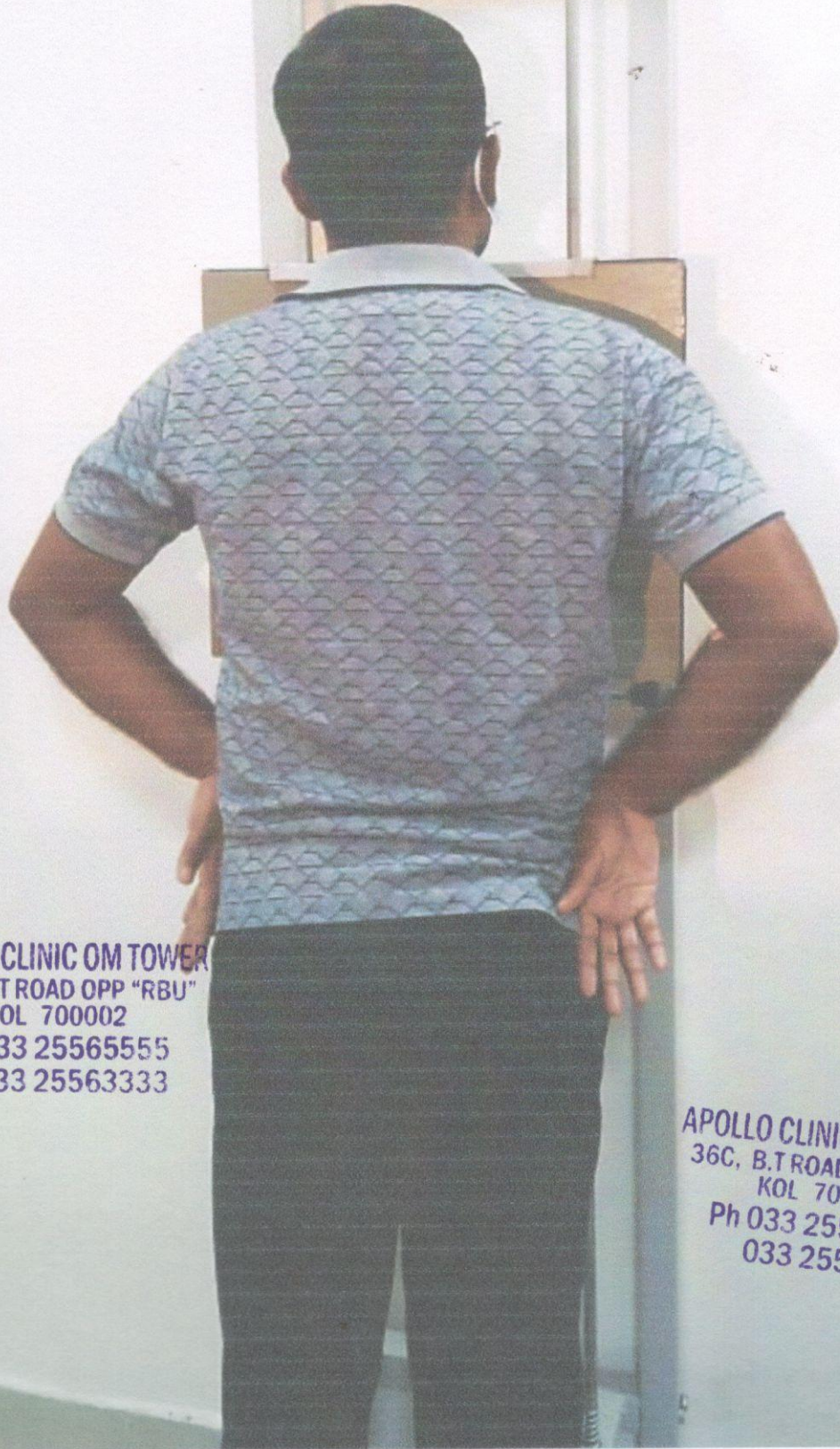

मेरा आधार, मेरी पहचान

APOLLO CLINIC OM TOWER
36C, B.T ROAD OPP "RBU"
KOL 700002
Ph 033 25565555
033 25563333

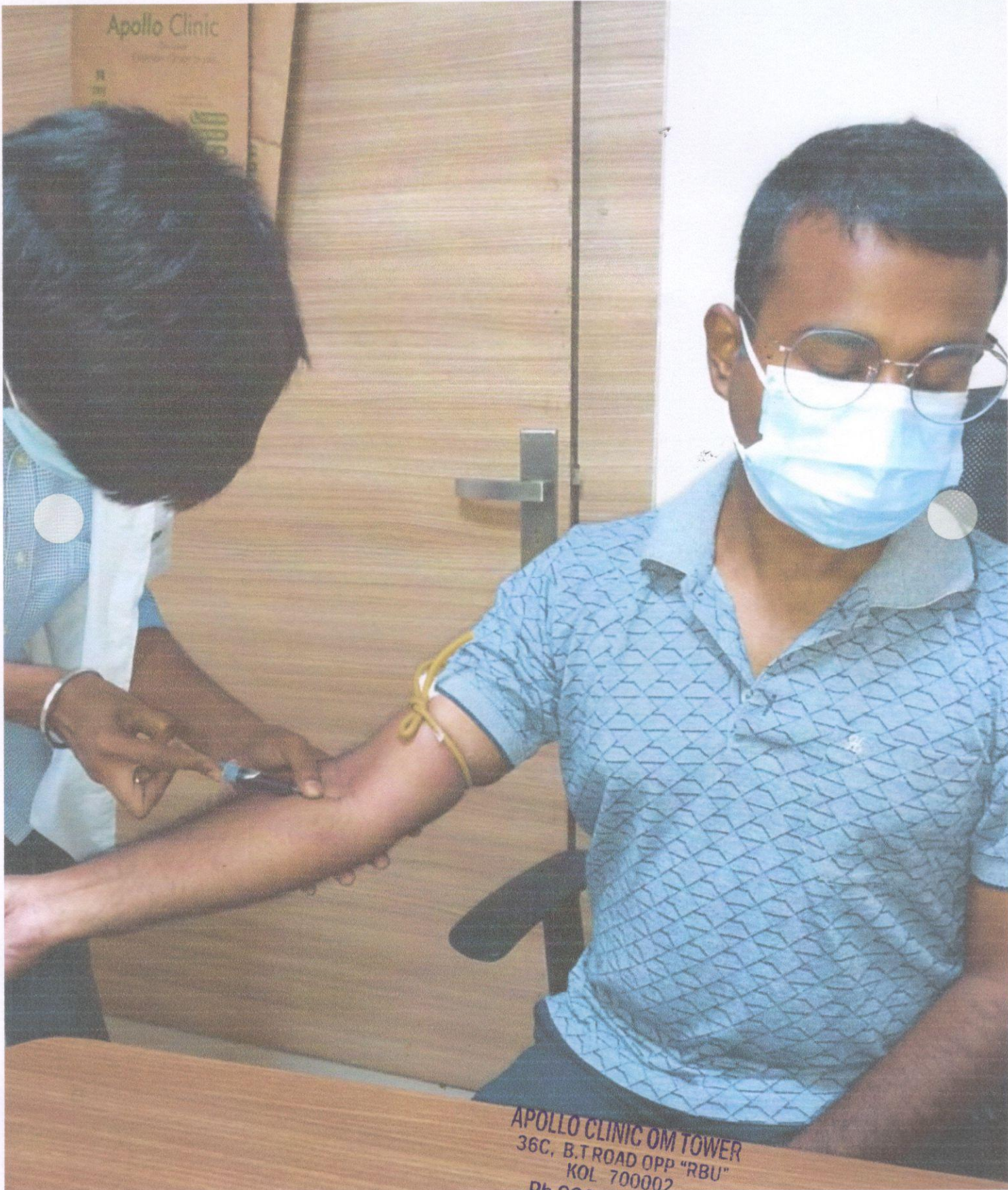
E.C.G. TMT





APOLLO CLINIC OM TOWER
36C, B.T ROAD OPP "RBU"
KOL 700002
Ph 033 25565555
033 25563333

APOLLO CLINIC OM TOWER
36C, B.T ROAD OPP "RBU"
KOL 700002
Ph 033 25565555
033 25563333



APOLLO CLINIC OM TOWER
36C, B.T.ROAD OPP "RBU"
KOL 700002
Ph 033 25565555
033 25563333

NAME:MR.SUDIP BISWAS	AGE:30YRS	SEX:MALE
REF BY:DR. CORPORATE (SELF)	MR NO:FSIN-0000	DATE:21.07.2021

ULTRASOUND OF WHOLE ABDOMEN

LIVER: Liver is **Enlarged Moderate fatty changes** seen. The intrahepatic tubular structures are normal.no focal area of altered echogenicity is noted. The porta hepatis is normal. The common bile duct at porta measures **0.34cm** . The portal vein measures **0.84cm** at porta.

GALL BLADDER: Gall bladder is distended .Wall is normal limits. No calculus or mass is seen within the gall bladder

PANCREAS: It is normal in size, Shape, Outline and echotexture. Pancreatic duct is not dilated.

SPLEEN: It is normal in size **9.22cm**, Shape, Outline and echotexture. No parenchymal lesion is noted.

RIGHT KIDNEY: kidneys are normal in position, size, shape, outline and echotexture.The cortico medullary differentiation is maintained. No calculus or hydronephrosis is seen.

RIGHT KIDNEY: measures – **9.22cm**.

LEFT KIDNEY: kidneys are normal in position, size, shape, outline and echotexture. The cortico medullary differentiation is maintained. No calculus or hydronephrosis is seen.


LEFT KIDNEY: measures – **10.29cm**.

URINARY BLADDER: : It is well distended with normal wall thickness. No calculus or mass is seen within the urinary bladder.

PROSTATE: It is normal in size, Shape & homogenous echotexture. The prostatic outline is smooth. The periprostatic plane is normal. It is normal size measures **2.89cmX3.47cmX3.40cm**
Vol= **17.86 ml**.

IMPRESSION:

- **HPATOMEGALY WITH MODERATE FATTY CHANGES.**


DR.SUSMITA CHOWDHURY
MBBS,MD.
CONSULTANT SONOLOGIST

APOLLO CLINIC @ OM TOWER
Opp. of Rabindra Bharati University
Licensee : Satyam Credit Pvt. Ltd.

36C, B.T. Road, Kolkata - 700 002

E-mail : sinthimor@theapolloclinic.com
satyamcreditpvtltd@gmail.com



033 2556 3333



033 2556 5555



+91 98521 66666



+91 74392 97827

DEPARTMENT OF RADIOLOGY X-RAY OF CHEST (PA) VIEW

MR. NO- FSIN.0000000

SEX-MALE

NAME: - Mr. SUDIP BISWAS

EXAMINATION DATE- 21/07/2021


AGE- 30YRS

REPORT DATE-21/07/2021

REF DR. SELF

FINDINGS:

- Bilateral accentuated pulmonary vascular marking noted.
- Tracheal shadow is in the midline.
- Bilateral CP angle are clear.
- Both hilum appear normal.
- CTR appears normal.



DR.ARNAB MANDAL

MD, Physician, PGDUS (Delhi) CEPT-USG (WBUHS KOLKATA)
Fellow of Jefferson Ultrasound Radiology and Education Institute
Philadelphia Ex-Radiology Resident (S.E.Railway)
Regd.No:72022(WBMC)

APOLLO CLINIC @ OM TOWER
Opp. of Rabindra Bharati University
Licensee : Satyam Credit Pvt. Ltd.
36C, B. T. Road, Kolkata - 700 002
E-mail : sinthimor@theapolloclinic.com
satyamcreditpvtltd@gmail.com



033 2556 3333



033 2556 5555



+91 98521 66666

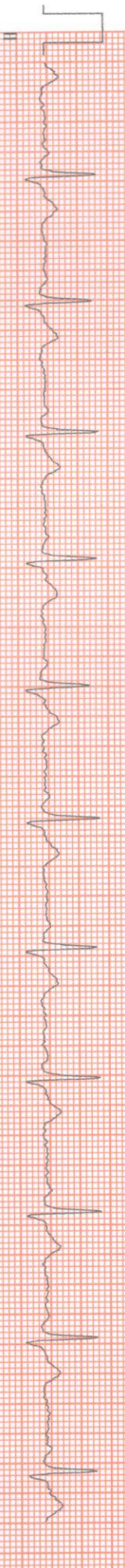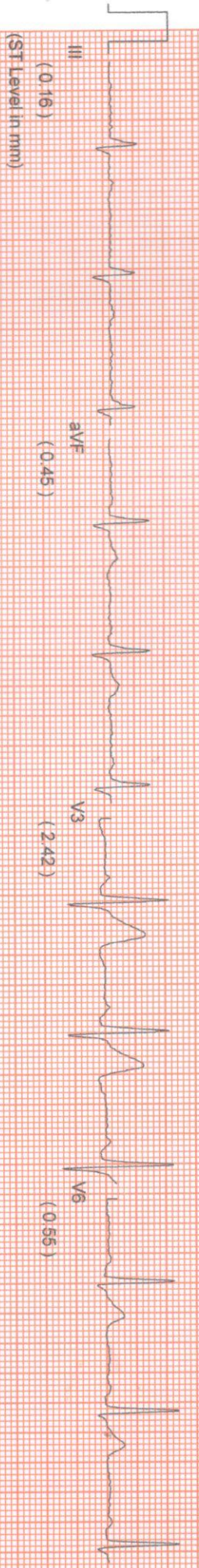
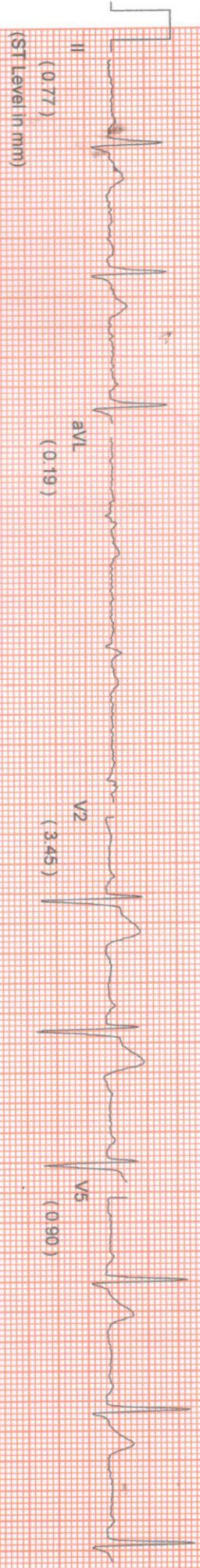

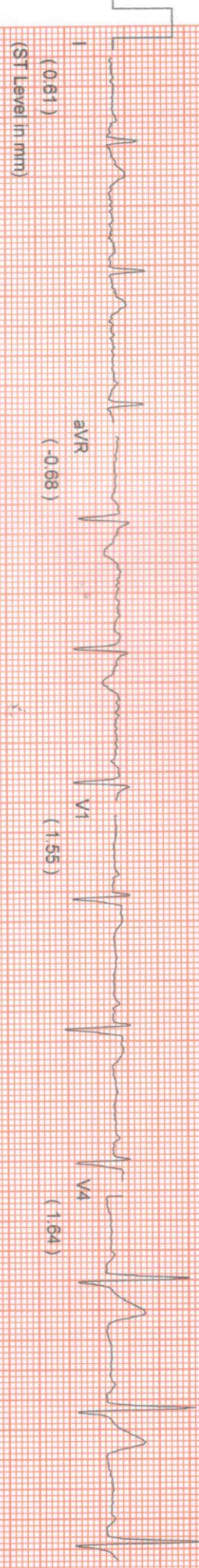
+91 74392 97827

Patient Name: Mr. SUDIP BISWAS 30/M

Resting ECG Report

July 21, 2021
Time: 13:32:47
QT / QTc : 0.420 / 0.440 Sec
P-QRS-T Axis (21)-(57)-(22) deg
PR Interval: 0.15 sec
RR Interval: 0.91 sec
HR : 66 bpm
BP : 120/80 mmHg
P-QRS-T Axis (21)-(57)-(22) deg
QRS Duration : 0.072 Sec



Comments :-

Dr. S. Biswas

NAME:MR. SUDIP BISWAS		MR NO: FSIN-0000	DATE : 21.07.2021
AGE: 30YRS.	SEX:MALE	REF BY: CORPORATE	

ECG REPORT

HR : 66 b/min
AXIS : NORMAL
RHYTHM : SINUS
PR INTERVAL : 0.15 sec
QT INTERVAL : 0.440 sec
QRS DURATION : 0.072 sec
T-WAVE : NORMAL

IMPRESSION:

- RESTING ECG IS WITHIN NORMAL LIMITS.



Dr. SIDDHARTHA KUNDU

MBBS (Cal), PGDCC, CCEBDM

Clinical Cardiologist

Ex Sr Resident, Cardiology Dept

B.R Singh Hospital, Eastern Railway

APOLLO CLINIC @ OM TOWER
Opp. of Rabindra Bharati University
Licensee : **Satyam Credit Pvt. Ltd.**

36C, B. T. Road, Kolkata - 700 002

E-mail : sinthimor@theapolloclinic.com
satyamcreditpvtltd@gmail.com



033 2556 3333



033 2556 5555



+91 98521 66666



+91 74392 97827