



DEPARTMENT OF PATHOLOGY

Patient Name : Mr. PAWAN KUMAR
MR No : 28166
Age/Sex : 38 Years 9 Months 14 Days / Male
Type : OPD
TPA/Corporate : MEDIWHEEL
Bill Date : 14/10/2023
Reporting Date : 14/10/2023
Sample ID : 43610
Bill/Req. No. : 23058504
Ref Doctor : Dr. CONSULTANT

Test	Result	Bio. Ref. Interval	Units
CBC			
HAEMOGLOBIN	15.9	12 - 16	g/dl
PACKED CELL VOLUME	49.1	35.0 - 50.0	%
RED BLOOD CELL COUNT	5.00	3.5 - 5.5	millions/ μ L
MEAN CORPUSCULAR VOLUME	98.3	83 - 101	fL
MEAN CORPUSCULAR HAEMOGLOBIN	31.8 H	27 - 31	pg
MEAN CORPUSCULAR HB CONC	32.4 L	33 - 37	g/dl
RDW	12.4	11.6 - 14.5	%
TOTAL LEUCOCYTE COUNT	7500	4000-11000	/ μ L
DIFFERENTIAL COUNT			
NEUTROPHILS	48	40.0 - 80.0	%
LYMPHOCYTES	42 H	20 - 40	%
MONOCYTES	09	2.0 - 10.0	%
EOSINOPHILS	01	0.0 - 5.0	%
BASOPHILS	00	0.0 - 2.0	%
PLATELET COUNT	2.39	1.50 - 4.50	lac/cumm

***** END OF THE REPORT *****



Sample no.

Dr. VAISHALI YADAV Dr. REETU JADHAV Dr. PARDIP KUMAR S.C. GAUR
 CONS. PATHOLOGIST CONS. PATHOLOGIST MICROBIOLOGIST & ICO LAB INCHARGE USER NAME DEEPCHAND

(This is only professional opinion and not the diagnosis, Please correlate clinically)

J-Block, Sector-10, Near Court, Faridabad - 121004, Haryana

Tel.: 0129-4200000 E-mail: parkfaridabad@gmail.com

PARK GROUP OF HOSPITALS : West Delhi • South Delhi • Gurgaon • Karnal • Panipat • Hodal • Ambala • Behror



DEPARTMENT OF PATHOLOGY

Patient Name : Mr. PAWAN KUMAR

MR No : 28166

Age/Sex : 38 Years 9 Months 14 Days / Male

Type : OPD

TPA/Corporate : MEDIWHEEL

Bill Date : 14/10/2023

Reporting Date : 14/10/2023

Sample ID : 43610

Bill/Req. No. : 23058504

Ref Doctor : Dr. CONSULTANT

Test	Result	Bio. Ref. Interval	Units
------	--------	--------------------	-------

BLOOD GROUPING AND RH FACTOR

BLOOD GROUP	" B " RH POSITIVE		
-------------	-------------------	--	--

***** END OF THE REPORT *****



Sample no.

Dr. VAISHALI YADAV
CONS.PATHOLOGIST

Dr.REETU JADHAV
CONS.PATHOLOGIST

Dr. PARDIP KUMAR
MICROBIOLOGIST & ICO

S.C.GAUR

LAB INCHARGE

USER NM

DEEPCHAND

(This is only professional opinion and not the diagnosis, Please correlate clinically)

J-Block, Sector-10, Near Court, Faridabad - 121004, Haryana

Tel.: 0129-4200000 E-mail : parkfaridabad@gmail.com

PARK GROUP OF HOSPITALS : West Delhi • South Delhi • Gurgaon • Karnal • Panipat • Hodal • Ambala • Behror



DEPARTMENT OF PATHOLOGY

Patient Name : Mr. PAWAN KUMAR
MR No : 28166
Age/Sex : 38 Years 9 Months 14 Days / Male
Type : OPD
TPA/Corporate : MEDIWHEEL

Bill Date : 14/10/2023
Reporting Date : 14/10/2023
Sample ID : 43610
Bill/Req. No. : 23058504
Ref Doctor : Dr. CONSULTANT

Test	Result	Bio. Ref. Interval	Units
BLOOD SUGAR FASTING			
PLASMA GLUCOSE FASTING	87.5	60 - 110	mg/dl

***** END OF THE REPORT *****



Sample no.

Dr. VAISHALI YADAV Dr. REETU JADHAV Dr. PARDIP KUMAR S.C. GAUR
CONS.PATHOLOGIST CONS.PATHOLOGIST MICROBIOLOGIST & ICO LAB INCHARGE USER NM DEEPCHAND

(This is only professional opinion and not the diagnosis, Please correlate clinically)

J-Block, Sector-10, Near Court, Faridabad - 121004, Haryana

Tel.: 0129-4200000 E-mail : parkfaridabad@gmail.com

DEPARTMENT OF PATHOLOGY

Patient Name : Mr. PAWAN KUMAR
MR No : 28166
Age/Sex : 38 Years 9 Months 14 Days / Male
Type : OPD
TPA/Corporate : MEDIWHEEL

Bill Date : 14/10/2023
Reporting Date : 14/10/2023
Sample ID : 43610
Bill/Req. No. : 23058504
Ref Doctor : Dr. CONSULTANT

Test	Result	Bio. Ref. Interval	Units
BLOOD SUGAR 2 HR. PP			
BLOOD SUGAR P.P.	90.0	80 - 150	mg/dl

***** END OF THE REPORT *****



Sample no.

Dr. VAISHALI YADAV
CONS.PATHOLOGIST

Dr. REETU JADHAV
CONS.PATHOLOGIST

Dr. PARDIP KUMAR
MICROBIOLOGIST & ICO

S.C. GAUR
LAB INCHARGE

USER NM DEEPCHAND

(This is only professional opinion and not the diagnosis, Please correlate clinically)

J-Block, Sector-10, Near Court, Faridabad - 121004, Haryana
Tel.: 0129-4200000 E-mail : parkfaridabad@gmail.com

PARK GROUP OF HOSPITALS : West Delhi • South Delhi • Gurgaon • Karnal • Panipat • Hodal • Ambala • Behror

the health care providers

the health care providers



DEPARTMENT OF PATHOLOGY

Patient Name : Mr. PAWAN KUMAR
MR No : 28166
Age/Sex : 38 Years 9 Months 14 Days / Male
Type : OPD
TPA/Corporate : MEDIWHEEL
Bill Date : 14/10/2023
Reporting Date : 14/10/2023
Sample ID : 43610
Bill/Req. No. : 23058504
Ref Doctor : Dr CONSULTANT

Test	Result	Bio. Ref. Interval	Units
KFT (RENAL PROFILE)			
KFT			
SERUM UREA	19.1	10 - 45	mg/dL
SERUM CREATININE	1.1	0.4 - 1.4	mg/dL
SERUM URIC ACID	5.8	2.5 - 7.0	mg/dL
SERUM SODIUM	137.1	136 - 148	mmol/L
SERUM POTASSIUM	4.4	3.5 - 5.5	mmol/L
CHLORIDE	103.0	96 - 106	mmol/L

***** END OF THE REPORT *****



Sample no.

Dr. VAISHALI YADAV Dr. REETU JADHAV Dr. PARDIP KUMAR S.C. GAUR
 CONS. PATHOLOGIST CONS. PATHOLOGIST MICROBIOLOGIST & ICO LAB INCHARGE USER NAME DEEPCHAND

(This is only professional opinion and not the diagnosis, Please correlate clinically)

J-Block, Sector-10, Near Court, Faridabad - 121004, Haryana
 Tel.: 0129-4200000 E-mail : parkfaridabad@gmail.com

PARK GROUP OF HOSPITALS : West Delhi • South Delhi • Gurgaon • Karnal • Panipat • Hodal • Ambala • Behror



DEPARTMENT OF PATHOLOGY

Patient Name : Mr. PAWAN KUMAR
 MR No : 28166
 Age/Sex : 38 Years 9 Months 14 Days / Male
 Type : OPD
 TPA/Corporate : MEDIWHEEL

Bill Date : 14/10/2023
 Reporting Date : 14/10/2023
 Sample ID : 43610
 Bill/Req. No. : 23058504
 Ref Doctor : Dr.CONSULTANT

Test	Result	Bio. Ref. Interval	Units
LFT (LIVER FUNCTION TEST)			
LFT		0 - 1.2	mg/dL
TOTAL BILIRUBIN	0.9	0 - 0.4	mg/dL
DIRECT BILIRUBIN	0.3	0.10 - 0.6	mg/dL
INDIRECT BILIRUBIN	0.6	0 - 45	U/L
SGOT (AST)	25.9	0 - 45	U/L
SGPT (ALT)	33.0	30 - 170	IU/L
ALKALINE PHOSPHATASE	97.5	6.4 - 8.0	g/dL
TOTAL PROTEIN	7.3	3.3 - 5.5	g/dL
ALBUMIN	4.4	2.3 - 4.5	g/dL
GLOBULIN	2.9	1.1 - 2.2	
A/G RATIO	1.52		

***** END OF THE REPORT *****



Sample no.

Dr. VAISHALI YADAV
 CONS.PATHOLOGIST

Dr.REETU JADHAV
 CONS.PATHOLOGIST

Dr. PARDIP KUMAR
 MICROBIOLOGIST & ICO

S.C GAUR

LAB INCHARGE USEKUM DLEPHAN

(This is only professional opinion and not the diagnosis, Please correlate clinically)

J-Block, Sector-10, Near Court, Faridabad - 121004, Haryana

Tel.: 0129-4200000 E-mail : parkfaridabad@gmail.com

PARK GROUP OF HOSPITALS : West Delhi • South Delhi • Gurgaon • Karnal • Panipat • Hodal • Ambala • Behror



DEPARTMENT OF PATHOLOGY

Patient Name : Mr. PAWAN KUMAR
 Patient No : 28166
 Age/Sex : 38 Years 9 Months 14 Days / Male
 Type : OPD
 TPA/Corporate : MEDIWHEEL

Bill Date : 14/10/2023
 Reporting Date : 14/10/2023
 Sample ID : 43610
 Bill/Req. No. : 23058504
 Ref Doctor : Dr. CONSULTANT

Test	Result	Bio. Ref. Interval	Units
------	--------	--------------------	-------

LIPID PROFILE

LIPID PROFILE

Test	Result	Ref. Interval	Units
TOTAL CHOLESTEROL	233.44 H	120.0 - 200.0	mg/dL
SERUM TRIGLYCERIDES	248.31 H	40.0 - 160.0	mg/dl
HDL-CHOLESTEROL	54.17	30 - 70	mg/dl
VLDL CHOLESTEROL	49.66 H	6 - 32	mg/dL
LDL	129.61	50 - 135	mg/dL
LDL CHOLESTEROL/HDL RATIO	2.39	1.0 - 3.0	mg/dl
TOTAL CHOLESTEROL/HDL RATIO	4.31	2.0 - 5.0	mg/dl

***** END OF THE REPORT *****



Sample no.

Dr. VAISHALI YADAV
CONS.PATHOLOGIST

Dr. REETU JADHAV
CONS.PATHOLOGIST

Dr. PARDIP KUMAR
MICROBIOLOGIST & ICO

S.C. GAUR

LAB INCHARGE

USER NM

DEEPCHAND

(This is only professional opinion and not the diagnosis. Please correlate clinically)

J-Block, Sector-10, Near Court, Faridabad - 121004, Haryana
 Tel.: 0129-4200000 E-mail : parkfaridabad@gmail.com

PARK GROUP OF HOSPITALS : West Delhi • South Delhi • Gurgaon • Karnal • Panipat • Hodal • Ambala • Behror

the health care providers

the health care providers

DEPARTMENT OF PATHOLOGY

Patient Name : Mr. PAWAN KUMAR
 MR No : 28166
 Age/Sex : 38 Years 9 Months 14 Days / Male
 Type : OPD
 TPA/Corporate : MEDIWHEEL

Bill Date : 14/10/2023
 Reporting Date : 14/10/2023
 Sample ID : 43610
 Bill/Req. No. : 23058504
 Ref Doctor : Dr. CONSULTANT

Test	Result	Bio. Ref. Interval	Units
URINE ROUTINE AND MICROSCOPY			
PHYSICAL CHARACTERSTICS			
QUANTITY	40.0 ML	5 - 100	ML
COLOUR	Pale Yellow		
TURBIDITY	CLEAR	clear	
SPECIFIC GRAVITY	1.010	1.003 - 1.030	
PH	5.0	Acidic	
CHEMICAL EXAMINATION-1			
URINE PROTEIN	NIL	NIL	
GLUCOSE	NIL	NIL	
MICRO.EXAMINATION			
PUS CELL	1 - 2/HPF		CELLS/HPF
RED BLOOD CELLS	NIL	0-2	CELLS/HPF
EPITHELIAL CELLS	1-2/HPF	0-5	CELLS/HPF
CASTS	NIL	NIL	CELLS/HPF
CRYSTALS	NIL	NIL	CELLS/HPF
OTHER	NIL		

***** END OF THE REPORT *****



Sample no.

Dr. VAISHALI YADAV
 CONS.PATHOLOGIST

Dr. REETU JADHAV
 CONS.PATHOLOGIST

Dr. PARDIP KUMAR
 MICROBIOLOGIST & ICO

S.C.GAUR

LAB INCHARGE

USER NM

SAMAY

(This is only professional opinion and not the diagnosis, Please correlate clinically)

J-Block, Sector-10, Near Court, Faridabad - 121004, Haryana
 Tel.: 0129-4200000 E-mail : parkfaridabad@gmail.com

DEPARTMENT OF PATHOLOGY

Patient Name : Mr. PAWAN KUMAR
MR No : 28166
Age/Sex : 38 Years 9 Months 14 Days / Male
Type : OPD
TPA/Corporate : MEDIWHEEL

Bill Date : 14/10/2023
Reporting Date : 14/10/2023
Sample ID : 43610
Bill/Req. No. : 23058504
Ref Doctor : Dr.CONSULTANT

Test	Result	Bio. Ref. Interval	Units
------	--------	--------------------	-------

STOOL ROUTINE AND MICROSCOPY

STOOL ROUTINE AND MICROSCOPY

COLOUR	BROWNISH		
CONSISTENCY	Semi Solid	Formed	
PH	ALKALINE	>= 5.5	
RBCS	NIL	NIL	
CYSTS	NIL	NIL	
OVA	NIL	Nil	
PUS CELLS	1-2/hpf	NIL	
MUCUS	NIL	NIL	

***** END OF THE REPORT *****



Sample no.

Dr. VAISHALI YADAV Dr.REETU JADHAV Dr. PARDIP KUMAR S.C.GAUR
CONS.PATHOLOGIST CONS.PATHOLOGIST MICROBIOLOGIST & ICO LAB INCHARGE USER NM SAKSHI

(This is only professional opinion and not the diagnosis, Please correlate clinically)

J-Block, Sector-10, Near Court, Faridabad - 121004, Haryana
Tel.: 0129-4200000 E-mail : parkfaridabad@gmail.com



DEPARTMENT OF PATHOLOGY

Patient Name : Mr. PAWAN KUMAR
 MR No : 28166 Bill Date : 14/10/2023
 Age/Sex : 38 Years 9 Months 14 Days / Male Reporting Date : 16/10/2023
 Type : OPD Sample ID : 43610
 TPA/Corporate : MEDIWHEEL Bill/Req. No. : 23058504
 Ref Doctor : Dr.CONULTANT

Test	Result	Bio. Ref. Interval	Units
PSA - TOTAL (PROSTATIC SPECIFIC ANTIGEN) - CANCER MARKER			
PROSTATE SPECIFIC ANTIGEN(PSA)	0.76	0.0 - 4.0	ng/ml
Method : chemiluminescent immunoassay			

Note : Clinical Use: -

An aid in the early detection of Prostate cancer in Male, Follow up and amazement of Prostate cancer patients. Detect metastatic or persistent disease in patients following surgical or medical treatment of Prostate cancer

Note: -

False negative / positive results are observed in patients receiving mouse monoclonal antibodies for diagnosis or therapy. PSA levels may appear consistently elevated / depressed due to the interference by heterophilic antibodies & non-specific protein binding. PSA values regardless of levels should not be interpreted as absolute evidence of the presence or absence of disease. All values should be correlated with clinical findings and results of other investigations.

***** END OF THE REPORT *****



Sample no.

Dr. VAISHALI YADAV Dr. REETU JADHAV Dr. PARDIP KUMAR S.C. GAUR
 CONS. PATHOLOGIST CONS. PATHOLOGIST MICROBIOLOGIST & ICO LAB INCHARGE USER NM SUNIL

(This is only professional opinion and not the diagnosis, Please correlate clinically)

J-Block, Sector-10, Near Court, Faridabad - 121004, Haryana

Tel.: 0129-4200000 E-mail : parkfaridabad@gmail.com



DEPARTMENT OF PATHOLOGY

Patient Name : Mr. PAWAN KUMAR

MR No : 28166

Age/Sex : 38 Years 9 Months 14 Days / Male

Type : OPD

TPA/Corporate : MEDIWHEEL

Bill Date : 14/10/2023

Reporting Date : 16/10/2023

Sample ID : 43610

Bill/Req. No. : 23058504

Ref Doctor : Dr. CONSULTANT

Test	Result	Bio. Ref. Interval	Units
THYROID PROFILE			
TRI-IODOTHYRONINE (T3)	1.41	0.60 - 1.81	ng/ml
THYROXINE (T4)	12.0	5.01 - 12.45	ug/dL
THYROID STIMULATING HORMONE	1.62	0.5-5.50	uIU/ml

***** END OF THE REPORT *****



Sample no.

Dr. VAISHALI YADAV Dr.REETU JADHAV Dr. PARDIP KUMAR S.C.GAUR
 CONS.PATHOLOGIST CONS.PATHOLOGIST MICROBIOLOGIST & ICO LAB INCHARGE USER NM SUNIL

(This is only professional opinion and not the diagnosis, Please correlate clinically)

J-Block, Sector-10, Near Court, Faridabad - 121004, Haryana

Tel.: 0129-4200000 E-mail : parkfaridabad@gmail.com

PARK GROUP OF HOSPITALS : West Delhi • South Delhi • Gurgaon • Karnal • Panipat • Hodal • Ambala • Behror

DEPARTMENT OF PATHOLOGY

Patient Name : Mr. PAWAN KUMAR

MR No : 28166

Age/Sex : 38 Years 9 Months 14 Days / Male

Type : OPD

TPA/Corporate : MEDIWHEEL

Bill Date : 14/10/2023

Reporting Date : 16/10/2023

Sample ID : 43610

Bill/Req. No. : 23058504

Ref Doctor : Dr. CONSULTANT

Test	Result	Bio. Ref. Interval	Units
------	--------	--------------------	-------

HB A1C GLYCOSYLATED HAEMOGLOBIN

HBA1C	5.5		%
-------	-----	--	---

Note : Non-Diabetics 4.0 - 6.0 %

In Diabetics

Good Control 6.1 - 6.8 %

Fair Control 6.9 - 7.6 %

Poor Control > 7.6 %

***** END OF THE REPORT *****



Sample no.

Dr. VAISHALI YADAV Dr. REETU JADHAV Dr. PARDIP KUMAR S.C. GAUR
 CONS. PATHOLOGIST CONS. PATHOLOGIST MICROBIOLOGIST & ICO LAB INCHARGE USER NM SUNIL

(This is only professional opinion and not the diagnosis, Please correlate clinically)

J-Block, Sector-10, Near Court, Faridabad - 121004, Haryana

Tel.: 0129-4200000 E-mail : parkfaridabad@gmail.com

PARK GROUP OF HOSPITALS : West Delhi • South Delhi • Gurgaon • Karnal • Panipat • Hodal • Ambala • Behror



DEPARTMENT OF RADIOLOGY

Patient Name	Mr PAWAN KUMAR	Billed Date	: 14/10/2023	8.37 AM
Reg No	28166	Reported Date	: 14/10/2023	
Age/Sex	38 Years 9 Months 14Days / Male	Req. No.	: 23058504	
Type	OPD	Consultant Doctor	: Dr. CONSULTANT	

X-RAY CHEST PA

Bilateral lungs appears normal.

Both hila are normal in size, have equal density and bear normal relationship.

The heart and trachea are central in position and no mediastinal abnormality is visible.

The cardiac size is normal for patient age and view.

The domes of the diaphragms are normal in position, and show smooth outline.

To be correlated clinically

DR BINOD KR CHAUDHARY
MBBS, MD
CONSULTANT RADIOLOGIST

(This is only professional opinion and not the diagnosis, Please correlate clinically)

J-Block, Sector-10, Near Court, Faridabad - 121004, Haryana
Tel.: 0129-4200000 E-mail : parkfaridabad@gmail.com

PARK GROUP OF HOSPITALS : West Delhi • South Delhi • Gurgaon • Karnal • Panipat • Hodal • Ambala • Behror



ECHO REPORT

Name of the patient: MR: Pawan Kumar Age: 38/ Sex: Male Female

UHID No: 28166 IPD No: # Date: 19/10/2023

Refer By Doctor: Dr. R. Arora

LVEF% 60%

2D ECHO

> Mitral Value Normal Pulmonary Value N Pulm
> Artery N
> Aortic avive N Tricuspid valve N

2D RWMA

> NO RWMA (Regional wall motion abnormality) at rest

COLD DOPPLER

> NO. Significant Vavular stenosis / Regurgiation

COMMENTS AND SUMMARY

> All cardiac chambers of N size and shape NO dilatation or hypertrophy.
> NO RWMA (Regional wall motion abnormality) at rest
> NO Cloth / Vegetation/ pericardial effusion
> LV 60% Systolic function
> NO Significant Vavular stenosis / Regurgiation

Final Impression

> EF at Rest 60%

COMMENTS

2DECHO & Color Doppler Study well

Consultant Cardiology

Doctor Name : Dr.

Date :

Dr. Rakesh Kumar Arora
MBBS, MD (CC) (Cardiology)
Registrar - Cardiology
Consultant - Cardiology
Park Hospital, Faridkot

Signature
Time



OPD PRESCRIPTION

MR.NO	: 28166	Date&Time	: 14/10/2023 10.21 AM
Name	: Mr. PAWAN KUMAR	Sex	: Male
Doctor Name	: Dr. POOJA BAINS	Age	: 38Years 9Months 14Days
Speciality	: DERMATOLOGIST	Mobile No	: 9911141571
Address	: H NO 571, SECTOR 21 D FARIDABAD NIT, Faridabad City, Faridabad, Haryana	Panel	: MEDIWHEEL FOC

Acute Urinary

do

- Tab Ebanit - M ① BD !
- Tab Encop AB 12 mg stat
- Calsoft 4 lotion YA 80g
- Moist syndet base
- Venuva urea lotion OD as adv

- CBC & ESR
- CAEC
- LFT
- RFT
- Urine CP
- Urinal microscopy
- Stool for occult blood & parasites
- T2/T4/TSH

X 15 days

[Signature]

J-Block, Sector-10, Near Court, Faridabad - 121004, Haryana Tel.: 0129-4200000 E-mail : parkfaridabad@gmail.com

PARK GROUP OF HOSPITALS : West Delhi • South Delhi • Gurugram • Karnal • Panipat • Hodal • Ambala • Behror

the **health** care providers

the **health** care providers

PANEL HOSPITAL : DELHI GOVT, CGHS, ECHS, MTNL, DJB, DTC NDPL MCD, NAFED, HUDCO, TRADE FAIR AUTHORITY OF INDIA, DDA, NDMC, PAWAN HANS HELICOPTER, IFFCO, METRO BHEL, MOTHER DAIRY, GAIL, VSNL, TCIL, IGL, TISCO, NPCC, NBCC, NTC, PEC, IREDA, IRCON, SCI, DU, SPG, MES, ESI, CERC, CCRT, UGC, DERC, IGNOU, JNU, DTL, CPCB, FCI, NPC, ICAR, IARI, BSNL, BSES, DELHI POLICE, ALL MAJOR TPA'S (MEDICLAIM CASHLESS HOSPITALISATION) ETC.

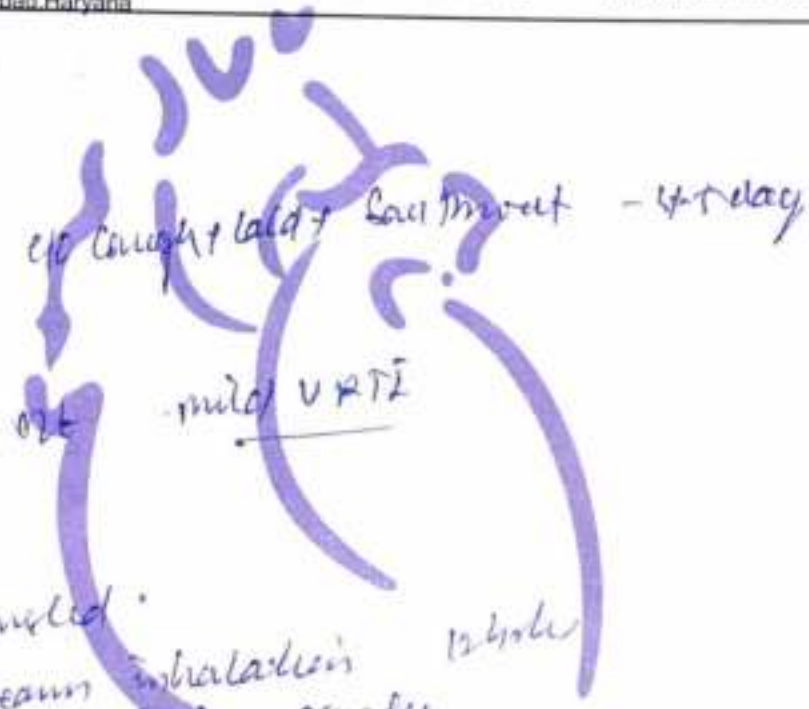


OPD PRESCRIPTION

MR.NO	: 28166	Date&Time	: 14/10/2023 10.19 AM
Name	: Mr. PAWAN KUMAR	Sex	: Male
Doctor Name	: Dr. HARSH VARDHAN SINGH	Age	: 38Years 9Months 14Days
Speciality	: ENT	Mobile No	: 9911141571
Address	: H NO 571, SECTOR 21 D FARIDABAD NIT, Faridabad City, Faridabad, Haryana	Panel	: MEDIWHEEL FOC

14/10/23

ENT



Adv: →

- o. Combed
- o. steam inhalation whole
- o. warm saline gargle
- o. Tab SIMARON - whole, 5 day
- o. Review of ENT

8888
Dr. H. V. S.

DEPARTMENT OF RADIOLOGY

Patient Name	Mr PAWAN KUMAR	Billed Date	14/10/2023	8:37 AM
Reg No	28166	Reported Date	14/10/2023	
Age/Sex	38 Years 9 Months 14Days / Male	Req. No.	23058504	
Type	OPD	Consultant Doctor	Dr. CONSULTANT	

USG WHOLE ABDOMEN

LIVER : The liver is normal in size, shape and echotexture. No evidence of any focal lesion. IHBR is NOT dilated. Portal vein is normal.

GALL BLADDER :The gall bladder is well distended. No evidence any calculus or mass seen. GB wall thickness with in normal limits. No evidence of pericholecystic fluid is seen. The common bile duct is normal.

SPLEEN :The spleen is normal in size and shape. Its echotexture is homogeneous. No evidence of focal lesion is noted. Splenic vein is normal.

PANCREAS :The pancreas is normal in size, shape, contours and echotexture.

BILATERAL KIDNEYS : The bilateral kidneys are normal in size and echotexture. Cortico-medullary differentiation is maintained. There is no evidence of obvious calculus or hydronephrosis seen.

URINARY BLADDER :The urinary bladder is well distended. Wall thickness within normal limits. No evidence of calculus is seen. No evidence of mass or diverticulum is noted.

PROSTATE: Prostate appears normal in size, shape and echotexture.

No free fluid is seen in peritoneal cavity.

No evidence of obvious retroperitoneal or mesenteric lymphadenopathy is seen.

There are few well defined oval shaped homogeneously hyperechoic lesions with linear echogenic strands are seen in subcutaneous plane of anterior abdominal wall. The lesions measures ~ 2-3cm in dimensions.

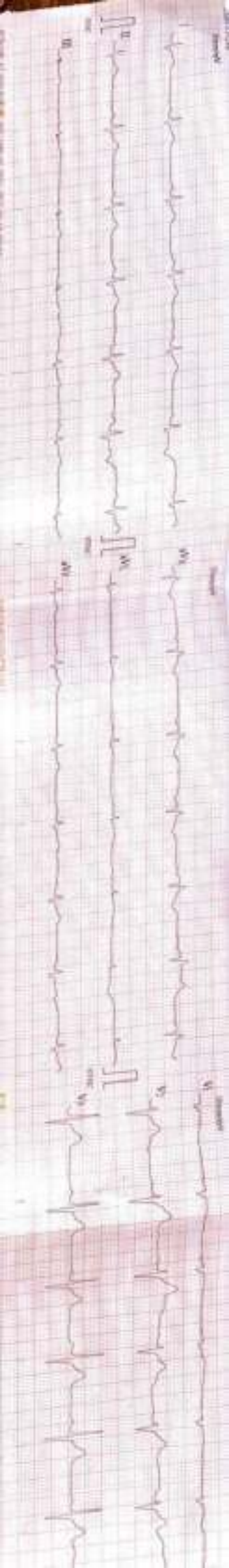IMPRESSION: - USG WHOLE ABDOMEN REVEALS Few subcutaneous tissue lipomas.

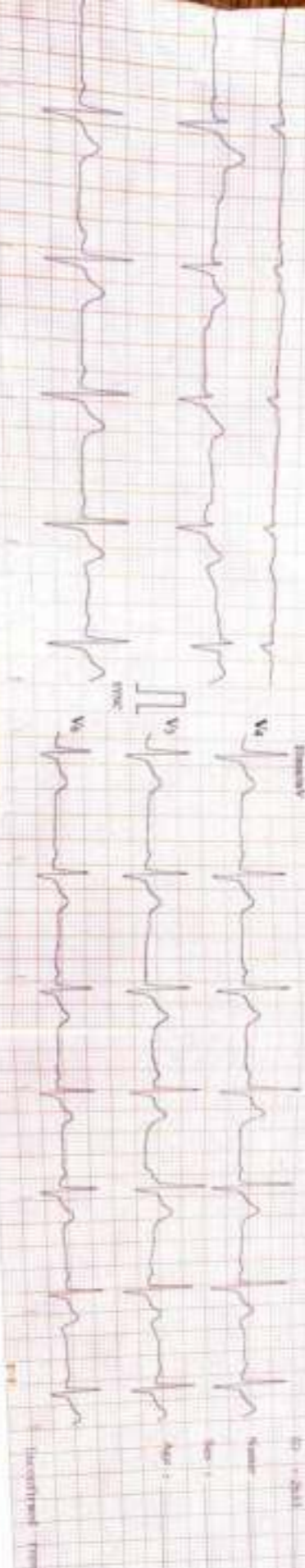
DIRENDRA K. CHAUDHARY
MBBS, MD
CONSULTANT RADIOLOGIST

(This is only professional opinion and not the diagnosis, Please correlate clinically)

J-Block, Sector-10, Near Court, Faridabad - 121004, Haryana

Tel.: 0129-4200000 E-mail : parkfaridabad@gmail.com





PR 160ms
 QRS 88ms
 QT 354ms
 QTc 41ms
 PRP 210ms
 PRP/QT 52%
 PRP/QTc 127%
 PRP/QTc 127%
 PRP/QTc 127%

ST-T: Abnormal
 ST-T: Abnormal

Pateon James

Interpreted by:

12-LEAD ECG

PARK HOSPITAL
J BLOCK SEC-10, FARIDABAD
 28166/HR PAWAN KUMAR
 38 Yrs/Male
 77 Kg/181 Cms
 Date: 14-Oct-2023 11:03:12 AM

HR: 209 bpm
 METS: 4.7
 BP: 80/0

MPHR: 115% of 181
 Speed: 1.7 mph
 Grader: 10.0%

Raw ECG
 BRUCE
 (0.05-100)Hz

Ex Time 03:00
 BLC : On
 Notch : On

Stage 1 (03:00)
 10.0 mm/mV
 25 mm/Sec

