



Grant Medical Foundation

Ruby Hall Clinic

Hinjawadi

2DECHO&DOPPLER REPORT

NAME: MRS. DHANVIJAY NEHA AGE: 30 Yrs/F DATE: 16 /09/2024

MITRAL VALVE: has thin leaflets with normal subvalvar motion.

No mitral regurgitation .

AORTIC VALVE : has three thin leaflets with normal opening

No aortic regurgitation.

PULMONARY VALVE; NORMAL,

LEFT VENTRICLE : is normal , has normal wall thickness, No RWMA at rest .

Normal LV systolic function. EF - 60%.

LEFT ATRIUM: is normal.

RIGHT ATRIUM & RIGHT VENTRICLE: normal in size.

TRICUSPID VALVE & PULMONARY VALVES : normal.

Trivial TR, No PH.

No pericardial effusion

IMP : **Normal LV Systolic function. EF-60%:**
 No diastolic dysfunction
 No RWMA at rest
 Normal Valves and Chambers
 IAS & IVS Intact
 No clot / vegetation / thrombus / pericardial effusion.

DR. YATIN VISAVE
MBBS,DMRD(RADIOLOGY)

| | | | |
|-----------------------|--------------------|-------------------|-------------------|
| Name: | DHANVIJAY NEHA | Exam Date: | 16-Sep-2024 |
| Age & Sex: | 030 Year /F | Accession: | 143177120025 |
| Exam: | ABDOMEN AND PELVIS | PID: | P00000698982 |
| Physician: | HOSPITAL CASE | OP/IP: | OP /«extrafield1» |

ULTRASOUND OF ABDOMEN AND PELVIS

Liver appears normal in size, shape and echotexture. No focal lesion is seen. No intrahepatic biliary radicle dilatation seen. The portal vein and CBD appear normal.

Gall bladder is well distended with normal wall thickness. No calculus or sludge is seen.
Pancreas appears normal in size and echotexture. No focal lesion is seen.
Spleen appears normal in size and echotexture. No focal lesion is seen.

Both kidneys appear normal in size, shape & echotexture. They show good cortico-medullary differentiation. There is no hydronephrosis, hydroureter or calculus seen on either side.

The urinary bladder is empty .

Visualised bowel loops are non-dilated and show normal peristalsis.
There is no ascites or significant lymphadenopathy seen.

IMPRESSION : No significant abnormality noted.

Suggest: Clinical Correlation.



DR. YATIN R. VISAVE
CONSULTANT RADIOLOGIST
MBBS, DMRD
Regd. No. 090812

16-Sep-2024 12:58:35 PM



| | |
|-----------------------------------|--------------------------------|
| Name: DHANVIJAY NEHA | Study Date: 16-Sep-2024 |
| Age & Sex: 030 Year /F | Accession: 143177120025 |
| Exam: CHEST X RAY | PID: P00000698982 |
| Physician: HOSPITAL CASE | OP OP /«extrafield1» |

Health Check

Radiograph Chest PA View :

Both lung fields normal.

Both costo-phrenic angles are clear.

Cardiac silhouette and aortic knuckle are normal.

Both hilar shadows and the diaphragmatic contours are normal.

Thoracic soft tissues and the rib cage normal.

Impression :

No significant abnormality noted.

DR. YATIN R. VISAVE
CONSULTANT RADIOLOGIST
MBBS, DMRD
Regd. No. 090812

16-Sep-2024 12:56:57 PM



Grant Medical Foundation
Ruby Hall Clinic
 Hinjawadi

Rajeev Gandhi Infotech Park, MIDC, Phase No. 1, Plot No P-33, Hinjawadi, Pune - 411057.

• Ph: 020 66999999 • Email : hinjawadi@rubyhall.com • 24 hrs Helpline - 7757005773 • Website : www.rubyhall.com, www.hinjawadi.rubyhall.com

16/09/2024

Mrs. Meha Dhanvijay 30/F married P, L, LSCS.

amp: 25/08/2024 3-4/28-30 days / moderate.

dysmenorrhoea out of.

no significant medical surgical history.

OLE

P/A - soft.

no A/R/T.

P/c - C4 (H)
 Vg

no craniom

Ubc taken.

Acle

- FIV SOS c Reports.

- T. Drohin SOS

Dr. Swarada J. Kulkarni
 M.B.B.S., MS, DNB, FMAS
 Obstetrics & Gynecology
 Regn. No. MMC2015084363



Grant Medical Foundation
Ruby Hall Clinic
Hinjawadi

MS DHANVIJAY NEHA



Ref: PS010165- Reg: OPS00006962
30.7.5/F - NH - 16/09/2024
P00000698982 -

Dental

O/E →

Stomach → +, Calcium →

Adv:-

Oral prophylaxis

Dr. Aniket

16-Sep-2024 9:08

MS DHANJAY NEHA



ID: Name: Sex: M cm Medication: Symptoms: History: Vent. rate 78 bpm PR int 142 ms QRS dur 88 ms QT/QTc(E) int 376/409 ms P/QRS/T axis 60/41/26 RV5/SV1 amp 1.93/1.21 mV RV5+SV1 amp 3.14 mV

1100 Sinus rhythm 9110 xx normal ECG **

Unconfirmed Report Reviewed by:

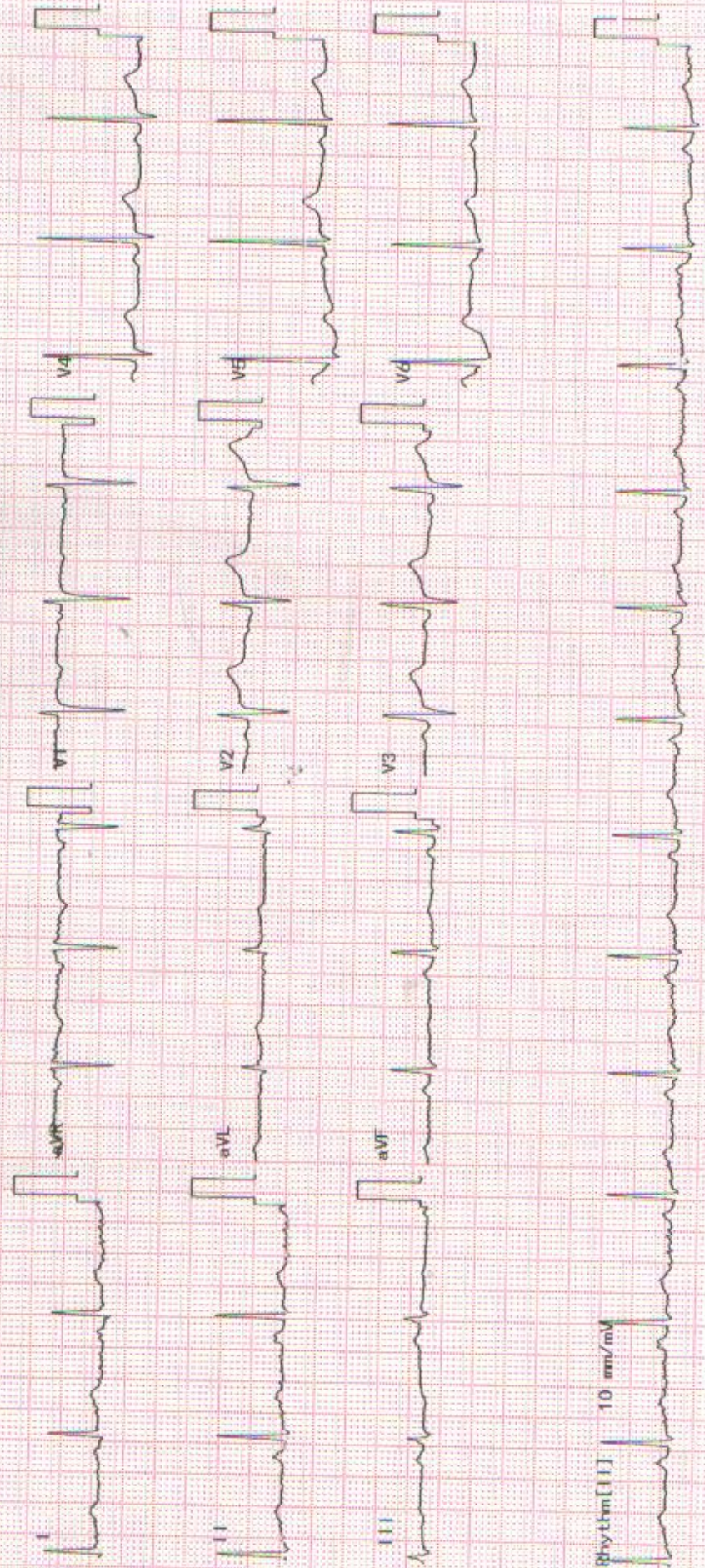
10 mm/mV

10 mm/mV

10 mm/mV

10 mm/mV

10 mm/mV





MS DHANVIJAY NEHA



Ref: PS010165- Reg: OPS0006962
 30.7.5/F - NH - 16/09/2024
 P0000069882 -

OPHTHALMOLOGY

AGE: 30/F

R

L

- 1) Vision $\left\{ \begin{array}{l} \text{unaided} \quad 6/12 \\ \text{c glasses} \end{array} \right.$ 6/12
- 2) Near Vision $\left\{ \begin{array}{l} \text{unaided} \quad N6 \\ \text{c glasses} \end{array} \right.$ N6
- 3) Binocular Vision N
- 4) Colour Vision N
- 5) Tension OIC N OIC
- 6) Anterior Segment
- 7) Pupils
- 8) Lens WNL WNL
- 9) Media & Fundus
- 10) Remarks To prefer glasses
- R: -0.50 / 1.25 x 100 (S/O)
- L: + / 1.75 x 70 (S/O)

Date: 16/9/24

(Signature)