

Duplicate

UHID	JNA2024009313	Visit No	EPD2024016347
Age / Gender	30 Y/Female	Bill Number	OPB2024023502
Patient Name	Mrs Solanki Dipika Pavankumar	Bill Date/Time	28-09-2024 11:31 AM
Dr. Name	Dr. Pinal Panara	Speciality	Dental Science
Referred By	SELF	GSTIN	24AAZFA0783D2ZC
Payer Name	Mediwheel	Mobile No.	8866645178
Address	Junagadh, Junagadh, Junagadh, Gujarat, India, 362001		

BILL DETAILS

S.No.	Service Type	Particular	Appointment Time	Qty	Amount	Net Amt.
1	Administration	OPD Registration Charges		1	0	0
2	Cardiology	ECG		1	100	100
3	Cardiology	2D Echo		1	800	800
4	OP Consultation	Dr. Pinal Panara	28-09-2024 12:00 PM	1	50	50
5	OP Consultation	Dr. Tulsi Jograjiya	28-09-2024 11:50 AM	1	50	50
6	Pathology	CBC		1	120	120
7	Pathology	ESR		1	50	50
8	Pathology	BGRh		1	50	50
9	Pathology	Urine Sugar		1	50	50
10	Pathology	PP2BS		1	40	40
11	Pathology	FBS		1	40	40
12	Pathology	Stool R/M		1	300	300
13	Pathology	Lipid Profile		1	400	400
14	Pathology	Liver function test(LFT)		1	1,000	1,000
15	Pathology	S Billirubin		1	120	120
16	Pathology	Serum Creatinine		1	100	100
17	Pathology	Urea		1	120	120
18	Pathology	HbA1c		1	400	400
19	Pathology	URINE R/M		1	50	50
20	Radiology	USG WHOLE ABDOMEN		1	600	600
21	Radiology	X RAY CHEST PA		1	250	250

RECEIPT DETAILS

Total Amount 4690.0
Net Amount 4690.0
Authorised Amount 4690.0

Printed By
Khyati Tala

Print Date & Time
07-10-2024 07:01 PM

Created By
Amisha Parmar



Patient Name	Mrs Solanki Dipika Pavankumar	Age/Gen	30 Y/Female
UHID	JNA2024009313	Ordering Doctor	Dr. Pinal Panara
Refer By	SELF	Sample Request	28-09-2024
Mob	8866645178	Sample Collected	28-09-2024 01:41 PM
Doctor	Dr. Pinal Panara	Specialty	Obstetrics & Gynaecology
Report Date	28-09-2024 03:12 PM	Specimen	Serum

Clinical Biochemistry

Service Name	Result	Unit	Reference Range
HbA1c			
Glycosylated Hb	7.16 H	%	Normal : ≤ 5.7 Prediabetes : 5.7 -6.4 Diabetes : ≥ 6.5 6-7 : Near Normal Glycemia, <7 : Goal, 7-8 : Good Control >8 : Action Suggested
Estimated Average Glucose	158.79	mg/dL	
FBS	100	mg/dL	60-110
PP2BS	140	mg/dL	80-140
Renal Function Test(RFT)			
Serum Creatinine	0.59	mg/dL	0.59-1.1
Urea	15.9	mg/dL	13-43
BUN (Blood Urea Nitrogen)	7.43	mg/dL	6-20
SODIUM (NA ⁺)	141	mmol/L	136-145
POTASSIUM (K ⁺)	4.4	mmol/L	3.5-5.1
Uric Acid	4.6	mg/dL	2.6-6.0
S Billirubin			
Billirubin Total	0.76	mg/dL	0.2-2.0
Billirubin Direct	0.33 H	mg/dL	0.0-0.2
Billirubin Indirect	0.43	mg/dL	0.2-0.7
Lipid Profile			
Cholesterol	179	mg/dL	Low Risk : < 200 Moderate Risk : 200-239 High Risk : ≥ 240
Triglyceride	157 H	mg/dL	Normal : < 150 Border Line : 150-199 High: 200-499 Very High : ≥ 500
HDL Cholesterol	37.1 L	mg/dL	Negative Risk : ≥ 60 High Risk : ≤ 40



Duplicate

UHID	JNA2024009313	Visit No	EPD2024016347
Age / Gender	30 Y/Female	Bill Number	OPB2024023502
Patient Name	Mrs Solanki Dipika Pavankumar	Bill Date/Time	28-09-2024 11:31 AM
Dr. Name	Dr. Pinal Panara	Speciality	Dental Science
Referred By	SELF	GSTIN	24AAZFA0783D2ZC
Payer Name	Mediwheel	Mobile No.	8866645178
Address	Junagadh, Junagadh, Junagadh, Gujarat, India, 362001		

BILL DETAILS

S.No.	Service Type	Particular	Appointment Time	Qty	Amount	Net Amt.
1	Administration	OPD Registration Charges		1	0	0
2	Cardiology	ECG		1	100	100
3	Cardiology	2D Echo		1	800	800
4	OP Consultation	Dr. Pinal Panara	28-09-2024 12:00 PM	1	50	50
5	OP Consultation	Dr. Tulsi Jograjiya	28-09-2024 11:50 AM	1	50	50
6	Pathology	CBC		1	120	120
7	Pathology	ESR		1	50	50
8	Pathology	BGRh		1	50	50
9	Pathology	Urine Sugar		1	50	50
10	Pathology	PP2BS		1	40	40
11	Pathology	FBS		1	40	40
12	Pathology	Stool R/M		1	300	300
13	Pathology	Lipid Profile		1	400	400
14	Pathology	Liver function test(LFT)		1	1,000	1,000
15	Pathology	S Billirubin		1	120	120
16	Pathology	Serum Creatinine		1	100	100
17	Pathology	Urea		1	120	120
18	Pathology	HbA1c		1	400	400
19	Pathology	URINE R/M		1	50	50
20	Radiology	USG WHOLE ABDOMEN		1	600	600
21	Radiology	X RAY CHEST PA		1	250	250

RECEIPT DETAILS

Total Amount 4690.0
Net Amount 4690.0
Authorised Amount 4690.0

Printed By
Khyati Tala

Print Date & Time
07-10-2024 07:01 PM

Created By
Amisha Parmar



NAME:	DIPIKABEN SOLANKI
SEX/AGE:	30 Y F
PATIENT ID:	JNA2024009313
REF. DR.:	SELF
DATE:	07-10-2024 19:49

USG ABDOMEN WITH PELVIS

LIVER:

Liver is normal in size, shape and echotexture. No e/o focal or diffuse parenchymal lesion is seen. No e/o dilated IHBR or portal venous radical. Portal vein are normal in caliber.

GALL BLADDER:

Gall Bladder is distended and normal. No e/o calculus or cholecystitis is seen.

PANCREAS:

Visualized proximal part of pancreas is normal in size & echo texture.

SPLEEN:

Spleen is normal in size & echo texture. No focal or diffuse lesion is seen

KIDNEYS:

Both kidneys are normal in shape, size and position.
Cortical thickness and echogenicity appear normal.
No evidence of calculus, hydronephrosis or mass seen.

U. BLADDER:

Urinary bladder is minimally distended and normal. No e/o calculus or mass seen.

Uterus appears normal in size and echo texture.
No e/o any adnexal mass seen.

No e/o ascites seen. No e/o significant lymphadenopathy seen.

IMPRESSION:

- No significant abnormality is seen.

Thanks for reference, clinical correlation and further investigations suggested

(CONSULTANT RADIOLOGIST)



Patient Name	Mrs Solanki Dipika Pavankumar	Age/Gen	30 Y/Female
UHID	JNA2024009313	Ordering Doctor	Dr. Pinal Panara
Refer By	SELF	Sample Request	28-09-2024
Mob	8866645178	Sample Collected	28-09-2024 01:41 PM
Doctor	Dr. Pinal Panara	Specialty	Obstetrics & Gynaecology
Report Date	28-09-2024 03:12 PM	Specimen	Blood

Haematology

Service Name	Result	Unit	Reference Range
CBC			
Hemoglobin(Hb)	12.9	gm/dl	12-16
RBC COUNT	4.75	millions/cumm	4.2-5.4
Hematocrit(PCV)	42.0	%	42-52
MCV (Mean Cell Volume)	88.42	fl	76-96
MCH (Mean Corpuscular Hemoglobin)	27.16	pg	27-32
MCHC (Mean Corpuscular Hemoglobin Concentration)	30.71	L g/dL	32-36
RDW (Red Cell Distribution Width)	13.4	%	11-16
WBC count - Total(TC)	7320	/cu.mm	4500-11000
Neutrophils.	60	%	40-70
Lymphocyte.	35	%	20-40
Eosinophils.	3	%	2-10
Monocytes.	2	%	1-6
Basophils.	0	%	0-2
Platelet Count	329000	/cu.mm	150000-400000
BGRh			
ABO	B		
Rh FACTOR	Positive		
ESR	27	mm/hr	0-20



Dr Prignal Aghera
M.B. D.C.P
Consultant Pathologist

-----End of the Report-----

Patient Name	Mrs Solanki Dipika Pavankumar	Age/Gen	30 Y/Female
UHID	JNA2024009313	Ordering Doctor	
Refer By	SELF	Sample Request	28-09-2024
Mob	8866645178	Sample Collected	28-09-2024 06:36 PM
Report Date	28-09-2024 06:40 PM	Specimen	Serum

Immunology

Service Name	Result	Unit	Reference Range
TFT (Thyroid Function Test)			
T3	2.37	ng/mL	0.750-2.10
T4	75.2	ng/mL	52.0-127.0
TSH	1.61	uIU/mL	0.300-4.50

Interpretation :

Dr Prignal Aghera
M.B. D.C.P
Consultant Pathologist

-----End of the Report-----



ECHOCARDIOGRAPHY AND COLOR DOPPLER REPORT


NAME: MRS.DIPIKABEN SOLANKI **AGE/SEX:30YEARS/FEMALE**
DATE:28/09/2024 **REF BY: AYUSH HOSPITAL**

OBSERVATION:

- NORMAL LV SIZE WITH NORMAL LV SYSTOLIC FUNCTION
- LVEF 55% [VISUAL]
- NO REGIONAL WALL MOTION ABNORMALITY AT REST
- E/O DIASTOLIC DYSFUNCTION I
- MILD MR, NO MS
- NO AR, NO AS
- MILD TR, NO PAH
- NORMAL LA, RA, RV, IVC WITH GOOD RV FUNCTION
- INTACT IAS / IVS
- NO PDA/COARCTATION
- NORMAL AORTIC ARCH AND VESSELS
- NO INTRA-CARDIAC CLOT/VEGETATION
- NORMAL PERICARDIUM / NO EFFUSION

FINAL IMPRESSION:

- NORMAL LV SIZE AND FUNCTION (LVEF 55%)
- NO RWMA AT REST
- E/O DIASTOLIC DYSFUNCTION I
- MILD MR,MILD TR; NO PAH


DR PRIYANK MODI
[DrNB CARDIO]
REG NO PG/G 37873



ECHOCARDIOGRAPHY AND COLOR DOPPLER REPORT

NAME: MRS.DIPIKABEN SOLANKI **AGE/SEX:30YEARS/FEMALE**
DATE:28/09/2024 **REF BY: AYUSH HOSPITAL**

OBSERVATION:

- NORMAL LV SIZE WITH NORMAL LV SYSTOLIC FUNCTION
- LVEF 55% [VISUAL]
- NO REGIONAL WALL MOTION ABNORMALITY AT REST
- E/O DIASTOLIC DYSFUNCTION I
- MILD MR, NO MS
- NO AR, NO AS
- MILD TR, NO PAH
- NORMAL LA, RA, RV, IVC WITH GOOD RV FUNCTION
- INTACT IAS / IVS
- NO PDA/COARCTATION
- NORMAL AORTIC ARCH AND VESSELS
- NO INTRA-CARDIAC CLOT/VEGETATION
- NORMAL PERICARDIUM / NO EFFUSION

FINAL IMPRESSION:

- NORMAL LV SIZE AND FUNCTION (LVEF 55%)
- NO RWMA AT REST
- E/O DIASTOLIC DYSFUNCTION I
- MILD MR,MILD TR; NO PAH

Priyank Modi
DR PRIYANK MODI
[DrNB CARDIO]
REG NO PG/G 37873





ધી ઈમરજન્સી, ICU & ટ્રોમા સેન્ટર

ઝાંઝરડા ચોકડી, જુનાગઢ. 75 72 88 88 72

Duplicate

UHID	JNA2024009313	Visit No	EPD2024016347
Age / Gender	30 Y/Female	Bill Number	OPB2024023589
Patient Name	Mrs Solanki Dipika Pavankumar	Bill Date/Time	28-09-2024 01:49 PM
Dr. Name	Dr. Chintan Tilala	Speciality	Medicine
Referred By	SELF	GSTIN	24AAZFA0783D2ZC
Payer Name	Mediwheel	Mobile No.	8866645178
Address	Junagadh, Junagadh, Junagadh, Gujarat, India, 362001		

BILL DETAILS

S.No.	Service Type	Particular	Appointment Time	Qty	Amount	Net Amt.
1	OP Consultation	Dr. Chintan Tilala	28-09-2024 02:00 PM	1	50	50

RECEIPT DETAILS

Total Amount 50.0
Net Amount 50.0
Authorised Amount 50.0

Printed By
Khyati Tala

Print Date & Time
07-10-2024 07:04 PM



Created By
Amisha Parmar



ધી ઈમરજન્સી, ICU & ટ્રોમા સેન્ટર

ઝાંઝરડા ચોકડી, જુનાગઢ. 75 72 88 88 72

Duplicate

UHID	JNA2024009313	Visit No	EPD2024016347
Age / Gender	30 Y/Female	Bill Number	OPB2024023654
Patient Name	Mrs Solanki Dipika Pavankumar	Bill Date/Time	28-09-2024 06:23 PM
Speciality		Referred By	SELF
GSTIN	24AAZFA0783D2ZC	Payer Name	Mediwheel
Mobile No.	8866645178	Address	Junagadh,Junagadh,Junagadh,Gujarat,India, 362001

BILL DETAILS

S.No.	Service Type	Particular	Qty	Amount	Net Amt.
1	Pathology	TFT (Thyroid Function Test)	1	750	750
2	Pathology	Renal Function Test(RFT)	1	220	220

RECEIPT DETAILS

Total Amount 970.0
Net Amount 970.0
Authorised Amount 970.0

Printed By
Khyati Tala

Print Date & Time
07-10-2024 07:01 PM

Created By
Amisha Parmar



NAME:	SOLANKI DIPIKA
AGE/SEX:	30 Y F
PATIENT ID:	JNA2024009313
REF. DR.:	DR CHINTAN TILALA
DATE:	28-09-2024

X-RAY CHEST – PA

- *Both lung field shows mild prominent broncho vascular markings.*
- Rest of both lung field appear normal.
- Both costo-phrenic angles are clear.
- Cardiac size and both hila appear normal.
- Domes of diaphragm appear normal.
- Visualized bony thorax appears normal.

(CONSULTANT RADIOLOGIST)



Patient Name	Mrs Solanki Dipika Pavankumar	Age/Gen	30 Y/Female
UHID	JNA2024009313	Ordering Doctor	Dr. Pinal Panara
Refer By	SELF	Sample Request	28-09-2024
Mob	8866645178	Sample Collected	28-09-2024 01:41 PM
Doctor	Dr. Pinal Panara	Specialty	Obstetrics & Gynaecology
Report Date	28-09-2024 03:12 PM	Specimen	Serum

Clinical Biochemistry

Service Name	Result	Unit	Reference Range
HbA1c			
Glycosylated Hb	7.16 H	%	Normal : ≤ 5.7 Prediabetes : 5.7 -6.4 Diabetes : ≥ 6.5 6-7 : Near Normal Glycemia, <7 : Goal, 7-8 : Good Control >8 : Action Suggested
Estimated Average Glucose	158.79	mg/dL	
FBS	100	mg/dL	60-110
PP2BS	140	mg/dL	80-140
Renal Function Test(RFT)			
Serum Creatinine	0.59	mg/dL	0.59-1.1
Urea	15.9	mg/dL	13-43
BUN (Blood Urea Nitrogen)	7.43	mg/dL	6-20
SODIUM (NA ⁺)	141	mmol/L	136-145
POTASSIUM (K ⁺)	4.4	mmol/L	3.5-5.1
Uric Acid	4.6	mg/dL	2.6-6.0
S Billirubin			
Billirubin Total	0.76	mg/dL	0.2-2.0
Billirubin Direct	0.33 H	mg/dL	0.0-0.2
Billirubin Indirect	0.43	mg/dL	0.2-0.7
Lipid Profile			
Cholesterol	179	mg/dL	Low Risk : < 200 Moderate Risk : 200-239 High Risk : ≥ 240
Triglyceride	157 H	mg/dL	Normal : < 150 Border Line : 150-199 High : 200-499 Very High : ≥ 500
HDL Cholesterol	37.1 L	mg/dL	Negative Risk : ≥ 60 High Risk : ≤ 40





ધી ઈમરજન્સી, ICU & ટ્રોમા સેન્ટર

ઝાંઝરડા ચોકડી, જુનાગઢ. 75 72 88 88 72

Duplicate

UHID	JNA2024009313	Visit No	EPD2024016347
Age / Gender	30 Y/Female	Bill Number	OPB2024023654
Patient Name	Mrs Solanki Dipika Pavankumar	Bill Date/Time	28-09-2024 06:23 PM
Speciality		Referred By	SELF
GSTIN	24AAZFA0783D2ZC	Payer Name	Mediwheel
Mobile No.	8866645178	Address	Junagadh,Junagadh,Junagadh,Gujarat,India, 362001

BILL DETAILS

S.No.	Service Type	Particular	Qty	Amount	Net Amt.
1	Pathology	TFT (Thyroid Function Test)	1	750	750
2	Pathology	Renal Function Test(RFT)	1	220	220

RECEIPT DETAILS

Total Amount 970.0
Net Amount 970.0
Authorised Amount 970.0

Printed By
Khyati Tala

Print Date & Time
07-10-2024 07:01 PM



Created By
Amisha Parmar

Patient Name	Mrs Solanki Dipika Pavankumar	Age/Gen	30 Y/Female
UHID	JNA2024009313	Ordering Doctor	Dr. Pinal Panara
Refer By	SELF	Sample Request	28-09-2024
Mob	8866645178	Sample Collected	28-09-2024 01:41 PM
Doctor	Dr. Pinal Panara	Specialty	Obstetrics & Gynaecology
Report Date	28-09-2024 03:12 PM	Specimen	Serum

Service Name	Result	Unit	Reference Range
LDL Cholesterol	110.50	mg/dL	Low Risk < 130 Moderate Risk : 131-159 High Risk > 160
VLDL	31.40	mg/dL	0-34
LDL/HDL RATIO	2.98	NA	Low Risk : 0.5-3.0 Moderate Risk : 3.0-6.0 Elevated Level High: >6.0
Total Chol/ HDL Ratio	4.82 H	NA	Low Risk : 3.3 to 4.4 Average Risk : 4.4 to 7.1 Moderate Risk > 7.1 to 11.0 High Risk : > 11.0
Total Lipids	672.00	mg/dL	400-700
Urea	16	mg/dL	13-43
Serum Creatinine	0.59	mg/dL	0.59-1.1
Urine Sugar	Absent		
Liver function test(LFT)			
SGPT	10	U/L	5-42
SGOT	14	U/L	5-40
Billirubin Total	0.76	mg/dL	0.2-2.0
ALKALINE PHOSPHATE	61	U/L	42-98
Billirubin Direct	0.33 H	mg/dL	0.0-0.2
Billirubin Indirect	0.43	mg/dL	0.2-0.7
Total Protein	5.8	g/dL	5.8-8.3
Serum Albumin	4.04	gm/dl	3.5-5.0
Serum Globulin	1.76 L	gm/dl	2.4-3.5
ALBUMIN/GLOBULIN RATIO	2.30 H	NA	1.2-2.2



(Signature)

Dr Prignal Aghera
M.B. D.C.P
Consultant Pathologist

-----End of the Report-----

NAME:	SOLANKI DIPIKA
AGE/SEX:	30 Y F
PATIENT ID:	JNA2024009313
REF. DR.:	DR CHINTAN TILALA
DATE:	28-09-2024

X-RAY CHEST – PA

- *Both lung field shows mild prominent broncho vascular markings.*
- Rest of both lung field appear normal.
- Both costo-phrenic angles are clear.
- Cardiac size and both hila appear normal.
- Domes of diaphragm appear normal.
- Visualized bony thorax appears normal.

(CONSULTANT RADIOLOGIST)



NAME:	DIPIKABEN SOLANKI
SEX/AGE:	30 Y F
PATIENT ID:	JNA2024009313
REF. DR.:	SELF
DATE:	07-10-2024 19:49

USG ABDOMEN WITH PELVIS

LIVER:

Liver is normal in size, shape and echotexture. No e/o focal or diffuse parenchymal lesion is seen. No e/o dilated IHBR or portal venous radical. Portal vein are normal in caliber.

GALL BLADDER:

Gall Bladder is distended and normal. No e/o calculus or cholecystitis is seen.

PANCREAS:

Visualized proximal part of pancreas is normal in size & echo texture.

SPLEEN:

Spleen is normal in size & echo texture. No focal or diffuse lesion is seen

KIDNEYS:

Both kidneys are normal in shape, size and position.
Cortical thickness and echogenicity appear normal.
No evidence of calculus, hydronephrosis or mass seen.

U. BLADDER:

Urinary bladder is minimally distended and normal. No e/o calculus or mass seen.

Uterus appears normal in size and echo texture.
No e/o any adnexal mass seen.

No e/o ascites seen. No e/o significant lymphadenopathy seen.

IMPRESSION:

- No significant abnormality is seen.

Thanks for reference, clinical correlation and further investigations suggested

(CONSULTANT RADIOLOGIST)



Patient Name	Mrs Solanki Dipika Pavankumar	Age/Gen	30 Y/Female
UHID	JNA2024009313	Ordering Doctor	Dr. Pinal Panara
Refer By	SELF	Sample Request	28-09-2024
Mob	8866645178	Sample Collected	28-09-2024 01:41 PM
Doctor	Dr. Pinal Panara	Specialty	Obstetrics & Gynaecology
Report Date	28-09-2024 03:12 PM	Specimen	Blood

Haematology

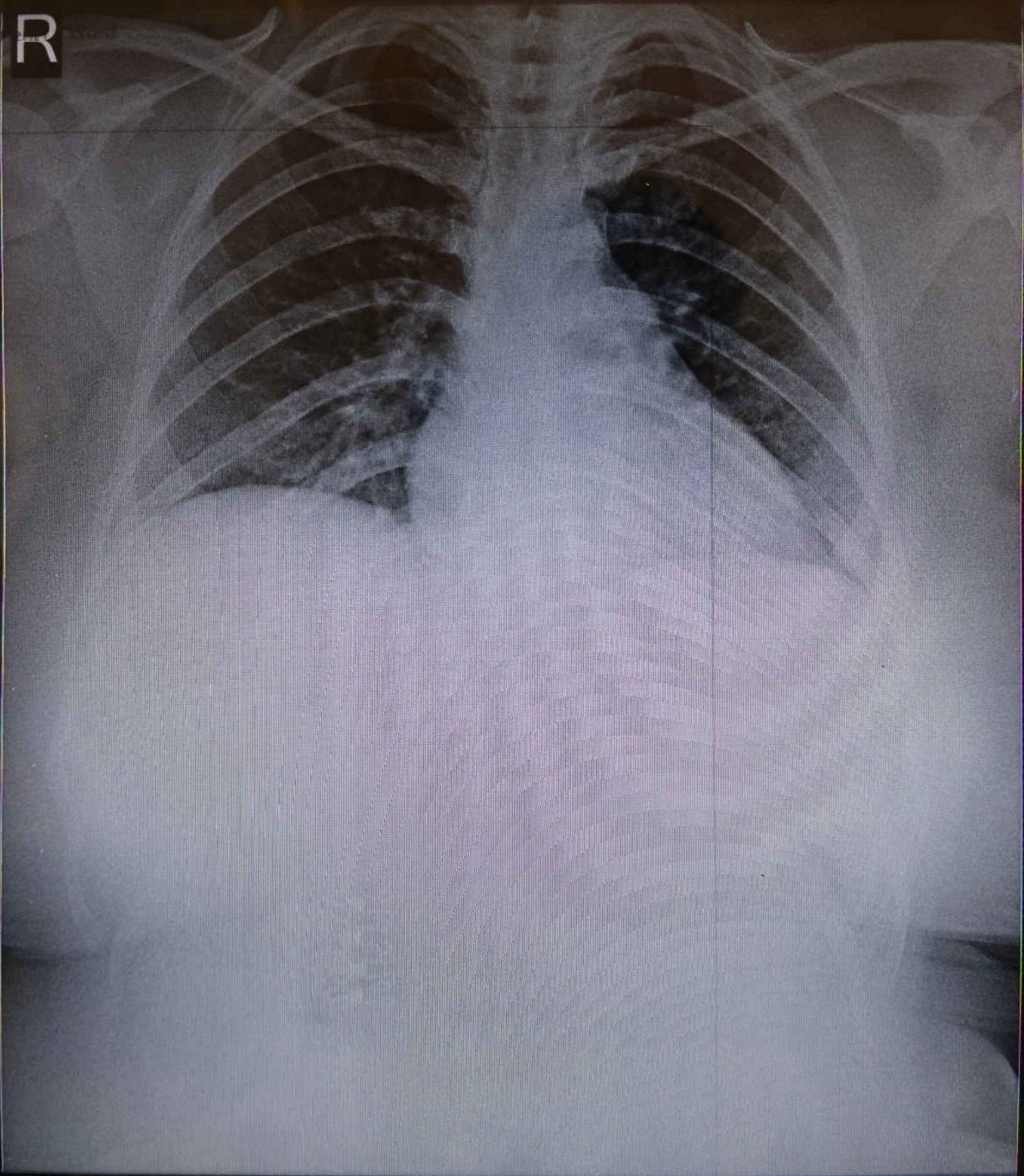
Service Name	Result	Unit	Reference Range
CBC			
Hemoglobin(Hb)	12.9	gm/dl	12-16
RBC COUNT	4.75	millions/cumm	4.2-5.4
Hematocrit(PCV)	42.0	%	42-52
MCV (Mean Cell Volume)	88.42	fl	76-96
MCH (Mean Corpuscular Hemoglobin)	27.16	pg	27-32
MCHC (Mean Corpuscular Hemoglobin Concentration)	30.71	L g/dL	32-36
RDW (Red Cell Distribution Width)	13.4	%	11-16
WBC count - Total(TC)	7320	/cu.mm	4500-11000
Neutrophils.	60	%	40-70
Lymphocyte.	35	%	20-40
Eosinophils.	3	%	2-10
Monocytes.	2	%	1-6
Basophils.	0	%	0-2
Platelet Count	329000	/cu.mm	150000-400000
BGRh			
ABO	B		
Rh FACTOR	Positive		
ESR	27	mm/hr	0-20



(Signature)

Dr Prignal Aghera
M.B. D.C.P
Consultant Pathologist

R



SOLANKI DIPIKA 30Y/F CHEST PA 28-09-2024
AAYUSH HOSPITAL , JUNAGADH



Reg. No : 2409400276

Reg. Date : 29-Sep-2024

Collection Date : 29-Sep-2024 09:58

Name : DIPIKABEN

Age / Sex : 30 Years / Female

Ref. By :

Report Date : 29-Sep-2024

Location: AAYUSH MULTISPECIALITY HOSPITAL


STOOL EXAMINATION

Parameter	Result	Unit	Biological Reference Interval
PHYSICAL EXAMINATION			
Colour	Yellow Brown		
Blood	Absent		
Consistency	Solid		
Mucus	Absent		
Adult Worm	Absent		
Parasites	Absent		
Pus	Absent		
CHEMICAL EXAMINATION			
Occult Blood	Absent		Absent
PH	Neutral		
Reducing Substance	Absent		
MICROSCOPIC EXAMINATION			
RBCs	Absent	/h.p.f.	
Pus cells	2-3	/h.p.f.	
Epithelial cells	Absent		
Veg. cells	Present		
Macrophages	Absent		
Fat Globules	Absent		
Trophozoites	Absent		
Ova	Absent		
Cysts	Absent		
Sample Status :	Sample received from out side.		

----- End Of Report -----



Thanks For Reference

Approved by: 
Dr. AJAY TILALA
M.D. PATHOLOGY

Dr. Ruchit Shah
M.B.B.S D.C.P. DNB