



A.L.C. Advance Imaging Dignostics

ISO 9001:2015 Certified center

(A Unit of P.K.Arogyam Health & Wellness Center)

E-95, P.C. Colony, Near Sai Netryalaya Transformer, Kankarbagh, Patna - 20

www.pkarogyamhealthcheckup.com

7050037694, 8271206196

OPINION MUST BE CORRELATES WITH CLINICALLY & OTHER INVESTIGATION FOR FINAL DIAGNOSIS. NOT FOR MEDICO LEGAL PURPOSE

PATIENT NAME : Mr. PRITY KUMARI PATIENT ID: 4092
COL DATE : 14/03/2022 REPORTING DATE: 09/02/2022 AGE SEX : 31 YRS/F
REF.BY : DR.MEDIWHEEL

| TEST NAME | RESULT | Unit | REF.RANGE |
|--------------------------|--------|--------|--------------------|
| Total Triiodothyronin T3 | 1.01 | ng/mL | 0.80 -2.00 ng/mL |
| Total Thyroxin T4 | 5.90 | µg/dL | 5.10 -14.10 µg/dL |
| Serum TSH | 2.11 | µIU/mL | 0.27 - 4.20 µIU/mL |

THYROID DISORDER (>: Increase: < Decrease: n Normal

1. T3(n) T4(n) TSH(n) :EUTHYROID STATE:
2. T3(>) T4(>) TSH(<): HYPERTHYROIDISM:
3. T3(<)T4(<) TSH(>): HYPOTHYROIDISM:
4. T3(n)T4(n) TSH(>) : SUB-CLINICAL HYPO-THYROIDISM:
5. T3(n)T4(n) TSH(<): SUB-CLINICAL HYPER-THYROIDISM:
6. T3(>) T4(n) TSH(<): T3 THYROTOXICOSIS:

Total T3/T4 level is dependent on Level:

So determination of free T3/T4is a better MARKER of Thyroid Function.



Dr. Ankur Kumar
MBBS, MD
Consultant Pathologist
Reg. No 39540

Consultant Radiologist

ESTD BY:-

Dr. P. K. Tiwari
MD, M.Sc (Radio Imaging)
Ph.D (Ab Nuclear Medicine)
Consultant Imagiologist & Sonologist

Dr. S. Kumar
MD (Pat)
Consultant Pathologist

Dr. Abhishek Kumar
MBBS, MD
Consultant Neuropatho Physiologist

Dr. Anjali
MBBS, MD
Consultant(TMT,EEG Specialist)

Dr. Kumari Suman
MBBS, DGO, MD
Consultant (TVS & HSG Specialist)

PRINTING MISTAKE SHOULD BE REPORTED BACK IMMEDIATELY/ यहाँ जन्म से पहले भ्रुण का लिंग जाँच नहीं होता है ।

A.L.C. Advance Imaging Dignostics

ISO 9001:2015 Certified center

(A Unit of P.K.Arogyam Health & Wellness Center)

E-95, P.C. Colony, Near Sai Netryalaya Transformer, Kankarbagh, Patna - 20

alcdiagnostics@gmail.com

www.pkarogayamhealthcheckup.com

7050037694, 8271206196

OPINION MUST BE CORRELATES WITH CLINICALLY & OTHER INVESTIGATION FOR FINAL DIAGNOSIS. NOT FOR MEDICO LEGAL PURPOSE

PATIENT NAME : Mrs. PRITY KUMARI

PATIENT ID: 4092

COL DATE : 14/03/2022 REPORTING DATE: 12/03/2022 AGE SEX:- 31 YRS/F

REF.BY : DR./ MEDIWHEEL.

| TEST NAME | RESULT | Unit | REF.RANGE |
|----------------------|---------|-------|------------------|
| LFT:- | | | |
| SGPT | 11.7 | IU/L | 5 - 48 IU/L |
| S G O T | 14.7 | IU/L | 5 - 40 IU/L |
| ALKALINE PHOSPHATASE | 84.1 | IU/L | 25 - 147 IU/L |
| TOTAL PROTIN | 7.1 | g/dl | 6.0 - 8.7 g/dl |
| SERUM ALBUMIN | 4.6 | g/dl | 3.5 - 5.4 g/dl |
| SERIUM GLUBLINE | 2.5 | g/dl | 2.3 - 3.6 g/dl |
| AG RATIO | 1.8 : 1 | | 1.0 - 2.3 g/dl |
| BILIRUBIN | | | |
| TOTAL | 0.62 | mg/dl | 0.1 - 1.1 mg/dl |
| IRECT | 0.24 | mg/dl | 0.0 - 0.32 mg/dl |
| INDIRECT | 0.38 | mg/dl | 0.0 - 0.78 mg/dl |

KFT/RFT

| | | | |
|---------------------------|------|-------|-----------------|
| URIC ACID | 4.1 | mg/dl | 3.2 - 7.0 mg/dl |
| SERUM CREATNINE | 0.7 | mg/dl | 0.6 - 1.5 mg/dl |
| BLOOD URIA | 29.9 | mg/dl | 5 - 45 mg/dl |
| BLOOD URIA NITROZEN(BUN). | 13.9 | mg/dl | 13 - 39 mg/dl |



Dr. Ankur Kumar
MBBS, MD
Consultant Pathologist
Reg No 39540

Consultant Radiologist

ESTB BY:-

Dr. P. K. Tiwari
MD, M.Sc (Radio Imaging)
Ph D (Ait Nuclear Medicine)
Consultant Imagonologist & Sonologist

Dr. S. Kumar
MD (Pat)
Consultant Pathologist

Dr. Abhishek Kumar
MBBS, MD
Consultant Neuropatho Physiologist

Dr. Anjali
MBBS, MD
Consultant(TMT,EEG Specialist)

Dr. Kumari Suman
MBBS, DGO, MD
Consultant (TVS & HSG Specialist)

PRINTING MISTAKE SHOULD BE REPORTED BACK IMMEDIATELY/ यहाँ जन्म से पहले भुण का लिंग जाँच नहीं होता है ।

P.K.A.C. Advance Imaging Dignostics

ISO 9001:2015 Certified center

(A Unit of P.K.Arogyam Health & Wellness Center)

E-95, P.C. Colony, Near Sai Netryalaya Transformer, Kankarbagh, Patna - 20

pkadiagnostics@gmail.com

www.pkarogayamhealthcheckup.com

7050037694, 8271206196

OPINION MUST BE CORRELATES WITH CLINICALLY & OTHER INVESTIGATION FOR FINAL DIAGNOSIS. NOT FOR MEDICO LEGAL PURPOSE

PATIENT NAME : Mrs. PRITY KUMARI

PATIENT ID: 4092

COL DATE : 14/03/2022 REPORTING DATE: 14/03/2022 AGE SEX : 31 YRS/F

REF.BY : DR. /MEDIWHEEL.

| TEST NAME | RESULT | Unit | REF.RANGE |
|-------------------|------------|------|----------------|
| BLOOD SUGAR (F) | 70.0 mg/dl | | 70 - 110 mg/dl |

LIPID PROFILE:-

| | | | |
|------------------|-------------|--|----------------|
| TOTAL CHOLESTROL | 150.9 mg/dl | | 130 -250 mg/dl |
| TRIGLYCERIDE | 97.4 mg/dl | | 50 -160 mg/dl |
| HDL CHOLESTROL | 41.0 mg/dl | | 30 - 60 mg/dl |
| LDL CHOLESTROL | 90.4 mg/dl | | 80 -130 mg/dl |
| VLDL CHOLESTROL | 19.5 mg/dl | | 15 - 40 mg/dl |
| T.CH./HDL RATIO | 3.6:1 | | Upto 5:1 |
| LDL/HDL RATIO | 2.2:1 | | 2 - 4:1 |



Dr. Ankur Kumar
MBBS, MD
Consultant Pathologist:
Reg No 39540

ESTB BY:-

Dr. P. K. Tiwari
MD, M.Sc (Radio Imaging)
Ph.D (AI Nuclear Medicine)
Consultant Imagiologist & Sonologist

Dr. S. Kumar
MD (Pat)
Consultant Pathologist

Dr. Abhishek Kumar
MBBS, MD
Consultant Neuropatho Physiologist

Dr. Anjali
MBBS, MD
Consultant(TMT,EEG Specialist)

Consultant Radiologist

Dr. Kumari Suman
MBBS, DGO, MD
Consultant (TVS & HSG Specialist)

PRINTING MISTAKE SHOULD BE REPORTED BACK IMMEDIATELY/ यहाँ जन्म से पहले म्रुण का लिंग जाँच नहीं होता है ।

A.L.C. Advance Imaging Dignostics

ISO 9001:2015 Certified center

(A Unit of P.K.Arogyam Health & Wellness Center)

E-95, P.C. Colony, Near Sai Netryalaya Transformer, Kankarbagh, Patna - 20

alcdiagnostics@gmail.com

www.pkarogayamhealthcheckup.com

7011337614, 9221221196

OPINION MUST BE CORRELATES WITH CLINICALLY & OTHER INVESTIGATION FOR FINAL DIAGNOSIS. NOT FOR MEDICO LEGAL PURPOSE

PATIENT NAME : Mrs. PRITY KUMARI PATIENT ID: 4092
COL DATE : 14/03/2022 REPORTING DATE: 14/03/2022 AGE SEX:- 31 YRS/F
REF.BY : DR. / MEDIWHEEL.

| TEST NAME | RESULT | Unit | REF.RANGE |
|-------------|------------|------|-----------|
| BLOOD GROUP | : 'O' | | |
| Rh Typing | : POSITIVE | | |

Note: Do always cross – matching before blood transfusion



Dr. Anjali Kumar
MBBS MD
Consultant Pathologist
Reg No 39540

ESTD BY:-

Dr. P. K. Tiwari
MD, M.Sc (Radio Imaging)
Ph D (Ab Nuclear Medicine)
Consultant Imaginologist & Sonologist

Dr. S. Kumar
MD (Pat)
Consultant Pathologist

Dr. Abhishek Kumar
MBBS, MD
Consultant Neuropatho Physiologist

Dr. Anjali
MBBS, MD
Consultant (TMT, EEG Specialist)

Consultant Radiologist

Dr. Kusumari Summan
MBBS, DGO, MCh
Consultant (GYN & HSG Specialist)

PRINTING MISTAKE SHOULD BE REPORTED BACK IMMEDIATELY/ यहाँ जन्म से पहले कुण का लिए जीव नहीं होता है ।

A.L.C. Advance Imaging Dignostics

ISO 9001:2015 Certified center

(A Unit of P.K.Arogyam Health & Wellness Center)

E-95, P.C. Colony, Near Sai Netryalaya Transformer, Kankarbagh, Patna - 20

alcdiagnostics@gmail.com

www.pkarogyamhealthcheckup.com

7050037694, 8271206196

OPINION MUST BE CORRELATES WITH CLINICALLY & OTHER INVESTIGATION FOR FINAL DIAGNOSIS. NOT FOR MEDICO LEGAL PURPOSE

PATIENT NAME : Mrs. PRITY KUMARI PATIENT ID: 4092
COL DATE : 14/03/2022 REPORTING DATE: 14/03/2022 AGE SEX : 31 YRS/F
REF.BY : DR./ MEDIWHEEL.

GLYCOSYLATED HEMOGLOBIN

| TEST NAME | RESULT | Unit | REF.RANGE |
|------------------------|------------|------|---|
| HbA1c | 4.0 % | | Below 5.7 % : Normal 5.7 – 6.4 % : Prediabetic > = 6.5 % : Diabetic |
| AVERAGE PLASMA GLUCOSE | 94.0 mg/dl | | 90 – 120 mg/dl : Good Control 121– 150 mg/dl : Fair Control 151- 180 mg/dl: Unsatisfactory Control >180 mg/dl : Poor Control |



Dr. Anur Kumar
MBBS MD
Consultant Pathologist
Reg No 39540

ESTD BY-

Dr. P. K. Tiwari
MD, M Sc (Radio Imaging)
Ph D (Air Nuclear Medicine)
Consultant Imagingologist & Sonologist

Dr. S. Kumar
MD (Pat)
Consultant Pathologist

Dr. Abhishek Kumar
MBBS, MD
Consultant Neuropatho Physiologist

Dr. Anjali
MBBS, MD
Consultant (TMT, EEG Specialist)

Consultant Radiologist

Dr. Kumari Suman
MBBS, DGO, MD
Consultant (IVS & HSG Specialist)

PRINTING MISTAKE SHOULD BE REPORTED BACK IMMEDIATELY/यहाँ जन्म से पहले भुण का सिग जौच नहीं होता है ।

A.L.C. Advance Imaging Dignostics

ISO 9001:2015 Certified center

(A Unit of P.K.Arogyam Health & Wellness Center)

E-95, P.C. Colony, Near Sai Netryalaya Transformer, Kankarbagh, Patna - 20

alcdiagnostics@gmail.com

www.pkarogyamhealthcheckup.com

7050037694, 8271206196

OPINION MUST BE CORRELATES WITH CLINICALLY & OTHER INVESTIGATION FOR FINAL DIAGNOSIS. NOT FOR MEDICO LEGAL PURPOSE

PATIENT NAME : Mrs. PRITY KUMARI

PATIENT ID: 4092

COL DATE : 14/03/2022 REPORTING DATE: 14/03/2022 AGE SEX:- 31 YRS/F

REF.BY : DR. / MEDIWHEEL.

| TEST NAME | RESULT | Unit | REF.RANGE |
|------------------------------|-----------------------|------|---------------------|
| ESR | 10 mm/hr | | <20 mm/hr |
| CBC | | | |
| Total W.B.C. Count | 6500 /cumm | | 4000-11,000 /cumm |
| R B C COUNT | 4.1 Million/ CUmm | | 4 - 7 Million/ CUmm |
| Platelets count | 1.77 Lakh/ cumm | | 1.5-5.0 Lakh/ cumm |
| Differential Count of W.B.C. | | | |
| Neutrophils | 68 % | | 40-70% |
| Lymphocytes | 28 % | | 25-40% |
| Eosinophils | 03 % | | 01-05% |
| Mnonocytes | 01 % | | 00-02% |
| Basophiles | 00 % | | 00-0% |
| HAEMOGLOBIN | 12.2 gm/dl (83.5 %) | | 14.6 gm/dl = 100% |
| PCV | 36.4 % | | 35-47 % |
| MCV | 87.2 fl | | 76-96 fl |
| MCH | 29.4 pg | | 29-35 pg |
| MCHC | 33.6 % | | 30-38 % |



Dr. Ankur Kumar
MBBS, MD
Consultant Pathologist
Reg. No 39540

ESTBY-

Consultant Radiologist

Dr. P. K. Tiwari
MD, M.Sc (Radio Imaging)
Ph.D (AIH Nuclear Medicine)
Consultant Imaginologist & Sonologist

Dr. S. Kumar
MD (Pat)
Consultant Pathologist

Dr. Abhishek Kumar
MBBS, MD
Consultant Neuropatho Physiologist

Dr. Anjali
MBBS, MD
Consultant (TMT, EEG Specialist)

Dr. Kumari Suman
MBBS, DGO, MD
Consultant (IVS & HSG Specialist)

PRINTING MISTAKE SHOULD BE REPORTED BACK IMMEDIATELY/ यहाँ जन्म से पहले भुण का लिंग जाँच नहीं होता है ।

A.L.C. Advance Imaging Dignostics

ISO 9001-2015 Certified center

(A Unit of P.K.Arogyam Health & Wellness Center)

E-95, P.C. Colony, Near Sai Netryalaya Transformer, Kankarbagh, Patna - 20

alcdiagnostics@gmail.com

www.pkarogoyamhealthcheckup.com

7050037694, 8771206196

OPINION MUST BE CORRELATES WITH CLINICALLY & OTHER INVESTIGATION FOR FINAL DIAGNOSIS. NOT FOR MEDICO LEGAL PURPOSE

PATIENT NAME : Mrs . PRITI KUMARI

PATIENT ID:A092

COL DATE : 14/03/2022 REPORTING DATE: 14/03/2022 AGE SEX:- 31 YRS/F

REF.BY : DR. / MEDIWHEEL.

ROUTINE EXAMINATION OF URINE

PHYSICAL EXAMINATION


| | | | |
|----------------------|-------|--------------|-------|
| Quantity | 20 ml | Colour.... | Straw |
| Appearance... | Clear | Sediment ... | Nil |
| Specific gravity.... | 1.010 | | |

CHEMICAL EXAMINATION

| | | | |
|-------------------------|----------|-------------------|----------|
| Reaction | 6.0 | Nitrite..... | Not done |
| Sugar | Nil | Bile Pigment | Not done |
| Albumin | Nil | Urobilinogen.... | Not done |
| Excess of Phosphate.... | Nil | Chile..... | Not done |
| Bile Salt | Not Done | Acetone... | Not done |

MICROSCOPIC EXAMINATION

| | | | |
|------------------|-----------|--------------|-----|
| Erythrocytes.... | Nil | Casts | Nil |
| Leucocytes | 1-3 / HPE | Crystals.... | Nil |
| Epith. Cell | A, Few | Others | Nil |


Dr. Anil Kumar
MBBS, MD
Consultant Pathologist
Reg No 39540



ESTB BY:-

Dr. P. K. Tiwari
MD, M.Sc (Radio Imaging)
Ph.D (Ali Nuclear Medicine)
Consultant Imagonologist & Sonologist

Dr. S. Kumar
MD (Pat)
Consultant Pathologist

Dr. Abhishek Kumar
MBBS, MD
Consultant Neuropatho Physiologist

Dr. Anjali
MBBS, MD
Consultant(TMT,EEG Specialist)

Consultant Radiologist

Dr. Kumari Suman
MBBS, DGO, MD
Consultant (TVS & HSG Specialist)

PRINTING MISTAKE SHOULD BE REPORTED BACK IMMEDIATELY/यहाँ जन्म से पहले भुण का लिंग जाँच नहीं होता है ।

ID: 4092 CASE: 1 PRITY KUMARI 14/03/2022 12:01:02
 AGE: 30Y 0M 0SD FEMALE ALC ADVANCE IMAGING DIAGNOSTICS
 155cms 51kg E95 PC COLONY KANKARBAGH PATNA

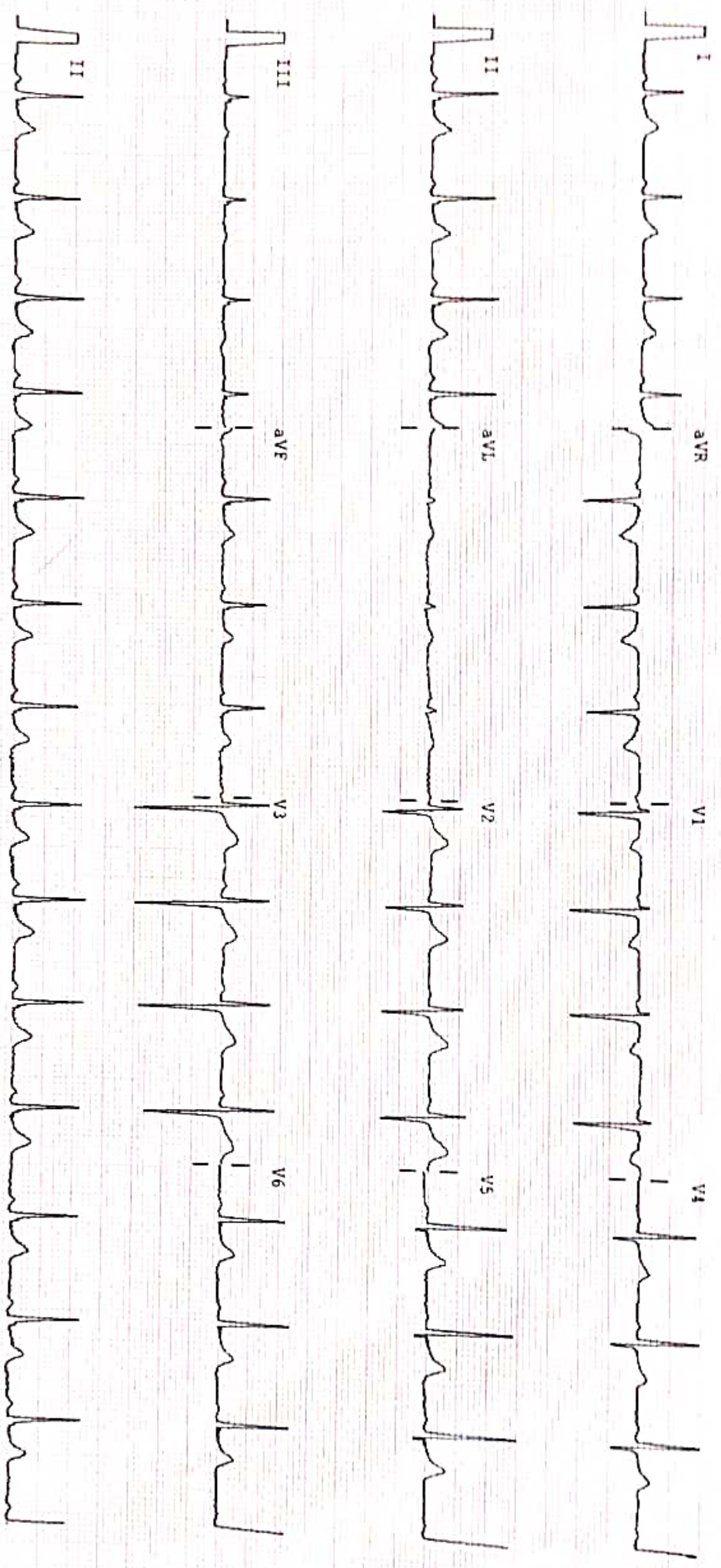
RATE : 85 bpm SINUS RHYTHM
 R-R : 704 ms SHORT PR INTERVAL
 P-R : 104 ms
 QRS : 78 ms
 QT : 352 ms
 QTc : 396 ms

..AXIS..
 P : 45°
 QRS : 54°
 T : 44°

12 SL. REPORT FORMAT: 3x1+1L SQ REF: DR BOB DR. DR ABHISHEK KUMAR MBBS MD



Dr. Abhishek Kumar
 MBBS, MD



25mm/sec 10mm/mV Notch: ON ELC: ON 0.05-35Hz ALLENGERS PISCES 1012(VER.---1.8) CLINICALLY CORRELATE THE FINDINGS.



A.L.C. Advance Imaging Dignostics

ISO 9001:2015 Certified center

(A Unit of P.K.Arogyam Health & Wellness Center)

E-95, P.C. Colony, Near Sai Netryalaya Transformer, Kankarbagh, Patna - 20

alcdiagnostics@gmail.com

www.pkarogyamhealthcheckup.com

7050037694, 8271206196

OPINION MUST BE CORRELATES WITH CLINICALLY & OTHER INVESTIGATION FOR FINAL DIAGNOSIS. NOT FOR MEDICO LEGAL PURPOSE

Pt. Name :- **PRITY KUMARI**
Ref. By :- **DR. B O B**

Date:- **14-Mar-22**
Age / Sex – **30 Yrs. F.**

Thanks for your kind referral

X-RAYCHEST (P.A.VIEW)

The lungs on the either side show equal translucency.

The peripheral pulmonary vasculature is normal.

No focal lung lesion is seen.

The pleural spaces are normal.

Both hila are normal in size, have equal density and bear normal relationship.

The heart and trachea are central in position and no mediastinal abnormality is visible.

The cardiac size is normal.

The domes of the diaphragms are normal in position, and show smooth outline.

IMPRESSION

- NO EVIDENCE OF PULMONARY OR CARDIAC PATHOLOGY IS NOTED.



Dr. A.K. Singh
MBBS, PGDMCH
Consultant Radiologist
Consultant Radiologist

ESTD BY:-

Dr. P. K. Tiwari
MD, M.Sc (Radio Imaging)
Ph.D (Ait Nuclear Medicine)
Consultant Imagionologist & Sonologist

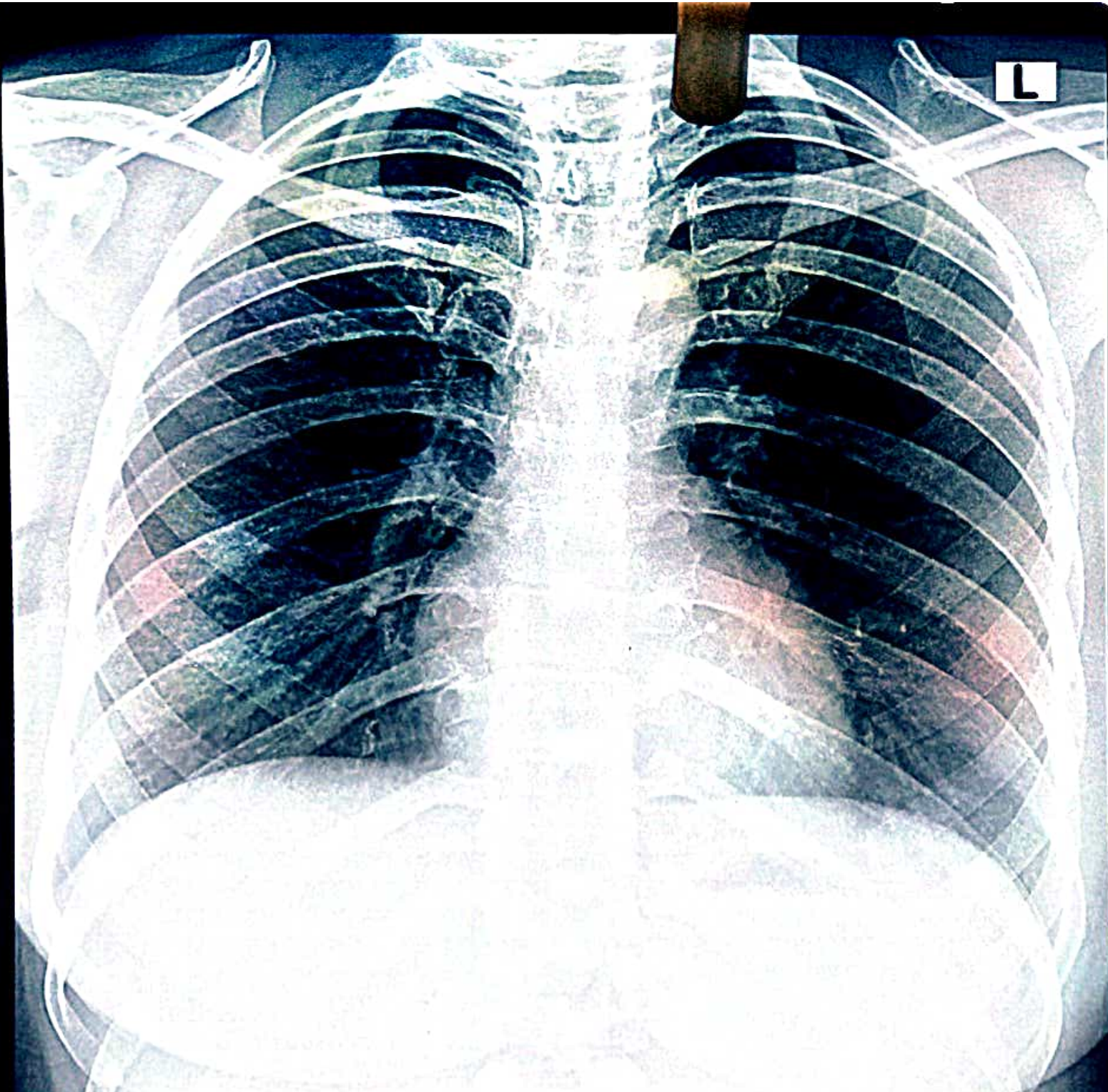
Dr. S. Kumar
MD (Pat)
Consultant Pathologist

Dr. Abhishek Kumar
MBBS, MD
Consultant Neuropatho Physiologist

Dr. Anjali
MBBS, MD
Consultant(TMT,EEG Specialist)

Dr. Kumari Suman
MBBS, DGO, MD
Consultant (TVS & HSG Specialist)

PRINTING MISTAKE SHOULD BE REPORTED BACK IMMEDIATELY/ यहाँ जन्म से पहले भुण का लिंग जाँच नहीं होता है ।



PRITY KUMARI AGE 30 YEARS 4092 BY DR. BOB CHEST,FRN P->A 3/14/2022
A.L.C. Advance Imaging Diagnostics Centre PATNA - 20



SUBHAM IMAGING & A.L.C. DIAGNOSTICS CENTRE

H.O. : Ajay Market, Bank of Baroda Building, East Ashok Nagar, Kankarbagh, Patna - 20

B.O. : Khanpura Road (Below Gyan Sharowar School), Paliganj, Patna.

e-mail : shubham.pat.usg@gmail.com # website : www.pkarogayamhealthcheckup.com

OPINION MUST BE CORRELATES WITH CLINICAL & OTHER INVESTIGATION FOR DIAGNOSIS NOT FOR MEDICO LEGAL PURPOSE

Pt. Name :- **PRITI KUMARI**

Date:- 14-Mar-22

Ref. By :- **DR/BOB MEDIWHEEL**

Age / Sex – 30 Yrs. F.

REAL TIME U.S.G. OF WHOLE ABDOMEN

Thanks for your kind referral

(Report.)

- LIVER** :- Measures 12.63 cm. Normal in shape , size and echo texture.I.H.B.R. are not dilated. Hepatic veins are normal. No SOL seen.
- G.BL.** :- Lumen is echo free. Wall thickness appears normal.
- C.B.D.** :- Measures 3.3 mm in diameter with echo free lumen. No calculi or mass seen.
- P.V.** :- Measures 7.2 mm in diameter. Appears normal. No thrombus seen.
- PANCREAS** :- Normal in shape, size and echo texture. No calcification mass seen.
- SPLEEN** :- Measures 9.80 cm. Normal in shape, size and echo texture. No SOL seen.
- KIDNEY** :- Both kidney shows normal shape, size & echotexture. C.M.D.intact. P.C.S.is not dilated. No calculi, cyst or hydronephrosis seen on either side.
Right Kidney :- Measures 9.10 X 4.3 cm.
Left Kidney :- Measures 9.0 X 4.4 cm.
- URETER** :- Not dilated .No apparent calculi seen.
- U.BLADDER**:- Shows normal in outline with echo free lumen. No calculi or mass seen.
Pre void – 210 ml. Post void – is in significant
- UTERUS** :- Is normal in size, shape & position measuring 7.70 X 5.50 cm. Endometrial And Myometeriam appears normal in limits No focal mass lesion seen
- ADNEXA** :- Both ovary appears normal in size and shape.
Rt Ovary Measures – 2.70 cm Lt Ovary Measures 2.30 cm
- P.O.D** :- No collection seen in P.O.D
- R.I.F.** :- Son graphically no appendicular mass or collection seen.
- OTHERS** :- No Ascites . no Lymph Adenopathy. No pleural effusion seen on either side .

IMPRESSION

➤ **Son graphically normal scan no detectable lesion seen**

ESTD BY-

Dr. P. K. Tiwari

MD, M.Sc (Radio Imaging)

Ph D (Art Nuclear Medicine)

Consultant Imagiologist & Sonologist

Dr. S. Kumar

MD. (Pat)

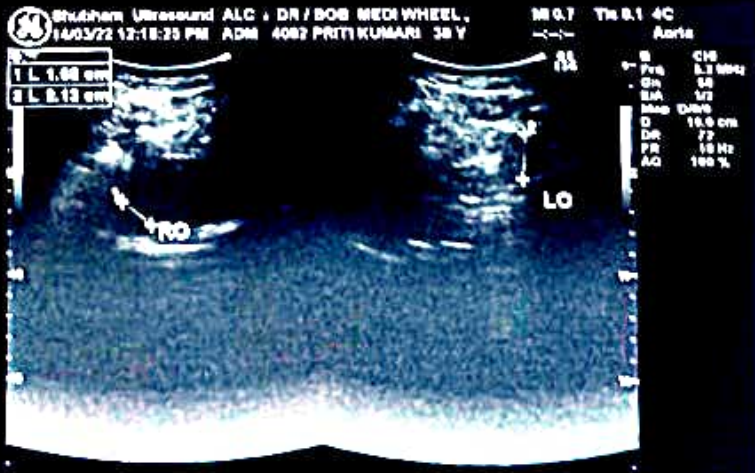
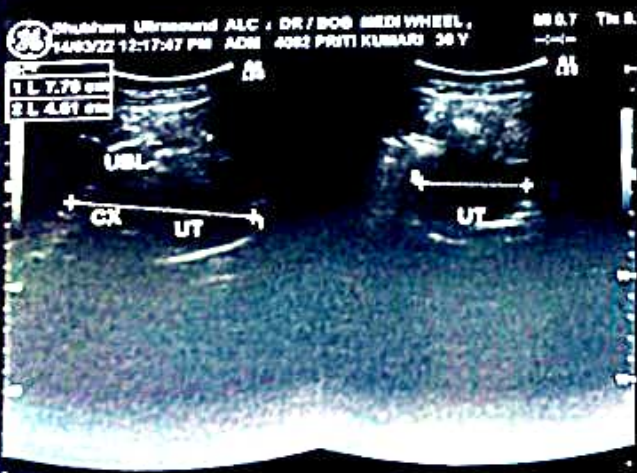
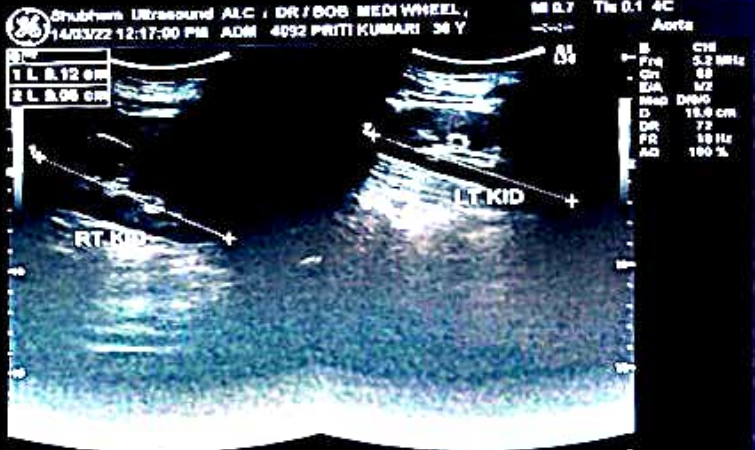
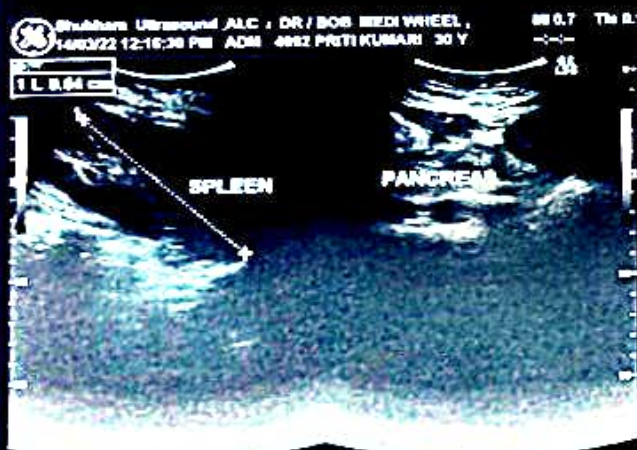
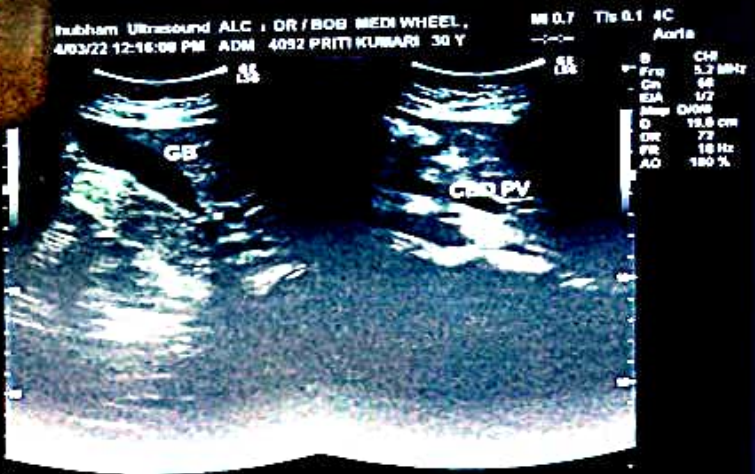
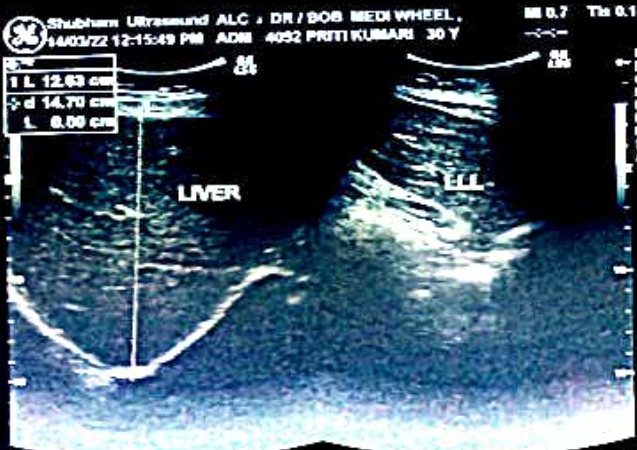
Consultant Pathologist

Dr. A. K. Singh

MBBS, PGDACH

Consultant Radiologist & Sonologist

PRINTING MISTAKE SHOULD BE REPORTED BACK IMMEDIATELY/ गहों जन्म से पहले मुण का लिंग जौच नही होता है ।





A.L.C. Advance Imaging Dignostics

ISO 9001:2015 Certified center

(A Unit of P.K.Arogyam Health & Wellness Center)

E-95, P.C. Colony, Near Sai Netryalaya Transformer, Kankarbagh, Patna - 20

alcdiagnostics@gmail.com

www.pkarogyamhealthcheckup.com

7050037694, 8271206196

OPINION MUST BE CORRELATES WITH CLINICALLY & OTHER INVESTIGATION FOR FINAL DIAGNOSIS. NOT FOR MEDICO LEGAL PURPOSE

ECHOCARDIOGRAPHY & COLOR DOPPLER REPORT

Patient's Name : Mr. PRITI KUMARI

Age/Sex : 30 Yrs /F

Ref. by : B O B

Date : 14-Mar-22

ECHOCARDIOGRAPHIC WINDOW: Fair

2D & M MODE ECHOCARDIOGRAPHY

Left ventricle

| | | | | | |
|--------------------|--------|------------------------------------|---------|----|----------------------------------|
| EDD: | 40 | mm (20 - 28 mm / m ²) | ESD: | 27 | mm(13 - 21 mm / m ²) |
| IVS : | 7 | mm (6 - 11 mm) | PW: | 10 | mm(6 - 11 mm) |
| Ejection fraction: | | 60% (61 ± 8%) | FS: | 30 | %(34 - 44 %) |
| IVS: | Intact | | LV clot | | Absent |

Left atrium/ Aorta 20/27 mm

Right ventricle Normal

Right atrium Normal

Pericardium Normal with no pericardial effusion

2D:

Normal LA/LV Size and normally contracting left ventricle. No RWMA, concentric LVH

Mitral valve

AML/ PML: Normal

Tricuspid valve Normal

Aortic valve Normal

Pulmonary valve Normal

Continuous & Pulse Wave Doppler study

| Valve | Velocity (m/sec) | | | Gradient (mmHg) | | | Valve area (PHT Method) | Regurg. |
|-----------|------------------|------|-----|-----------------|------|-----|-------------------------|---------|
| | Peak | Mean | EDV | Peak | Mean | EDG | | |
| Mitral | E=1.2 A=0.7 | | | 5.2 | 2.0 | | | Nil |
| Tricuspid | E=0.7 A=0.5 | | | 1.8 | 0.2 | | | Nil |
| Aortic | 1.4 | | | 5.0 | 2.5 | | | Nil |
| Pulmonary | 7.6 | | | 3.5 | 1.7 | | | Nil |



Consultant Radiologist

ESTBY:-

Dr. P. K. Tiwari
MD, M.Sc (Radio Imaging)
Ph D (Alt Nuclear Medicine)
Consultant Imaginologist & Sonologist

Dr. S. Kumar
MD (Pat)
Consultant Pathologist

Dr. Abhishek Kumar
MBBS, MD
Consultant Neuropathology Physiologist

Dr. Anjali
MBBS, MD
Consultant (TMT, EEG Specialist)

Dr. Kumari Suman
MBBS, DGO, MD
Consultant (TVS & HSG Specialist)

PRINTING MISTAKE SHOULD BE REPORTED BACK IMMEDIATELY/ यहाँ जन्म से पहले भ्रुण का लिंग जाँच नहीं होता है ।

A.L.C. Advance Imaging Dignostics

ISO 9001:2015 Certified center

(A Unit of P.K.Arogyam Health & Wellness Center)

E-95, P.C. Colony, Near Sai Netryalaya Transformer, Kankarbagh, Patna - 20

alcdiagnostics@gmail.com

www.pkarogyamhealthcheckup.com

7050037694, 8271206196

OPINION MUST BE CORRELATES WITH CLINICALLY & OTHER INVESTIGATION FOR FINAL DIAGNOSIS. NOT FOR MEDICO LEGAL PURPOSE

Colour Flow Imaging

No TR, No MR/PR, No AR

No flow shunt

COMMENTS :

- ◆ Normal size all chamber
- ◆ Normal LV filling Pressure
- ◆ No RWMA
- ◆ Normal LV systolic function
- ◆ Grade I LV diastolic dysfunction.
- ◆ Global LVEF = 60%
- ◆ All cardiac valves are normal
- ◆ No PAH, Mild concentric LVH
- ◆ No MS / TS / AS / PS / PR
- ◆ No clot / vegetation / pericardial effusion.

IMPRESSION:

All chambers are normal

No RWMA, No PAH

Grade I LV diastolic dysfunction.

Normal LV systolic function, LVEF – 60%

Please correlate clinically

DR. SANDEEP KUMAR MBBS MD

DR. SANDEEP KUMAR

M.B.B.S., M.D. (Med.)

Reg. No.-BCMR33225



Consultant Radiologist

ESTD BY:-

Dr. P. K. Tiwari

MD, M.Sc (Radio Imaging)
Ph.D (Ali Nuclear Medicine)

Consultant Imag-onologist & Sonologist

Dr. S. Kumar

MD (Pat)
Consultant Pathologist

Dr. Abhishek Kumar

MBBS, MD
Consultant Neuropatho Physiologist

Dr. Anjali

MBBS, MD
Consultant (TMT, EEG Specialist)

Dr. Kumari Suman

MBBS, DGO, MD
Consultant (TVS & HSG Specialist)

PRINTING MISTAKE SHOULD BE REPORTED BACK IMMEDIATELY/ यहाँ जन्म से पहले भ्रुण का लिंग जाँच नहीं होता है ।

