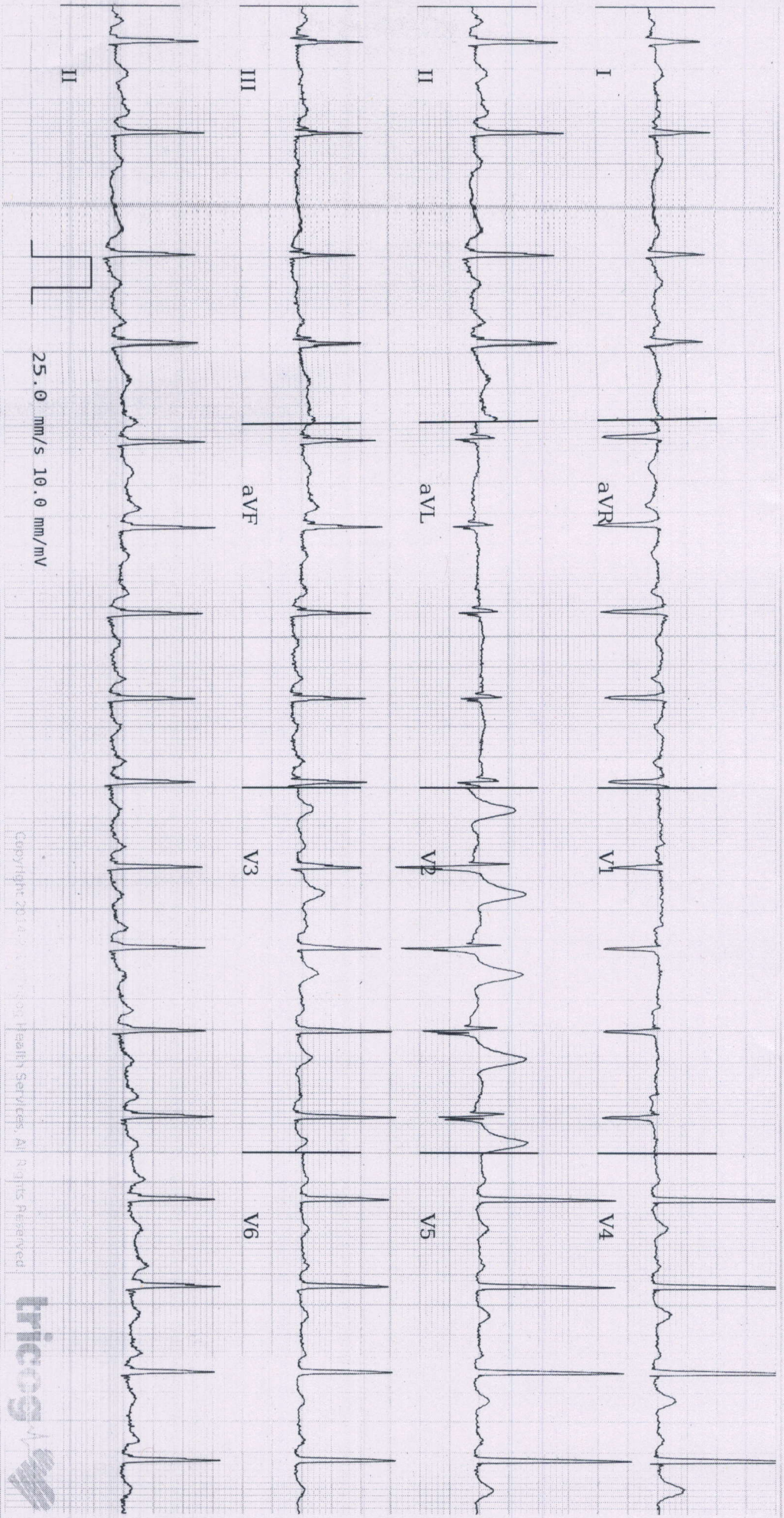


आयकर विभाग
INCOME TAX DEPARTMENT
MANTRI ATUL PURUSHOTTAM
PURUSHOTTAM MANTRI
13/07/1990
Permanent Account Number
BWHPM0492C
Signature
भारत सरकार
GOVT. OF INDIA
28072012

Rumita
DR. RUMITA SINGH
MBBS
Reg. No.: 67188

SHURBAN DIAGNOSTICS (I) PVT. LTD.
Plot No 22, Ground Floor, Raikar Bhavan,
Sector-17, Vashi, Navi Mumbai - 400 703
Tel 27884547 / 27864548.

Patient Name: **MANTRI ATUL PURUSHOTTAM** Date and Time: **26th Mar 22 12:16 PM**
Patient ID: **2208525659**



ECG Within Normal Limits: Sinus Tachycardia. Otherwise, Please correlate clinically.

Disclaimer: 1) Analysis in this report is based on ECG alone and should be used as an adjunct to clinical history, symptoms, and results of other invasive and non-invasive tests and must be interpreted by a qualified physician. 2) Patient vitals are as entered by the clinician and not derived from the ECG.

Age **31**

years mo

Gender **Male**

Heart Rate **1**

Patient Vitals

BP: **110/8**

Weight: **58 kg**

Height: **175 c**

Pulse: **NA**

Spo2: **NA**

Resp: **NA**

Others:

Measuremen

OSRD: **76ms**

QT: **324m**

QTc: **430m**

PR: **138m**

P-R-T: **69° 65**

REPORTED BY

Arundhan

Dr. Anand N Motwani
M.D (General Medicine)
Reg No 39329 M.M.C

PHYSICAL EXAMINATION REPORT

Patient Name	Mr. Atul Mantoji	Sex/Age	M / 31
Date	26/3/2022	CID	2208525659

History and Complaints

H/O epigastric pain 4 x Syss.
Indigestion

EXAMINATION FINDINGS:

Height (cms):	175 cm	Temp (0c):	Afebrile
Weight (kg):	58 kg	Skin:	NAD
Blood Pressure	110/80	Nails:	NAD
Pulse	90/min	Lymph Node:	NAD
BMI	18.9		

Systems :

Cardiovascular:	S ₁ S ₂ (N)
Respiratory:	(N) Breath sounds
Genitourinary:	NAD
GI System:	NAD
CNS:	NAD

Impression:

Abnormal

Advice:


CHIEF COMPLAINTS:

1)	Hypertension:	
2)	IHD	
3)	Arrhythmia	
4)	Diabetes Mellitus	
5)	Tuberculosis	
6)	Asthama	
7)	Pulmonary Disease	
8)	Thyroid/ Endocrine disorders	
9)	Nervous disorders	
10)	GI system	
11)	Genital urinary disorder	
12)	Rheumatic joint diseases or symptoms	
13)	Blood disease or disorder	
14)	Cancer/lump growth/cyst	
15)	Congenital disease	
16)	Surgeries	
17)	Musculoskeletal System	

PERSONAL HISTORY:

1)	Alcohol	NO
2)	Smoking	no
3)	Diet	Vegn.
4)	Medication	no

SUBURBAN DIAGNOSTICS (I) PVT. LTD.
 Shop No 22, Ground Floor, Raikar Bhavan,
 Sector-17, Vashi, Navi Mumbai - 400 703
 Tel 27884547 / 27864548.


DR. RUMITA SINGH
MBBS
 Reg. No.: 67188

Date:- 26/3/2022

CID: 2208525659

Name:- Atul Manoj

Sex / Age: M / 31

EYE CHECK UP

Chief complaints:

—

Systemic Diseases:

—

Past history:

—

Unaided Vision:

(R) 6/9 N₆ (L) 6/9 N₆

Aided Vision:

Refraction:

(Right Eye)

(Left Eye)

	Sph	Cyl	Axis	Vn	Sph	Cyl	Axis	Vn
Distance								
Near								

Colour Vision: Normal / Abnormal

Remark:

Rumita

SUBURBAN DIAGNOSTICS (I) PVT. LTD.
Shop No 22, Ground Floor, Raikar Bhavan,
Sector-17, Vashi, Navi Mumbai - 400 703
Tel 27884547 / 27864548.

DR. RUMITA SINGH
MBBS
Reg. No.: 67188

CID#	: 2208525659	SID#	: 177805002890
Name	: MR.MANTRI ATUL PURUSHOTTAM	Registered	: 26-Mar-2022 / 09:56
Age / Gender	: 31 Years/Male	Collected	: 26-Mar-2022 / 09:56
Consulting Dr.	: -	Reported	: 26-Mar-2022 / 19:42
Reg.Location	: Vashi (Main Centre)	Printed	: 26-Mar-2022 / 20:04

USG WHOLE ABDOMEN

LIVER :

The liver is normal in size, shape and smooth margins. It shows normal parenchymal echo pattern. The intra hepatic biliary and portal radical appear normal. No evidence of any intra hepatic cystic or solid lesion seen. The main portal vein and CBD appears normal.

GALL BLADDER :

The gall bladder is physiologically distended and appears normal. No evidence of gall stones or mass lesions seen

PANCREAS :

The pancreas well visualised and appears normal.
No evidence of solid or cystic mass lesion is noted.

KIDNEYS :

Both the kidneys are normal in size shape and echotexture.
No evidence of any calculus, hydronephrosis or mass lesion seen.
Right kidney measures 8.5 x 3.3 cms. Left kidney measures 9.7 x 4.6 cms.

SPLEEN :

The spleen is normal in size (7.3 cm) and shape and echotexture.
No evidence of focal lesion is noted. There is no evidence of any lymphadenopathy or ascitis.

URINARY BLADDER :

The urinary bladder is partially distended. It shows thin walls and sharp mucosa.
No evidence of calculus is noted. No mass or diverticulum is seen.

PROSTATE :

The prostate is normal in size and echotexture. It measures 3.4 x 3.2 x 3.0 cms and weighs 17.7 gms.

IMPRESSION :

No Significant abnormality is detected.

*** End Of Report ***

Famila

CID# : 2208525659
Name : MR.MANTRI ATUL PURUSHOTTAM
Age / Gender : 31 Years/Male
Consulting Dr. : -
Reg.Location : Vashi (Main Centre)

SID# : 177805002890
Registered : 26-Mar-2022 / 09:56
Collected : 26-Mar-2022 / 09:56
Reported : 26-Mar-2022 / 19:42
Printed : 26-Mar-2022 / 20:04

Dr.Jamila Fanii
RADIOLOGIST

CID# : 2208525659
Name : MR.MANTRI ATUL PURUSHOTTAM
Age / Gender : 31 Years/Male
Consulting Dr. : -
Reg.Location : Vashi (Main Centre)

SID# : 177805002890
Registered : 26-Mar-2022 / 09:56
Collected : 26-Mar-2022 / 09:56
Reported : 26-Mar-2022 / 18:23
Printed : 26-Mar-2022 / 20:03

X-RAY CHEST PA VIEW

The lung fields are clear with no parenchymal lesion.

The cardiothoracic ratio is maintained and the cardiac outline is normal

The domes of the diaphragm are normal.


The cardio and costophrenic angles are clear.

Bony thorax is normal.

IMPRESSION:

No significant abnormality detected.

*** End Of Report ***



Dr. Jamila Fanii
RADIOLOGIST