



# SHREE RAM MULTISPECIALITY HOSPITAL

L o k a h S a m a s t a S u k h i n o B h a v a n t u

Near Railway Under Bridge, Basant Vihar Gate No. 1, Gondwara Chowk, Gudhiyari, Raipur (C.G.)  
Phone: 0771-4343161, 08404840479 Email: Shreeramhospital.op@gmail.com



PT. NAME : MRS. ANJANA PRASAD AGE/SEX : 55Y 0M 0D/FEMALE BILL NO. : 790  
 GUARDIAN : MR. ALOK KUMAR MOBILE NO. : 9440877087 DATE : 17-Feb-2024  
 DOCTOR : DR. UMESH MIRJHA REFER-BY : SELF TIME : 09:37 AM  
 H. TARIFF : SHREE RAM MULTISPECIALITY HOS UHID : SRMH-24021859 IP/OP NO. : O20240000272  
 ADDRESS : ADARSH NAGAER MOWA SARDHOO BARCODE : 6872581

NO. : 1

SN	ITEM/PROCEDURE NAME	S. CODE	RATE	QTY	TOTAL
1	<b>General, Eye, Dental, Gynae, Dietician, ENT</b> CBC with ESR, Urine analysis Blood Group, BMI, Blood Sugar & Urine Sugar Fasting, Blood Sugar - Post Prandial, Urine Sugar PP, Hba1c, TSH, T3, T4, Triglycerides, Cholesterol Total, HDL, LDL, VLDL, LDL/HDL Ratio, Cholesterol Total / HDL Ratio, Uric Acid, BUN, Creatinine, BUN/Creatinine Ratio, Total Protein, Bilirubin Total & Direct and Indirect, Alkaline Phosphatase, Albumin, Globulin, A:G Ratio, Serum Protein, GGT, AST/ALT Ratio, ECG, (2D or TMT), X Ray Chest, Ultrasound, Pap Smear, Mamography		2,600.00	1.00	2,600.00
<b>General, Eye, Dental, Gynae, Dietician, ENT TOTAL :</b>					1.00 2,600.00
<b>GRAND TOTAL :</b>					1.00 2,600.00

In Words -  
Two Thousand Six Hundred Rs. Only/-

SERVICE BY : TARNI  
Authorized Signature



Payment Mode	TOTAL BILL AMOUNT :	2,600.00
	TOTAL DISCOUNT :	0.00
Payment Code	NET BILL AMOUNT :	2,600.00
	TOTAL PAID AMOUNT :	0.00
	TOTAL DUE AMOUNT :	2,600.00



# Shree Ram Multispeciality Hospital (SRMH)

L o k a h S a m a s t a S u k h i n o B h a v a n t u

OPD - ID : 020240000272  
UH-ID : SRMH-24021859

PT. TYPE : FREE  
PRINT DATE : 17-02-2024 / 09:54:49AM  
TOKEN NO. : 1

PATIENT NAME : MRS. ANJANA PRASAD	DEPARTMENT : MEDICINE
AGE / SEX : 55-Y 0-M 0-D / FEMALE	CONSULTANT : DR. AJIT KUMAR
DOB : none	CONSULT-DATE : 17-Feb-2024 - 09:05 AM
MOB-NO : 9440877087	COMPANY NAME : SHREE RAM MULTISPECIALITY HOSPITAL
GUARDIAN NAME : W/o MR. ALOK KUMAR	OPD PAID FEE : 0.00
ADDRESS : ADARSH NAGAER MOWA SARDHOO, RAIPUR, CG	

Weight : 79.2kg Temp : 36.2F B.P. : 120/70 Pulse : 83 SPO2 : 98%



6872581

\* work as a professor  
in Kavalpara Sarkar, inst.  
(CAAFI)  
CAR - work

- Normal bowel and bladder.  
- Inadequate sleep.  
- ECG - work.

Diagnosis - Hypothyroidism  
- Dysmenorrhea :: last 2 months.  
- H/o - Heavy bleed in last 2 time  
- Cough and expectoration, since long.  
- Hot flashes since long.  
- Constipation, also having some pruritic over  
Anol region.  
- Iron & Supplementation op. Breathless during rest.  
- All discussions given all in seen.

Dr. Ajit Kumar  
MBBS, MD  
CGMC 13960/2023  
SRMH, RAIPUR

FOLLOW-UP DATE :

ADVICE FOR ADMISSION  YES  NO

Near Railway Under Bridge, Basant Vihar Gate No. 1, Gondwara Chowk, Gudhiyari, Raipur (Chhattisgarh)

0771-43 43 161, 0771-43 40 162, 8404 8404 79

shreeramhospital.op@gmail.com www.srmhraipur.com



asg **ASG EYE HOSPITALS**  
meet the experts

Date (OP NO): 17-02-2024 (ORA017035)

Name: Mrs ANJANA PRASAD

Age (Gender): 53Y | DOM | DOD (Female)

Consultant: Dr. Praphull Dewangan

Add: Raipur, Chattisgarh, India



MRD: RAIP100465

MOB: 9440877087

Age

Sex

M F

Patient Name

MR No.

IOP

Right Eye 16

Left Eye 15

mm  
hg

6/18 P

6/6 P

Right Eye

Left Eye

VISION 20/20

Diagnosis

(Bb) Ref. error

Adn

① glasses

② bc: cellveoth yd 47d (30)  
oooo

Refcos / Gently

Seal and Signature of the treating Doctor

NOT VALID FOR MEDICO-LEGAL PURPOSE

REGISTER NOW

1800 1200 111

हैं। जिससे

नहीं होता है।

arement

कारण है  
द्वारा बच्चों को  
बचाया



# Shree Ram Multispeciality Hospital (SRMH)

L o k a h S a m a s t a S u k h i n o B h a v a n t u

OPD - ID : 020240000273  
UH-ID : SRMH-24021859

PT. TYPE : NEW REGISTRATION  
PRINT DATE : 17-02-2024 / 11:00

TOKEN NO. : 1

PATIENT NAME	: MRS. ANJANA PRASAD	DEPARTMENT	: DENTAL
AGE / SEX	: 55-Y 0-M 0-D / FEMALE	DOB	: none
CONSULT-DATE	: 17-Feb-2024 - 11:00 AM		
MOB-NO	: 9440877087	COMPANY NAME	: MEDIWHEEL FULL BODY ANNUAL PLUS CHECK
GUARDIAN NAME	: W/o MR. ALOK KUMAR	OPD PAID FEE	: 0.00
ADDRESS	: ADARSH NAGAER MOWA SARDHOO, RAIPUR, CG		
Weight :	Temp :	B.P. :	Pulse :
			SPO2 :

Please indicate whether you are presently suffering from anyone of the following symptoms:

Oral Health Status:

- Yes  No Dental Sealants Present on Permanent Molars
- Yes  No Caries Experience / Restoration History : A filling (Temporary / Permanent) OR a Tooth that is missing because it was extracted as a result of caries .
- Yes  No Untreated Caries/ Open Treatment Plan
- Yes  No Urgent Treatment: abscess, Nerve Exposure, Advanced Disease State, Signs of Symptoms that include pain/ infection / swelling

DENTAL

Treatment Needs:

- Restorative Care- Fillings, crowns, etc.
- Preventative Care-prophylaxis, sealants, fluoride Treatment
- Sedation / Surgery Needs to Complete Treatment

Present chief complaints:- *No significant complaints at present*

Dr. Signature

📍 Near Railway Under Bridge, Basant Vihar Gate No. 1, Gondwara Chowk, Gudhiyari, Raipur (Chhattisgarh)

☎ 0771-43 43 161, 0771-43 40 162, 📞 8404 8404 79  
✉ shreeramhospital.op@gmail.com 🌐 www.srmhraipur.com





# Shree Ram Multispeciality Hospital (SRMH)

Lokah Samasta Sukhino Bhavantu

OPD - ID : 020240000273	PT. TYPE : NEW REGISTRATION
UH-ID : SRMH-24021859	PRINT DATE : 17-02-2024 / 11:00
TOKEN NO. : 1	
PATIENT NAME : MRS. ANJANA PRASAD	DEPARTMENT : ENT
AGE / SEX : 55-Y 0-M 0-D / FEMALE	DOB : none
CONSULT-DATE : 17-Feb-2024 - 11:00 AM	
MOB-NO : 9440877087	COMPANY NAME : MEDIWHEEL FULL BODY ANNUAL PLUS CHECK
GUARDIAN NAME : W/o MR. ALOK KUMAR	OPD PAID FEE : 0.00
ADDRESS : ADARSH NAGAER MOWA SARDHOO, RAIPUR, CG	
Weight :	Temp :
B.P. :	Pulse :
	SPO2 :

Please indicate whether you are presently suffering from anyone of the following symptoms:

Ears, Nose, Mouth, Throat

Yes No

ENT

Ear pain	0	PPPPPPPP
Ear itch	0	PPPPPPPP
Ear drainage	0	PPPPPPPP
Dizziness/ Loss of balance	0	PPPPPPPP
Loss of Hearing	0	PPPPPPPP
Popping Noise	0	PPPPPPPP
Tinnitus	0	PPPPPPPP
Nosebleeds	0	PPPPPPPP
Post-nasal Drip	0	PPPPPPPP
Sinus pain	0	PPPPPPPP
Sinus pressure	0	PPPPPPPP
Nasal congestion	0	PPPPPPPP
Loss of smell/taste	0	PPPPPPPP
Hoarseness	0	PPPPPPPP
Sore Throat	0	PPPPPPPP
Throat tickle	0	PPPPPPPP
Dry Mouth / Throat	0	PPPPPPPP
Throat clearing	0	PPPPPPPP
Snoring	0	PPPPPPPP

Present chief complaints:- *there is no complain*

Dr. S. 

Near Railway Under Bridge, Basant Vihar Gate No. 1, Gondwara Chowk, Gudhiyari, Raipur (Chhattisgarh)

☎ 0771-43 43 161, 0771-43 40 162, 📞 8404 8404 79  
✉ shreeramhospital.op@gmail.com 🌐 www.srmhraipur.com





# Shree Ram Multispeciality Hospital (SRMH)

Lokah Samasta Sukhino Bhavantu

OPD - ID : 020240000273  
UH-ID : SRMH-24021859

PT. TYPE : NEW REGISTRATION  
PRINT DATE : 17-02-2024 / 11:02:51AM  
TOKEN NO. : 1

PATIENT NAME	: MRS. ANJANA PRASAD	DEPARTMENT	: OBS & GYNE
AGE / SEX	: 55-Y 0-M 0-D / FEMALE	CONSULTANT	: DR. ARPITA NAMDEV YADAV
DOB	: none	CONSULT-DATE	: 17-Feb-2024 - 11:00 AM
MOB-NO	: 9440877087	COMPANY NAME	: MEDIWHEEL FULL BODY ANNUAL PLUS C
GUARDIAN NAME	: W/o MR. ALOK KUMAR	OPD PAID FEE	: 0.00
ADDRESS	: ADARSH NAGAER MOWA SARDHOO, RAIPUR, CG		

Weight : 79.2 kg    Temp : 96.2°f    B.P. 120/70    Pulse 83    SPO2 98.1



CO - Irregular menstrual cycle.  
- Constipation  
- Stress incontinence.

KCO Hypothyroid on TTT 75mcg/day  
DM2 2 Jan  
MH = 5/10  
30-90d.  
Family → DM  
Bilateral breasts  
Syc - no discharge

P/L2 → Both FND  
d/c → 2/3 yr.  
Not pregnant

- d/c (Pap's)  
- Urine  $\leq$  4  
- USG  $\leftarrow$  whole abd + pelvis.

PA → Syc  
PLS →  $Cx < \frac{D}{B}$ , Mucoid discharge  
P/L2 CW AV, NR, firm  
mobile, Non tender  
B d/c taken

FOLLOW-UP DATE :  
ADVICE FOR ADMISSION    YES     NO

📍 Near Railway Under Bridge, Basant Vihar Gate No. 1, Gondwara Chowk, Gudhiyari, Raipur (Chhattisgarh)

☎ 0771-43 43 161, 0771-43 40 162, 📞 8404 8404 79  
✉ shreeramhospital.op@gmail.com    🌐 www.srmhraipur.com



Adw Kiegel's

- Review & report

- Tas ~~A~~ Wispus 13DX 74

o—o-

*Amrita*  
Dr. Amrita Namdeo Yadav  
MBBS, MD (Obstetrics & Gynecologist)  
CGMC 176/2015  
SRM, RAIPUR

To,  
The Coordinator,  
Mediwheel (Arcofemi Healthcare Limited)  
Helpline number: 011- 41195959

Dear Sir / Madam,

**Sub: Annual Health Checkup for the employees of Bank of Baroda**

This is to inform you that the following spouse of our employee wishes to avail the facility of Cashless Annual Health Checkup provided by you in terms of our agreement.

PARTICULARS OF HEALTH CHECK UP BENEFICIARY	
NAME	ANJANA PRASAD
DATE OF BIRTH	01-08-1971
PROPOSED DATE OF HEALTH CHECKUP FOR EMPLOYEE SPOUSE	17-02-2024
BOOKING REFERENCE NO.	23M161399100089542S
<b>SPOUSE DETAILS</b>	
EMPLOYEE NAME	MR. KUMAR ALOK
EMPLOYEE EC NO.	161399
EMPLOYEE DESIGNATION	SINGLE WINDOW OPERATOR B
EMPLOYEE PLACE OF WORK	RAIPUR, PANDHARI
EMPLOYEE BIRTHDATE	11-08-1964

This letter of approval / recommendation is valid if submitted along with copy of the Bank of Baroda employee id card. This approval is valid from **08-02-2024** till **31-03-2024**. The list of medical tests to be conducted is provided in the annexure to this letter. Please note that the said health checkup is a **cashless facility** as per our tie up arrangement. We request you to attend to the health checkup requirement of our employee's spouse and accord your top priority and best resources in this regard. The EC Number and the booking reference number as given in the above table shall be mentioned in the invoice, invariably.

We solicit your co-operation in this regard.

Yours faithfully,

Sd/-

**Chief General Manager  
HRM Department  
Bank of Baroda**

(Note: This is a computer generated letter. No Signature required. For any clarification, please contact Mediwheel (Arcofemi Healthcare Limited))



**SUGGESTIVE LIST OF MEDICAL TESTS**

<b>FOR MALE</b>	<b>FOR FEMALE</b>
CBC	CBC
ESR	ESR
Blood Group & RH Factor	Blood Group & RH Factor
Blood and Urine Sugar Fasting	Blood and Urine Sugar Fasting
Blood and Urine Sugar PP	Blood and Urine Sugar PP
Stool Routine	Stool Routine
<b>Lipid Profile</b>	<b>Lipid Profile</b>
Total Cholesterol	Total Cholesterol
HDL	HDL
LDL	LDL
VLDL	VLDL
Triglycerides	Triglycerides
HDL / LDL ratio	HDL / LDL ratio
<b>Liver Profile</b>	<b>Liver Profile</b>
AST	AST
ALT	ALT
GGT	GGT
Bilirubin (total, direct, indirect)	Bilirubin (total, direct, indirect)
ALP	ALP
Proteins (T, Albumin, Globulin)	Proteins (T, Albumin, Globulin)
<b>Kidney Profile</b>	<b>Kidney Profile</b>
Serum creatinine	Serum creatinine
Blood Urea Nitrogen	Blood Urea Nitrogen
Uric Acid	Uric Acid
HBA1C	HBA1C
Routine urine analysis	Routine urine analysis
USG Whole Abdomen	USG Whole Abdomen
<b>General Tests</b>	<b>General Tests</b>
X Ray Chest	X Ray Chest
ECG	ECG
2D/3D ECHO / TMT	2D/3D ECHO / TMT
Stress Test	Thyroid Profile (T3, T4, TSH)
PSA Male (above 40 years)	Mammography (above 40 years) and Pap Smear (above 30 years).
Thyroid Profile (T3, T4, TSH)	Dental Check-up consultation
Dental Check-up consultation	Physician Consultation
Physician Consultation	Eye Check-up consultation
Eye Check-up consultation	Skin/ENT consultation
Skin/ENT consultation	Gynaec Consultation

भारत सरकार  
Government of India

आधार प्रमाणिका  
Anjana Prasad  
जन्म तिथि/DOB: 01/07/1969  
लिंग/ GENDER: FEMALE

7629 2321 9006  
VID: 9158 4736 2313 6465

मेरा आधार, मेरी पहचान

भारतीय विशिष्ट पहचान प्राधिकरण  
Unique Identification Authority of India

पता:  
W/O आलोक कुमार, वार्ड नं.- 27, हनुमन्ते कृपा निवास,  
आदर्श नगर, जनेसत्ता प्रेस के पास, मोवा, सर्धु (सर्धु),  
रायपुर,  
छत्तीसगढ़ - 492014

Address:  
W/O Alok Kumar, Ward No.- 27,  
Hanumante Kripa Niwas, Adarsh Nagar,  
Near Jansatta Press, Mowa, Sardhu  
(sardhu), Raipur,  
Chhattisgarh - 492014

7629 2321 9006  
VID: 9158 4736 2313 6465

QR Code with Photograph

Ma No. - 9440877087

**Mrs Anjana Prasad**

Age: 55 Years

Sex: Female

PID: 1534



**Sample Collected At:**

**Ref. By: Dr. ARPIT YADAV**



1763L45437

Registered: 17 Feb, 24 02:40 PM

Collected: 19 Feb, 24 04:38 PM

Reported: 19 Feb, 24 04:42 PM

**BUN / Creatinine Ratio PANAL**

Investigation	Observed Value	Unit	Biological Reference Interval
BUN			
BUN	10.33	mg/dL	7.00 - 20.00
Serum Creatinine	0.75	mg/dL	0.55 - 1.20
BUN / Creatinine Ratio	13:97		10:1 - 20:1



**Dr. D. Prasad**  
M.D.(Pathologist)

\*\*\*\*\*END OF REPORT\*\*\*\*\*



# Shree Ram Multispeciality Hospital (SRMH)

L o k a h S a m a s t a S u k h i n o B h a v a n t u

PT. NAME : MRS. ANJANA PRASAD  
MOBILE NO : 9440877087  
DOCTOR : DR. UMESH MIRJHA  
REFERRED BY : SELF

AGE / SEX : 55/FEMALE  
UH ID NO. : SRMH-24021859  
COLLECTION : 17-02-2024  
REPORTING : 17-Feb-2024

TEST NO  
264

## HAEMATOLOGY

TEST NAME

RESULT

UNIT

NORMAL VALUES

### ESR by Western Green

ESR (ERYTHROCYTE SENDIMENTATION RATE )


35

mm at end of 1 hr 0 - 30

-- End Of Report --

  
LAB TECHNICIAN

Note : This Report is not for medicolegal purpose

  
Dr. Dhananjay Prasad  
( MD PATHOLOGY )

📍 Near Railway Under Bridge, Basant Vihar Gate No. 1, Gondwara Chowk,  
Gudhiyari, Raipur (Chhattisgarh)

☎ 0771-43 43 161, 0771-43 40 162, 📞 8404 8404 79

✉ shreeramhospital.op@gmail.com 🌐 www.srmhraipur.com

24/7  
Emergency  
Services





# Shree Ram Multispeciality Hospital (SRMH)

L o k a h S a m a s t a S u k h i n o B h a v a n t u

PT. NAME : MRS. ANJANA PRASAD  
MOBILE NO : 9440877087  
DOCTOR : DR. UMESH MIRJHA  
REFERED BY : SELF


AGE / SEX : 55/FEMALE  
UH ID NO. : SRMH-24021859  
COLLECTION : 17-02-2024  
REPORTING : 17-Feb-2024  
TEST NO  
264

## HAEMATOLOGY

TEST NAME	RESULT	UNIT	NORMAL VALUES
<b>BLOOD GROUPING AND RH TYPING</b>			
BLOOD GROUP	"B"		-
RH FACTOR	POSITIVE		-

-- End Of Report --

LAB TECHNICIAN

  
 Dr. Dhananjay Prasad  
 ( MD PATHOLOGY )

Note : This Report is not for medicolegal purpose

Near Railway Under Bridge, Basant Vihar Gate No. 1, Gondwara Chowk, Gudhiyari, Raipur (Chhattisgarh)

0771-43 43 161, 0771-43 40 162, 8404 8404 79

shreeramhospital.op@gmail.com www.srmhraipur.com





# Shree Ram Multispeciality Hospital (SRMH)

L o k a h S a m a s t a S u k h i n o B h a v a n t u

PT. NAME : MRS. ANJANA PRASAD  
MOBILE NO : 9440877087  
DOCTOR : DR. UMESH MIRJHA  
REFERRED BY : SELF

AGE / SEX : 55/FEMALE  
UH ID NO. : SRMH-24021859  
COLLECTION : 17-02-2024  
REPORTING : 17-Feb-2024  
TEST NO : 264


## BIOCHEMISTRY

TEST NAME	RESULT	UNIT	NORMAL VALUES
<b>BLOOD SUGAR - FASTING AND PP</b>			
BLOOD SUGAR FASTING	93.2	mg/dL	60 - 120
BLOOD SUGAR PP	120.7	mg/dL	80 - 140

-- End Of Report --

LAB TECHNICIAN

Note : This Report is not for medicolegal purpose

  
Dr. Dhananjay Prasad  
( MD PATHOLOGY )

Near Railway Under Bridge, Basant Vihar Gate No. 1, Gondwara Chowk,  
Gudhiyari, Raipur (Chhattisgarh)

☎ 0771-43 43 161, 0771-43 40 162, 📞 8404 8404 79

✉ shreeramhospital.op@gmail.com 🌐 www.srmhraipur.com





# Shree Ram Multispeciality Hospital (SRMH)

L o k a h S a m a s t a S u k h i n o B h a v a n t u

PT. NAME : MRS. ANJANA PRASAD	AGE / SEX : 55/FEMALE	TEST NO
MOBILE NO : 9440877087	UH ID NO. : SRMH-24021859	264
DOCTOR : DR. UMESH MIRJHA	COLLECTION : 17-02-2024	
REFERRED BY : SELF	REPORTING : 17-Feb-2024	

## BIOCHEMISTRY

TEST NAME	RESULT	UNIT	NORMAL VALUES
<b>HBA1c (GLYCOSYLATED HEAMOGLOBIN)</b>			
HBA1c	4.56	%	Normal Range : <6% - Good Control : 6 - 7% - Fair Control : 7 - 8% - Unsatisfactory Control : 8-10% - Poor Control : >10% -
Estimated average plasma glucose	85.03	mg/dl	80 - 120

### Interpretation: As per American Diabetes Association(ADA)

Non diabetic adults >= 18 years	<5.7
At risk (prediabetes)	5.7 - 6.4
Diagnosing Diabetes	>= 6.5
Therapeutic goals for glycemic control	Good of Therapy > 19 years - <7.0 <19 years - <7.5

### NOTE:

- HbA1c reflects long term fluctuations in the blood glucose concentration
- A diabetic patient who is recently under good control may still have a high concentration of HbA1c. Converse is true for a diabetic previously under good control but now poorly controlled.


### Significance of Test:

HbA1c provides an index of average blood glucose levels over the past 8-12 weeks and is a much better indicator of long term glycemic control as compared to blood and urinary glucose determinations.

-- End Of Report --

  
LAB TECHNICIAN

Note : This Report is not for medicolegal purpose

  
Dr. Dhananjay Prasad  
( MD PATHOLOGY )

📍 Near Railway Under Bridge, Basant Vihar Gate No. 1, Gondwara Chowk,  
Gudhiyari, Raipur (Chhattisgarh)

☎ 0771-43 43 161, 0771-43 40 162, 📞 8404 8404 79

✉ shreeramhospital.op@gmail.com 🌐 www.srmhraipur.com





# Shree Ram Multispeciality Hospital (SRMH)

L o k a h S a m a s t a S u k h i n o B h a v a n t u

PT. NAME : MRS. ANJANA PRASAD  
MOBILE NO : 9440877087  
DOCTOR : DR. UMESH MIRJHA  
REFERRED BY : SELF

AGE / SEX : 55/FEMALE  
UH ID NO. : SRMH-24021859  
COLLECTION : 17-02-2024  
REPORTING : 17-Feb-2024  
TEST NO  
264

## BIOCHEMISTRY

TEST NAME	RESULT	UNIT	NORMAL VALUES
<b>LIPID PROFILE</b>			
CHOLESTEROL	135.7	mg / dl	150 - 220
SERUM TRIGLYCERIDE	189.2	mg / dl	60 - 165
HDL	36.5	mg / dl	35 - 80
LDL	61.36	mg/dL	90 - 160
VLDL	37.84	mg/dl	20 - 50
CHOLESTEROL / HDL RATIO	3.72	mg/dl	3.5 - 5.5
LDL/HDL Ratio	1.68	mg/dl	2.5 - 3.5
TRIGLYCERIDES/HDL RATIO	5.18	mg/dl	2.0 - 4.0

-- End Of Report --

LAB TECHNICIAN

Note : This Report is not for medicolegal purpose

Dr. Dhananjay Prasad  
( MD PATHOLOGY )

📍 Near Railway Under Bridge, Basant Vihar Gate No. 1, Gondwara Chowk,  
Gudhiyari, Raipur (Chhattisgarh)

☎ 0771-43 43 161, 0771-43 40 162, 📞 8404 8404 79

✉ shreeramhospital.op@gmail.com 🌐 www.srmhraipur.com







# Shree Ram Multispeciality Hospital (SRMH)

L o k a h S a m a s t a S u k h i n o B h a v a n t u

PT. NAME : MRS. ANJANA PRASAD  
MOBILE NO : 9440877087  
DOCTOR : DR. UMESH MIRJHA  
REFERRED BY : SELF

AGE / SEX : 55/FEMALE  
UH ID NO. : SRMH-24021859  
COLLECTION : 17-02-2024  
REPORTING : 17-Feb-2024  
TEST NO : 264


## BIOCHEMISTRY

TEST NAME	RESULT	UNIT	NORMAL VALUES
<b>URIC ACID</b>			
URIC ACID	4.97	mg/dL	2.5 - 6.8

-- End Of Report --

LAB TECHNICIAN

Note : This Report is not for medicolegal purpose

  
Dr. Dhnanjay Prasad  
( MD PATHOLOGY )

Near Railway Under Bridge, Basant Vihar Gate No. 1, Gondwara Chowk,  
Gudhiyari, Raipur (Chhattisgarh)

0771-43 43 161, 0771-43 40 162, 8404 8404 79

shreeramhospital.op@gmail.com www.srmhraipur.com





# Shree Ram Multispeciality Hospital (SRMH)

L o k a h S a m a s t a S u k h i n o B h a v a n t u

PT. NAME : MRS. ANJANA PRASAD  
MOBILE NO : 9440877087  
DOCTOR : DR. UMESH MIRJHA  
REFERRED BY : SELF


AGE / SEX : 55/FEMALE  
UH ID NO. : SRMH-24021859  
COLLECTION : 17-02-2024  
REPORTING : 17-Feb-2024  
TEST NO  
264

## BIOCHEMISTRY

TEST NAME	RESULT	UNIT	NORMAL VALUES
	<b>CREATININE</b>		
CREATININE	0.82	mg / dl	0.6 - 1.2

-- End Of Report --

  
LAB TECHNICIAN

  
Dr. Dhananjay Prasad  
( MD PATHOLOGY )

Note : This Report is not for medicolegal purpose

📍 Near Railway Under Bridge, Basant Vihar Gate No. 1, Gondwara Chowk,  
Gudhiyari, Raipur (Chhattisgarh)

☎ 0771-43 43 161, 0771-43 40 162, 📞 8404 8404 79

✉ shreeramhospital.op@gmail.com 🌐 www.srmhraipur.com

24x7  
Emergency  
Services





# Shree Ram Multispeciality Hospital (SRMH)

L o k a h S a m a s t a S u k h i n o B h a v a n t u

PT. NAME : MRS. ANJANA PRASAD  
MOBILE NO : 9440877087  
DOCTOR : DR. UMESH MIRJHA  
REFERRED BY : SELF

AGE / SEX : 55/FEMALE  
UH ID NO. : SRMH-24021859  
COLLECTION : 17-02-2024  
REPORTING : 17-Feb-2024  
TEST NO  
264

## BIOCHEMISTRY

TEST NAME	RESULT	UNIT	NORMAL VALUES
<b>Total Protein</b>			
TOTAL PROTEIN	6.39	g / dl	6 - 8
ALBUMIN	3.89	g/dl	4.1 - 5.3
GLOBULIN	2.80	g / dl	2 - 3.5
A.G.RATIO	1.38		1 - 2.5

-- End Of Report --

LAB TECHNICIAN

Note : This Report is not for medicolegal purpose

Dr. Dhananjay Prasad  
( MD PATHOLOGY )

Near Railway Under Bridge, Basant Vihar Gate No. 1, Gondwara Chowk,  
Gudhiyari, Raipur (Chhattisgarh)

☎ 0771-43 43 161, 0771-43 40 162, 📞 8404 8404 79

✉ shreeramhospital.op@gmail.com 🌐 www.srmhraipur.com

24/7  
Emergency  
Services





# Shree Ram Multispeciality Hospital (SRMH)

L o k a h S a m a s t a S u k h i n o B h a v a n t u

PT. NAME : MRS. ANJANA PRASAD  
MOBILE NO : 9440877087  
DOCTOR : DR. UMESH MIRJHA  
REFERRED BY : SELF

AGE / SEX : 55/FEMALE  
UH ID NO. : SRMH-24021859  
COLLECTION : 17-02-2024  
REPORTING : 17-Feb-2024  
TEST NO  
264


## BIOCHEMISTRY

TEST NAME	RESULT	UNIT	NORMAL VALUES
<b>BILIRUBIN</b>			
BILIRUBIN TOTAL	0.63	mg/dl	0.2 - 1
BILIRUBIN DIRECT	0.29	mg/dl	0.1 - 0.6
BILIRUBIN INDIRECT	0.34	mg/dl	0.1 - 0.4

-- End Of Report --

LAB TECHNICIAN

Note : This Report is not for medicolegal purpose

  
Dr. Dhananjay Prasad  
( MD PATHOLOGY )

Near Railway Under Bridge, Basant Vihar Gate No. 1, Gondwara Chowk,  
Gudhiyari, Raipur (Chhattisgarh)

☎ 0771-43 43 161, 0771-43 40 162, 📞 8404 8404 79  
✉ shreeramhospital.op@gmail.com 🌐 www.srmhraipur.com





# Shree Ram Multispeciality Hospital (SRMH)

Lokah Samasta Sukhino Bhavantu

PT. NAME : MRS. ANJANA PRASAD  
MOBILE NO : 9440877087  
DOCTOR : DR. UMESH MIRJHA  
REFERED BY : SELF

AGE / SEX : 55/FEMALE  
UH ID NO. : SRMH-24021859  
COLLECTION : 17-02-2024  
REPORTING : 17-Feb-2024  
TEST NO : 264


## BIOCHEMISTRY

TEST NAME	RESULT	UNIT	NORMAL VALUES
<b>ALKALINE PHOSPHATASE</b>			
ALKALINE PHOSPHATASE	176.7	U/L	0 - 240

-- End Of Report --

LAB TECHNICIAN

Note : This Report is not for medicolegal purpose

  
Dr. Dhananjay Prasad  
( MD PATHOLOGY )

📍 Near Railway Under Bridge, Basant Vihar Gate No. 1, Gondwara Chowk,  
Gudhiyari, Raipur (Chhattisgarh)

☎ 0771-43 43 161, 0771-43 40 162, 📞 8404 8404 79  
✉ shreeramhospital.op@gmail.com 🌐 www.srmhraipur.com





# Shree Ram Multispeciality Hospital (SRMH)

L o k a h S a m a s t a S u k h i n o B h a v a n t u

PT. NAME : MRS. ANJANA PRASAD  
MOBILE NO : 9440877087  
DOCTOR : DR. UMESH MIRJHA  
REFERRED BY : SELF

AGE / SEX : 55/FEMALE  
UH ID NO. : SRMH-24021859  
COLLECTION : 17-02-2024  
REPORTING : 17-Feb-2024  
TEST NO  
264

## BIOCHEMISTRY

TEST NAME	RESULT	UNIT	NORMAL VALUES
	<b>SGOT/SGPT</b>		
SGOT	28.1	U/L	0 - 46
SGPT	24.4	U/L	0 - 40

-- End Of Report --

LAB TECHNICIAN

Note : This Report is not for medicolegal purpose

Dr. Dhananjay Prasad  
(MD PATHOLOGY)

📍 Near Railway Under Bridge, Basant Vihar Gate No. 1, Gondwara Chowk,  
Gudhiyari, Raipur (Chhattisgarh)

☎ 0771-43 43 161, 0771-43 40 162, 📞 8404 8404 79

✉ shreeramhospital.op@gmail.com 🌐 www.srmhraipur.com

24x7  
Emergency  
Services





# Shree Ram Multispeciality Hospital (SRMH)

L o k a h S a m a s t a S u k h i n o B h a v a n t u

PT. NAME : MRS. ANJANA PRASAD  
MOBILE NO : 9440877087  
DOCTOR : DR. UMESH MIRJHA  
REFERRED BY : SELF

AGE / SEX : 55/FEMALE  
UH ID NO. : SRMH-24021859  
COLLECTION : 18-02-2024  
REPORTING : 18-Feb-2024  
TEST NO : 264


## CLINICAL PATHOLOGY

TEST NAME	RESULT	UNIT	NORMAL VALUES
<b>URINE SUGAR FASTING AND PP</b>			
URINE SUGAR - FASTING	Absent		Absent -
URINE SUGAR - PP	Absent		Absent -

-- End Of Report --

LAB TECHNICIAN

Note : This Report is not for medicolegal purpose

  
 Dr. Dhananjay Prasad  
 ( MD PATHOLOGY )

📍 Near Railway Under Bridge, Basant Vihar Gate No. 1, Gondwara Chowk, Gudhiyari, Raipur (Chhattisgarh)

☎ 0771-43 43 161, 0771-43 40 162, 📞 8404 8404 79

✉ shreeramhospital.op@gmail.com 🌐 www.srmhraipur.com





# Shree Ram Multispeciality Hospital (SRMH)

L o k a h S a m a s t a S u k h i n o B h a v a n t u

PT. NAME : MRS. ANJANA PRASAD  
MOBILE NO : 9440877087  
DOCTOR : DR. UMESH MIRJHA  
REFERRED BY : SELF

AGE / SEX : 55/FEMALE  
UH ID NO. : SRMH-24021859  
COLLECTION : 17-02-2024  
REPORTING : 17-Feb-2024  
TEST NO : 264

## CLINICAL PATHOLOGY

TEST NAME	RESULT	UNIT	NORMAL VALUES
<b>URINE ROUTINE AND MICROSCOPY</b>			
<b>PHYSICAL EXAMINATION</b>			
QUANTITY	20	ml	-
COLOUR	Pale Yellow		Pale Yellow -
APPEARANCE	Clear		Clear -
REACTION	Acitic		Acitic -
<b>CHEMICAL EXAMINATION</b>			
ALBUMIN	Absent		Absent -
SUGAR	Absent		Absent -
KETONE	Absent		Absent -
BILE SALT	Absent		Absent -
BILE PIGMENT	Absent		Absent -
<b>MICROSCOPIC EXAMINATION</b>			
PUS CELLS	2-4	/hpf	2 - 5
EPITHELIAL CELLS	3-5	/hpf	1 - 5
RBC	Nil	/hpf	0 - 3
CAST	Nil	/lpf	Nil -
YEAST	Nil		Nil -
CRYSTAL	Nil	/lpf	Nil -
Bacteria	Nil		Nil -
OTHERS	-		-

-- End Of Report --

LAB TECHNICIAN

Note : This Report is not for medicolegal purpose

Dr. Dhananjay Prasad  
( MD PATHOLOGY )

📍 Near Railway Under Bridge, Basant Vihar Gate No. 1, Gondwara Chowk, Gudhiyari, Raipur (Chhattisgarh)

☎ 0771-43 43 161, 0771-43 40 162, 📞 8404 8404 79

✉ shreeramhospital.op@gmail.com 🌐 www.srmhraipur.com





**Mrs Anjana Prasad**

Age: 55 Years

Sex: Female

PID: 1534



Sample Collected At:

Ref. By: Dr. ARPITA YADAV



1741L45437

Registered: 17 Feb, 24 02:20 PM

Collected: 17 Feb, 24 02:30 PM

Reported: 17 Feb, 24 06:38 PM

**TFT****Thyroid Function Test (TFT)**

Investigation	Observed Value	Unit	Biological Reference Interval
<b>THYROID SERUM HORMONS</b>			
Serum Triiodothyronine (T3)	1.23	ng/mL	0.89 - 1.87
Serum thyroxine (T4)	9.06	ug/dL	5.1 - 14.28
Thyroid Stimulating Hormone (TSH)	3.87	μIU/mL	0.66 - 5.67

**Comments:-**

(i) Ethnicity, iodine intake, gender, age, body mass index and Exercise influences the reference range of Thyroid hormones and serum TSH concentrations.

(ii) Changes in Thyroid Hormones (especially T3) and TSH may be seen as early as 24 hours after the onset of non-thyroidal illness. (Poor nutrition/starvation, sepsis, burns, malignancy, myocardial infarction, post-surgery, and with chronic liver and renal disease)

(iii) Serum total T4 and T3 concentrations increase to approximately 150% of non-pregnant values – this occurs during the first half of pregnancy and is maintained thereafter until parturition. Free T4 concentrations also change during pregnancy: in the first trimester a transient rise is often observed.

(iv) Measurement of FT4 and FT3 is best avoided in patients receiving heparin therapy. (When indicated, blood sample should be taken 10 hours after the last injection of heparin, and analyzing it without delay, can reduce the risk of artifactual hyperthyroxinaemia.)

(v) Phenytoin, carbamazepine and furosemide cause artifactual increase in free T4 (FT4) and decrease in total T4.

Dr. D. Prasad  
M.D.(Pathologist)

\*\*\*\*\*END OF REPORT\*\*\*\*\*

Mrs - Anjana Bhasin

~~Dr. Anjana Bhasin~~

F 56y 072Kg

09:31 AM

17/02/2024

AUTO 12LS BLC-Y

25 mm/s

10mm/mV

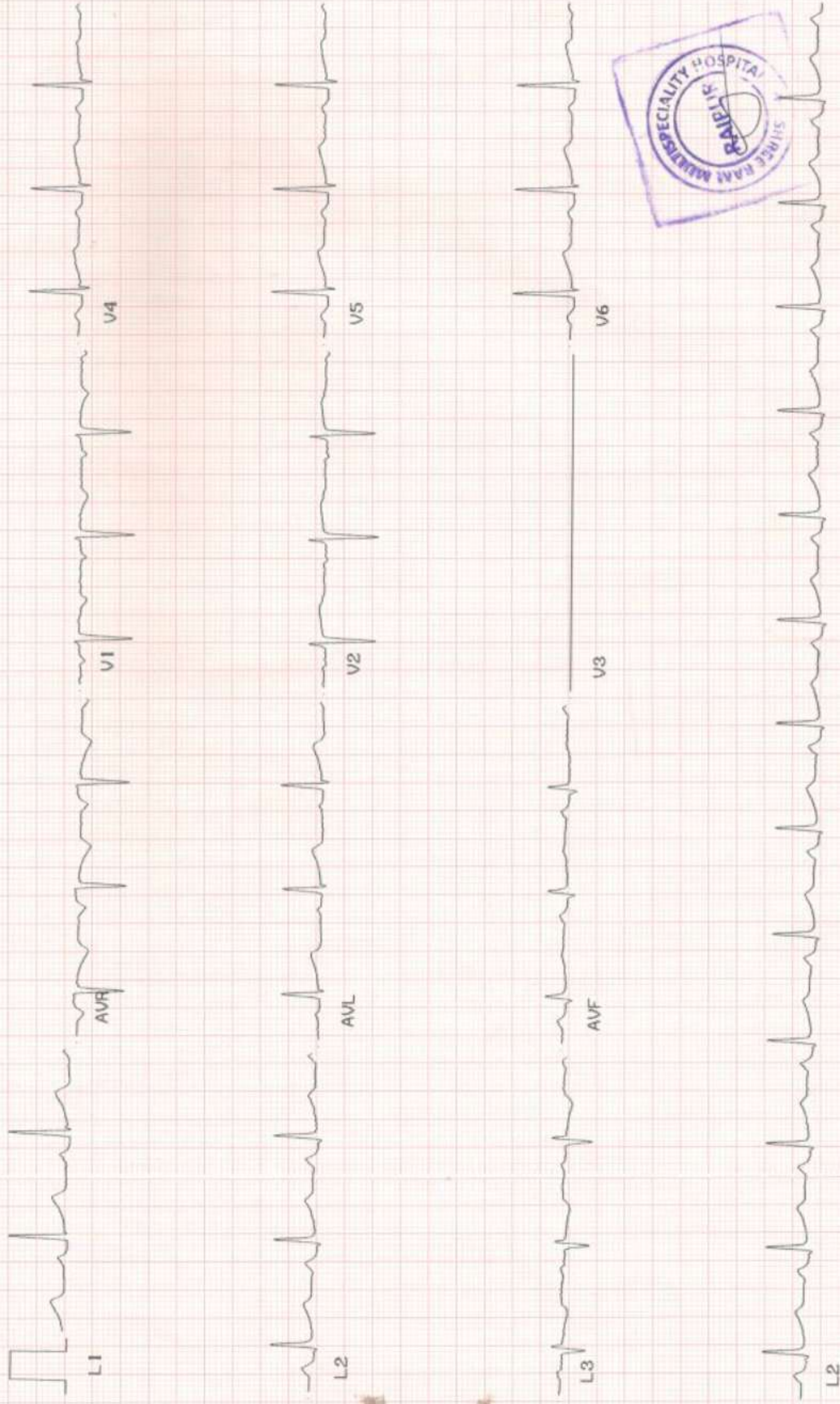
0.1 - 35Hz

50Hz ReJ-Y

BLC-Y

P	=	87	ms	QT/QTc	=	86%
QRS	=	95	ms	QT/RR	=	49%
PR	=	170	ms	QRS axis	=	17°
QT	=	367	ms	P axis	=	43°
QTc	=	426	ms	T axis	=	17°

To be clinically correlated: HR = 81bpm  
Lead Open. No Analysis done.





# Dr. Agrawal Onco-Path Diagnostics & Research Centre

\*Near SBI Shantinagar Branch, Main Road, New Shanti Nagar, Shankar Nagar, RAIPUR-492001 (C.G.)

\*Infront of AIIMS Hospital Gate No.-3, Beside Gurudwara Tatibandh, RAIPUR-492001 (C.G.)

E-mail : dragrawaloncolab@gmail.com, Web. : www.agrawaloncopathlab.com

◆◆◆◆ **Dr. Rajesh Agrawal** M.D. Pathology PGI, Chandigarh ◆◆◆◆

**\*NOTE:** Sample has been processed using Automatic liquid based cytology Prep-stain system

BD SurePath(FDA approved Technology)

## GYNECOLOGICAL CYTOLOGY FORM

---

CASE NO : C-273/24

COLLECTION/REPORTINGDATE: 17-02/20-02-2024

LBC/CONVENTION : LIQUID BASED CYTOLOGY

NEW/FOLLOW-UP: NEW

CYTOLOGY : CERVICAL (PAP) SMEAR

AGE/SEX : 55 YEAR/F

NAME : MRS. ANJANA PRASAD

REF. BY : DR. ARPITA NAMDEV (SHRI RAM MULTISPECIALITY HOSPITAL)

---



# Dr. Agrawal Onco-Path Diagnostics & Research Centre

\*Near SBI Shantinagar Branch, Main Road, New Shanti Nagar, Shankar Nagar, RAIPUR-492001 (C.G.)

\*Infront of AIIMS Hospital Gate No.-3, Beside Gurudwara Tatibandh, RAIPUR-492001 (C.G.)

E-mail : dragrawaloncolab@gmail.com, Web. : www.agrawaloncopathlab.com

♦♦♦♦ **Dr. Rajesh Agrawal** M.D. Pathology PGI, Chandigarh ♦♦♦♦

CASE NO: C-273/24

NAME: MRS. ANJANA PRASAD

## MICROSCOPIC FINDING ACCORDING TO BETHESDA SYSTEM

### SPECIMEN ADEQUACY

- |   |  |   |
|---|--|---|
| <input checked="" type="checkbox"/> Satisfactory for interpretation | <input type="checkbox"/> Within normal limit | <input type="checkbox"/> Unsatisfactory |
| <input type="checkbox"/> Satisfactory but limited                   | <input type="checkbox"/> Benign Cellular     |   |

### BENIGN CELLULAR CHANGES

#### Infection

- |                                       |                                      |
|---------------------------------------|--------------------------------------|
| <input type="checkbox"/> TV           | <input type="checkbox"/> Actinomyces |
| <input type="checkbox"/> Coccobacilli | <input type="checkbox"/> Candida     |
| <input type="checkbox"/> HSV          |                                      |

#### Associated Reactive Changes

- |  |                                    |                                      |
|--|------------------------------------|--------------------------------------|
| <input checked="" type="checkbox"/> Inflammation | <input type="checkbox"/> Repair    | <input type="checkbox"/> IUCD Effect |
| <input type="checkbox"/> Atrophic                | <input type="checkbox"/> Radiation | <input type="checkbox"/> Others      |

### EPITHELIAL CELL ABNORMALITY

#### Squamous cells

- Atypical squamous cells of undetermined significance (ASCUS)
- Atypical squamous cells cannot exclude HSIL (ASC-H)
- LSIL (Low Grade Squamous Intraepithelial lesion)
- HSIL (High Grade Squamous Intraepithelial lesion)
- Squamous Cell Carcinoma

#### Glandular Cells

- Atypical Glandular cells (Not otherwise specified)
- Atypical Glandular cells favor neoplastic
- Endocervical adenocarcinoma in situ

#### Adenocarcinoma Probable site of Origin

- |  |  |
|--|--|
| <input type="checkbox"/> Endocervical  | <input type="checkbox"/> Endometrial             |
| <input type="checkbox"/> Extra Uterine | <input type="checkbox"/> Not otherwise specified |

**CYTODIAGNOSIS:** Smears are adequate and Inflammatory (Moderate).

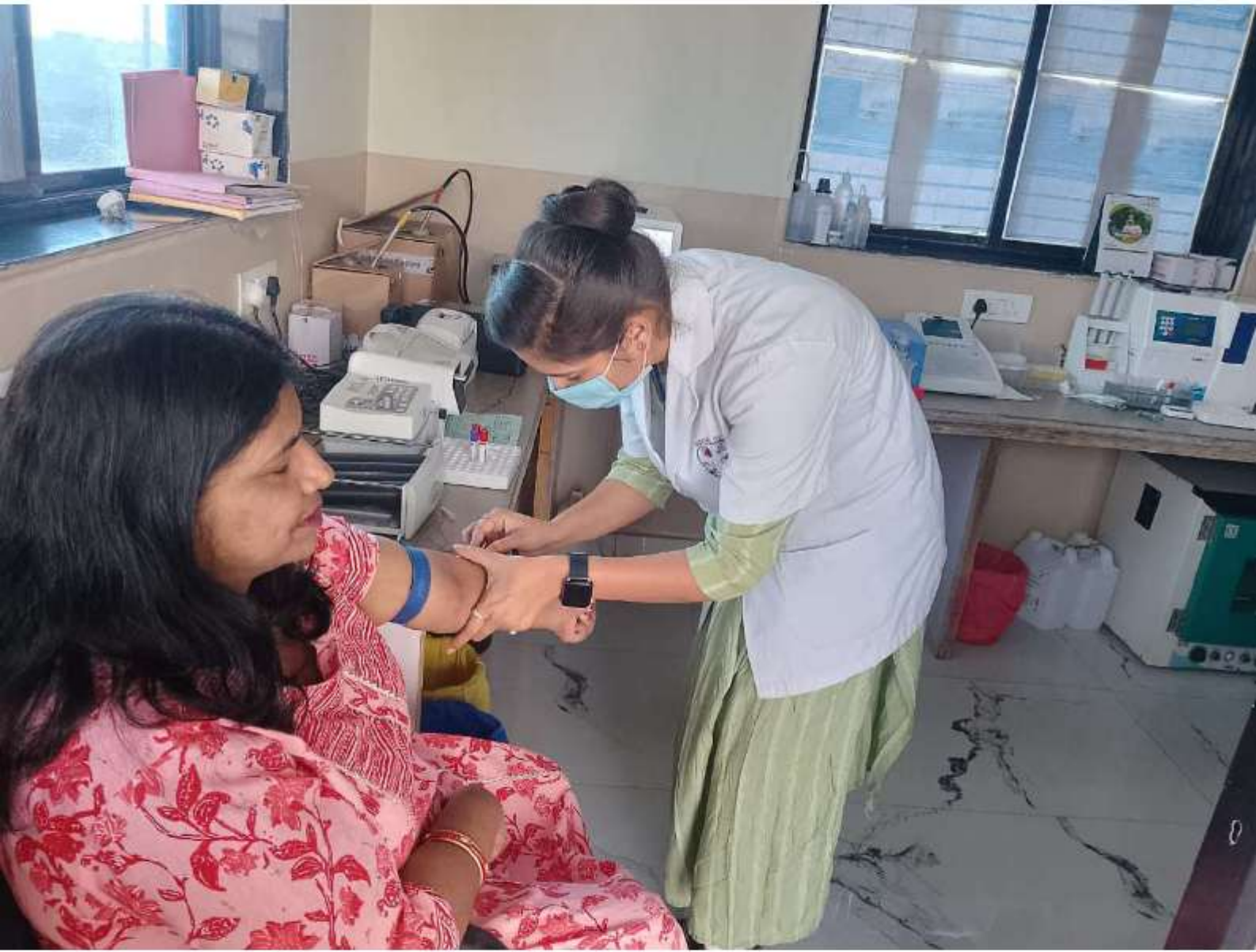**ADVISE:** Clinical correlation with Endometrial tissue evaluation.

\*This is a screening test not the confirmatory test.

DR. RAJESH K. AGRAWAL

M.D.(PATHOLOGY PGI CHANDIGARH)

REGISTRATION NO.-C.G.M.C-2975/2010





NAME : MRS. ANJANA PRASAD  
REF BY : SHREE RAM HOSPITAL

AGE/SEX : 53 YRS/ FEMALE  
DATE : 17.02.2024

## ULTRASONOGRAPHY OF WHOLE ABDOMEN

### Liver :

Liver is normal in size, shows increase in echogenicity with smooth margins. No evidence of volume redistribution. No focal lesions. No intra hepatic biliary dilatation.

### Portal vein :

Portal vein is normal in caliber with anechoic lumen. No obvious periportal collaterals.

### Spleen:

Spleen is normal in size and echotexture. No focal lesion.

### Pancreas:

Pancreas shows normal morphology & echotexture. No focal lesions.  
Pancreatic duct is normal in caliber. No peripancreatic fluid collection.

### Gall Bladder & CBD :

GB is physiologically distended and shows normal walls and clear lumen.  
CBD is normal in caliber .

### KUB region:

Right kidney measures 10.3 x 4.8 cm and left kidney measures 9.9 x 4.4 cm. Both the kidneys show normal parenchymal and sinus echoes. Corticomedullary differentiation is maintained. No calculi / hydronephrosis.

There is no evidence of any ureteric abnormality.  
The urinary bladder is well distended and shows normal walls and clear lumen.

### Pelvic Region :

Uterus is normal in size ( 8.0 x 4.2 x 4.4 cm ) and echotexture. No focal lesions.  
Endometrial thickness measures 12.3 mm.

Bilateral ovaries are normal in size and echotexture.

### Others :


Aorta, IVC are normal in course and caliber without any intraluminal abnormality.  
There is no evidence of any fluid collection or lymphadenopathy in the abdomen.

NAME : MRS. ANJANA PRASAD  
REF BY : SHREE RAM HOSPITAL

AGE/SEX : 53 YRS/ FEMALE  
DATE : 17.02.2024


**IMPRESSION :**

Diffuse Fatty liver grade I.  
No other demonstrable abnormality.

<p>DR SONAL AGRAWAL MD RADIODIAGNOSIS CONSULTANT RADIOLOGIST REG.NO.CGMC 5693 /2014 10:00 AM To 2:00 PM</p>	<p>DR VIPLAV CHATTERJEE DNB RADIODIAGNOSIS CONSULTANT RADIOLOGIST REG.NO.CGMC 5314 /2014 12:00 PM To 3:00 PM</p>	 <p>DR PANKAJ ARORA MBBS; DMRD; DNB (HYDERABAD) CONSULTANT RADIOLOGIST REG. NO. CGMC 0093/2003 2:00 TO 8:00 PM.</p>
---	--	---

NAME : MRS. ANJANA PRASAD  
REF BY : SHREE RAM HOSPITAL

AGE/SEX : 53 YRS/ FEMALE  
DATE : 17.02.2024

**2D  ECHOCARDIOGRAPHY & COLOUR DOPPLER REPORT**

MEASUREMENT	PTS. VALUE	NORMAL VALUE (MM)	MEASUREMENT	PTS. VALUE	NORMAL VALUE (MM)
AO	3.14Cm	20 - 37	IVS (d)	1.48 Cm	6 - 11
LA	3.23Cm	19 - 40	LVID (d)	4.53 Cm	45 - 50
MACS	-	15 - 26	LVPW (d)	1.24 Cm	6 - 11
EPSS	-	<8 MM	LVID (s)	2.90 Cm	23 - 39
FS	-	%	EF	60%	( 60 - 62 % )
RA	-	<26 MM	RV	-	<26 MM

**2D ECHO % CFI :-**

CHAMBERS - CONCENTRIC LVH PRESENT.  
VALVE - Normal valves  
SEPTAE - NORMAL  
RWMA - Nil  
EF (Over all ) - 60 %  
CLOT/VEGETAION - Nil  
PER EFFUSION - Nil

**Continuous wave & colour wave Doppler :-**

Value	Regurgitation	Gradient (mmhg)
Mitral value	Nil	Not significant
Aortic value	Nil	Not significant
Tricuspid value	Nil	Not significant
Pulmonary value	Nil	Not significant

**Mitral value inflow shows:-** E WAVES < A WAVES DT m sec.



NAME : MRS. ANJANA PRASAD  
REF BY : SHREE RAM HOSPITAL

AGE/SEX : 53 YRS/ FEMALE  
DATE : 17.02.2024

**IMPRESSION** : CONCENTRIC LVH PRESENT,  
NORMAL LV SYSTOLIC FUNCTION (LVEF 60 %)  
NORMAL VALVES  
NO E/O LV DIASTOLIC DYSFUNCTION  
NO E/O RWMA  
NO E/O CLOT / PERICARDIAL EFFUSION / VEGETATION



DR. NIKHIL MOTIRAMANI  
MD( Medicine),DM (Cardiology)  
Sr. interventional cardiologist

NAME : MRS. ANJANA PRASAD  
REF BY : SHREE RAM HOSPITAL

AGE/SEX : 53 YEARS /FEMALE  
DATE : 17.02.2024

### X-RAY : MAMMOGRAPHY

- Breast parenchyma is predominantly fatty.
- No obvious mass lesion / architectural distortion.
- No abnormal calcific foci.
- Nipple and subareolar tissue are normal.
- No retraction or skin thickening is seen.
- The pectoralis and retro mammary space appears normal.
- Axillary shadows appear normal.

### CORRELATIVE USG

- No obvious mass lesion in either breast.
- No obvious enlarged axillary lymph nodes.

### IMPRESSION:-

- No obvious abnormality on mammography / correlative USG breast.

<p><b>DR. SONAL AGRAWAL</b> MD RADIODIAGNOSIS CONSULTANT RADIOLOGIST REG. NO CGMC – 5693/2014 10:00 AM to 2.00 PM.</p>	<p><b>DR. VIPLAV CHATTERJEE</b> DNB RADIODIAGNOSIS CONSULTANT RADIOLOGIST REG. NO. CGMC 5314/2014 12:00 PM To 3:00 PM</p>	<p><b>DR. PANKAJ ARORA</b> MBBS; DMRD;DNB CONSULTANT RADIOLOGIST REG. NO CGMC - 0093/2003 2:00PM to 8:00 PM.</p>
--	---	--