

भारत सरकार
Government of India

मनोज कुमार
Manoj Kumar
जन्म तिथि/DOB: 15/04/1965
पुरुष/ MALE


7468 4777 9574
VID : 9189 9929 1781 5504

मेरा आधार मेरी पहचान

Download Date: 28/05/2020

Issue Date: 10/04/2020

Handwritten signature in blue ink.



ONEPLUS ULTRASOUND LAB
47, Harsh Vihar, Pitam Pura,
Delhi-110034
Ph. 011-42480101, 9599913051
E-mail: oneplusul@gmail.com

Handwritten signature in blue ink.

Dr. NITIN AGARWAL
MBBS, MD
Regn. No. DMC-R-1436

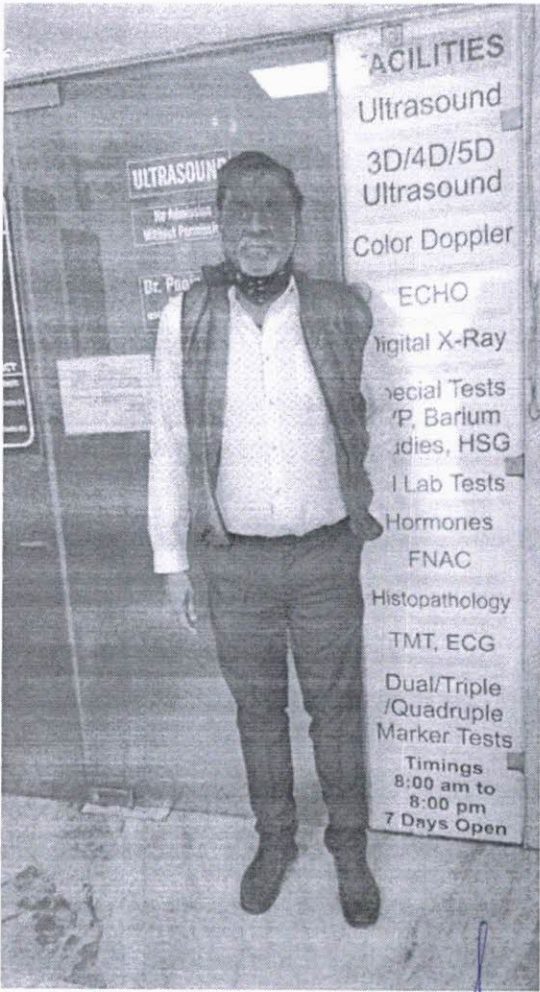
भारतीय विशिष्ट पहचान प्राधिकरण
Unique Identification Authority of India

पता: मनोज कुमार, फ्लैट नं. 361, पॉकेट जी एच-1, रोहिणी, दिल्ली - 110085
रिजि. - 110085
रोहिणी, नॉर्थ पॉकेट 29, रोहिणी, दिल्ली - 110085

Address: C/O MANOJ KUMAR, Flat No 361, POCKET GH-1, ROHINI, Sector 29, Rohini, North Delhi - 110085

7468 4777 9574
VID : 9189 9929 1781 5504

1947 | help@uidai.gov.in | www.uidai.gov.in




Dr. NITIN AGARWAL
MBBS, MD
Regn. No. DMC-R-1436

Dr. Medical tests

ONEPLUS ULTRASOUND LAB
47, Harsh Vihar, Pitam Pura,
Delhi-110034
Ph. 011-42480101, 9599913051
E-mail: oneplusul@gmail.com

ONEPLUS ULTRASOUND LAB

47, HARSH VIHAR, PITAMPURA, DELHI- 110034

Mr. MANOJ KUMAR
 Age : 57M
 Ref. by : MEDIWHEEL
 Indication1 :
 Indication2 :
 Indication3 :
 COMMENTS :

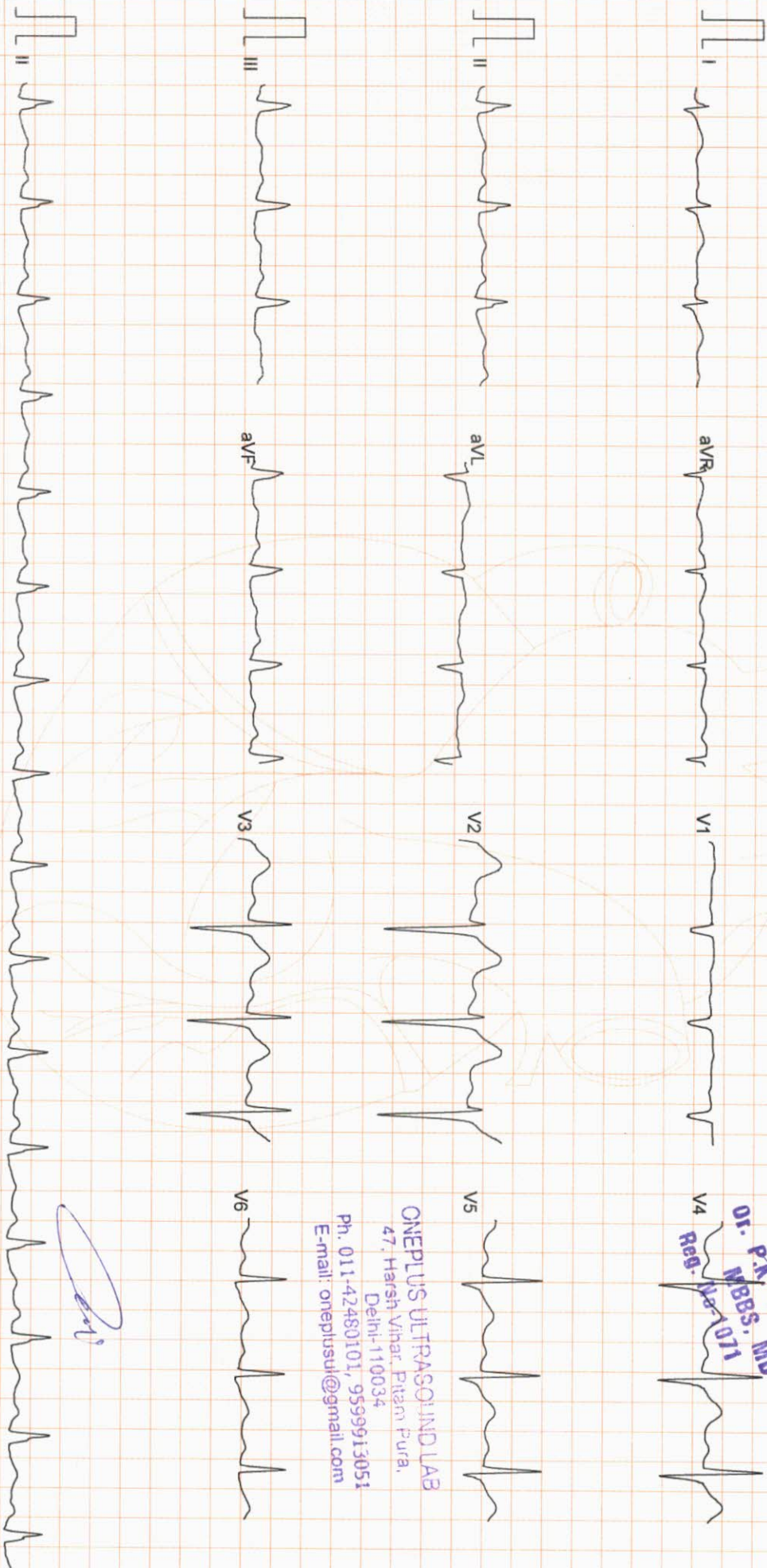
ID : 1883
 H/Wt : 17779
 Recorded : 26-2-2022 9:20
 Medication1 :
 Medication2 :
 Medication3 :

BPM : 95
 BP : 126/82
 P Axis : 77 deg
 QRS Axis : 82 deg
 T Axis : 15 deg

P duration : 113 msec
 PR duration : 183 msec
 QRS duration : 116 msec
 QT interval : 333 msec
 QTc interval : 394 msec
 Raw E.C.G. (Seq)

Unconfirmed Report Reviewed By:
 Cardiologist

Dr. P.K. GUPTA
 MBBS, MD
 Reg. No. 17017



ONEPLUS ULTRASOUND LAB
 47, Harsh Vihar, Pitam Pura,
 Delhi-110034
 Ph. 011-42460101, 9599913051
 E-mail: oneplusul@gmail.com

[Signature]

ONEPLUS ULTRASOUND LAB

47, HARSH VIHAR PITAMPURA DELHI 110034

Mr. MANOJ KUMAR
Age/Sex : 57/M
Ref. by : MEDIWHEEL
Indication1 :
Indication2 :
Indication3 :

ID : 986
HWM : 177/79
Recorded : 26-2-2022 9:23

TREADMILL TEST SUMMARY REPORT
Protocol: BRUCE
History:
Medication1 :
Medication2 :
Medication3 :

PHASE	PHASE TIME	STAGE TIME	SPEED (Km./Hr.)	GRADE (%)	H.R. (BPM)	B.P. (mmHg)	RPP X100	II	ST LEVEL (mm) V2	V5	METS
STANDING SUPINE					91	126/82	114	0.5	2.4	0.6	
					93	126/82	117	0.5	2.4	0.6	
STAGE 1	2:59	2:59	2.70	10.00	119	138/86	164	0.4	3.4	0.9	4.80
STAGE 2	5:59	2:59	4.00	12.00	136	148/88	201	-0.2	4.1	1.1	7.10
STAGE 3	6:29	0:29	5.40	14.00	143	164/90	234	-0.7	3.8	0.6	7.57
PEAK EXER	6:31	0:31			144	164/90	236	-0.4	4.0	0.9	
RECOVERY	2:59	2:59	0.00	0.00	106	130/82	137	0.3	2.3	0.5	7.60

RESULTS

Exercise Duration 6:31 Minutes
Max Heart Rate 144 bpm 88 % of target heart rate 163 bpm
Max Blood Pressure 164/90 mmHg
Max Work Load 7.60 METS
Reason of Termination

IMPRESSIONS

Regular for skill also

Cardiologist



Dr. P.K. GUPTA
M.BBS, MD

Reg. No-1071



ONEPLUS ULTRASOUND LAB
47, Harsh Vihar, Pitampura,
Delhi-110034
Ph. 011-42480101, 9559913051
E-mail: oneplusul@gmail.com

ONEPLUS ULTRASOUND LAB

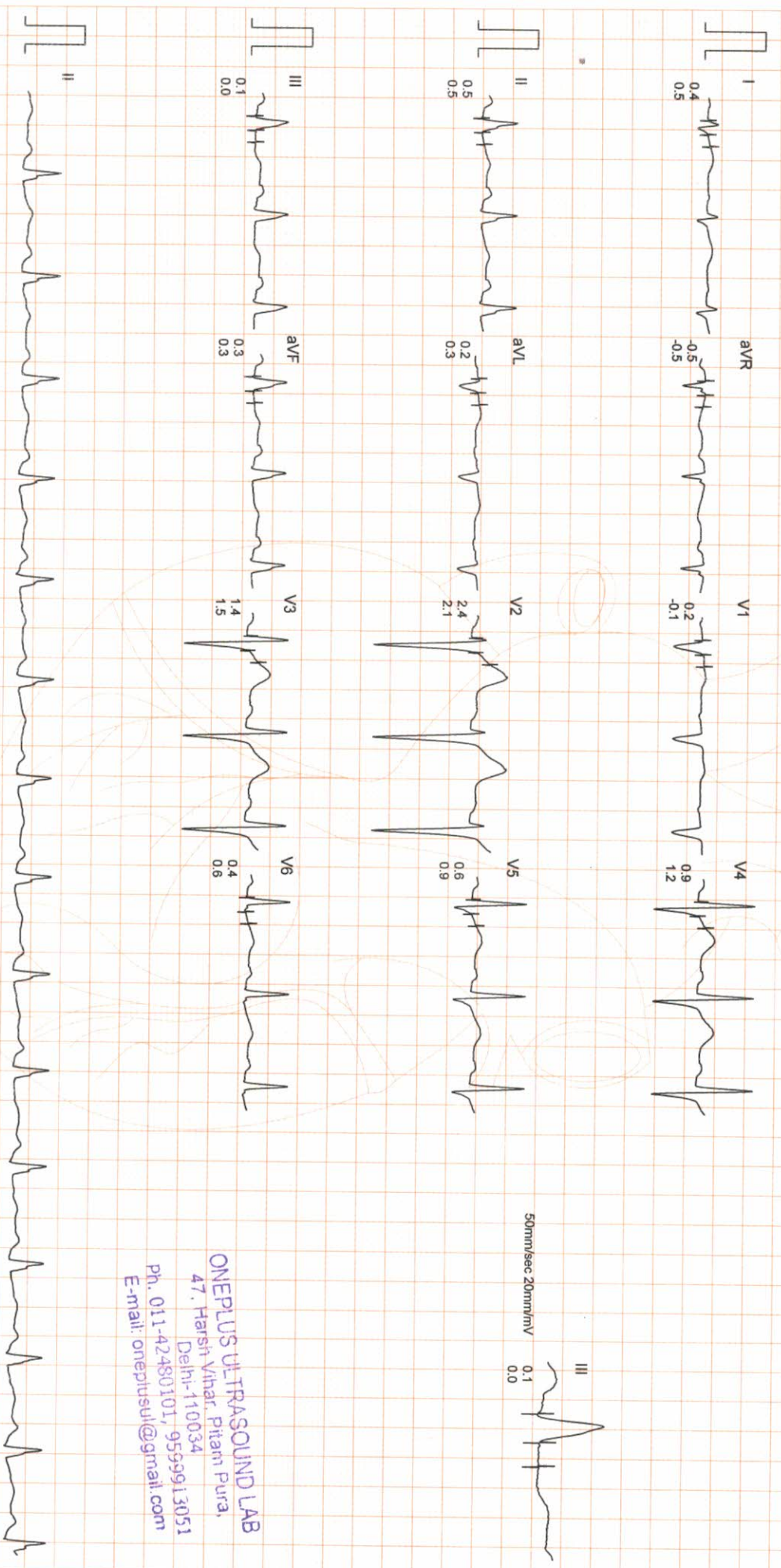
STANDING
PRETEST

ST @ 10mm/mV
80ms PostJ

Mr. MANOJ KUMAR
I.D. : 986
AGE/SEX : 57/M
RECORDED : 26-2-2022 9:23

RATE : 91 BPM
B.P. : 126/82 mmHg

LINKED MEDIAN



ONEPLUS ULTRASOUND LAB
47, Harsh Vihar, Pitamhi Pura,
Delhi-110034
Ph. 011-42480101, 9559913051
E-mail: oneplusul@gmail.com

Filtered Computer Corrected Baseline

25mm/sec 10mm/mV



CardiCom, INDIA Ph.:091-731-2620740, TeleFax:091-731-2431214

ONEPLUS ULTRASOUND LAB

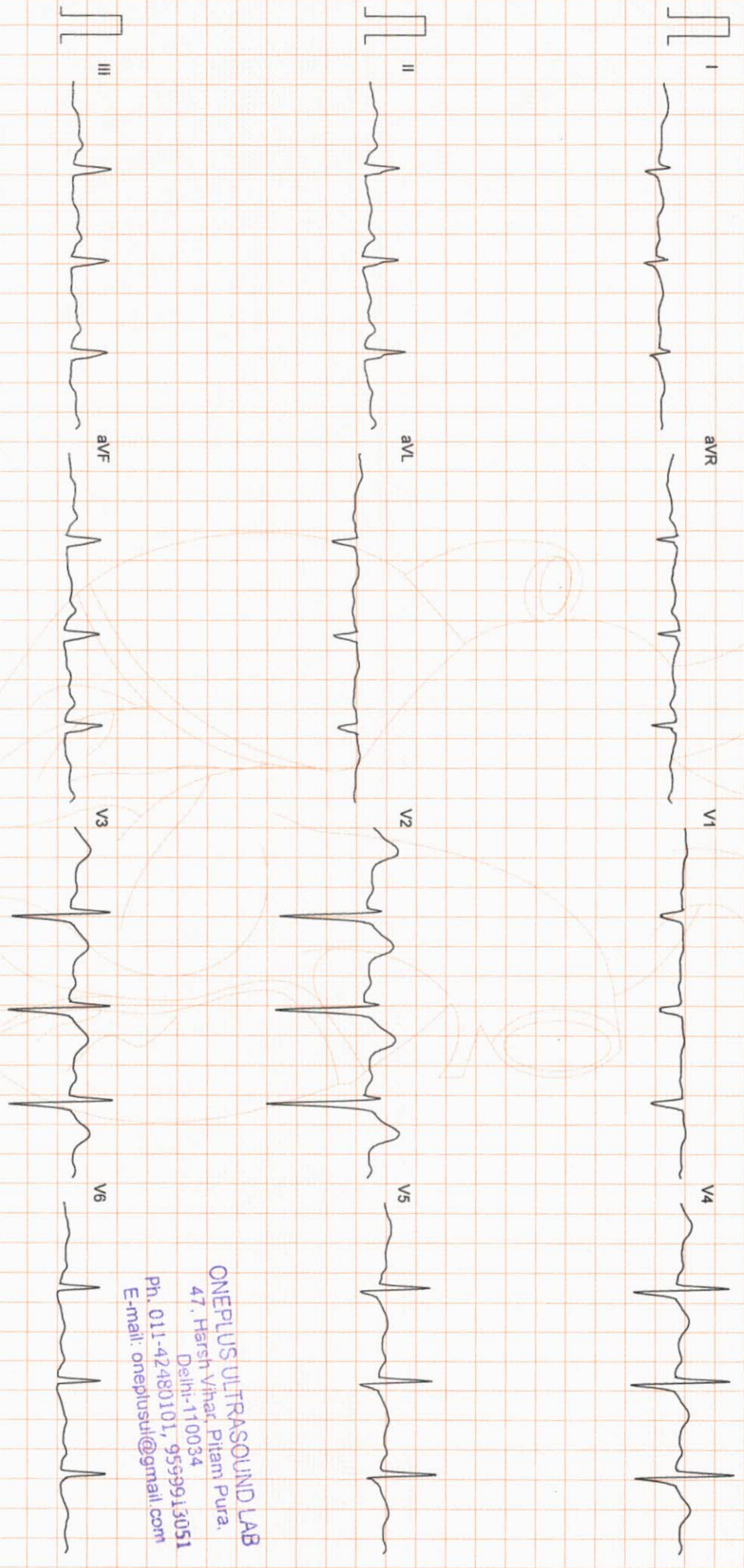
SUPINE
PRETEST

ST @ 10mm/mV
80ms PostJ

Mr. MANOJ KUMAR
I.D. : 986
AGE/SEX : 57/M
RECORDED : 26-2-2022 9:23

RATE : 93 BPM
B.P. : 126/82 mmHg

RAW E.C.G.



ONEPLUS ULTRASOUND LAB
47, Harsh Vihar Pitam Pura,
Delhi-110034
Ph. 011-42480101, 9599913051
E-mail: oneplusul@gmail.com

Filtered

25mm/sec 10mm/mV

ARROW

Cardicom, INDIA Ph.:091-731-2620740, TeleFax:091-731-2431214

ONEPLUS ULTRASOUND LAB

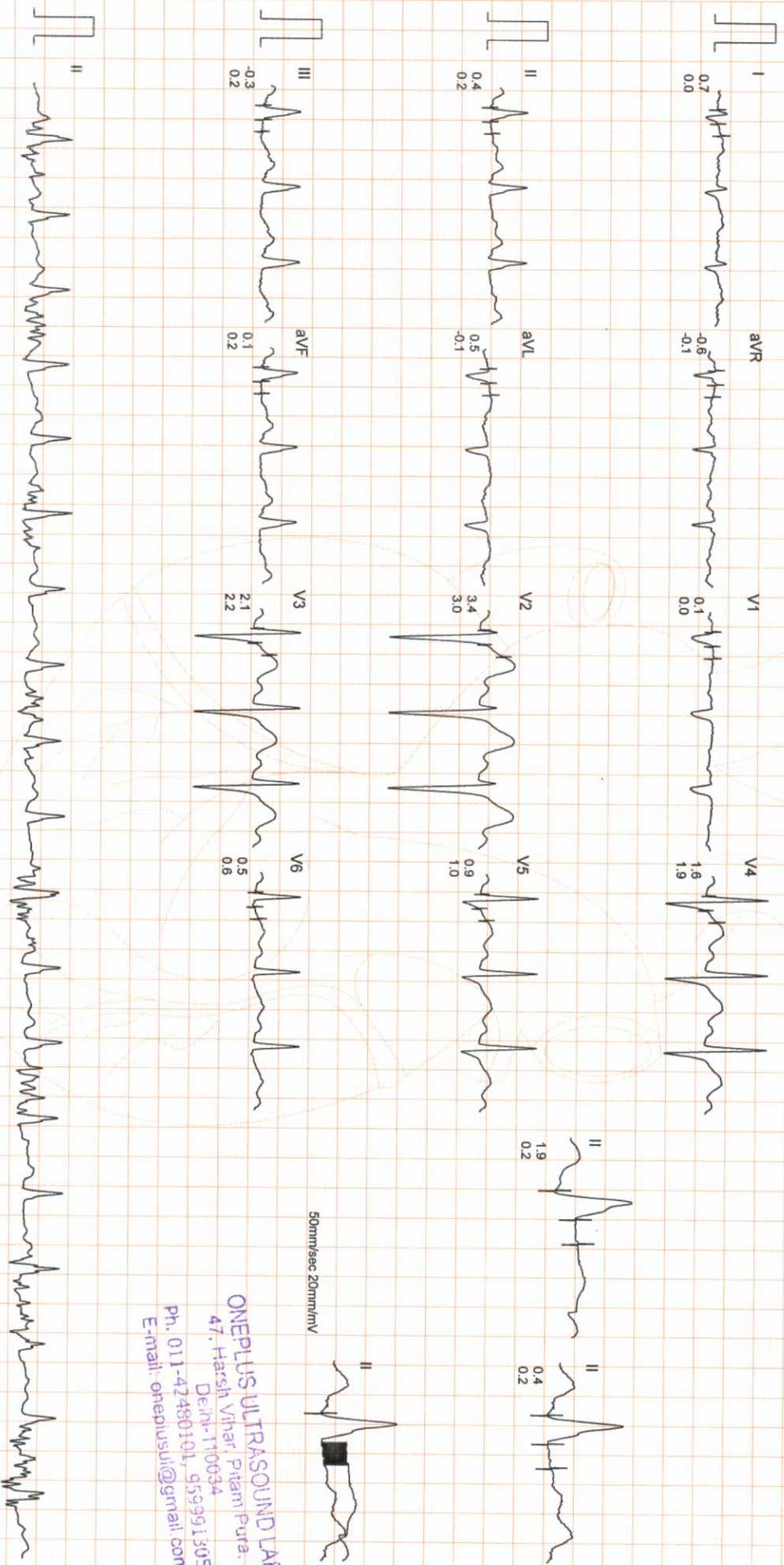
Mr. MANOJ KUMAR
I.D. : 986
AGE/SEX : 57/M
RECORDED : 26-2-2022 9:23

RATE : 119 BPM
B.P. : 138/86 mmHg

BRUCE
EXERCISE 1
PHASE TIME : 2:59
STAGE TIME : 2:59

ST @ 10mm/mV
80ms PostJ
SPEED : 2.7 Km./Hr.
GRADE : 10.0 %

LINKED MEDIAN



ONEPLUS ULTRASOUND LAB
47, Harsh Vihar, Pitam Pura,
Delhi-110034
Ph. 011-42480101, 9599913051
E-mail: oneplusul@gmail.com

ONEPLUS ULTRASOUND LAB

Mr. MANOJ KUMAR

I.D. : 986

AGE/SEX : 57/M

RECORDED : 26-2-2022 9:23

RATE : 136 BPM

B.P. : 148/88 mmHg

BRUCE

EXERCISE 2

PHASE TIME : 5:59

STAGE TIME : 2:59

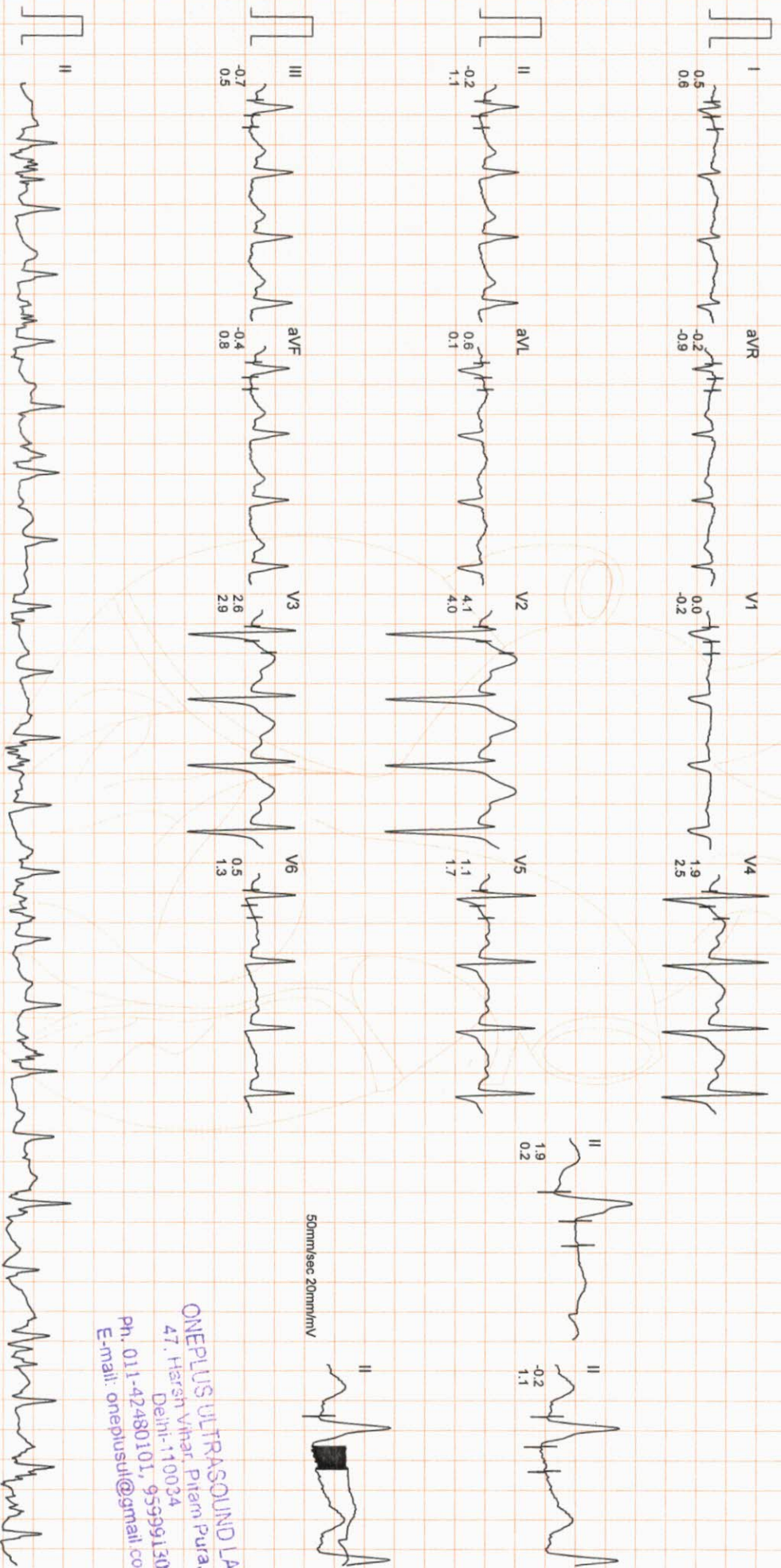
ST @ 10mm/mV

80ms PostJ

SPEED : 4.0 Km/Hr.

GRADE : 12.0 %

LINKED MEDIAN



50mm/sec 20mm/mV

ONEPLUS ULTRASOUND LAB
47, Harsh Vihar, Pitam Pura,
Delhi-110034
Ph. 011-42480101, 9599913051
E-mail: oneplusul@gmail.com

ONEPLUS ULTRASOUND LAB

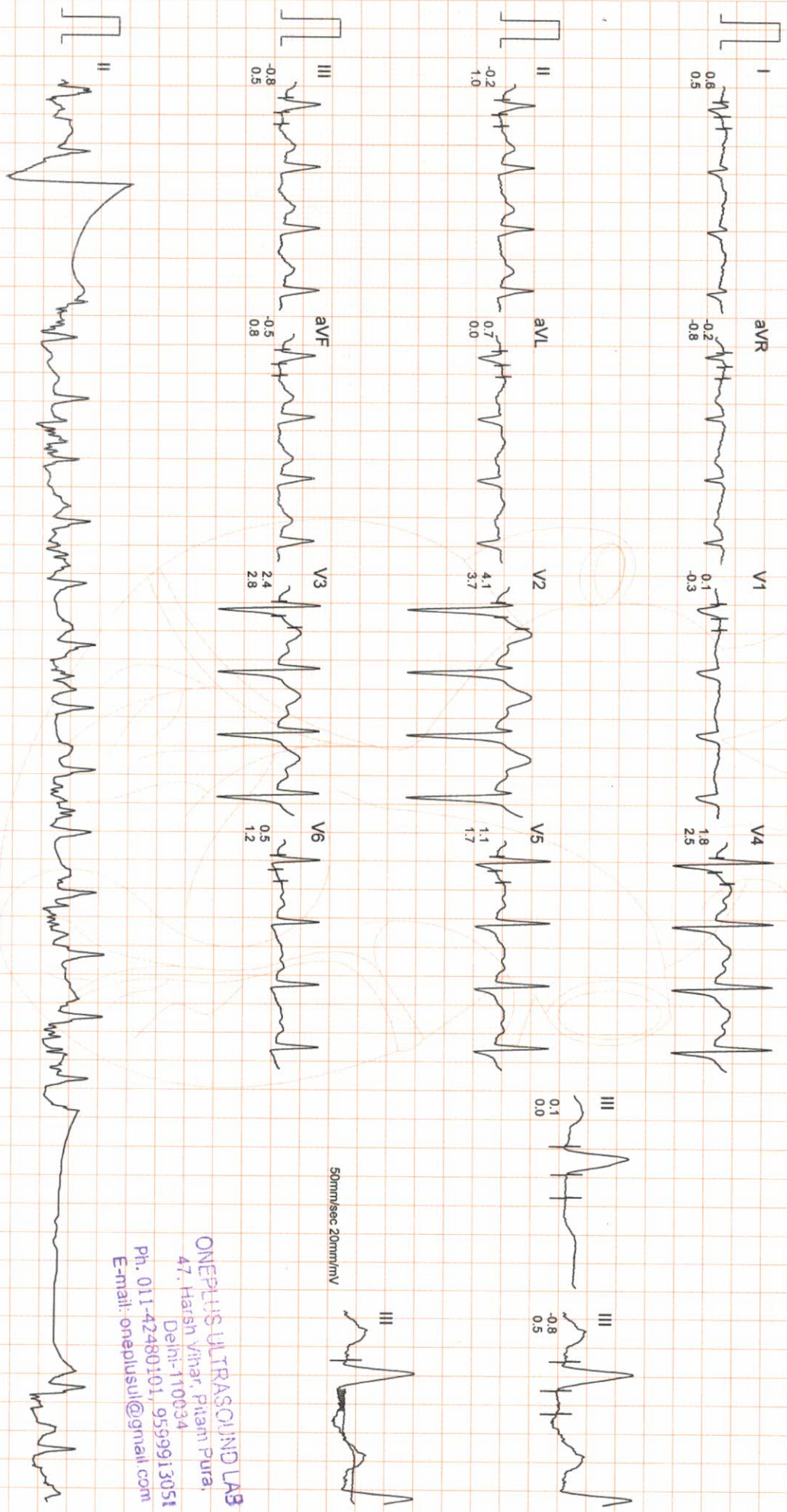
Mr. MANOJ KUMAR
 I.D. : 986
 AGE/SEX : 57/M
 RECORDED : 26-2-2022 9:23

RATE : 140 BPM
 B.P. : 148/88 mmHg

BRUCE
 EXERCISE 3
 PHASE TIME : 6:14
 STAGE TIME : 0:14

ST @ 10mm/mv
 80ms PostJ
 SPEED : 5.4 Km./Hr.
 GRADE : 14.0 %

LINKED MEDIAN



Filtered Computer Corrected Baseline 25mm/sec 10mm/mv CardCom, INDIA Ph.:091-731-2620740, TeleFax:091-731-2431214

ONEPLUS ULTRASOUND LAB
 47, Harsh Vihar, Pitam Pura,
 Delhi-110034
 Ph. 011-42480101, 9599913051
 E-mail: oneplusul@gmail.com

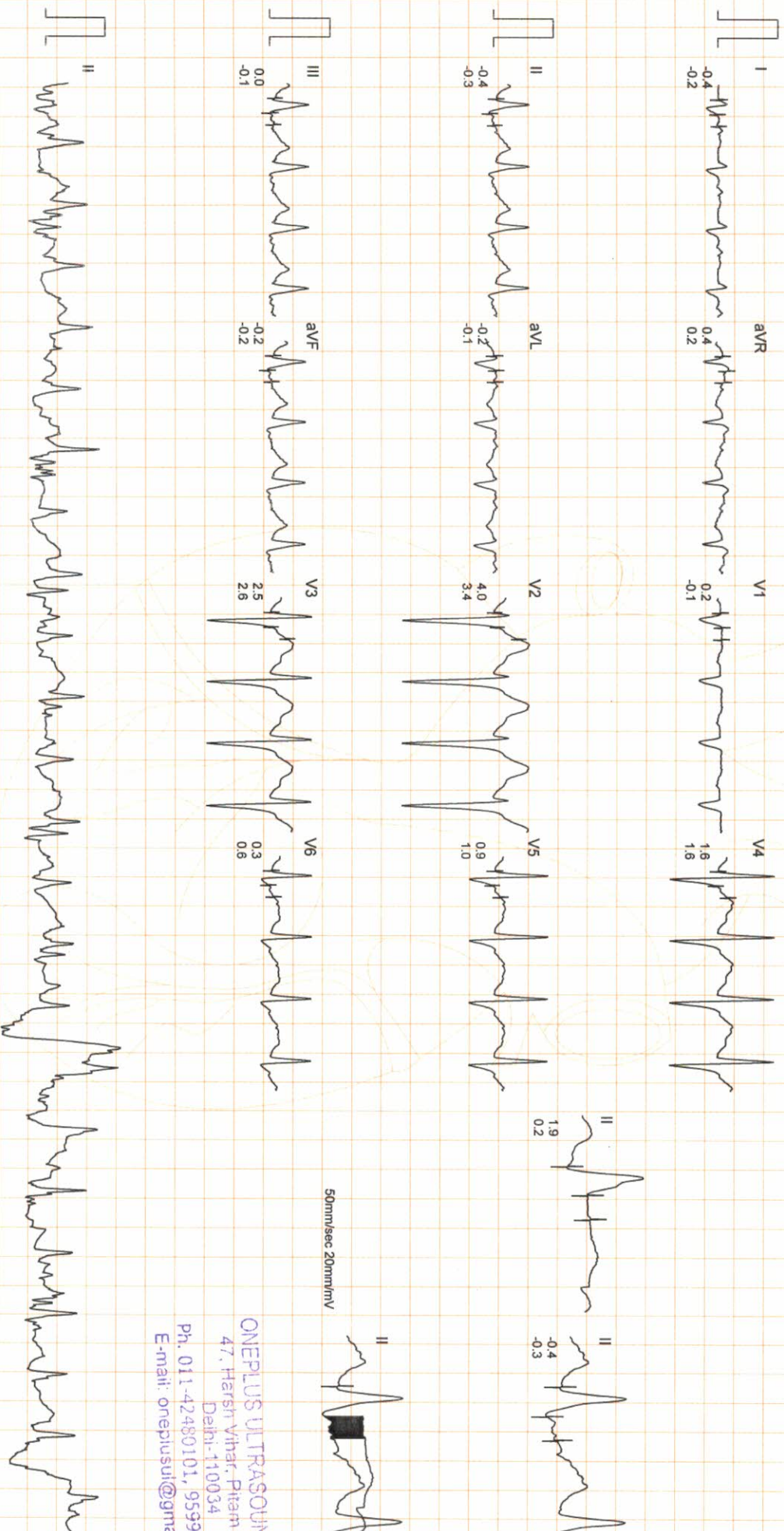
ONEPLUS ULTRASOUND LAB

Mr. MANOJ KUMAR
I.D. : 986
AGE/SEX : 57/M
RECORDED : 26-2-2022 9:23

RATE : 144 BPM
B.P. : 164/90 mmHg

BRUCE
PEAK EXER
PHASE TIME : 6:31
STAGE TIME : 0:31

ST @ 10mm/mV
80ms PostJ
SPEED : 5.4 Km./hr.
GRADE : 14.0 %
LINKED MEDIAN



ONEPLUS ULTRASOUND LAB
47, Hersh Vihar, Pitam Pura,
Delhi-110034
Ph. 011-42480101, 9599913051
E-mail: oneplusul@gmail.com

ONEPLUS ULTRASOUND LAB

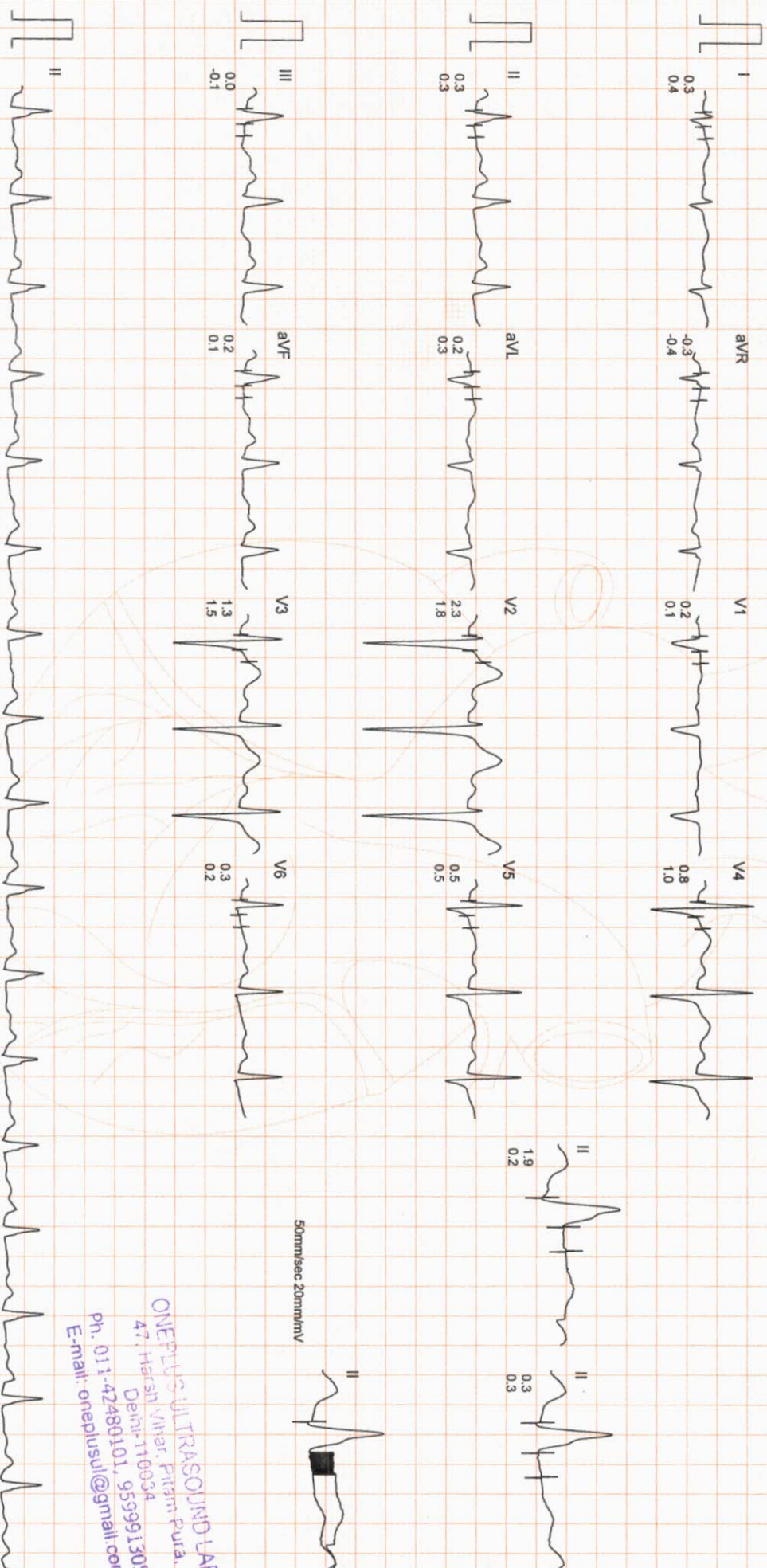
Mr: MANOJ KUMAR
I.D. : 986
AGE/SEX : 57/M
RECORDED : 26-2-2022 9:23

RATE : 106 BPM
B.P. : 130/82 mmHg

BRUCE
RECOVERY
PHASE TIME : 2:59



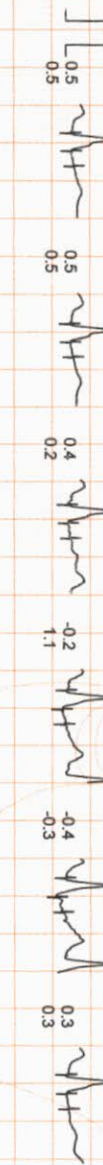
ST @ 10mm/mV
80ms PostJ
SPEED : 0.0 Km./Hr.
GRADE : 0.0 %

LINKED MEDIAN



ONEPLUS ULTRASOUND LAB
47, Harsh Vihar, Pitam Pura,
Delhi-110034
Ph. 011-42480101, 9599913051
E-mail: onepusul@gmail.com

STANDING	SUPINE	STAGE 1	STAGE 2	PEAK EXERCISE	RECOVERY
0.0Kmph 0.0% 91 bpm B.P. 126/82 80ms PostJ	0.0Kmph 0.0% 93 bpm B.P. 126/82 80ms PostJ	2:59 2:59 2.7Kmph 10.0% 119 bpm B.P. 138/86 80ms PostJ	5:59 5:59 4.0Kmph 12.0% 136 bpm B.P. 148/88 80ms PostJ	6:31 0:31 5.4Kmph 14.0% 144 bpm B.P. 164/90 80ms PostJ	2:59 0.0Kmph 0.0% 108 bpm B.P. 130/82 80ms PostJ



















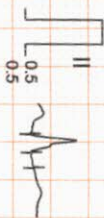



ONEPLUS ULTRASOUND LAB
 47, Harsh Vihar, Pitam Pura.
 Delhi-110034
 Ph. 011-42480101, 9559913051
 E-mail: onepiusul@gmail.com

SUPINE
 0.0Kmph
 0.0%
 93 bpm
 B.P. 126/82
 80ms PostJ

PEAK EXERCISE
 6.31
 0.31
 5.4Kmph
 14.0%
 144 bpm
 B.P. 164/90
 80ms PostJ

SUPINE
 0.0Kmph
 0.0%
 93 bpm
 B.P. 126/82
 80ms PostJ

PEAK EXERCISE
 6.31
 0.31
 5.4Kmph
 14.0%
 144 bpm
 B.P. 164/90
 80ms PostJ



ONEPLUS ULTRASOUND LAB
 47, Herish Vihar, Pitam Pura,
 Delhi-110034
 Ph. 011-42480101, 9559913051
 E-mail: oneplusul@gmail.com



OnePLUS
Ultrasound Lab
— QUALITY FIRST... ALWAYS! —

Dr. Nitin Agarwal
Pathologist & Director
Ex. Sr. Res. MAMC
& Lok Nayak Hospital
Ex. Chief of Lab Dr. Lal Path Labs.

Dr. Pooja (Garg) Agarwal
Radiologist & Director
MAMC & Lok Nayak Hospital

Name	: Mr. MANOJ KUMAR	Age/Sex	: 57 YRS/Male
Ref. By	: Dr. MEDIWHEEL	Lab No	: 012202260003
Date	: 26-Feb-2022	Patient ID	: LSHHI91721

ULTRASOUND EXAMINATION----WHOLE ABDOMEN

Liver is normal in size (14.2 cm) and normal in outline with **altered echopattern. Diffuse increase in echogenicity of liver parenchyma is noted, suggestive of fatty infiltration (grade I). Intrahepatic biliary radicles are not dilated.** No abscess or mass lesion seen. Hepatic veins, portal vein, IVC and aorta are normal. CBD is normal (3.5 mm) in caliber.

Gall bladder is well distended with anechoic lumen. Wall thickness is normal.

Both kidneys are normal in size, shape, position, outline and echopattern. Corticomedullary differentiation is maintained. No pelvicalyceal dilation or mass lesion is seen.

Renal measurements are --

Rt. Kidney - 10.7 x 4.9 cm.

Lt. kidney - 11.5 x 4.9 cm

Spleen is normal in size and echotexture. No mass lesion seen.

Pancreas is normal in size, outline and echotexture.

Urinary bladder is normal in shape and position. No evidence of intravesical stone or mass seen.

Prostate is **enlarged**, normal in shape and echopattern.


Prostate measures 4.1 x 4.0 x 5.4 cm. **Weight of prostate is 46.4 grams.**

No abnormal bowel wall thickening seen in right iliac fossa.

No free fluid seen anywhere in abdomen.

IMPRESSION:

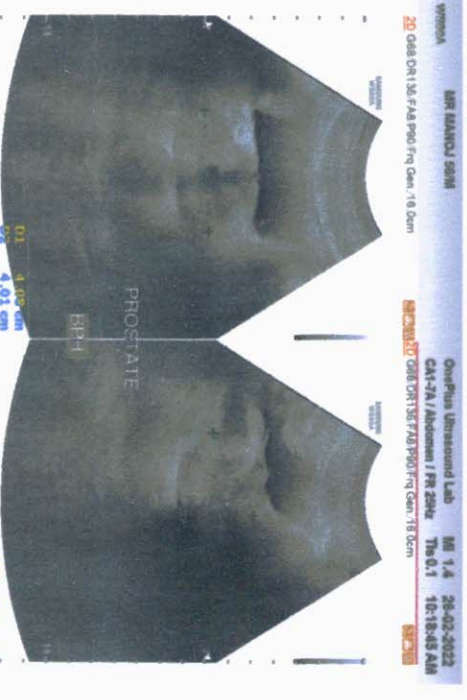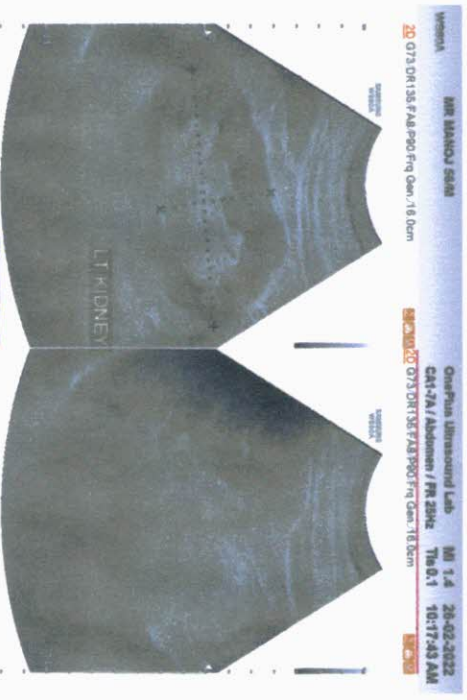

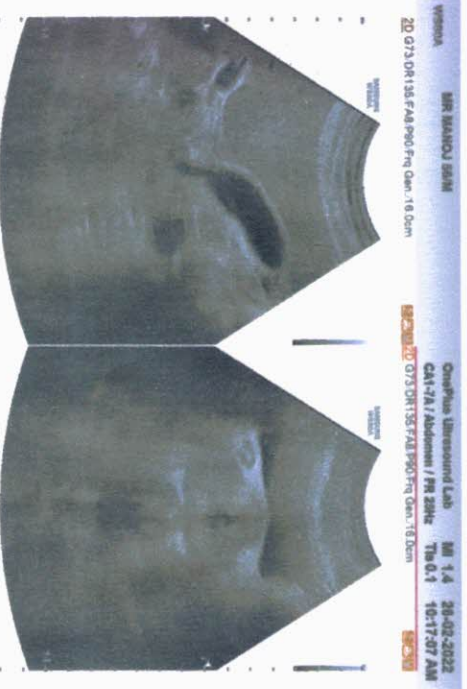- **Fatty infiltration of liver (grade I) with no hepatomegaly.**
- **Prostatic hypertrophy.**


DR. POOJA GARG
RADIOLOGIST
REG NO- DMC/R/03398
Dr. POOJA GARG
M.B.B.S., D.M.R.D
Reg No. DMC/R/03398
Radiologist

Type By : pooja

47, Harsh Vihar, Pitampura, New Delhi-110034 | Ph.: 011-42480101, 9599913051

E-mail: oneplusul@gmail.com | Web.: www.oneplusul.in



D1 11.45 cm
D2 4.88 cm

D1 0.35 cm

D3 14.37 cm

D1 1.00 cm
D2 4.01 cm
D3 5.42 cm
Vol. 46.43 ml

D1 10.08 cm
D2 4.84 cm

D1 4.08 cm
D2 4.01 cm






PLATE 10. THE BUST OF THE VIRGIN MARY



OnePLUS
Ultrasound Lab
— QUALITY FIRST... ALWAYS! —

Dr. Nitin Agarwal

Pathologist & Director
Ex. Sr. Res. MAMC
& Lok Nayak Hospital
Ex. Chief of Lab Dr. Lal Path Labs.

Dr. Pooja (Garg) Agarwal


Radiologist & Director
MAMC & Lok Nayak Hospital

Name	: Mr. MANOJ KUMAR	Age/Sex	: 57 YRS/Male
Ref. By	: Dr. MEDIWHEEL	Lab No	: 012202260003
Date	: 26-Feb-2022	Patient ID	: LSHHI91721

X-ray-Chest PA view

Bony cage and soft tissues are normal.
Cardiothoracic ratio is normal.
Mediastinum is normal.
Both hila are normal.
Both costophrenic angles are clear.
Both domes of diaphragm are normal.
Lung fields are clear. No parenchymal lesion seen.

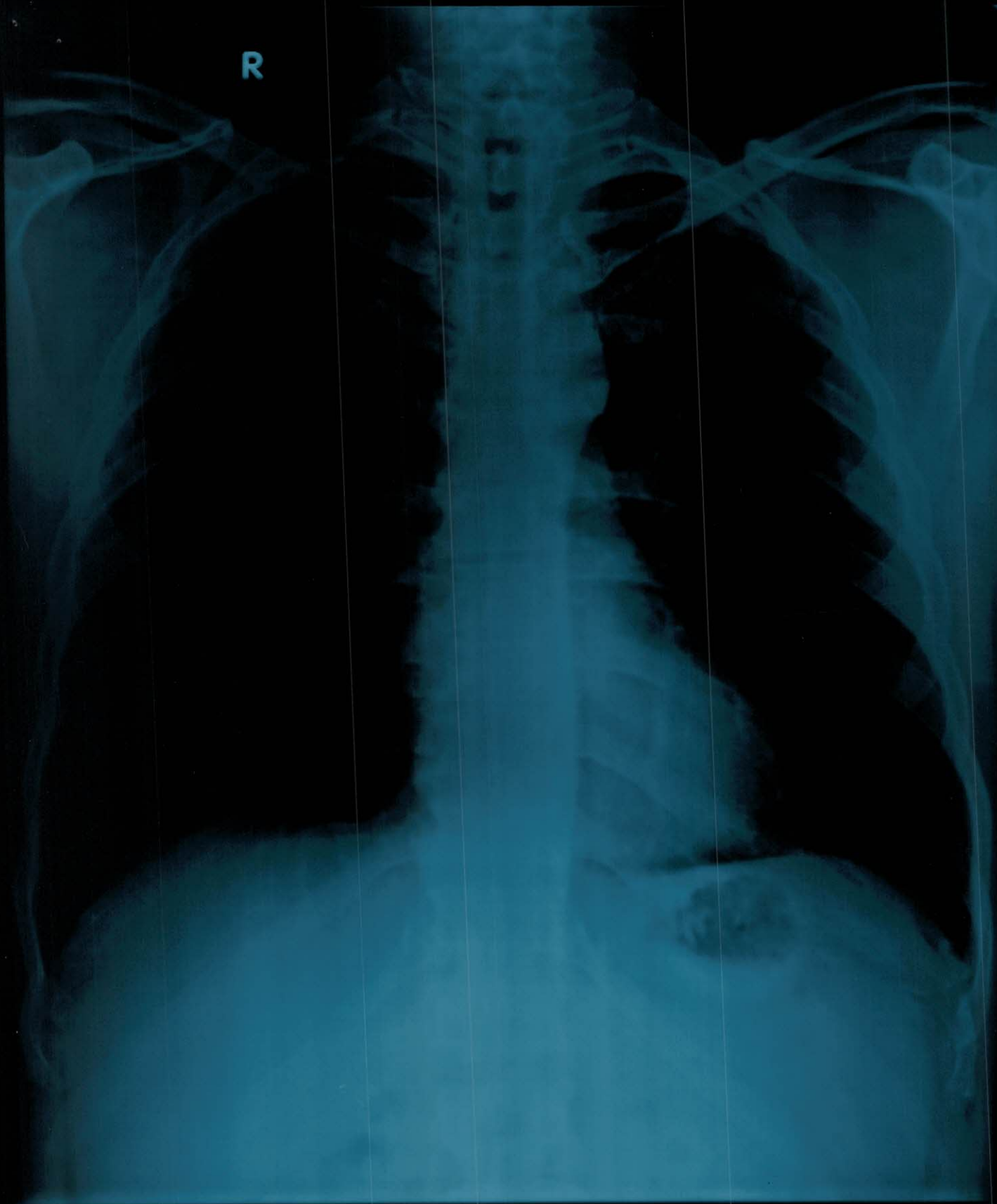
IMPRESSION: Normal Study.


DR. POOJA GARG
RADIOLOGIST
REG NO- DMC/R/03398
Dr. POOJA GARG
M.B.B.S., D.M.R.D
Reg No. DMC/R/03398
Radiologist

Type By : pooja

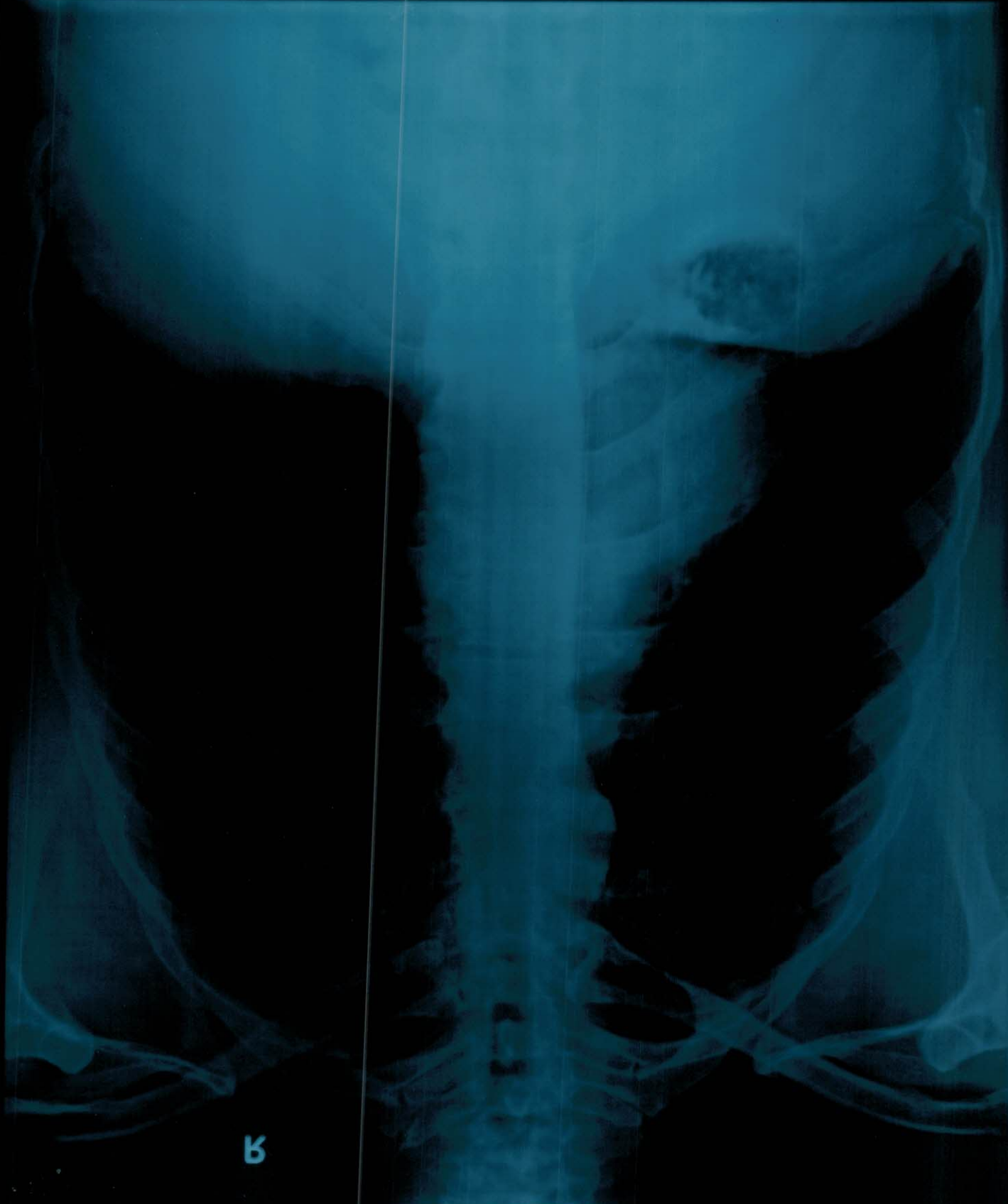47, Harsh Vihar, Pitampura, New Delhi-110034 | Ph.: 011-42480101, 9599913051
E-mail: oneplusul@gmail.com | Web.: www.oneplusul.in

R



MR MANOJ KUMAR AGE 57 YRS 26-2-2022 M CHEST PA
ONEPLUS ULTRASOUND LAB, 47-HARSH VIHAR, PITAMPURA

ОИЕГУС ПГТРАСОИИД ГАВ'41-НАР2Н УИНАР'ПИТАМЬУБА
МБ МАИОУ КУМАР АСЕ 27 УР2 20-2-2022 М СЕШТ РА



Б