

<b>Name: MRS AMITA SHARMA</b>	<b>Age/sex: 44 Yrs / FEMALE</b>
<b>Ref by: MEDIWHEEL</b>	<b>Date: 20/02/2022</b>

**ULTRASOUND EXAMINATION OF ABDOMEN & PELVIS**

**Findings-**

The Liver is mildly enlarged in size (15 cm ) shape and raised echogenicity. No focal lesion is seen. The Hepatic veins appear normal. There is no IHBR dilatation. The portal vein appears normal.

The gall bladder is well distended. The extra hepatic C.B.D. is of normal caliber.

The visualized Pancreas appears normal in size and reflectivity. The pancreatic duct is not dilated. The spleen is normal in size (11.6 cm ), No focal lesion is seen. Splenic vein is normal at hilum.

Both kidneys are normal in position and size. They show normal cortical reflectivity and cortico-medullary differentiation. There is no evidence of renal calculus, hydronephrosis or mass.

Right kidney measures 10.95 x 3.36 cm

Left kidney measures 10.66 x 4.20cm

The Urinary bladder is well distended. No evidence of any intraluminal mass or calculi.

Uterus is anteverted and measures 6.92 x 3.6 x 2.7cm, appears normal in size, shape and echotexture . No focal lesion noted. Endometrial echoes are mid line and measure 4.1 mm.

A 16 x 13 mm sized nebothian cyst is noted in cervix with internal echoes .

Both ovaries are normal in size and morphology.

Right ovary measures 1.95 x 1.18 cm

Left ovary measures 2.68 x 1.11 cm

No free fluid is noted in abdomen and pelvis .

No probe tenderness seen in present study

**IMPRESSION :-**

- **Mild hepatomegaly with grade 2 fatty infiltration.**
- **Nebothian cyst in cervix**

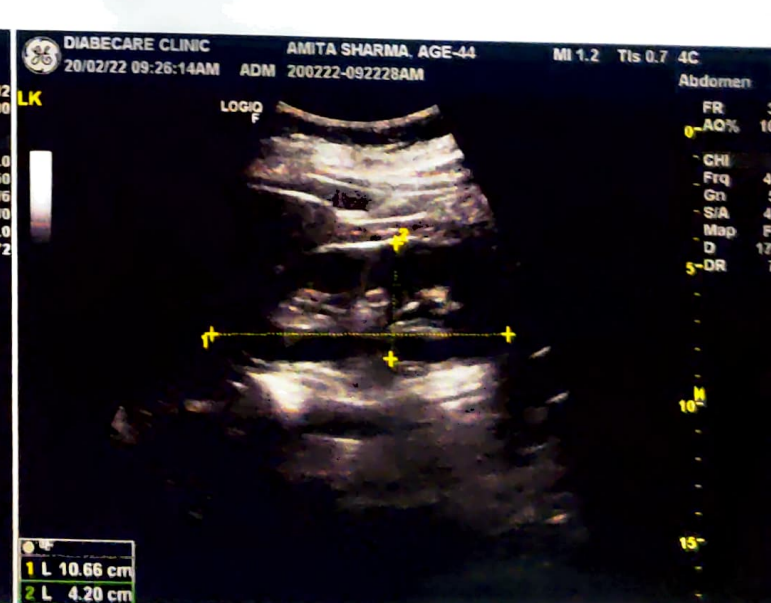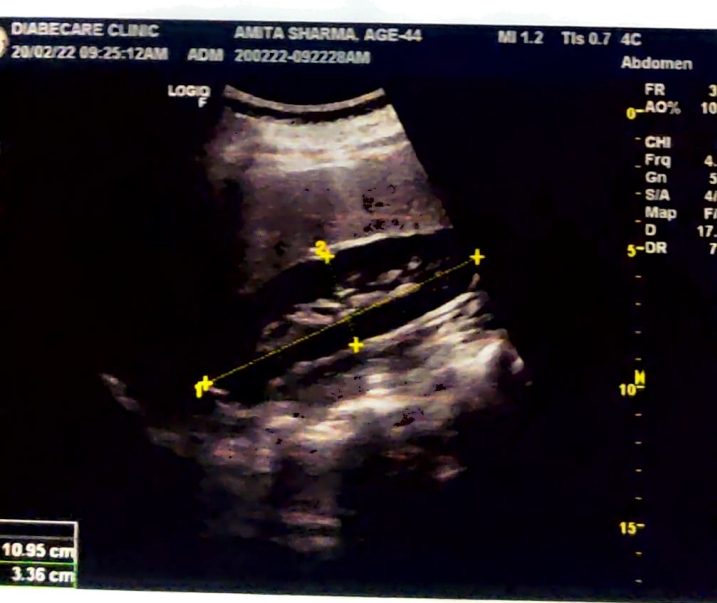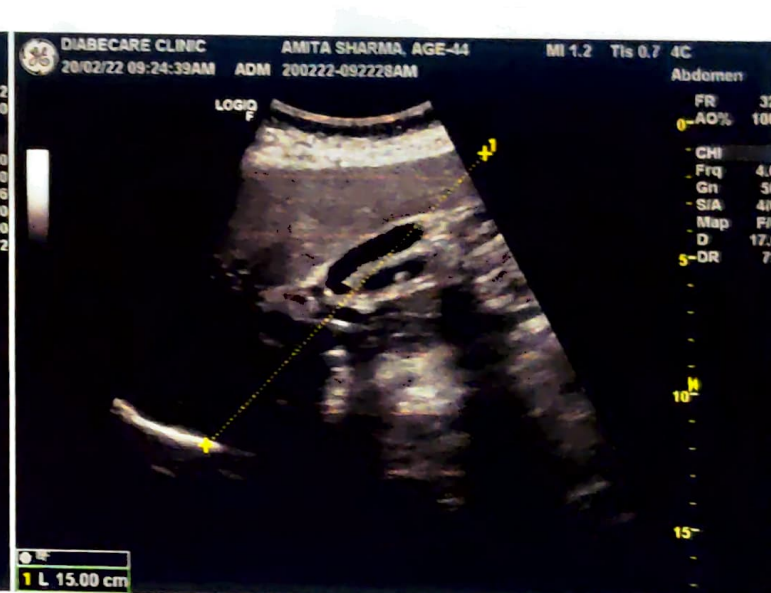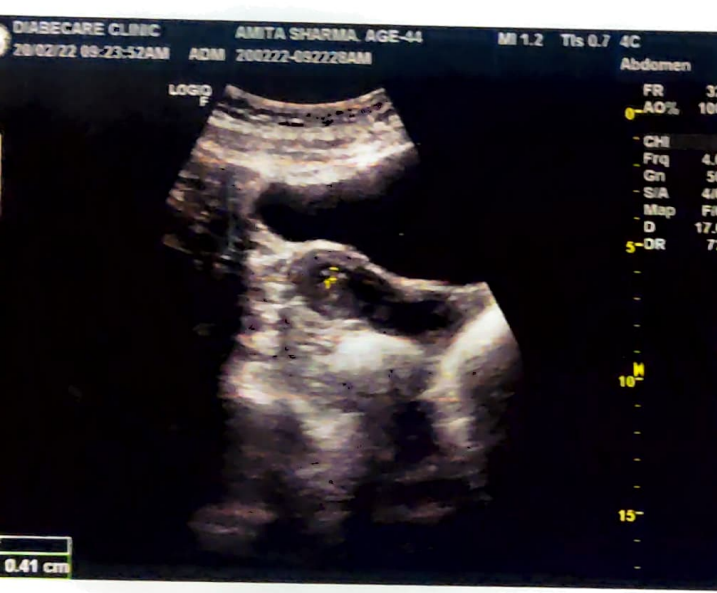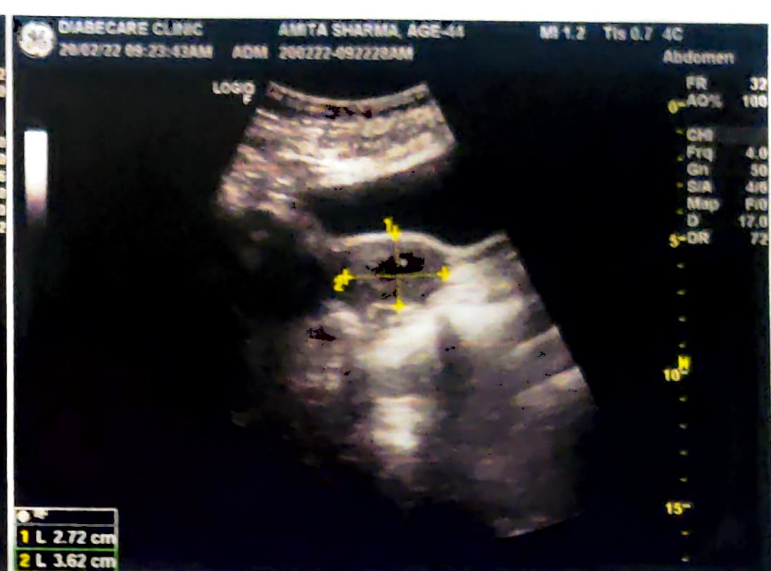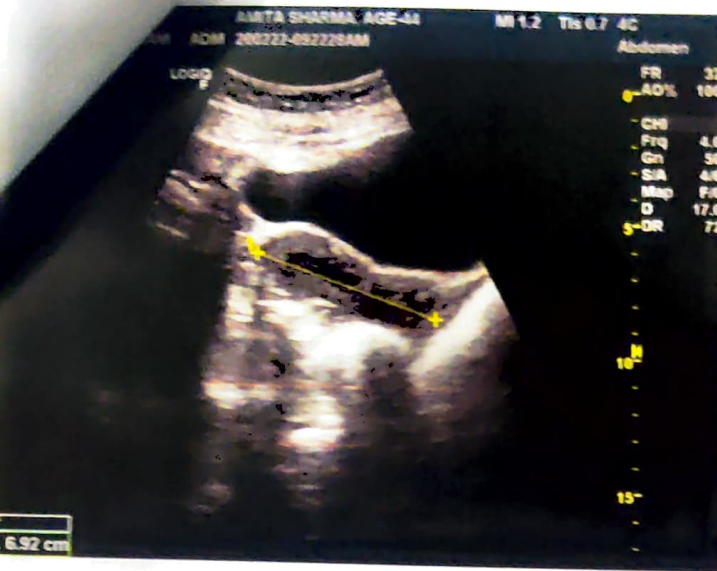Adv: clinical correlation





**DR.MRUDULA BABAR**  
**CONSULTANT RADIOLOGIST.**

**Dr. MRUDULA BABAR**  
DMRE, CPS Mumbai 2009  
(RADIOLOGIST)  
Reg. No. 2005/03/2139





Amita sharma  
ID: as

20.02.2022 11:14:47  
DIABECARE-DIABETES & ENDOCRINE  
OPP. GRAND CENTRAL MALL  
SEAWOOD

Female

QRS : 80 ms  
QT / QTcBaz : 380 / 424 ms  
PR : 160 ms  
P : 106 ms  
RR / PP : 802 / 800 ms  
P / QRS / T : 46 / 8 / 64 degrees

Normal sinus rhythm  
Normal ECG

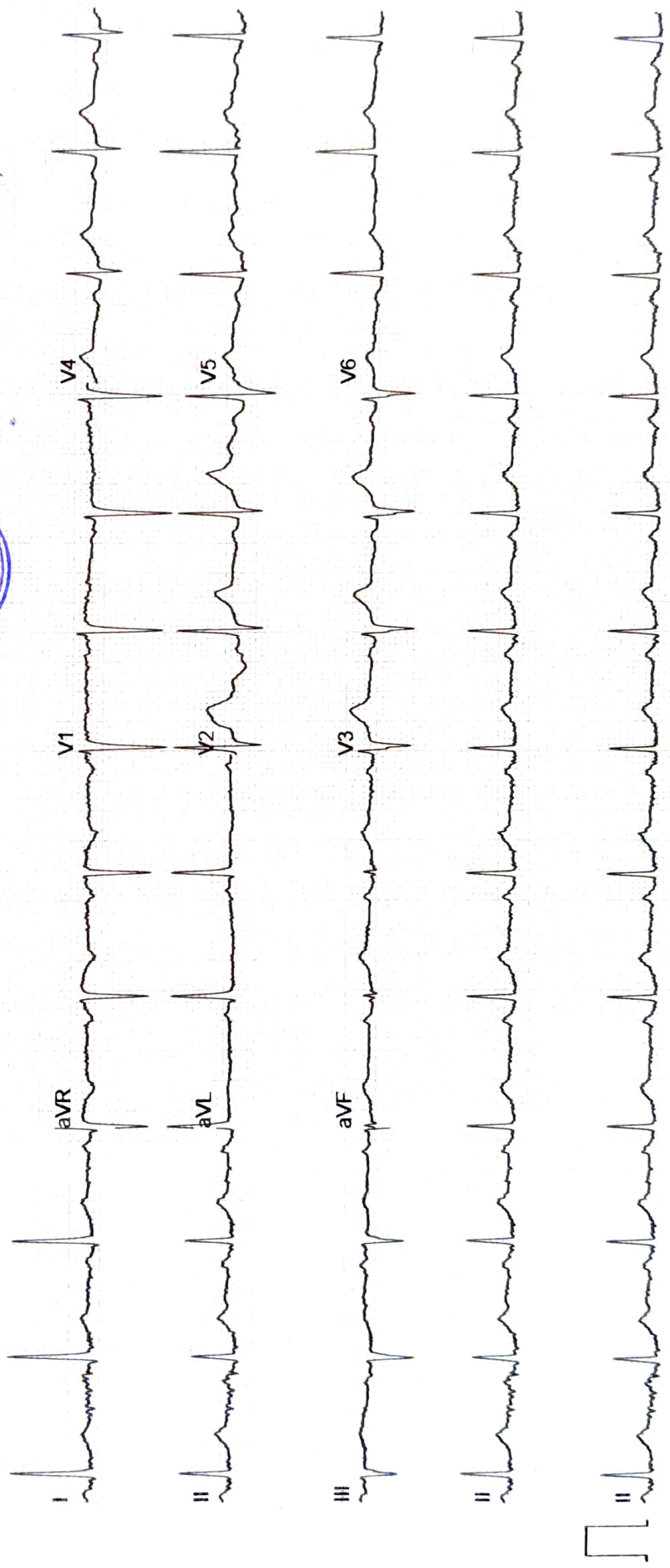
75 bpm  
- / - mmHg



*ECG - normal*




*Amita*

*Dr. Mahesh V. Padsalge*  
MD. (Medicine)  
Consultant Physician  
Reg. No. 91424 (MMC)




भारत सरकार  
Government of India


Download Date: 08/08/2021



**Amita Sharma**  
Date of Birth/DOB: 07/11/1977  
Female/ FEMALE

Issue Date: 05/08/2021


3338 2800 5666



VID : 9110 4442 3322 6248

---

मेरा **आधार**, मेरी पहचान

Amita


  
**Dr. Mahesh V. Padsalge**  
 MD. (Medicine)  
 Consultant Physician  
 Reg. No. 91424 (MMC)


भारतीय विशिष्ट पहचान प्राधिकरण  
Unique Identification Authority of India


Download Date: 08/08/2021

**Address:**  
W/O: Vishnu Kant Sharma, D-3/308  
SUBHASH NAGAR HOUSING COMPLEX,  
Serampore M, Hooghly,  
West Bengal - 712249




Issue Date: 05/08/2021



3338 2800 5666

VID : 9110 4442 3322 6248

---

 1947 | 
  help@uidai.gov.in | 
  www.uidai.gov.in





**DIABECARE - DIABETES & ENDOCRINE CLINIC**  
 OFFICE NO-03, PLOT NO-46647, RAMKRISHNA CHS, OPP. GRAND CENTRAL MALL, SEAWOODS , NAVIMUMBAI -400706

**MRS AMITA SHARMA**

**TREADMILL TEST REPORT**

ID : 9845  
 DATE : 20/02/2022  
 AGE/SEX : 44 / F  
 HT/WT : 156 / 67  
 REF. BY : MEDIWHEEL

PROTOCOL : Bruce  
 HISTORY :  
 INDICATION : FOR MEDIWHEEL  
 MEDICATION : PURPOSE,

PHASE	TOTAL TIME	STAGE TIME	SPEED Km/Hr	GRADE %	H.R. bpm	B.P. mmHg	RPP x100	ST LEVEL (MM)			METS
								II	V1	V5	
SUPINE					97	140 / 90	135	0.5	0.5	0.9	
HYPERVENT					93	140 / 90	130	0.1	0.6	0.7	
STANDING					97	140 / 90	135	0.3	0.5	0.5	
Stage 1	2:55	2:55	2.7	10	130	150 / 90	195	0.1	0.9	0.4	4.67
Stage 2	5:55	2:55	4	12	135	160 / 90	216	0.6	0.6	0	7.04
PR-EXERCISE	6:37	0:37	5.4	14	153	160 / 90	244	-0.8	1.2	-0.5	7.70
RECOVERY	9:40	2:55			116	150 / 90	174	-0.2	0.6	-0.5	
RECOVERY	9:40	2:55			116	150 / 90	174	-0.2	0.6	-0.5	
RECOVERY	12:40	5:55			113	140 / 90	158	0.4	0.7	0	
RECOVERY	12:40	5:55			113	140 / 90	158	0.4	0.7	0	
RECOVERY	15:40	8:55			101	140 / 90	141	0.3	0.6	0.5	
RECOVERY	15:40	8:55			101	140 / 90	141	0.3	0.6	0.5	

**RESULTS**

EXERCISE DURATION : 6:37  
 MAX HEART RATE : 153 bpm  
 MAX BLOOD PRESSURE : 160 / 90 mm Hg  
 REASON OF TERMINATION : Achieved THR,  
 BP RESPONSE : Normal,  
 ARRYTHMIA : None,  
 H.R. RESPONSE : Normal Chronotropic Response,  
**IMPRESSIONS** :  
 Negative for Provocable myocardial ischemia,  
 MAX WORK LOAD : 7.70 METS

*Amita*



*Dr. Mahesh V. Padsalge*  
 MD (Medicine)  
 Consultant Physician  
 Reg. No. 91424 (MMC)

Technician : **DR. MAHESH PADSALGE ( MD )**

# DIABECARE - DIABETES & ENDOCRINE CLINIC

MRS AMITA SHARMA  
 I.D. 9845  
 Age 44/F  
 Date 20/02/2022

RATE 97bpm  
 B.P. 140/90


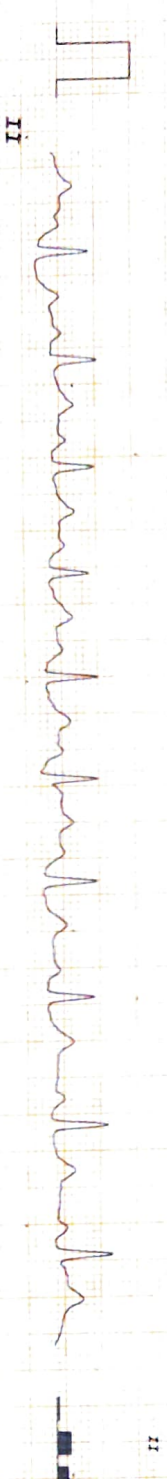


PRETEST  
 SUPINE

ST @ 10mm/mV  
 80ms PostJ

LINKED MEDIAN

Mag. X 2

V6





# DIABECARE - DIABETES & ENDOCRINE CLINIC

MRS AMITA SHARMA  
 I.D. 9845  
 Age 44/F  
 Date 20/02/2022

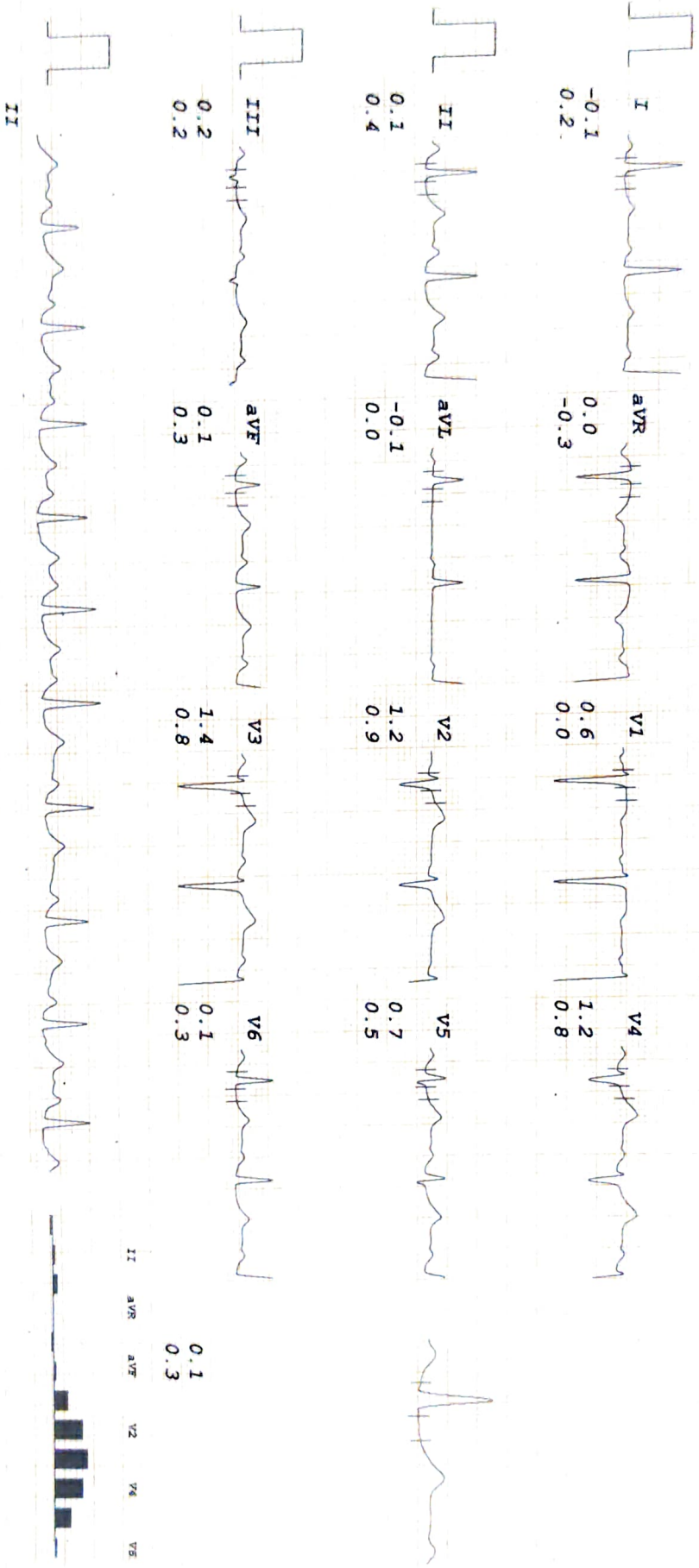
RATE 93bpm  
 B.P. 140/90

PRETEST  
 HYPERVENT

ST @ 10mm/mV  
 80ms PostJ

LINKED MEDIAN

Mag. X 2



# DIABECARE - DIABETES & ENDOCRINE CLINIC

MRS ANITA SHARMA  
 I.D. 9845  
 Age 44/F  
 Date 20/02/2022

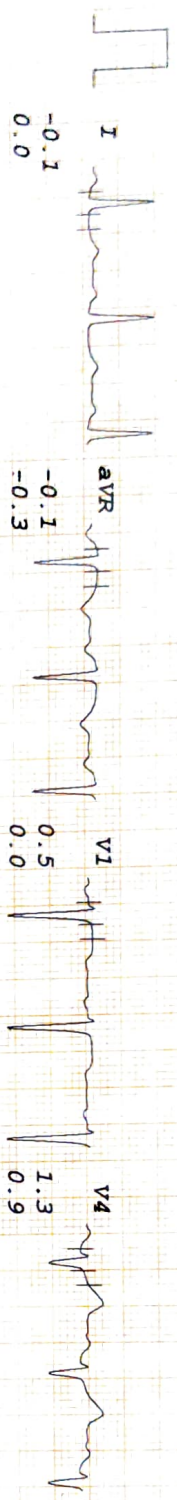
RATE 97bpm  
 B.P. 140/90  
 PRETEST  
 STANDING

ST @ 10mm/mV  
 80ms PostJ

LINKED MEDIAN

Mag. X 2

V6




I  
 -0.1  
 0.0

aVR  
 -0.1  
 -0.3

V1  
 0.5  
 0.0

V4  
 1.3  
 0.9




II  
 0.3  
 0.6

aVL  
 -0.3  
 -0.3

V2  
 1.3  
 0.8

V5  
 0.5  
 0.6

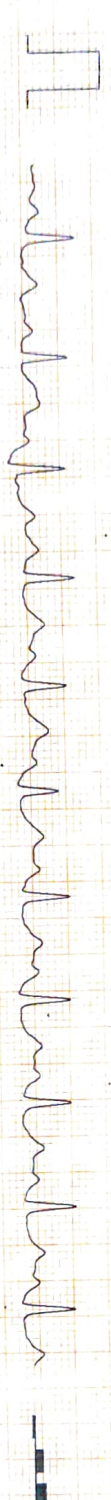


III  
 0.4  
 0.6

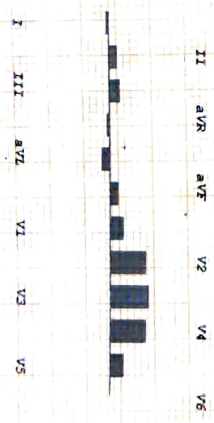
aVF  
 0.3  
 0.6

V3  
 1.4  
 0.9

V6  
 0.0  
 0.1



II



I III aVR aVL V1 V3 V5



# DIABECARE - DIABETES & ENDOCRINE CLINIC

MRS AMITA SHARMA  
 I.D. 9845  
 Age 44/F  
 Date 20/02/2022


Rate 130bpm  
 B.P. 150/90  
 Bruce Stage 1  
 TOTAL TIME 2:55  
 PHASE TIME 2:55

ST @ 10mm/mV  
 80ms PostJ  
 Speed 2.7 km/hr  
 SLOPE 10 %


LINKED MEDIAN

Mag. X 2

V6



I



II



III



aVR



aVL

0.3

0.5

1.2

1.0

0.3


0.3

0.3

0.3

II aVR aVF V2 V4 V6

I III aVL V1 V3 V5



# DIABECARE - DIABETES & ENDOCRINE CLINIC

MRS AMITA SHARMA  
 I.D. 9845  
 Age 44/F  
 Date 20/02/2022

RATE 135bpm  
 B.P. 160/90


Brucce  
 Stage 2  
 TOTAL TIME 5:55  
 PHASE TIME 2:55

ST @ 10mm/mv  
 80ms PostJ  
 Speed 4 km/hr  
 SLOPE 12 &

LINKED MEDIAN

Mag. X 2

V6

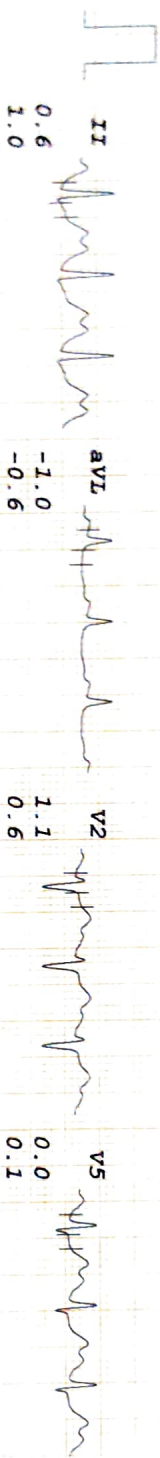


I  
 -0.7  
 -0.1

aVR  
 0.0  
 -0.4

V1  
 0.6  
 -0.4

V4  
 0.7  
 1.0




II  
 0.6  
 1.0

aVL  
 -1.0  
 -0.6

V2  
 1.1  
 0.6

V5  
 0.0  
 0.1




III  
 1.3  
 1.1

aVF  
 1.0  
 1.1


V3  
 1.1  
 1.2

V6  
 -0.7  
 -0.6

-0.7  
 -0.6



aVF  
 1.0  
 1.1





# DIABECARE - DIABETES & ENDOCRINE CLINIC

MRS AMITA SHARMA  
 I.D. 9845  
 Age 44/F  
 Date 20/02/2022

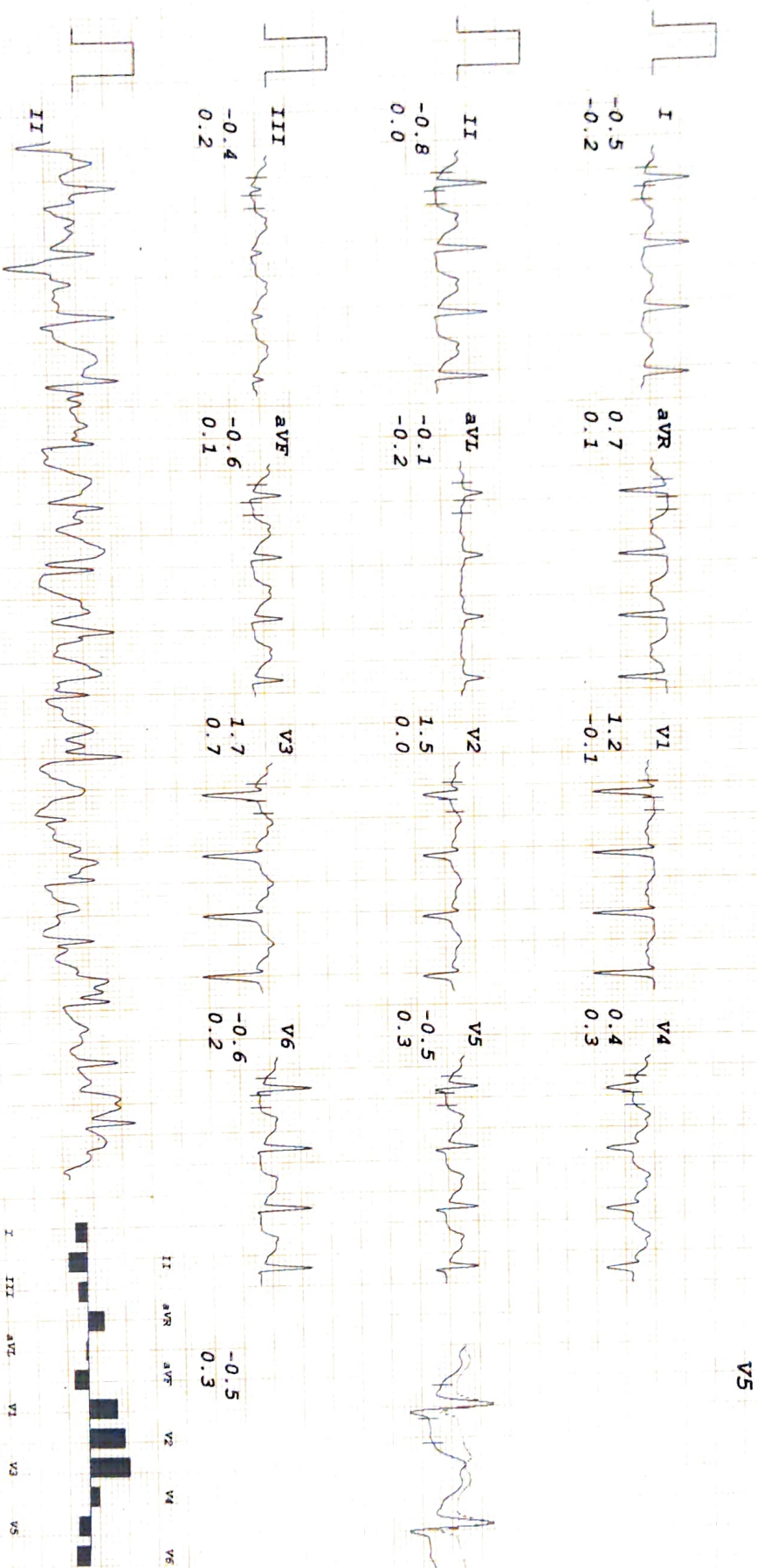
RATE 153bpm  
 B.P. 160/90

Bruce  
 PK-EXERCISE  
 TOTAL TIME 6:37  
 PHASE TIME 0:37

ST @ 10mm/mv  
 80ms PostJ  
 Speed 5.4 km/hr  
 SLOPE 14 %

LINKED MEDIAN

Mag. X 2







# DIABECARE - DIABETES & ENDOCRINE CLINIC

MRS ANITA SHARMA  
 I.D. 9845  
 Age 44/F  
 Date 20/02/2022


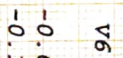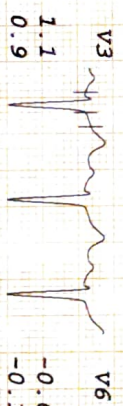

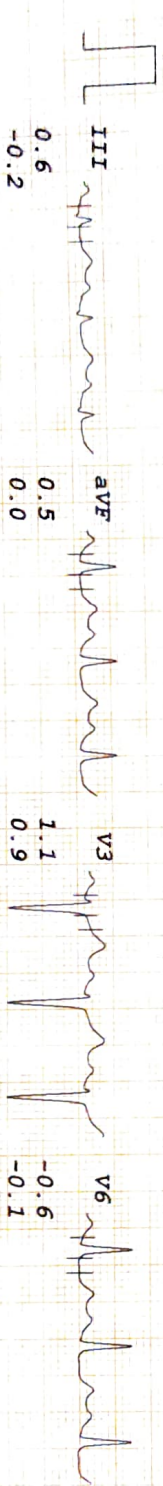
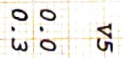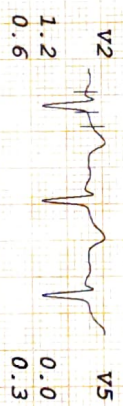


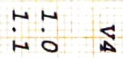
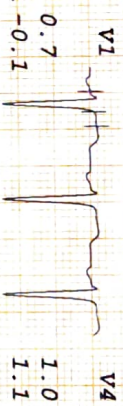


BRUCE  
 RATE 113bpm  
 B.P. 140/90  
 RECOVERY  
 TOTAL TIME 12:40  
 PHASE TIME 5:55

ST @ 10mm/mV  
 80ms PostJ

LINKED MEDIAN

Mag. X 2

V6



-0.6  
 -0.1



# DIABECARE - DIABETES & ENDOCRINE CLINIC

MRS AMITA SHARMA  
 I.D. 9845  
 Age 44/F  
 Date 20/02/2022

RATE 101bpm  
 B.P. 140/90





Brice  
 RECOVERY  
 TOTAL TIME 15:40  
 PHASE TIME 8:55

ST @ 10mm/mV  
 80ms PostJ

LINKED MEDIAN

Mag. X 2

V6





**NAME - AMITA SHARMA**

**DATE- 20/2/2022**

**AGE- 44/F**

**X-RAY CHEST PA**

THE SOFT TISSUES AND BONY THORAX ARE NORMAL.

BOTH THE COSTOPREHNIC AND CARDIOPHRENIC ANGLES ARE CLEAR.


THE LUNG FIELDS ARE NORMAL.

CARDIAC SHAPE AND SIZE APPEARS NORMAL.

BOTH THE HILA ARE NORMAL IN DENSITY AND POSITION.

BOTH THE DOMES OF DIAPHRAGM AND MEDIASTINUM ARE NORMAL.

**IMPRESSION: NORMAL CHEST X-RAY.**

For, 

**DR.MRUDULA BABAR**  
**RADIOLOGIST**

Dr. MRUDULA BABAR  
DMRF CPS Mumbai 2009  
(RADIOLOGIST)  
Reg. No. 2005/03/2139