



THAREJA CLINIC

DIGITAL X-RAY, & OPG COMPUTERISED ECG & EEG, DIAGNOSTIC
LABORATORY EQUIPED WITH COMPUTERISED AUTO ANALYZER & CBC



1, Ram Kuteer, Company Bagh Road, ALWAR - 301001 (Raj.) Ph: 0144-2700184, 2331842

PROPOSAL NO. PKG10000227

Patient Name MR. VISHWAS GAUR

Ref. By Dr. M. N. THAREJA

Date

12/07/2021

Age

28 Yrs.

Sex

M

Details of packages		Patients report	Units	Normal value
HB		13.1	gm%	M-13.5-18, F-11.5-16.5
TRBC		4.51	million /cu mm	M-4.0-5.5, F-3.9-5.6
TWBC		5900	cu mm	4000-11000
DLC	Polymorphs	60	%	42-75
	Lymphocytes	38	%	20-50
	Eosinophil	02	%	1-6
ESR		04	mm 1 st Hr.	M-0-9, F-0-20
Platelets		3,12000	Lack / cu mm	1.5-4
PCV		34.9	%	37-54
MCV		77.4	Cubicmicrons	86-98
MCH		29.0	Picograms	26-34
MCHC		37.5	%	32-36
Blood Grouping & Rh Factor		" B "Rh+(POSITIVE)		
BUN		14.5	mg %	M-7-20
S. Creatinine		0.91	Mg/100ml	0.9-1.4 mg /100 ml
HBsAg		-		
HIV I & II		-	Elisa Method	
HbA1C		5.4	%	4-6%
VDRL		-		

Details of packages		Patients report	Units	Normal value	
LFT	GGTP	33.5	U/L	5-60	
	SGOT	22.0	Units / ml	Upto 40	
	SGPT	27.0	Units / ml	Upto 40	
	S. Bilirubin	Total Bilirubin	0.56	mg%	Upto 1.2
		Direct Bilirubin	0.21	mg%	0-0.25
		Indirec Bilirubin	0.35	mg%	
		T. Protein	7.91	Gm%	6.2-8.3
	S. Albumin	4.60	Gm%	3.2-5.3	
	Globulin	3.31	Gm%		
	Alkaline phosphate	125.0	IU/L	60 - 170	
S. Calcium	-	Gm%	8.5-10.5		
Uric Acid	4.21	Mg%	2.5-7 mg%		
Blood Sugar Fasting		70.0	Mg%	60-110 mg %	
Blood Sugar PP		112.0	Mg%	Upto 160	
Lipid Profile	S. Cholesterol	215.0	mg%	120-220	
	S. Triglycerides	136.0	mg/ml	Upto 170	
	HDL Cholesterol	62.0	IU/L		
	LDL cholesterol	26.0	IU/L	450 at 37° C	
	VLDL	27.0	mg %	Upto 35	

Routine Urine Analysis

Physical/ Chemical		Microscopic:	
Appearance	Clear	RBCs	Nil
Specific Gravity	1010	WBCs	2-3/ HPF
Ph	ACIDIC	Epith. Cells	1-2/HPF
Albumin	Nil	Casts	Nil
Glucose F	NIL	Crystals	Nil
Ketones	----	Bacteria	Nil
Blood	Nil	Glucose P.P.	NIL

Signature of Technician

Signature of Doctor

Dr. M. N. THAREJA
MBBS
Thareja Nursing Home
-301001 (Raj.)

THIS REPORT IS NOT VALID FOR MEDICAL LEGAL PURPOSE



THAREJA CLINIC



1, Ram Kuteer Company Bagh Road, ALWAR (Raj.) ☎ 2700184, 2331842 (H)

POLY CLINIC EQUIPPED WITH COMPUTERISED AUTOANALYSER, CBC
SONOGRAPHY, X-RAY, OPG, COMPUTERISED ECG, EEG &
DIAGNOSTIC LABORATORY, COMPUTERISED LUNG FUNCTION TEST

DEADDICATION CENTRE

Dr. M.N. Thareja

M.B.B.S., F.C.G.P.

F.R.S.T.M. & H (London)

- ❖ Vice Chairperson of Sex Education & Parenthood International.
- ❖ Vice President of National Sexology Society of India
- ❖ Member of American Association of Sex Educator USA
- ❖ Executive Member of Indian Andro-Pause Society
- ❖ Life Member of Association for Prevention & Control of Rabies in India (APCRI)
- ❖ Life Member of Indian Red Cross Society
- ❖ Life Member of IMA College of General Practitioners
- ❖ Post Graduate Certificate Course of HIV/AIDS & STD Management Counsellor.
- ❖ Post Graduate Certificate Course Environmental & Occupational Health.

ELECTROCARDIOGRAM

Patient Name Vishwas gaur

Date 12-7-21 Age 28 Sex M

Referred by Dr. M.N. Thareja

Vishwas gaur

Age: 28 M / F

..... cm / kg

..... / mmHg

Intervals: QRS 90 °
 RR 841 ms T 34 ° 5.70
 P 102 ms
 PR 140 ms P (II) 0.12 mV
 QRS 88 ms S (V1) -0.64 mV
 QT 344 ms R (V5) 1.56 mV
 QTC 378 ms Sokol. 2.90 mV

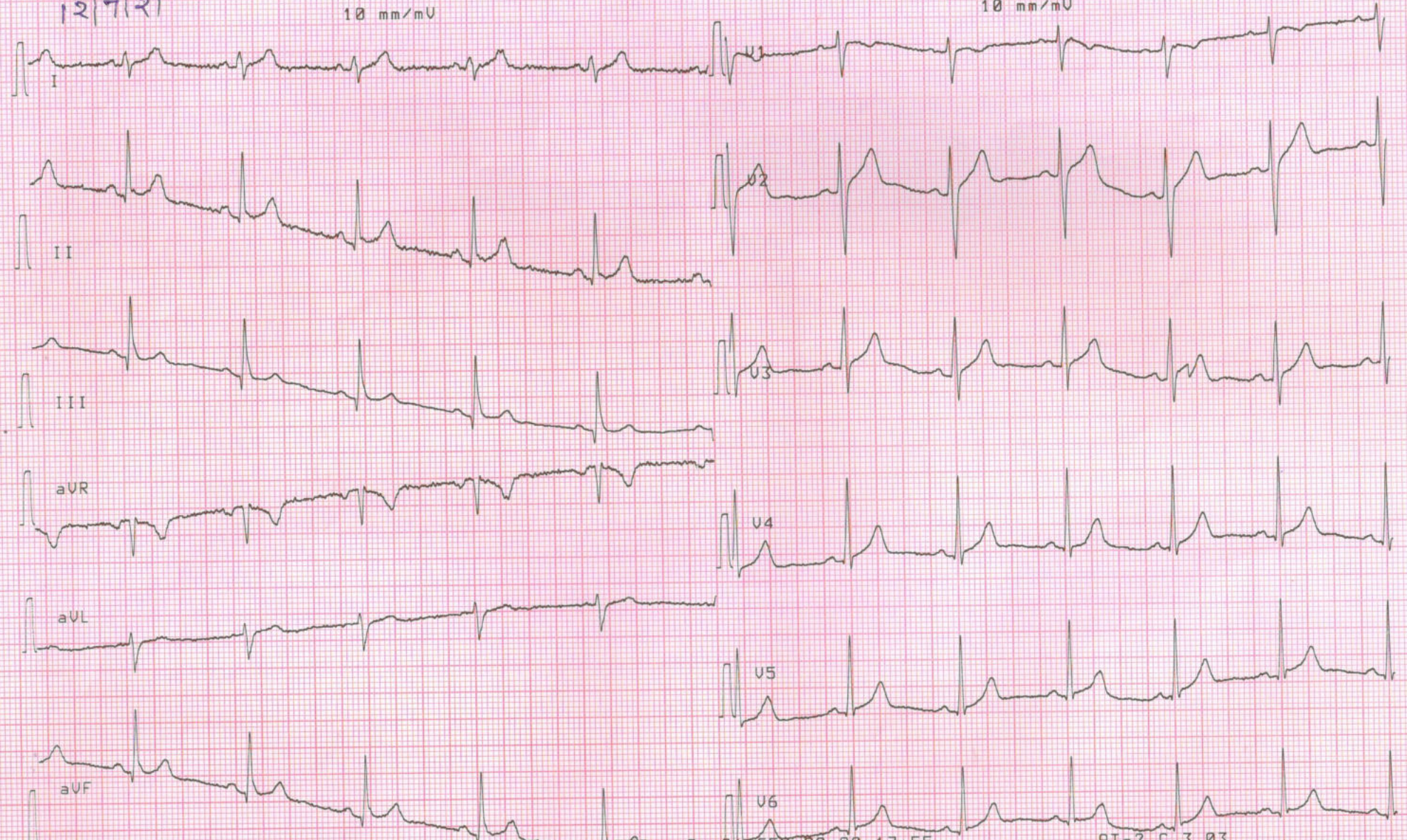
UNCONFIRMED REPORT

Signature

12/7/21

10 mm/mV

10 mm/mV



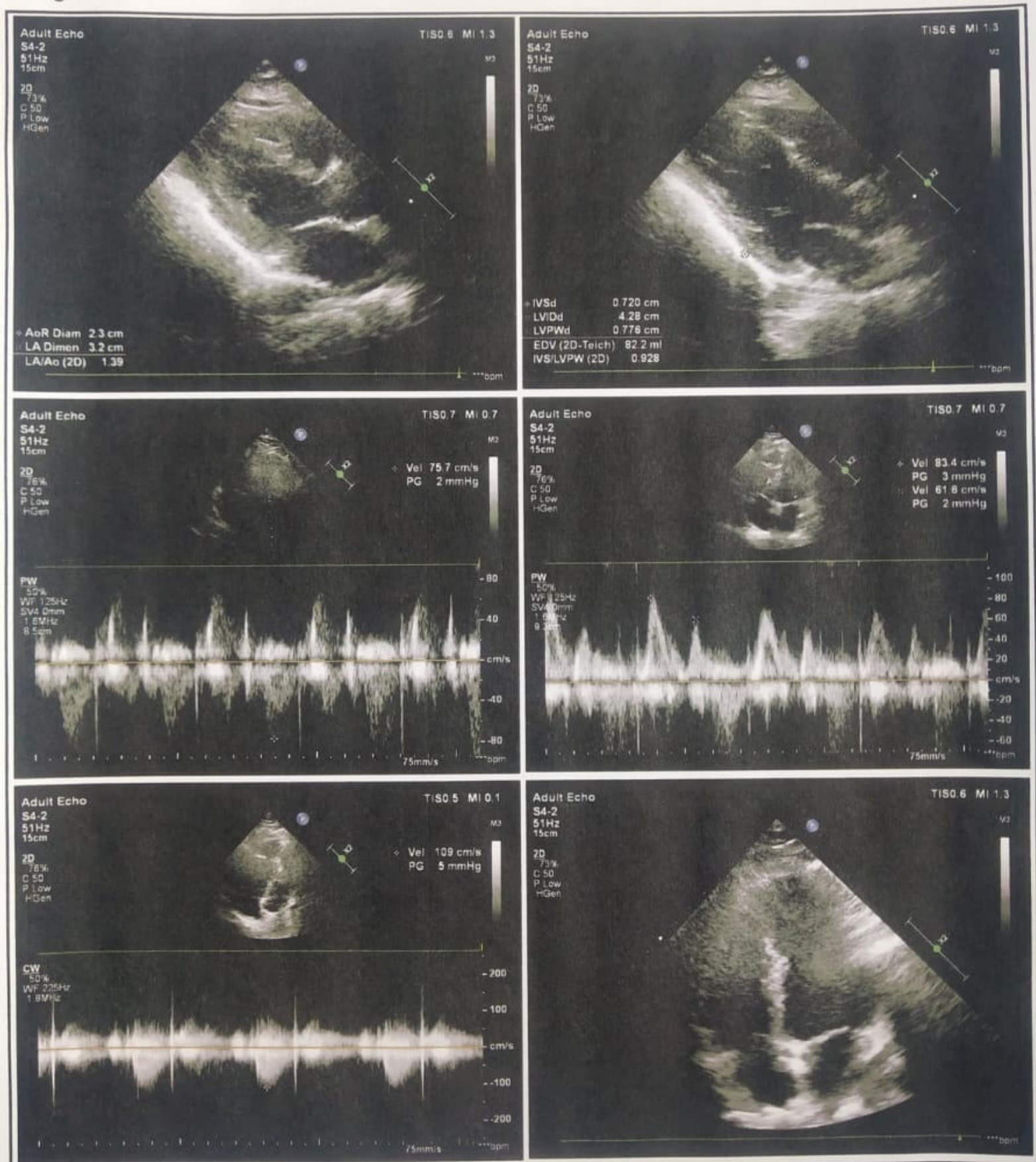
25 mm/s
SCHILLER

0.05-35 Hz E50 5mV 01-SEP-00 20:17:55

Part No.2.157017M CE0123 AT-2 C 3.03

TAH

Images





GUPTA ENT & HEART CENTRE

Dayanand Marg, Nangli Circle, Alwar Ph.: 0144-3591336, 7378184427

Echocardiography Report

Name : Mr. Vishwas God Refd by: Dr. M.N. Thareja
Age / Sex : 29yrs./male Date : 12 July 2021

Clinical Diagnosis : For Cardiac Evaluation

2D Echocardiography Findings

Mitral Valve : Normal
Aortic Valve : Normal
Tricuspid Valve : Normal
Pulmonary Valve : Normal
Left Atrium : 3.2cm: Normal
Left Ventricle : Normal LV size with normal LV systolic function. No RWMA

LVIDd	4.2cm.	IVSd	0.7cm.	EF	60%	Visual
LVIDs	2.3cm.	PWd	0.7cm.	EF	%	F.S.

Right Atrium : Normal
Right Ventricle : Normal
Aorta : 2.3cm: Normal
Pulmonary Artery : Normal
Pulmonary Veins : Normal
Superior Venacava : Normal
Inferior Venacava : Normal
Pericardium : Normal
Intracardiac Masses : No Intracardiac masses seen
IAS/IVS : Intact

Doppler Findings:

Valve	Peak Velocity (cm/s)	Peak Gradient (mmHg)	Mean Gradient (mmHg)	Regurgitation Grade	others/comments
Mitral Valve	E-/A-83/61			Mild MR	
Aortic Valve	109				
Tricuspid Valve				Trace TR, No PAH.	
Pulmonary Valve	75				

Diagnosis : Transthoracic echo done in supine position at resting heart rate of 70bpm, shows **Normal LV size with normal LV systolic function. LVEF~60% (Visual). No RWMA.**
Other cardiac chambers are normal in Size.
Mild MR, Trace TR, No PAH.
Normal MIP.
No pericardial effusion /Vegetation /Clot Intracardiac masses seen.
Normal left sided arch of aorta, No Coarctation.

M.N. Thareja
Dr. M. N. THAREJA
MBBS
Thareja Nursing Home
Alwar-301001, (Raj.)

Dr. Prachi Gupta
MBBS, PGDCC
(Non-invasive cardiologist)



THAREJA CLINIC

DIGITAL X-RAY, & OPG COMPUTERISED ECG & EEG, DIAGNOSTIC
LABORATORY EQUIPED WITH COMPUTERISED AUTO ANALYZER & CBC



1, Ram Kuteer, Company Bagh Road, ALWAR - 301001 (Raj.) Ph: 0144-2700184, 2331842

Name : **VISHWAS GAUR**

age **28**

Sex : **MALE**

Ref. By : **DR M.N.THAREJA**

Lab No. : **227**

Date : **July 12, 2021**

HORMONES & MARKERS

<u>Test</u>	<u>Value</u>	<u>Units</u>	<u>Biological Ref. Values</u>
T3 (Total Triiodothyronine)	1.76	ng/dL	0.60-1.81 ng/dL Adults
T4 (Total Thyroxine)	4.50	µg/dL	3.2-12.60 µg/dL : Adults
TSH (Thyroid Stimulating Hormone)	0.82	µIU/mL	Adults : 0.35-5.50 µIU/mL

Interpretation of TSH :-

Children

0 Days : 1.0~39.0 uIU/mL

5 days : 1.7~9.1 uIU/mL

1 year : 0.4~8.6 uIU/mL

2 years : 0.4~7.6 uIU/mL

3 years : 0.3~6.7 uIU/mL

4-19 years : 0.4~6.2 uIU/mL

Adults

20-54 years : 0.35-5.50 uIU/mL

55-87 years : 0.5-8.9 uIU/mL

Pregnancy

1st Trimester : 0.30 - 4.50 µIU/mL

2nd Trimester : 0.50 - 4.60 µIU/mL

3rd Trimester : 0.80 - 5.20 µIU/mL

Interpretation of TSH :-

Children

3.20 - 34.6 µIU/mL 1 - 2 Days

0.70 - 15.4 µIU/mL 3 - 4 Days

0.70 - 9.10 µIU/mL 15 Days - 5 Months

0.70 - 6.40 µIU/mL 5 Months - 20 Years

Pregnancy

0.30 - 4.50 µIU/mL 1st Trimester

0.50 - 4.60 µIU/mL 2nd Trimester

0.80 - 5.20 µIU/mL 3rd Trimester

Method : **Fluorescence Immunoassay Technology**


Sample Type : **Fresh Blood Serum**


Remarks :

Primary malfunction of the Thyroid gland may result in excessive (hyper) or Low (hypo) release of T3 or T4. In addition, as TSH directly affect thyroid function, malfunction of the pituitary or the hypothalamus influences the thyroid gland activity.

Disease in any portion of the thyroid-pituitary-hypothalamus system may influence the level of T3 and T4 in the blood, in Primary Hypothyroidism,



TSH levels are significantly elevated, while in secondary and tertiary hypothyroidism, TSH levels may be low. In addition, in Euthyroid sick syndrome, multiple alterations in serum thyroid function test findings have been recognized.


Signature of Technician


Dr. M.N. THAREJA
Signature of Doctor
MBBS

THIS REPORT IS NOT VALID FOR MEDICAL LEGAL PURPOSE

Thareja Nursing Home
Alwar-301001, (Raj.)


भारत सरकार
Government of India




विश्वास गौड
Vishwas Gaur
 जन्म तारीख / DOB: 21/11/1992
 पुरुष / Male

Issue Date: 25/01/2013

6006 3344 5360

भारो आधार, भारी ओणभ

Copy





भारतीय विश्व आणभ प्रधिकरण
Unique Identification Authority of India


सरनाम: S/O: अखिलेश कुमार गौड, 25, अशोक विहार, अलवर,
 राजस्थान, 301001

Address: S/O: Akhilesh Kumar Gaur, 25,
 ASHOK VIHAR, Alwar, Rajasthan, 301001

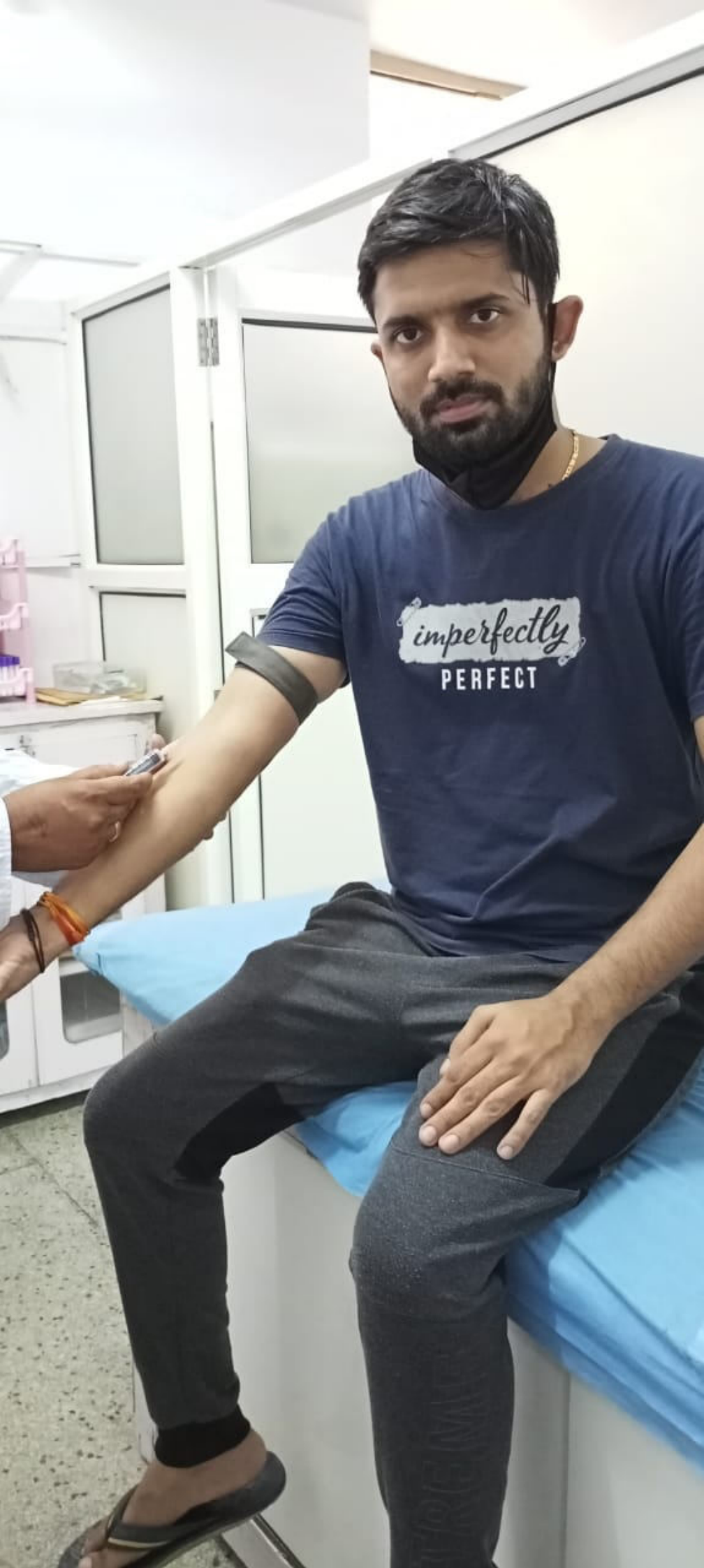Print Date: 11/01/2021

6006 3344 5360

 1947
  help@uidai.gov.in
 www.uidai.gov.in

Dr. M. N. Thareja

Dr. M. N. THAREJA
 MBBS
 Thareja Nursing Home
 Alwar-301001, (Raj.)



imperfectly
PERFECT



THAREJA SONOGRAPHY CENTRE

1, Ram Kuteer, Company Bagh Road, ALWAR - (0144) 2700184



This report is not valid for MLC Purpose

Ref. No.

Date.....
12/07/2021

Name of Patient: VISHVAS Age : 29 yrs. Sex: M
Ref.by : DR.SAVITA THAREJA

Sonography Report – abdomen

LIVER:	Size: RL: 13.6 cm	L. L.: 5.9 cm.
	Margins: Regular	I.H.B.R: ND
	Parenchyma : Echo	
C. B. D.	Size: 3.6 mm	LUMEN: Clear
P.V.	Size: -	LUMEN: Clear
GALL BLADDER :	Size: 4.6 X 1.9 cm	
Wall thickness	N	Lumen : Clear
PANCREAS:	N	
SPLEEN:	9.4 cm	
KIDNEYS: Right:	9.6 X 4.8 cm	
Left:	10.0 X 4.8 cm	

PELVICALYCAL SYSTEM:	N
CORTICO – MEDU. DIFF:	
RETROPERITONEUM :	Not Seen
LYMPH – NODES	
PLEURAL EFFUSION :	
ASCITES	
URINARY BLADDER:	
Prevoiding Volume	96 cc
Wall Thickness	N
PROSTATE: N	

Residual Urine:
Lumen: CLEAR

Capsule: Intact

Conclusion:- Normal Study.

Dr. Savita Thareja
Reg. No. 7600
Rajasthan Medical Council

Enclosed: Photo - 2

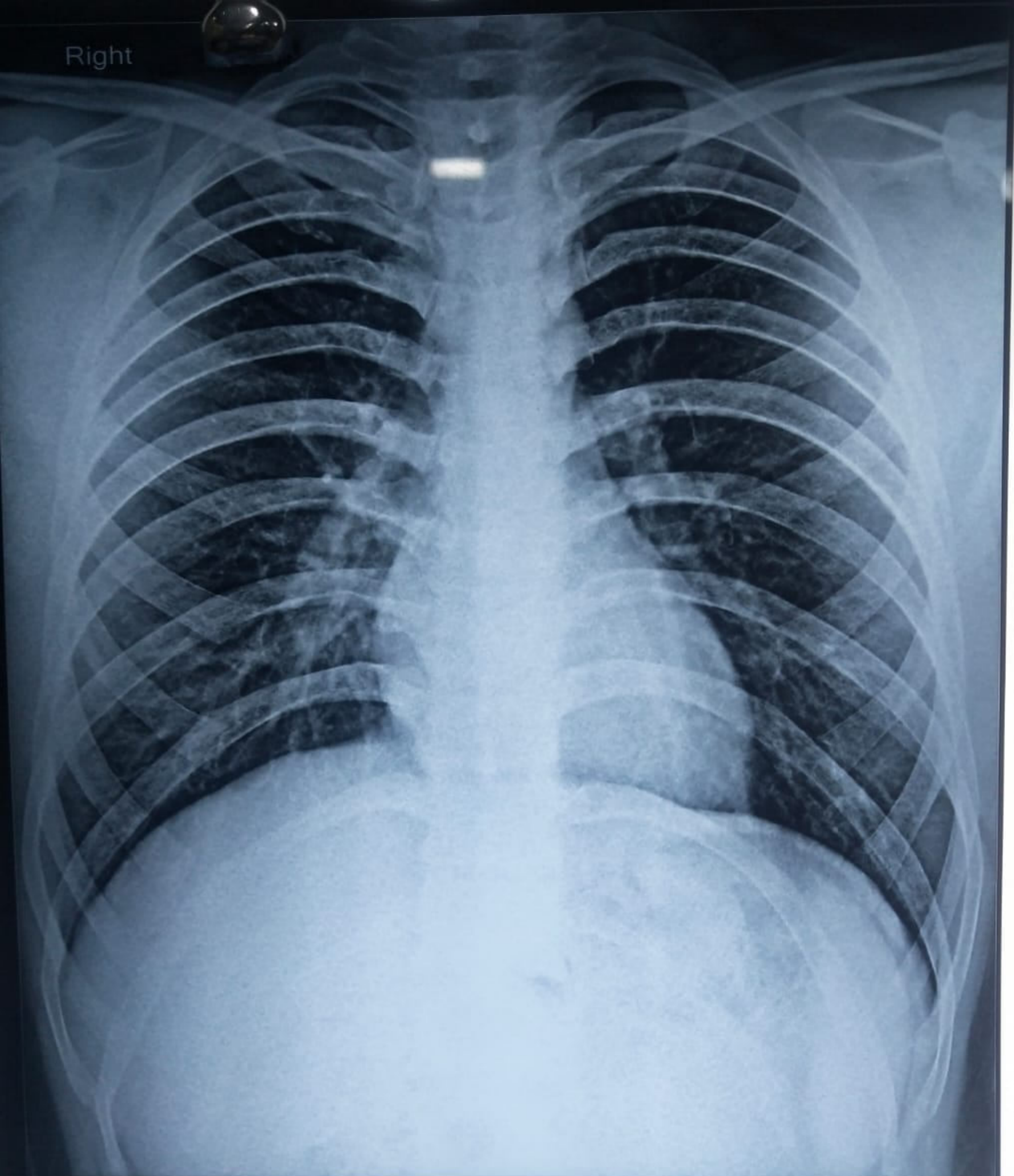
PLEASE NOTE: INTESTINAL PATHOLOGY CAN NOT BE RULE OUT

This is only an opinion, not a diagnosis, which should be clinically co-related. No procedure/surgery should be undertaken simply on the basis of this opinion because Ultrasound accuracy is only 96%.

* Subject to Alwar jurisdiction. * Not valid for medico-legal purpose.

Dr. M. N. THAREJA
MBBS
Thareja Nursing Home
Alwar-301001, (Raj.)

Right



VISHWAS GOUR 28 Y BY DR M.N.THAREJA 4343.21.1 M CHEST, PA 7/12/2021
THAREJA NURSING HOME. COMPANY BAGH ROAD, ALWAR

THAREJA CLINIC

DIGITAL X-RAY, COMPUTERISED ECG & EEG, DIAGNOSTIC LABORATORY
EQUIPED WITH COMPUTERISED AUTO ANALYZER

Dr. M.N. THAREJA
M.B.B.S., FCGP
F.R.S.T.M. & H. (LONDON)

1, RAM KUTEER
COMPANY BAGH ROAD
ALWAR-301001
PH. NO:-0144-2700184

Reciept No PKG10000227

Patient Name VISHWAS GAUR

Ref. By Dr. M.N.THAREJA


Date 12/07/2021


Age 28 Yrs.

Sex M

PART - X-RAYED : X-RAY CHEST PAVIEW
REPORT : X-RAYCHEST P.A. VIEW
:- Chest is bilaterally symmetrical.
:- C.P. Angles are clear.

CONCLUSSION:- NORMAL STUDY


SIGNATURE OF TECHNICIAN


SIGNATURE OF DOCTOR
Dr. M. N. THAREJA
MBBS
Thareja Nursing Home
Alwar-301001, (Raj.)

THIS REPORT IS NOT VALID FOR MEDICAL LEGAL PURPOSE