



## BANK OF BARODA MEDICAL EXAMINATION REPORT

Client name :- Rami Senkar  
 Ref. No. :- .....  
 Date of birth :- 12.09.1993 Sex :- Male / Female   
 Identification mark on the body :- nothing as such found  
 Photo ID Xerox :- Adhar card No. 62134091 6394  
 Date & place of medical examination :- 24.11.22, Asansol

Request for medical exam. of **BANK OF BARODA** through Medi Assist Health Care India (Pvt.) Ltd.

- A) 1. Height :- 162 cm.      2. Weight :- 66 kgs.  
 3. Chest Inspiration :- 103 cm.      4. Chest Expiration :- 100 cm.  
 5. Abdomen Girth :- 95 cm.  
 6. Blood Pressure :- I) 132/84 mm. of Hg. II) ..... mm. of Hg.  
 7. Pulse Rate :- 80 / minute.      Character of pulse :- Regular.
- B) 1. Are you now in good health ? Yes  
 2. Are you currently taking any medicine ? NO  
 3.) Are you married ? Yes  
 4. Have you ever had a positive test for HIV / AIDS / Malignancy ? NO  
 5. Have you ever suffering from sexually transmitted disease or Hepatitis B or C ? NO  
 6. Have you any congenital disorders ? NO  
 7. Have you any respiratory disorders ? NO  
 8. Have you any musculo skeletal disorders ? NO  
 9. Have you CVS disorders ? NO  
 10. Have you GI system disorders ? NO  
 11. Have you urinary system disorders ? NO  
 12. Have you reproductive system disorders ? NO

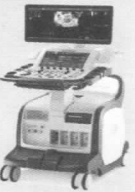



# ANUBIKSHAN

Diagnostic Centre

Near Asansol District Hospital(Main Gate)  
S.B. Gorai Road, Asansol-713301  
Email ID : anubikshan.dc@gmail.com  
Ph. : 0341-3590332, M. : 9732362727, 7872772680



13. Have you Diabetes / Hypertension / Endocrine disorders? NO
14. Have you ever done any surgical operation? NO
15. Have you any ear problem? NO
16. Have you any eye problem? NO
17. Have you nervous system disorders? NO
18. Have you any abnormal growth? NO
19. Have you any blood disorders? NO
20. What is general appearance of the client? Healthy
21. Does the appearance correspond with the age? Yes
22. Is there any personal peculiarities? NO
23. Tobacco (Stick / gms)- Panmasala/Cigar / Cigarette / Bidi / Gutkha Yes No  
Alcohol( ml)- Beer / Wine / Hard Liquor :- Qty./ Day For No. of Yrs

24.Family History	Age if living	Age at death	Present state of health or cause of death
Father	50y		Good health
Mother	45y		"
Brother (s)	30y, 25y		"
Sister (s)	32y		"

25. ANY REMARK BY THE MEDICAL EXAMINAR: - She is fit and healthy according to clinical and investigations reports.

Ravisakar  
Signature of the Client



Dr. S.K. SHAR  
Name of the Doctor

Date: - 24/11/2022

Dr. Sanjeev Kevin Shah  
Signature & Seal of the Doctor

Dr. Sanjeev Kevin Shah  
M.B.B.S., MD (Med.)  
Reg. No. 16138

ভারত সরকার  
Government of India

রানী সোনকার  
RANI SONKAR  
পিতা : অশোক সোনকার  
Father : ASHOK SONKAR  
জন্মতারিখ / DOB : 12/09/1993  
মহিলা / Female

6213 4091 6394

আধার - সাধারণ মানুষের অধিকার



*Ranisankar*

*Sanjeev*  
*Shah*  
Dr. Sanjeev Kevin Shah  
M.B.B.S., MD (Med.)  
Reg. No. 16138



# ANUBIKSHAN

Diagnostic Centre

Near Asansol District Hospital(Main Gate)  
S.B. Gorai Road, Asansol-713301  
Email ID : anubikshan.dc@gmail.com  
website: www.anubikshan.com

PATIENT ID: 2022K9537 NAME: RANI SONKAR AGE: 29 YR FEMALE  
ADVISED BY: Dr. .M.O., BANK OF BARODA.,  
DATE OF RECEIPT : 24/11/2022 DELIVERY DATE : 24/11/2022 TIME : 07:00 PM

## HEAMATOLOGY TEST

TEST	RESULT	NORMAL RANGE
* Haemoglobin :-	11.2 gm/dl	12 - 16 gm/dl
* Total Leucocyte Count :-	6,600 /cu mm	4,000-11,000/cu mm
* Differential Leucocyte Count ::		
* -----		
Neutrophil	60 %	40-75%
Lymphocyte	35 %	20-45%
Monocyte	01 %	2-10%
Eosinophil	04 %	1-6%
Basophil	00 %	0-1%
* Erythrocyte Sedimentation	15 mm / 1st hour	Less than 15 mm (M) Less than 20 mm (F)
* P. C. V.	44 %	45.0-50.0% (M) 37.0-47.0% (F)
* M. C. V.	89.8 fl.	77-93 fl
* M. C. H.	22.9 pg.	27.0-32.0 pg
* M.C.H.C.	25.5 gm/dl.	31.0-35.0 gm/dl
* Platelet Count	2,16,000 /cu mm	1.5 - 4.0Lakh/cu mm
* R. B. C.	4.9 million/cu mm	6.0-8.0million/cu mm(M) 3.8-5.8million/cu mm(F)

All Reference ranges are age and sex matched. Reference limit mentioned herein are in accordance with the literature provided along with the kit. Which may change in chemistry or the kit.

**DR. APARNA MONDAL.**  
M.B.B.S., M.D (Pathology)  
(Regd. No. 57881)

**DR. SWARUP GHOSH**  
M.B.B.S., M.D (Pathology)  
(Regd. No. 52140)



# ANUBIKSHAN

Diagnostic Centre

Near Asansol District Hospital(Main Gate)  
S.B. Gorai Road, Asansol-713301  
Email ID : anubikshan.dc@gmail.com  
website: www.anubikshan.com

PATIENT ID:2022K9537 NAME: RANI SONKAR AGE:29 YR FEMALE  
ADVISED BY:Dr. .M.O., BANK OF BARODA.,  
DATE OF RECEIPT : 24/11/2022 DELIVERY DATE : 24/11/2022 TIME : 07:00 PM

## BIO CHEMISTRY REPORT

TEST	RESULT	NORMAL RANGE
Plasma Glucose (Fasting)	80.4 mg/dl	70 - 115 mg/dl
Plasma Glucose (P.P)	DUE SAMPLE	80 - 150 mg/dl.
Uric-Acid	3.5 mg/dl	2.6 mg/dl - 6.0 mg/dl
B.U.N.	15.4 mg/dl	5.0 - 21.0 mg/dl
Creatinine	0.86 mg/dl	0.7 - 1.4 mg/dl
Cholesterol	135.0 mg/dl	00 - 200 mg/dl
Triglyceride	105.0 mg/dl	0 - 200 mg/dl
HDL Cholesterol	40.0 mg/dl	40 - 90.0 mg/dl
LDL Cholesterol	74.0 mg/dl	00 - 130 mg/dl
V.L.D.L.	21.0 mg/dl	23 - 45 mg/dl
CHOLESTEROL/HDL RATIO	3.4 : 1	upto - 5.0
LDL/HDL RATIO	1.9 : 1	upto - 3.0
Serum Bilirubin(Total)	0.84 mg/dl	0.1 - 1.2 mg/dl
Serum Bilirubin (Direct)	0.33 mg/dl	0.0 - 0.4 mg/dl
Serum Bilirubin(Indirect)	0.51 mg/dl	UPTO - 0.8 mg/dl

All biochemistry done by fully automated system Diasys respons 910.

All Reference ranges are age and sex matched. Reference limit mentioned herein are in accordance with the literature provided along with the kit. Which may change in chemistry or the kit.

**DR. APARNA MONDAL.**  
M.B.B.S., M.D (Pathology)  
(Regd. No. 57881)

**DR. SWARUP GHOSH**  
M.B.B.S., M.D (Pathology)  
(Regd. No. 52140)



# ANUBIKSHAN

Diagnostic Centre

Near Asansol District Hospital(Main Gate)  
S.B. Gorai Road, Asansol-713301  
Email ID : anubikshan.dc@gmail.com  
website: www.anubikshan.com

PATIENT ID:2022K9537 NAME: RANI SONKAR AGE:29 YR FEMALE  
ADVISED BY:Dr. .M.O., BANK OF BARODA.,  
DATE OF RECEIPT : 24/11/2022 DELIVERY DATE : 24/11/2022 TIME : 07:00 PM

## BIO CHEMISTRY REPORT

TEST	RESULT	NORMAL RANGE
S.G.P.T	29.6 U/L	00 - - 35.0 U/L
S.G.O.T	25.4 U/L	00 - 31.0 U/L
Alkaline Phosphatase	75.3 U/L	35 - 105 U/L
Total Protein	7.3 gm/dl	6.6 - 8.8 gm/dl
Albumin	4.0 gm/dl	3.5 - 5.2 gm/dl
Globulin	3.3 gm/dl	2.3 - 3.5 gm/dl
A : G	1.2:1	upto - 2.5:1
G.G.T	25.4 U/L	00 - 38 U/L

All biochemistry done by fully automated system Diasys respons 910.

All Reference ranges are age and sex matched. Reference limit mentioned herein are in accordance with the literature provided along with the kit. Which may change in chemistry or the kit.

**DR. APARNA MONDAL.**  
M.B.B.S., M.D (Pathology)  
(Regd. No. 57881)

**DR. SWARUP GHOSH**  
M.B.B.S., M.D (Pathology)  
(Regd. No. 52140)



Pathology Department

REPORT ON EXAMINATION OF

**GLYCOSYLATED HEMOGLOBIN**

PATIENT'S NAME:- RANI SONKAR	AGE: - 29 YEAR	SEX:- FEMALE
REF. BY DR.:- M.O. BANK OF BARODA.	DATE:- 24-11-2022	

## HbA1C

<u>TEST</u>	<u>RESULT</u>	<u>NORMAL RANGE</u>
HbA1C	4.2 %	NON-DIABETIC - (<6% )
		GOOD CONTROL-(6.0%-7%)
		FAIR CONTROL- (7.1%-8%)
		POOR CONTROL- (>8%)

**Alert: -** Poor control may develop long term complications such as Retinopathy, Nephropathy, Neuropathy and Cardiopathy etc.

**Comment: -** MBG is a value calculated from HbA1c and indicator of average more or less glucose Level over past three months.

DR. APARNA MONDAL.  
M.B.B.S., M.D (Pathology)  
(Regd. No. 57881)

DR. SWARUP GHOSH  
M.B.B.S., M.D (Pathology)  
(Regd. No. 52140)



# ANUBIKSHAN

Diagnostic Centre

Near Asansol District Hospital(Main Gate)  
S.B. Gorai Road, Asansol-713301  
Email ID : anubikshan.dc@gmail.com  
website: www.anubikshan.com

PATIENT ID: 2022K9579    NAME: RANI SONKAR    AGE: 29 YR    FEMALE  
ADVISED BY: Dr. .M.O., BANK OF BARODA.,  
DATE OF RECEIPT : 25/11/2022    DELIVERY DATE : 25/11/2022    TIME : 07:00 PM

## URINE ROUTINE EXAMINATION

### PHYSICAL EXAMINATION

Colour : STRAW  
S.P.Gravity : 1.010  
Appearance : HAZY  
Sediment : NIL

### CHEMICAL EXAMINATION

pH : 6.0  
Protein : TRACE  
Sugar : NIL  
Blood : NIL

### MICROSCOPICAL EXAMINATION

R.B.C : NIL  
Pus Cells : 1-2/HPF  
Epethilial Cells : 0-1/HPF  
Casts : NOT FOUND  
Crystals : NOT FOUND  
Bacteria : NOT FOUND  
Others : NOT FOUND

All Reference ranges are age and sex matched. Reference limit mentioned herein are in accordance with the literature provided along with the kit. Which may change in chemistry on the kit.

**DR. APARNA MONDAL.**  
M.B.B.S., M.D (Pathology)  
(Regd. No. 57881)

**DR. SWARUP GHOSH**  
M.B.B.S., M.D (Pathology)  
(Regd. No. 52140)

Phone : 0341-2221195, Mobile : 9732362727, 7872772680




 ভারত সরকার  
 Government of India

রানী সোনকার  
 RANI SONKAR  
 পিতা : অশোক সোনকার  
 Father : ASHOK SONKAR  
 জন্মতারিখ / DOB : 12/09/1993  
 মহিলা / Female



**6213 4091 6394**

**আধার - সাধারণ মানুষের অধিকার**

*Dr. Sanjeev*  
 24.11.20



Dr. Sanjeev Kevan Shah  
 M.B.B.S., MD (Med.)  
 Reg. No. 16138

Unique Identification Authority of India

ঠিকানা:  
 গৌর মন্দির রোড, আসনোল,  
 আসনোল (১ম ফ্ল),  
 আসনোল, বর্ডামান, পশ্চিমবঙ্গ,  
 Bardhaman, West Bengal, 713301

Address:  
 GOUR MANDHIR ROAD,  
 ASANSOL, Asansol MC, Asansol,  
 Bardhaman, West Bengal, 713301

6213 4091 6394

1947  
 1800 300 1947

help@uidai.gov.in  
 www.uidai.gov.in

# Dr. Rajib Banerjee

B.Sc., B.H.M.S., DOS (Kol)  
Consultant Homoeopathic Physician  
and optometric Eye Specialist

## ADDRESS :

1 No. Mohishila Colony  
Bottala Bazar  
Asansol - 3  
Mob. : 9832197360

Rx

Ravi Senkar

Rt. Eye		Lt. Eye	
Sph	Cyl	Sph	Cyl
0	0	0	1
Near Add. →	0	Near Add. →	1

C 0/6  
VA < 9/6  
Near vision - NC  
CV - Normal

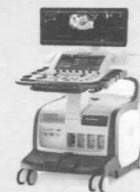

25/11/22

### Chamber

Balananda Homoeo Clinic  
Khejurtala More  
Mohishila - 2, Asansol

Morning : 8.00 a.m. to 9.00 a.m.  
Evening : 6.00 p.m. to 9.30 p.m.  
Saturday Evening Closed  
& Sunday Morning Closed




## ELECTRO CARDIO GRAM FORMAT

<b>PATIENT NAME:- RANI SONKAR</b>
<b>AGE:- 29 YRS      GENDER:- FEMALE</b>
<b>REF BY DR:- M.O. BANK OF BARODA.      DATE:- 24.11.2022</b>

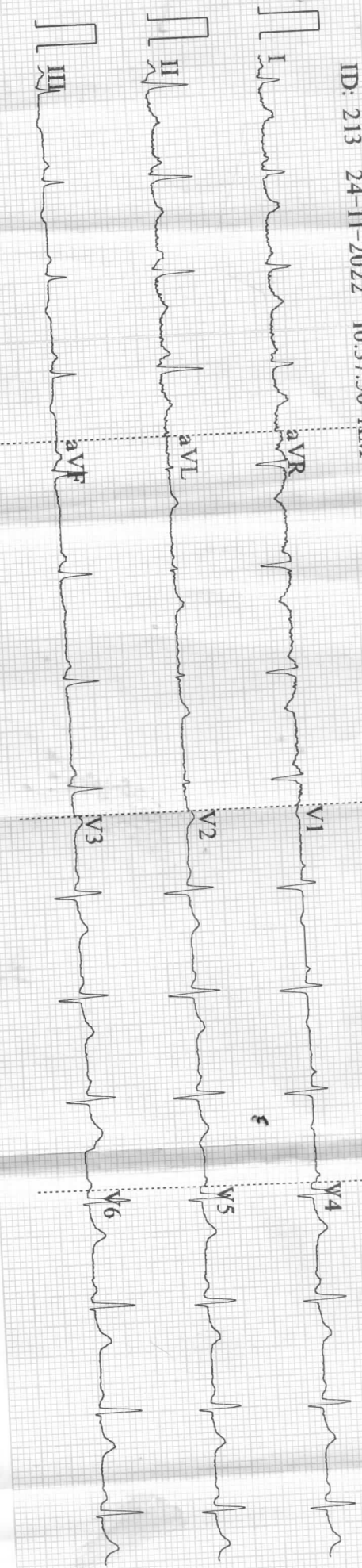
- ❖ RATE :- 88/m
- ❖ AXIS :- (N)
- ❖ P- WAVE :-
- ❖ P-R :-
- ❖ QRS :- (N)
- ❖ ST - T :-
- ❖ T - WAVE :-

➤ **IMPRESSION :-** NAD

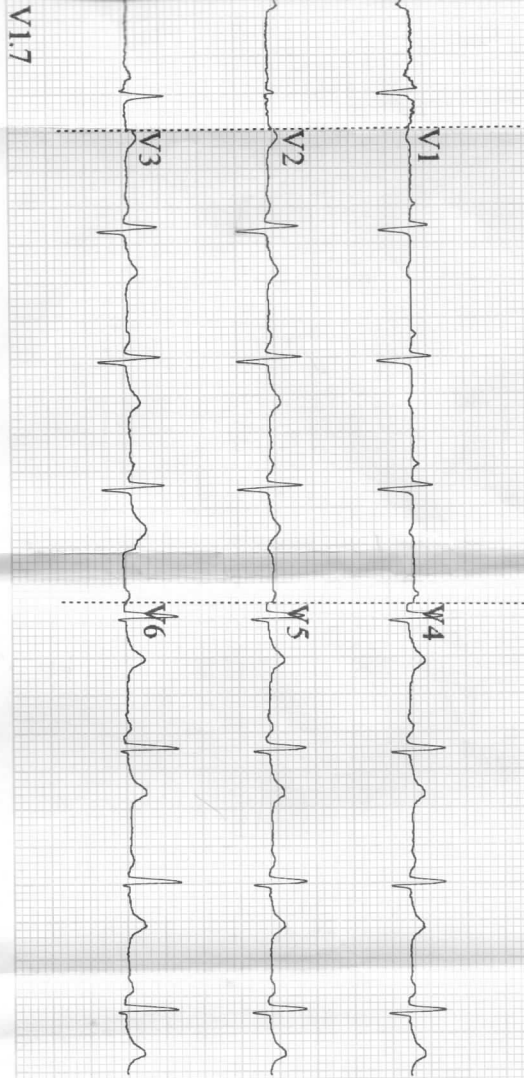
  
**Dr. Kaushik Sur**  
MD. DM (Cardio)  
Reg. No. WB.-62545

ID: 213 24-11-2022 10:37:50 AM

0.67~35Hz AC50 25mm/s 10mm/mV ●92 V1.0 SEMIP V1.7  
CARDIART



BPL



BPL

ID: 213

Female  
29 Years  
cm

kg  
mmHg

Diagnosis Information:  
Sinus Rhythm  
Poor R Wave Progression (V4)  
Low Voltage (Chest Leads)

*David S. [Signature]*

HR	:	88	bpm
P	:	98	ms
PR	:	124	ms
QRS	:	75	ms
QT/QTc	:	344/418	ms
P/ORS/T	:	57/52/16	°
RV5/SV1	:	0.500/0.418	mV

Report Confirmed by:



# KRISHNA DIAGNOSTICS (P) LTD

Where You Matter Most



AN ISO CERTIFIED LABORATORY

UID: 1058577

Nationality: Indian



<b>Patient ID:</b> 012211240187	<b>Primary Sample Collection Time:</b> 24/Nov/2022 13:52:48
<b>Name:</b> Ms. RANI SONKAR	<b>Collection Date/Time:</b> 24/Nov/2022 01:59PM
<b>Age/Gender:</b> 29 Y/Female	<b>Received Date/Time:</b> 24/Nov/2022 07:18PM
<b>Referred By:</b> Dr. M.O. BANK OF BARODA	<b>Approved Date/Time:</b> 24/Nov/2022 09:31PM
<b>LabID:</b> 11058226	<b>Print Date/Time:</b> 24/Nov/2022 10:19PM
<b>SpecimenType:</b> Serum	<b>Client Grp.:</b> NIBEDITA COLLECTION

## DEPARTMENT OF IMMUNOLOGY

Test Description	Observed Value	Unit	Method	Biological Ref. Interval
<b>T3, T4, TSH (THYROID PROFILE)</b>				
Triiodothyronine, Total (TT3)	1.00	ng/ml	CMIA	0.58 to 1.59
Thyroxine, Total (TT4)	8.03	ug/dl	CMIA	4.87 to 11.72
Thyroid Stimulating Hormone (TSH)	2.85	µIU/ml	CMIA	0.35 to 4.94
Ultrasensitive / Third generation assay				

TSH Clinical Condition	Range (µIU/mL) ECI	Range (uIU/mL) CMIA
Euthyroid	0.46-4.68	0.35-4.94
Hyperthyroid	<0.46	<0.35
Hypothyroid	>4.68	>4.94

### \* TSH: Interpretation (Pregnancy)

REFERENCE GROUP	REFERENCE RANGE in uIU/mL (As per American Thyroid Association)
Pregnancy	
1st Trimester	0.100 - 2.500
2nd Trimester	0.200 - 3.000
3rd Trimester	0.300 - 3.000

### COMMENT :

The levels of thyroid hormone (T3 & T4) Are Low In case of Primary, secondary and tertiary hypothyroidism and sometimes in non-thyroidal illness also. Increased levels are found in grave's disease, hyperthyroidism and thyroid hormone resistance. T3 levels are also raised in T3 thyrotoxicosis. TSH levels are raised in primary hypothyroidism and are low in hyperthyroidism and secondary hypothyroidism.

Disclaimer: The test result mentioned here should be interpreted in view of clinical condition of the patient. In case of any clinical suspicion regarding any parameter, repeat test with fresh sample essential to conclude.

\*\*\* End Of Report \*\*\*

DR. PARTHA PRATIM PURKAIT  
MBBS, MD(PATH)  
CONSULTANT PATHOLOGIST



MC-4154

Dr. N. Mondal  
MD (Biochemistry)  
Consultant Biochemist

Our Presence: Burdwan | Delhi | Kalyani | Kolkata | Odissa | Patna | Ranchi | Sharanpur (U.P) | Siliguri  
Vaishali (Delhi NCR)

Entered By: PARTHA & N. MONDAL



PATIENT'S NAME:- RANI SONKAR      AGE:- 29 YEARS      SEX:- FEMALE

REFERRED BY DR:- BANK OF BARODA      DATE:- 24.11.2022



## Transthoracic Echo 2-D/M-Mode, Echo Report

### 2-D/ M-Mode Measurements :( mm.)

	Observed Values(mm)	Normal Values(mm)
Aortic root diameter	31.92	20 – 36 mm
Left Atrium Size	31.96	19 – 40 mm

	End Diastolic(mm)	End Systolic(mm)	Normal Values(mm)
Interventricular Septum	11.40	15.20	ED=6-10
Left Ventricle Size	40.28	27.36	ED=37-53; ES=22-40
Posterior Wall Thickness	11.40	16.72	ED=5-10

LV Ejection Fraction (%)	60.78 %	55 – 80%
--------------------------	---------	----------

### ❖ FINDINGS :-

1. No LV Regional Wall Motion Abnormality, Global LVEF is 60.78 %.
2. Normal Cardiac chambers dimension.
3. All valves normal.
4. Normal L.V. Compliance.
5. No intracardiac clot/veg.
6. No pericardial effusion.
7. Normal RV systolic function.

### ❖ IMPRESSION:-

❖ NORMAL 2D ECHOCARDIOGRAPHY.

**DR. KAUSHIK SUR.**  
(M.B.B.S., M.D., D.M)  
(Sr. Consultant Interventional Cardiologist  
(Regd. No: - WB-62545)

PATIENT'S NAME:- RANI SONKAR

AGE:- 29 YEAR      SEX:- FEMALE

REF BY DR: - BANK OF BARODA

DATE:- 24.11.2022

2D ECHO DONE BY :-

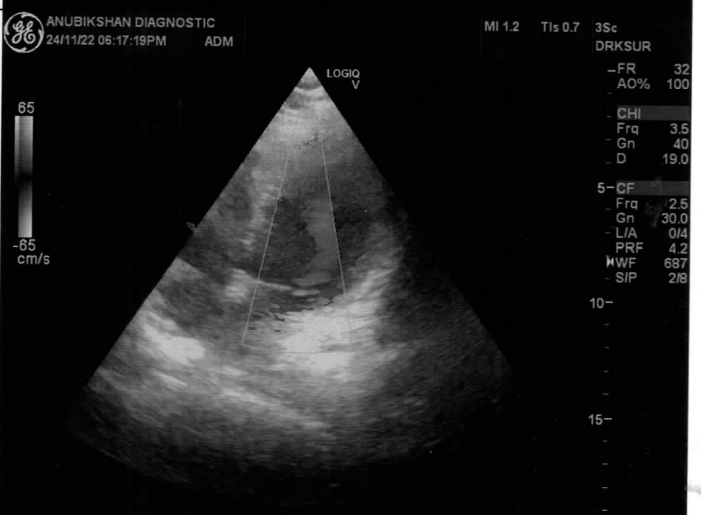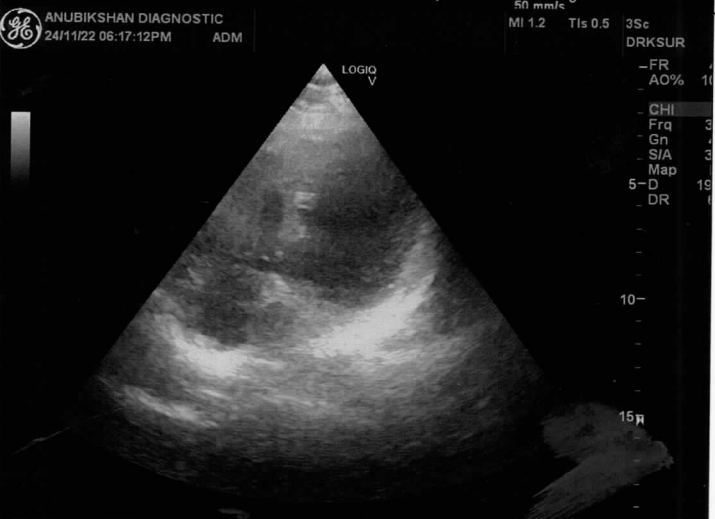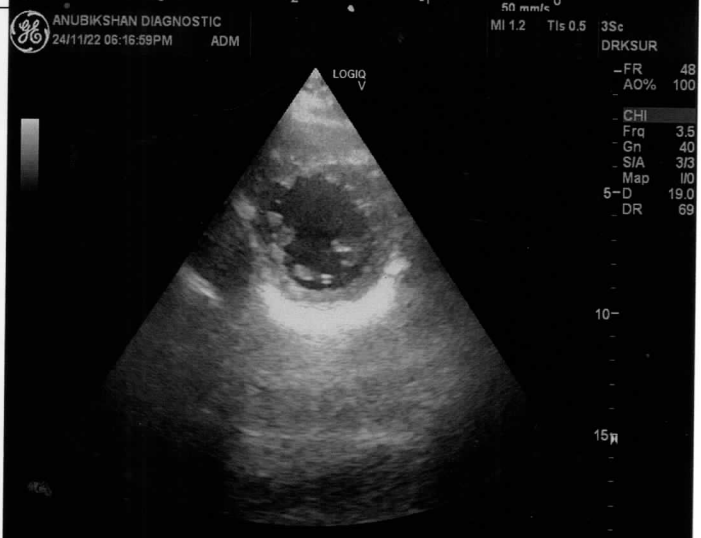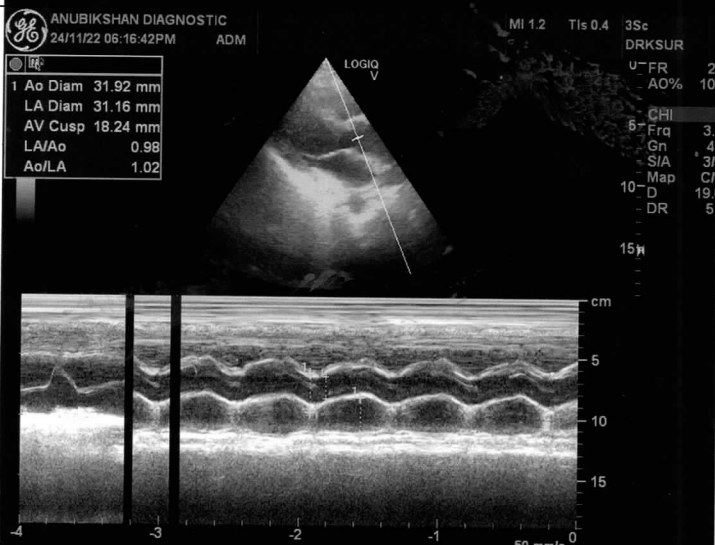
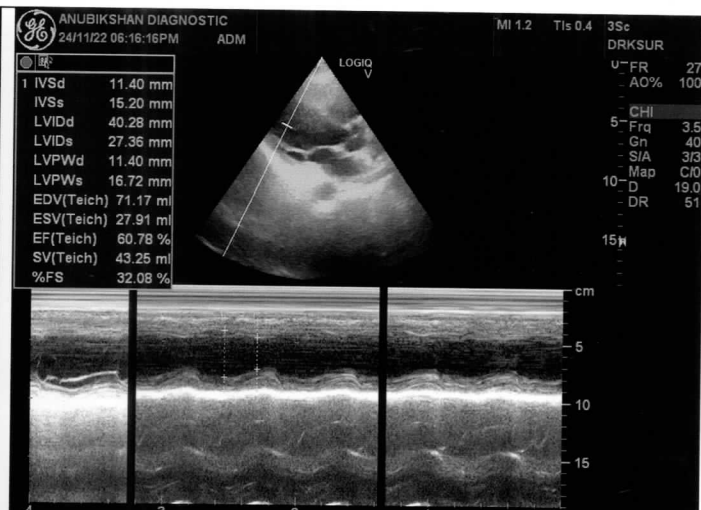
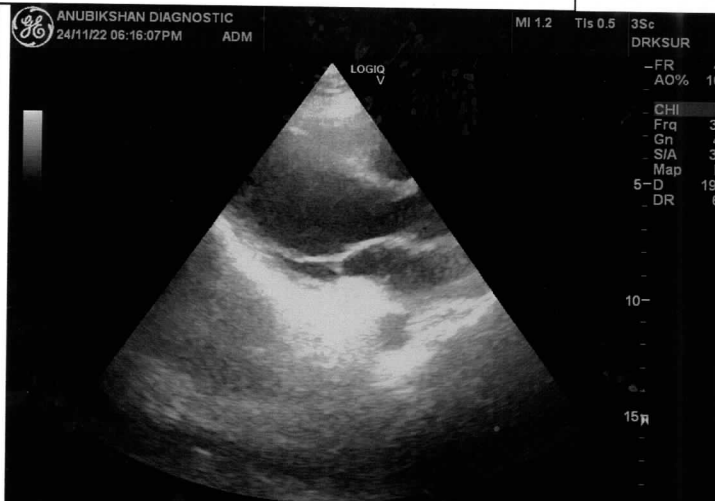DR. KAUSHIK SUR (MD, DM) (CARDIOLOGIST)

# ANUBIKSHAN DIAGNOSTIC CENTRE

NEAR ASANSOL DISTRICT HOSPITAL (MAIN GATE)  
S.B.GORAI ROAD (EAST), PIN - 713301

LANDLINE: - 0341-3590332 // MOB - 7872772680

E-mail add: - anubikshan.dc@gmail.com







# ANUBIKSHAN

Diagnostic Centre

Near Asansol District Hospital(Main Gate)  
S.B. Gorai Road, Asansol-713301  
Email ID : anubikshan.dc@gmail.com  
Ph. : 0341-3590332, M. : 9732362727, 7872772680

**PATIENT'S NAME: - RANI SONKAR**      **AGE:- 29 YEAR**      **SEX:- FEMALE**

**REF. BY DR.:- BANK OF BARODA.**      **DATE: - 25.11.2022**



## U.S.G OF WHOLE ABDOMEN

### LIVER

Normal shape and size.Homogeneous echo texture of the liver is seen.  
No focal parenchymal lesion is seen. (Measure:- 139.02 mm.)

### PORTA VEIN

Portal vein at porta hepatis measures: - 6.14 mm. in diameter.  
The appearance of porta is normal.

### GALL BLADDER

Normal shape, size and position of the Gall Bladder is seen.  
No calculus or any intraluminal mass is seen.

### COMMON BILEDUCT

Common bile duct is not dilated (1.18 mm.)  
No calculus or any intraluminal echogenecity.

### PANCREAS

Normal echo-texture of the pancreas is seen. No space occupying lesion is seen.  
Its relation with the anatomical landmark is normal.

### SPLEEN

Normal dimension of the spleen is seen. It shows normal echo-texture.  
No space occupying lesion is seen in the spleen. (Measure: - 91.49 mm.)

### KIDNEYS

Both the kidneys are normal in shape, size, margin and axis.  
Cortico medullary differentiation is normal.  
No calcular opacity or any hydronephrotic changes noted.  
(Rt. Kidney Measure: - 97.12 mm. in length. & Lt. Kidney Measure:- 100.66 mm. in length.)

### URINARY BLADDER

Normal shape and size of the urinary bladder is seen.  
No intraluminal echo is noted.

### UTERUS


A/V, Bulky. (Measure: - 64.71 mm x 35.16 mm x 36.88 mm.)

### OVARIES

Normal shape and size of the ovaries are seen.  
No space occupying lesion is seen in the ovaries. Normal echo texture is seen.  
(Right ovary Measure: - 20.14 mm. x 29.71 mm.)  
(Left ovary Measure: - 27.87 mm. x 23.17 mm.)

- **IMPRESSION :-**  
➤ **BULKY UTERUS.**

**ADVICE**  
Clinical co-relation.

  
25/11

**DR. DIPANKAR DASGUPTA.**  
**(M.B.B.S., D.M.R.D)**  
**(Regd.No:- WB-34374)**

**PATIENT'S NAME:- RANI SONKAR**

**AGE:- 29 YEAR    SEX:- FEMALE**

**REF BY DR: - BANK OF BARODA**

**DATE:- 25.11.2022**

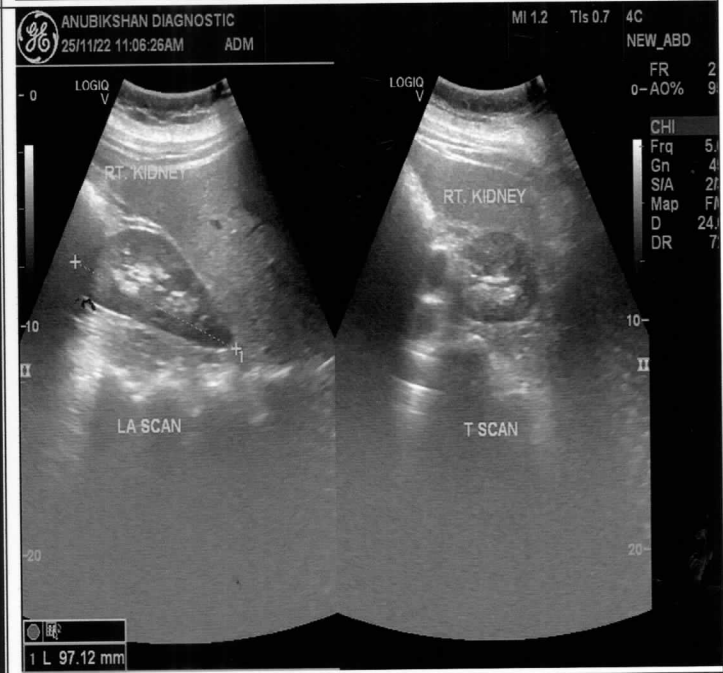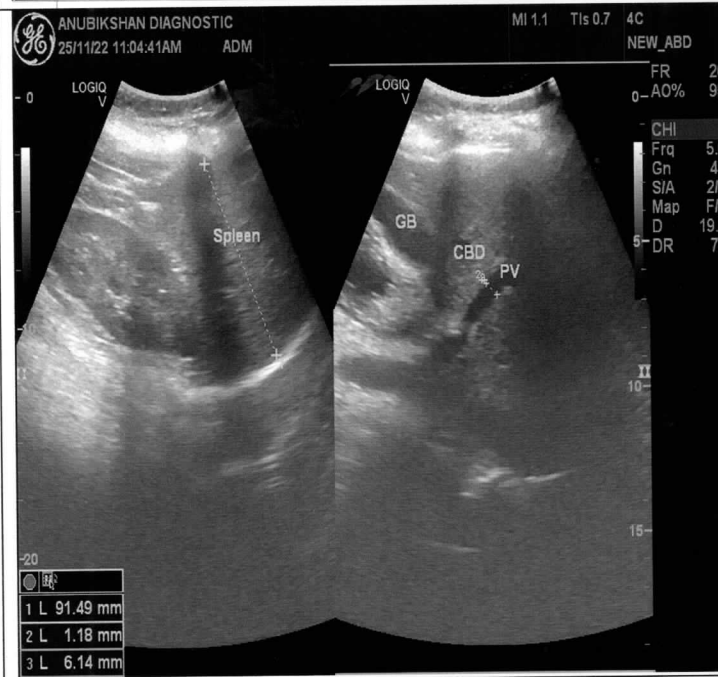
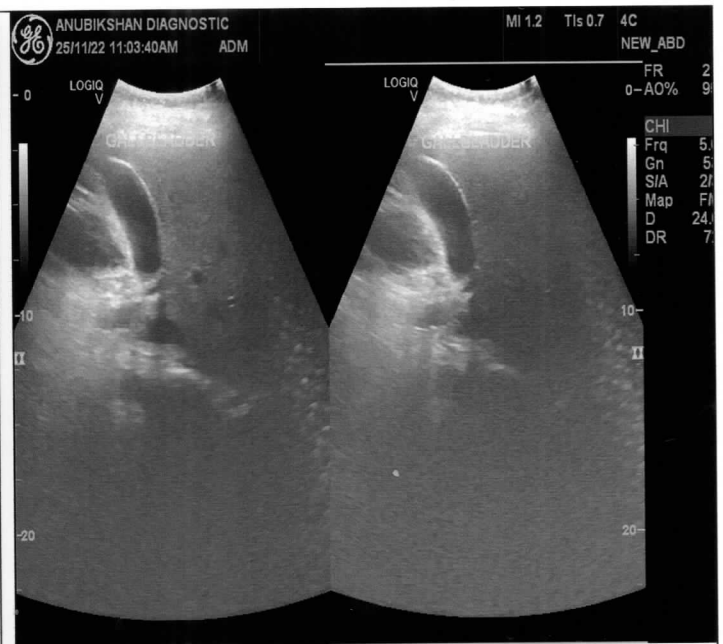
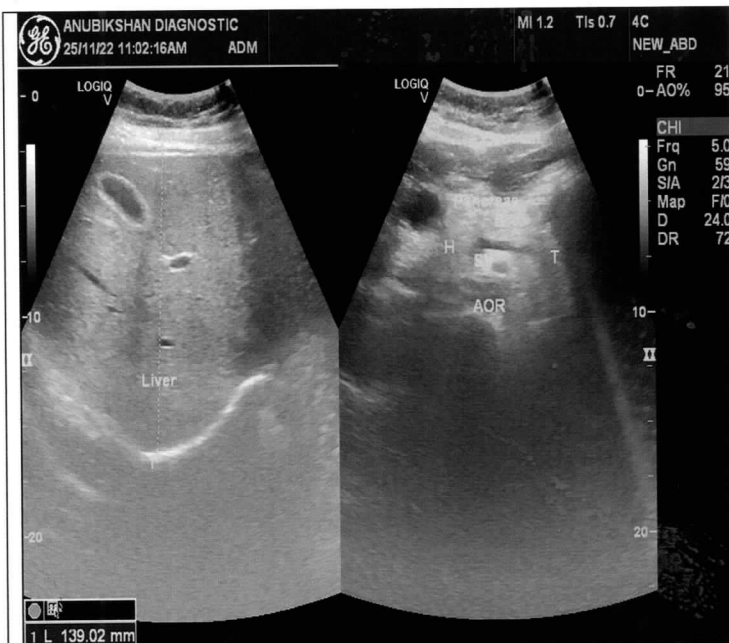**U.S.G. OF WHOLE ABDOMEN**

# **ANUBIKSHAN DIAGNOSTIC CENTRE**

NEAR ASANSOL DISTRICT HOSPITAL (MAIN GATE)  
S.B.GORAI ROAD (EAST), PIN - 713301

**LANDLINE: - 0341-3590332 // MOB - 7872772680**

**E- mail ID: - anubikshan.dc@ gmail.com    (1)**



**PATIENT'S NAME:- RANI SONKAR**

**AGE:- 29 YEAR    SEX:- FEMALE**

**REF BY DR: - BANK OF BARODA**

**DATE:- 25.11.2022**

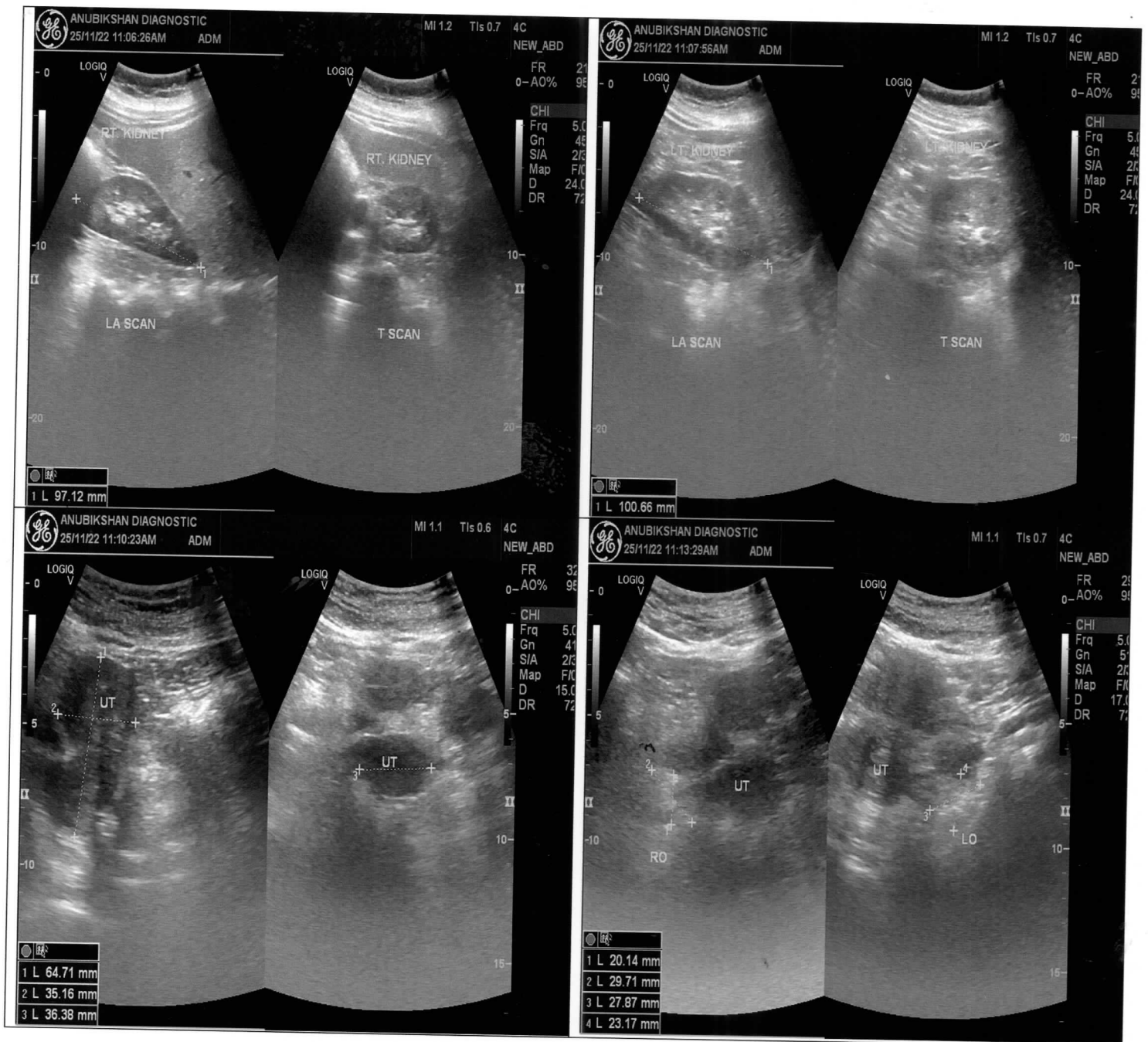
**U.S.G. OF WHOLE ABDOMEN**

# ANUBIKSHAN DIAGNOSTIC CENTRE

NEAR ASANSOL DISTRICT HOSPITAL (MAIN GATE)  
S.B.GORAI ROAD (EAST), PIN - 713301

**LANDLINE: - 0341-3590332 // MOB - 7872772680**

**E- mail ID: - anubikshan.dc@gmail.com    (2)**





# ANUBIKSHAN

Diagnostic Centre

Near Asansol District Hospital(Main Gate)  
S.B. Gorai Road, Asansol-713301  
Email ID : anubikshan.dc@gmail.com  
Ph. : 0341-3590332, M. : 9732362727, 7872772680

PATIENT'S NAME: - RANI SONKAR

AGE:- 29 YEAR

SEX:- FEMALE

REF. BY DR.:- BANK OF BARODA.

DATE:- 24.11.2022



## REPORT

### CHEST X - RAY P A VIEW

**Soft tissue around chest and bony cage --- normal.**

**No active lung lesion in either field.**

**Cardiac configuration normal.**

**Pleural recesses are clear.**

## I M P R E S S I O N

**✓ NORMAL SKIAGRAM OF CHEST.**

### ADVICE

Clinical co-relation.

*[Handwritten signature]*  
25/11

**DR. DIPANKAR DASGUPTA.**  
(M.B.B.S., D.M.R.D)  
(Regd.No:- WB-34374)

R

RANI SONKAR 29Y Female  
NEW ASANSOL X RAY CLINIC MOB-9434236862

8cm

4cm

Self  
24/11/2022

