


**Health Check up Booking Request(bobE42863), Beneficiary Code-29505**

1 message

Mediwheel <wellness@mediwheel.in>  
 To: vidhidiagnostics@gmail.com  
 Cc: customercare@mediwheel.in

26 July 2023 at 19:12



011-41195959

Email:wellness@mediwheel.in

Dear VIDHI DIAGNOSTICS,

**City :** Ahmedabad . **Address :** L-86 Swatantra - Senani Nagar , Opp- Akhbarnagar Bus Terminals, New Wadaj , Ahmedabad -13,

We have received the confirmation for the following booking .

**Name** : MR. ARYA ASHISH  
**Age** : 29  
**Gender** : Male  
**Package Name** : Medi-Wheel Metro Full Body Health Checkup Male Below 40  
**Contact Details** : 9198648055  
**Booking Date** : 26-07-2023  
**Appointment Date** : 29-07-2023

Member Information			
Booked Member Name	Age	Gender	Cost(In INR)
MR. ARYA ASHISH	29	Male	Cashless
Total amount to be paid			Cashless

We will get back to you with confirmation update shortly. Please find the package details as attached for your reference.

**Package Name** : Medi-Wheel Metro Full Body Health Checkup Male Below 40 - Includes (37)Tests

**Tests included in this Package**

Ecg, TSH, X-ray Chest, Stress Test (tmt)/ 2d Echo, Blood Sugar Postprandial, A:g Ratio, Blood Group, Total Cholesterol, Triglycerides, Fasting Blood Sugar, Ultrasound Whole Abdomen , Glycosylated Haemoglobin (hba1c), Hdl, Vldl, Urine Analysis, LDL, Total Protine, General Consultation, HDL/ LDL ratio, GGT(Gamma-glutamyl Transferase), Eye Check-up consultation, ALP (ALKALINE PHOSPHATASE), Uric Acid, AST/ALT Ratio, Serum Protein, CBC with ESR, Stool Analysis, Urine Sugar Fasting, Urine Sugar PP, T3, T4, Cholesterol Total / HDL Ratio, BUN, BUN/Creatinine Ratio, Bilirubin Total & Direct and Indirect, Albumin, Globulin



**Dr. Dinesh S. Modh**

M.D., D.M.R.E. (Radiodiagnosis)

Consultant Radiologist & Sonologist

Ex. Junior Lecturer, B.J. Medical College, Civil Hospital, A'bad.



07/08/2023

Ashish Ashu  
32 years / male

Height ! - 172 cm

Weight ! - 72 kg

BP ! - 118/74 mmHg

Pulse ! - 64 per min

T : - ⊕

RS ⊕ ⊕  
CVS ⊕

SpO2 :- 98

Asymptomatic

NO H/O DM / HTN / Thyroid or TB

ADV  
He is medically fit

Basic Eye check-up

6/6 normal in both eye  
N/6 normal in both eye  
No night & Color  
Blindness

**Vidhi Diagnostics**  
L-86, Swatantra-Senani Nagar,  
Opp. Akhbarnagar Bus Terminals,  
Nr. Akhbarnagar Circle,  
New Vadaj, Ahmedabad-13.

Dr. Vidhi D. Modh  
MBBS  
Reg. No. G-74540

ISO 9001:2015 Certified Diagnostics Center

Vidhi Imaging Center

L-86, Swatantra Senani Nagar, Opp. Indian Oil Petrol Pump, Akhbarnagar Circle, Nava Vadaj, Ahmedabad - 380 013.

Phone : (Radiology) 079-2762 1406 | M. 98799 29406, 98250 09406 | Time (Radiology) : Mon. to Sat. 9 am to 2 pm, 5 to 9 pm, Sunday 9 am to 12 Noon

E-mail : vidhidiagnostics@gmail.com, Website : www.vidhidiagnostics.com

Multislice CT Scan | CBCT-Dental Scan | Live 3D-4D Sonography | Colour Doppler | Echo Cardiography | Interventional Radiology | Maxillofacial Radiology | Fetal Medicine  
Digital X-Ray | Digital Mammography | Digital OPG / TMJ | ECG / TMT / PFT / EEG / EMG | Audiometry | Pathology Laboratory | Health Check Up Plans | Pre Employment Check Up

**CT SCAN & CBCT FACILITY NOW AVAILABLE**



01-08-2023 09:05:04

<< Analysis Result >>

ID: 10229

HR : 64 bpm

\*\* normal ECG \*\*

Name: ashish arya

PR : 152 ms

Sinus rhythm

Age: 32yrs

Dr. Avinash Bhaskar

QRS : 96 ms

**Vidhi Diagnostics**  
L-88, Swatantra-Senani Nagar,  
Opp. Akhbarnagar Bus Terminals,  
Nr. Akhbarnagar Circle,  
New Wadaj, Ahmedabad-13.

Sex: Male

M.B.B.S. D'Cardio  
Reg. No.: G-45946

QT/QTc : 358/368 ms

P/QRS/T : 69/66/66 deg.

RV5/SV1 : 1.518/-0.317 mv

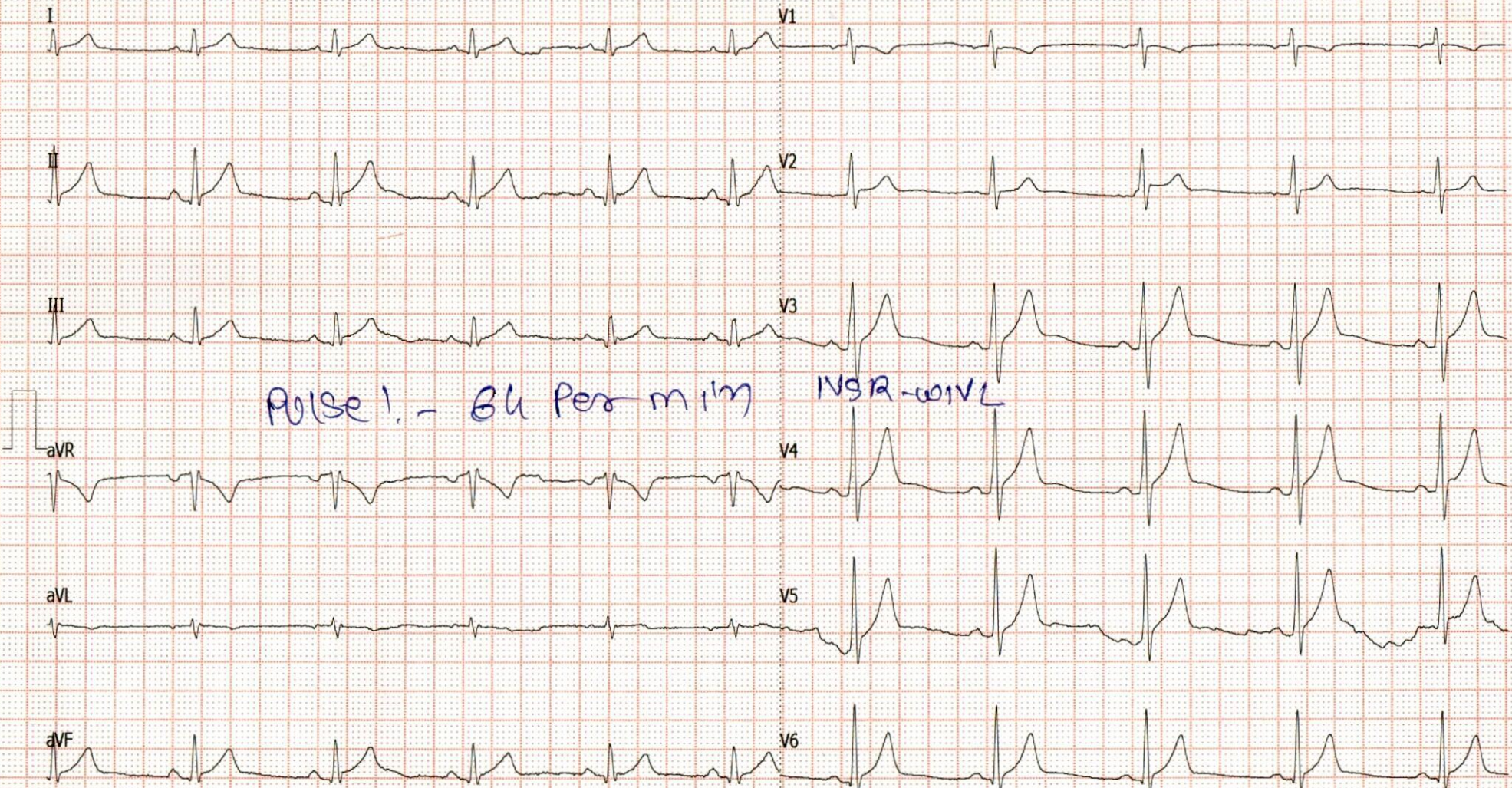
Hospital:

RV5+SV1 : 1.835 mv

Department:

Need to be confirmed by doctor. Doctor Name: \_\_\_\_\_

0.67Hz - 35Hz AC 50Hz 25 mm/s 10 mm/mv





## Dr. Dinesh S. Modh

M.D., D.M.R.E. (Radiodiagnosis)

Consultant Radiologist & Sonologist

Ex. Junior Lecturer, B.J. Medical College, Civil Hospital, A'bad.



Patient's name : ASHISH ARYA  
Reg. ID : R-5020-23  
Referred by : Dr. MEDIWHEEL

Age/Sex : 32 Years/Male  
Accession : 10375  
Date : 01/08/2023

### USG ABDOMEN

LIVER:- Liver appears normal in size & echo texture. No evidence of focal lesion is seen. IHBR appear normal. Portal vein and CBD appear normal. No e/o calculus is seen in bile duct.

GALL BLADDER:- Gall bladder is distended & appears normal. No evidence of calculus or cholecystitis is seen.

SPLEEN:- Spleen appears normal in size & shows normal echo texture. No evidence of diffuse or focal lesion is seen.

PANCREAS:- Pancreas appears normal size and echo pattern. No e/o diffuse or focal lesion is seen. Main pancreatic duct appears normal.

KIDNEY:-Both Kidneys appear normal in size & echo texture.

- No e/o calculus or hydronephrosis/ hydroureter is seen on both sides.

Cortico-medullary differentiation is maintained on both sides.

Both suprarenal regions appear normal.

No evidence of pre & para aortic lymphadenopathy is seen.

Both suprarenal regions appear normal.

No evidence of pre & para aortic lymphadenopathy is seen.

RIF & BOWEL LOOPS (By high frequency probe):-Normal.

No evidence of dilated or thickened bowel loops is seen.

No evidence of free fluid is seen in abdomen.

Urinary bladder:- appears normal. No e/o calculus or mass lesion is seen in bladder.

Prostate appears normal size and echopattern.

Thanks for reference.

Dr. Dinesh S. Modh  
MD DMRE (Radiodiagnosis)  
DR DINESH S. MODHS  
M.D. DMRE(RADIODIAGNOSIS)

ISO 9001:2015 Certified Diagnostics Center

Vidhi Imaging Center

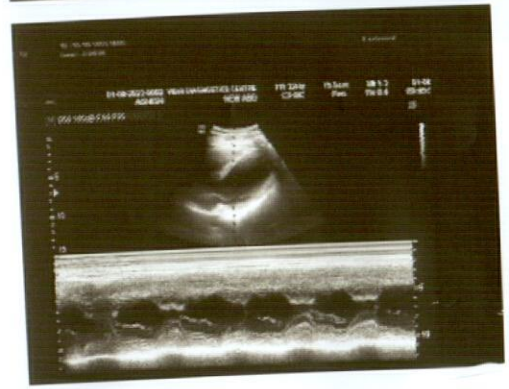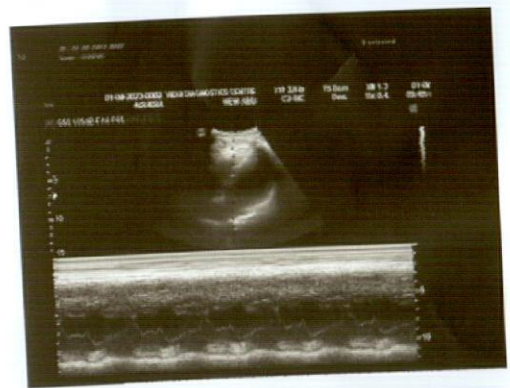
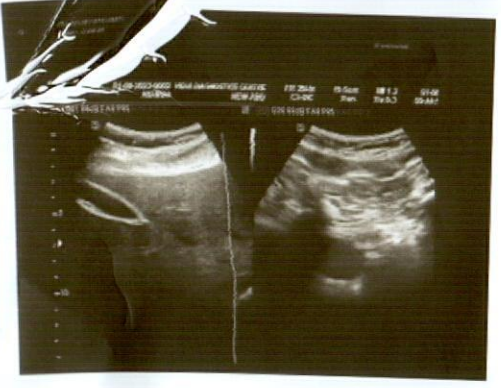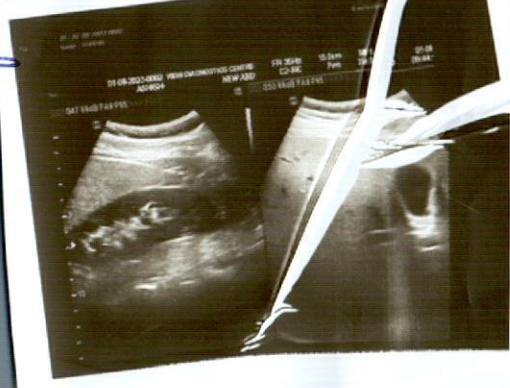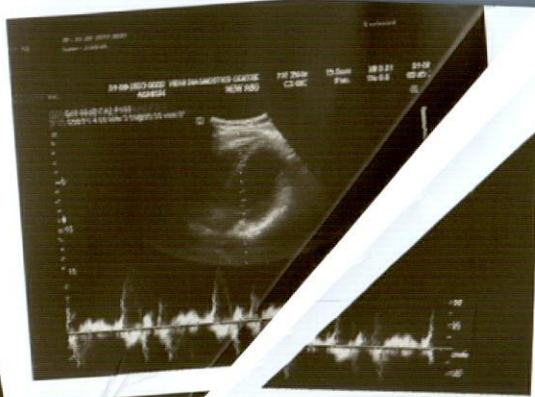
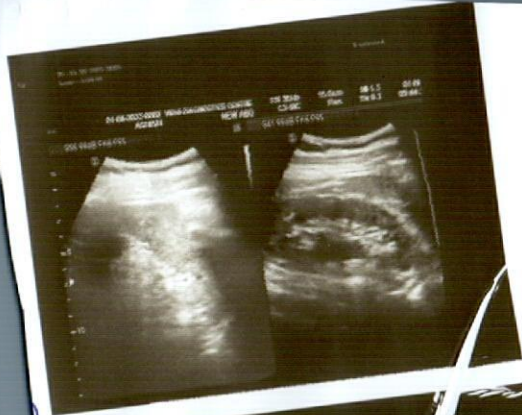L-86, Swatantra Senani Nagar, Opp. Indian Oil Petrol Pump, Akhbarnagar Circle, Nava Vadaj, Ahmedabad - 380 013.

Phone : (Radiology) 079-2762 1406 | M. 98799 29406, 98250 09406 | Time (Radiology) : Mon. to Sat. 9 am to 2 pm, 5 to 9 pm, Sunday 9 am to 12 Noon

E-mail : vidhidiagnostics@gmail.com, Website : www.vidhidiagnostics.com

Multislice CT Scan | CBCT-Dental Scan | Live 3D-4D Sonography | Colour Doppler | Echo Cardiography | Interventional Radiology | Maxillofacial Radiology | Fetal Medicine  
Digital X-Ray | Digital Mammography | Digital OPG/TMJ | ECG/TMT/PFT/EEG/EMG | Audiometry | Pathology Laboratory | Health Check Up Plans | Pre Employment Check Up

**CT SCAN & CBCT FACILITY NOW AVAILABLE**





## Dr. Dinesh S. Modh

M.D., D.M.R.E. (Radiodiagnosis)

Consultant Radiologist & Sonologist

Ex. Junior Lecturer, B.J. Medical College, Civil Hospital, A'bad.



Patient's name : ASHISH ARYA  
Reg. ID : R-5020-23  
Referred by : Dr. MEDIWHEEL

Age/Sex : 32 Years/Male  
Accession : 10375  
Date : 01/08/2023

### X-RAY CHEST (PA VIEW)

Both lung fields appear normal.  
No e/o consolidation or cavitations is seen.  
Both costo-phrenic angles appear clear.  
Cardiac size is with in normal limits.  
Both domes of diaphragm appear normal.  
Bony thoracic cage appears normal.

Thanks for reference.

*Dr. Dinesh S. Modh*  
MD DMRE (Radiodiagnosis).

G-23825  
DR DINESH S. MODH

M.D. DMRE(RADIODIAGNOSIS)

ISO 9001:2015 Certified Diagnostics Center

Vidhi Imaging Center

L-86, Swatantra Senani Nagar, Opp. Indian Oil Petrol Pump, Akhbarnagar Circle, Nava Vadaj, Ahmedabad - 380 013.

Phone : (Radiology) 079-2762 1406 | M. 98799 29406, 98250 09406 | Time (Radiology) : Mon. to Sat. 9 am to 2 pm, 5 to 9 pm, Sunday 9 am to 12 Noon

E-mail : vidhidiagnostics@gmail.com, Website : www.vidhidiagnostics.com

Multislice CT Scan | CBCT-Dental Scan | Live 3D-4D Sonography | Colour Doppler | Echo Cardiography | Interventional Radiology | Maxillofacial Radiology | Fetal Medicine  
Digital X-Ray | Digital Mammography | Digital OPG/TMJ | ECG/TMT/PFT/EEG/EMG | Audiometry | Pathology Laboratory | Health Check Up Plans | Pre Employment Check Up

**CT SCAN & CBCT FACILITY NOW AVAILABLE**

## Dr. Dinesh S. Modh

M.D., D.M.R.E. (Radiodiagnosis)

Consultant Radiologist & Sonologist

Ex. Junior Lecturer, B.J. Medical College, Civil Hospital, A'bad.



Patient's name : ASHISH ARYA  
Reg. ID : R-5020-23  
Referred by : Dr. MEDIWHEEL

Age/Sex : 32 Years/Male  
Accession : 10375  
Date : 01/08/2023

### 2D- ECHO REPORT

#### FINAL CONCLUSION:

LV IS NORMAL SIZE. GOOD LV SYSTOLIC FUNCTION NO RWMA.  
LVEF- 60%. NO CONCENTRIC LVH.  
NORMAL LV COMPLANCE.  
LA IS NORMAL SIZE. NO LA CLOT.  
RV IS NORMAL SIZE. GOOD RV SYSTOLIC FUNCTION.  
RA IS NORMAL SIZE.  
MITRAL VALVE IS NORMAL. NO MS. NO MR . NO MVP.  
AORTIC VALVE IS NORMAL. NO AS. NO AR.  
TRICUSPID VALVE IS NORMAL. NO TR. RVSP-26 mmHg. NO PAH.

NO CLOT, NO VEGETATION, NO PERICARDIAL EFFUSION.

#### DIMENSIONS:

AORTA	2.6 C.M
LEFT ATRIUM	2.7 C.M
LVDD	4.1 C.M.
IVSD	1.0 C.M
PWD	1.0 C.M
LVDS	2.6 C.M.

#### COLOUR DOPPLER FINDING:

STRUCTURE	VELOCITY m/sec
	Max
PULMONARY VALVE	0.7
MITRAL VALVE	E : 0.7 A : 0.4
AORTIC VALVE	1.0

Dr. Avinash Bhaskar  
M.D.S. (Radio)

Reg. No.: G-45946

DR AVINASH BHASKAR

ISO 9001:2015 Certified Diagnostics Center

Vidhi Imaging Center

L-86, Swatantra Senani Nagar, Opp. Indian Oil Petrol Pump, Akhbarnagar Circle, Nava Vadaj, Ahmedabad - 380 013.

Phone : (Radiology) 079-2762 1406 | M. 98799 29406, 98250 09406 | Time (Radiology) : Mon. to Sat. 9 am to 2 pm, 5 to 9 pm, Sunday 9 am to 12 Noon

E-mail : vidhidiagnostics@gmail.com, Website : www.vidhidiagnostics.com

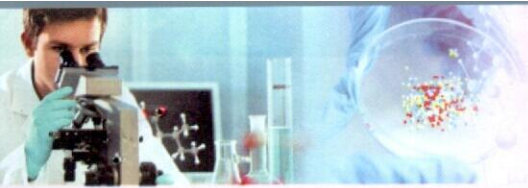Multislice CT Scan | CBCT-Dental Scan | Live 3D-4D Sonography | Colour Doppler | Echo Cardiography | Interventional Radiology | Maxillofacial Radiology | Fetal Medicine  
Digital X-Ray | Digital Mammography | Digital OPG/TMJ | ECG/TMT/PFT/EEG/EMG | Audiometry | Pathology Laboratory | Health Check Up Plans | Pre Employment Check Up

**CT SCAN & CBCT FACILITY NOW AVAILABLE**









## Pathology Department



Patient's name : ASHISH ARYA  
 Age/Sex : 32 Years/Male  
 Referred by : Dr. MEDIWHEEL  
 Collection Time : 09:32

Reg. ID : P-2385-23  
 Accession : 10374  
 Order Dt/time : 01/08/2023 09:32

### Complete Blood Count

Sample Type: EDTA

Test Name	Result	Units	Biological Reference Interval
<b><u>Blood Counts</u></b>			
Haemoglobin :	14.1	Gms%	13.5 - 18.0
Total R.B.C. :	<b>4.52</b>	mill/c.mm	4.7 - 6.0
Total W. B. C. :	5760	/cu mm	4000 - 10500
Platelet Count :	157000	/cu.mm	1,50,000 - 4,50,000
<b><u>Differential Count</u></b>			
Neutrophils :	50	%	40 - 70
Lymphocytes :	<b>45</b>	%	20 - 40
Eosinophils :	03	%	1 - 4
Monocytes :	02	%	2 - 6
Basophils :	00	%	0 - 01
<b><u>Blood Indices</u></b>			
P. C. V. :	<b>40.9</b>	%	42 - 52
M. C. V. :	90.5	fl	78 - 100
M.C.H. :	<b>31.2</b>	pg	27 - 31
M. C. H. C. :	34.5	%	32 - 36
R.D.W. :	<b>14.1</b>	%	11.5 - 14.0
<b><u>E.S.R.( Westergren Method )</u></b>			
After one hour :	06	mm/hr	1 - 7

TESTS DONE ON FULLY AUTOMATED HEMATOLOGY ANALYZER.

*Dr. Gayatri M. Mehta*  
 M. D. (Patho)

DR. GAYATRI MEHTA  
 MD(PATHOLOGY)

DR. ANAND D. PARIKH  
 MD(PATHOLOGY)

LAB USE ONLY (Entered by : GM Enter Date/Time:01/08/2023 1:35:00 PM) (Verify by : GM Verify Date/Time:01/08/2023 1:35:00 PM)



Vidhi Imaging Center | Pathology Department

L-86, Swatantra Senani Nagar, Opp. Akhbarnagar Petrol Pump, Nr. Akhbarnagar Circle, Nava-Vadaj, Ahmedabad - 380 013.

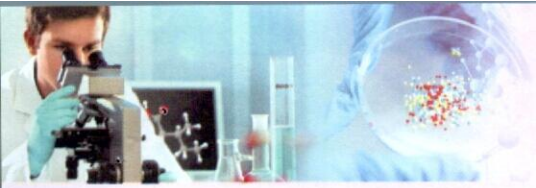Ph. (Pathology) : 8849893954 M. 98799 29406, 98250 09406, E-mail : vidhidiagnostics@gmail.com, Web. : www.vidhidiagnostics.com

Time (Pathology) : Mon. to Sat. 8.30 am to 8.00 pm, Sunday 9 am to 12 Noon

*Pathology means science behind medicine*

**CT SCAN & CBCT FACILITY NOW AVAILABLE**





Creating life in Images

**VIDHI**<sup>®</sup>  
**DIAGNOSTICS**

Pathology Department

Patient's name : ASHISH ARYA  
Age/Sex : 32 Years/Male  
Referred by : Dr. MEDIWHEEL  
Collection Time : 09:32

Reg. ID : P-2385-23  
Accession : 10374  
Order Dt/time : 01/08/2023 09:32

**Blood Group**

Sample Type: EDTA sample.

Test Name	Result
BG :	" B "
RH :	POSITIVE
Remarks	Done by forward grouping method.

*Dr. Gayatri M. Mehta*

M. D. (Patho)

DR. GAYATRI MEHTA  
MD(PATHOLOGY)

Reg. No. G-32215

DR. ANAND D. PARIKH  
MD(PATHOLOGY)

LAB USE ONLY (Entered by :GM Enter Date/Time:01/08/2023 1:35:00 PM) (Verify by :GM Verify Date/Time:01/08/2023 1:35:00 PM)



Vidhi Imaging Center | Pathology Department

L-86, Swatantra Senani Nagar, Opp. Akhbarnagar Petrol Pump, Nr. Akhbarnagar Circle, Nava-Vadaj, Ahmedabad - 380 013.

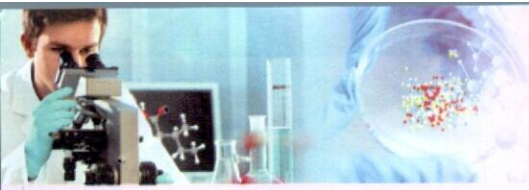Ph. (Pathology) : 8849893954 M. 98799 29406, 98250 09406, E-mail : vidhidiagnostics@gmail.com, Web. : www.vidhidiagnostics.com

Time (Pathology) : Mon. to Sat. 8.30 am to 8.00 pm, Sunday 9 am to 12 Noon

*Pathology means science behind medicine*

**CT SCAN & CBCT FACILITY NOW AVAILABLE**





Creating Life in Punjab



## Pathology Department

Patient's name : ASHISH ARYA  
Age/Sex : 32 Years/Male  
Referred by : Dr. MEDIWHEEL  
Collection Time : 09:32

Reg. ID : P-2385-23  
Accession : 10374  
Order Dt/time : 01/08/2023 09:32

### Blood Glucose

Sample Type: Serum

Test Name	Result	Units	Biological Reference Interval
Fasting Blood Glucose : <i>GOD-POD Method.</i>	98.8	mg/dl	70 - 110

### Blood Glucose

Sample Type: Serum

Test Name	Result	Units	Biological Reference Interval
Post Prandial Blood Glucose After 2hr. : <i>GOD-POD Method.</i>	103.6	mg/dl	80 - 140

*Dr. Gayatri M. Mehta*

M. D. (Patho)

Reg. No. G-32215  
DR GAYATRI MEHTA  
MD(PATHOLOGY)

DR. ANAND D. PARIKH  
MD(PATHOLOGY)

LAB USE ONLY (Entered by :GM Enter Date/Time:01/08/2023 4:03:00 PM) (Verify by :GM , Verify Date/Time:01/08/2023 4:04:00 PM)



Vidhi Imaging Center | Pathology Department

L-86, Swatantra Senani Nagar, Opp. Akharnagar Petrol Pump, Nr. Akharnagar Circle, Nava-Vadaj, Ahmedabad - 380 013.

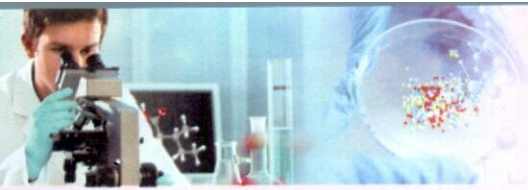Ph. (Pathology) : 8849893954 M. 98799 29406, 98250 09406, E-mail : vidhidiagnostics@gmail.com, Web. : www.vidhidiagnostics.com

Time (Pathology) : Mon. to Sat. 8.30 am to 8.00 pm, Sunday 9 am to 12 Noon

*Pathology means science behind medicine*

**CT SCAN & CBCT FACILITY NOW AVAILABLE**





## Pathology Department



Patient's name : ASHISH ARYA  
Age/Sex : 32 Years/Male  
Referred by : Dr. MEDIWHEEL  
Collection Time : 09:32

Reg. ID : P-2385-23  
Accession : 10374  
Order Dt/time : 01/08/2023 09:32

### Lipid Profile

Sample Type: Serum

Test Name	Result	Units	Biological Reference Interval
<b>S. Cholesterol :</b> Oxidase-esterase method.	112	mg/dl	0 - 200
<b>S. Triglyceride :</b> Enzymatic Colorimetry method	97.1	mg/dL	0 - 200
<b>S. HDL - Cholesterol :</b> Serum by Enzymatic method.	43.3	mg/dL	35 - 65
<b>S. LDL - Cholesterol :</b> Serum by Enzymatic method	49.28	mg/dL	0 - 130
<b>S. VLDL - Cholesterol :</b>	19.42	mg/dL	0 - 30
<b>S. Chole/HDL.Ratio :</b>	2.59		1 - 6
<b>S. LDL / HDL Cholesterol Ratio :</b>	1.14		0 - 3.5

*Dr. Gayatri M. Mehta*

M. D. (Patho)

Reg. No. G-32215

DR GAYATRI MEHTA  
MD(PATHOLOGY)

DR. ANAND D. PARIKH  
MD(PATHOLOGY)

LAB USE ONLY (Entered by :GM Enter Date/Time:01/08/2023 1:35:00 PM) (Verify by :GM Verify Date/Time:01/08/2023 1:35:00 PM)



Vidhi Imaging Center | Pathology Department

L-86, Swatantra Senani Nagar, Opp. Akhbarnagar Petrol Pump, Nr. Akhbarnagar Circle, Nava-Vadaj, Ahmedabad - 380 013.

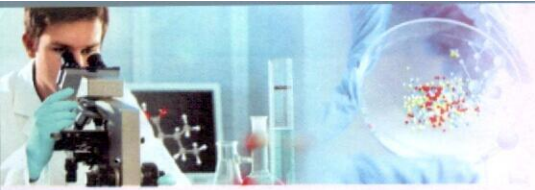Ph. (Pathology) : 8849893954 M. 98799 29406, 98250 09406, E-mail : vidhidiagnostics@gmail.com, Web. : www.vidhidiagnostics.com

Time (Pathology) : Mon. to Sat. 8.30 am to 8.00 pm, Sunday 9 am to 12 Noon

*Pathology means science behind medicine*

**CT SCAN & CBCT FACILITY NOW AVAILABLE**





Creating Life in Samples

## Pathology Department

Patient's name : ASHISH ARYA  
Age/Sex : 32 Years/Male  
Referred by : Dr. MEDIWHEEL  
Collection Time : 09:32

Reg. ID : P-2385-23  
Accession : 10374  
Order Dt/time : 01/08/2023 09:32

### HbA1C

Sample Type: Serum

Test Name	Result	Units	Biological Reference Interval
HbA1C :	5.1	%	Non-diabetic: 4.2-6.2 Pre-diabetic : 6.3-7.2 Diabetic : 7.3-8.2
Mean Blood Glucose of Last 03 months.	100	mg/dl	

#### Comment

\*As per the new 2009 update of American Diabetes Association regarding HbA1C & Mean Blood Glucose relationship.

#### NOTE:

This test is used to monitor diabetic patients compliance with the therapeutic regimen and logo It's level is proportional to both the average blood glucose concentration and the life span of the red blood cells (RBC) in circulation. HbA1c values are free of day to day glucose fluctuations and are unaffected by exercise or recent food intake.

*Dr. Gayatri M. Mehta*  
M. D. (Patho)

Reg. No. G-32215

DR GAYATRI MEHTA  
MD(PATHOLOGY)

DR. ANAND D. PARIKH  
MD(PATHOLOGY)

LAB USE ONLY (Entered by :GM Enter Date/Time:01/08/2023 1:35:00 PM) (Verify by :GM Verify Date/Time:01/08/2023 1:35:00 PM)



Vidhi Imaging Center | Pathology Department

L-86, Swatantra Senani Nagar, Opp. Akharnagar Petrol Pump, Nr. Akharnagar Circle, Nava-Vadaj, Ahmedabad - 380 013.

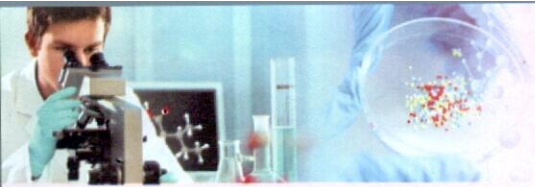Ph. (Pathology) : 8849893954 M. 98799 29406, 98250 09406, E-mail : vidhidiagnostics@gmail.com, Web. : www.vidhidiagnostics.com

Time (Pathology) : Mon. to Sat. 8.30 am to 8.00 pm, Sunday 9 am to 12 Noon

*Pathology means science behind medicine*

**CT SCAN & CBCT FACILITY NOW AVAILABLE**





## Pathology Department

Patient's name : ASHISH ARYA  
Age/Sex : 32 Years/Male  
Referred by : Dr. MEDIWHEEL  
Collection Time : 09:32

Reg. ID : P-2385-23  
Accession : 10374  
Order Dt/time : 01/08/2023 09:32

### BIOCHEMISTRY

Sample type :Serum

Test Name	Result	Units	Biological Reference Interval
Urea, (Serum by GLDH method) :	28.6	mg/dl	10 - 50
S.Uric acid, (Serum by Uricase method) :	7.0	mg/dl	3.4 - 7.0
Bun :	13.4	mg/dl	6-20
Creatinine, (Serum by Enzymatic reaction) :	1.02	mg/dl	0.5-1.2
BUN/CREATRATIO	13.13		13 - 20
S.G.P.T (ALT) : (Serum by IFCC method )	17.5	U/L	0 - 40
S.G.O.T (AST) : (Serum by IFCC method )	19.3	U/L	0 - 37
ALK.PHOSPHATASE : (Serum by PNP method )	61	U/L	40-129
G.G.T :	16.5	U/L	8 - 78
<b><u>BILIRUBIN</u></b>			
Total :	0.94	mg/dl	Up to 1.2
Direct :	0.45	mg/dl	0-0.7
Indirect :	0.49	mg/dl	0 - 0.5
<b><u>SERUM PROTEINS</u></b>			
Total Protein (Serum by Biuret method) :	7.01	gms/dl	6.4 - 8.5
Albumin (Serum by BCG method) :	4.64	gms/dl	3.97-4.94
Globulins :	2.37	gms/dl	2.3 - 3.5
A/G Ratio :	1.958		0.9 - 2.9

Dr. Gayatri M. Mehta  
M. D. (Patho)  
Reg. No. G-32215  
DR GAYATRI MEHTA  
MD(PATHOLOGY)

DR. ANAND D. PARIKH  
MD(PATHOLOGY)



LAB USE ONLY Entered by :GM Enter Date/Time:01/08/2023 2:06:00 PM) (Verify by :GM Verify Date/Time:01/08/2023 2:06:00 PM)

### Vidhi Imaging Center | Pathology Department

L-86, Swatantra Senani Nagar, Opp. Akharnagar Petrol Pump, Nr. Akharnagar Circle, Nava-Vadaj, Ahmedabad - 380 013.

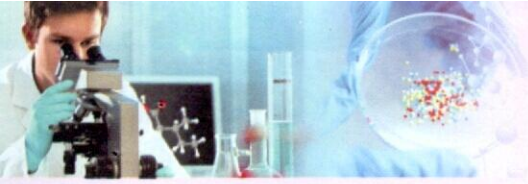Ph. (Pathology) : 8849893954 M. 98799 29406, 98250 09406, E-mail : vidhidiagnostics@gmail.com, Web. : www.vidhidiagnostics.com

Time (Pathology) : Mon. to Sat. 8.30 am to 8.00 pm, Sunday 9 am to 12 Noon

*Pathology means science behind medicine*

**CT SCAN & CBCT FACILITY NOW AVAILABLE**





Pathology Department

**VIDHI**<sup>®</sup>  
**DIAGNOSTICS**

Patient's name : ASHISH ARYA  
Age/Sex : 32 Years/Male  
Referred by : Dr. MEDIWHEEL  
Collection Time : 09:32

Reg. ID : P-2385-23  
Accession : 10374  
Order Dt/time : 01/08/2023 09:32

### Thyroid Function Test

Sample Type: Serum

Test Name	Result	Units	Biological Reference Interval
TOTAL T3 :	1.13	ng/ml	0.84 - 2.0
TOTAL T4 :	8.8	ug/dl	5.1 - 14.0
TSH(Ultra sensitive) :	3.813	mIU/L	0.27 - 4.2

*Dr. Gayatri M. Mehta*

DR GAYATRI MEHTA M. D. (Patho)  
MD(PATHOLOGY) 32275

DR. ANAND D. PARIKH  
MD(PATHOLOGY)

LAB USE ONLY (Entered by :GM Enter Date/Time:01/08/2023 1:37:00 PM) (Verify by :GM Verify Date/Time:01/08/2023 1:37:00 PM)



Vidhi Imaging Center | Pathology Department

L-86, Swatantra Senani Nagar, Opp. Akhbar Nagar Petrol Pump, Nr. Akhbar Nagar Circle, Nava-Vadaj, Ahmedabad - 380 013.

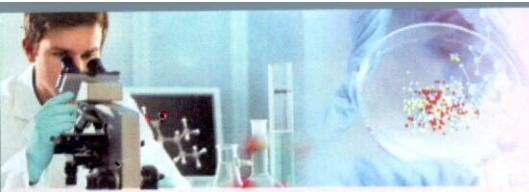Ph. (Pathology) : 8849893954 M. 98799 29406, 98250 09406, E-mail : vidhidiagnostics@gmail.com, Web. : www.vidhidiagnostics.com

Time (Pathology) : Mon. to Sat. 8.30 am to 8.00 pm, Sunday 9 am to 12 Noon

*Pathology means science behind medicine*

**CT SCAN & CBCT FACILITY NOW AVAILABLE**





## Pathology Department

Patient's name : ASHISH ARYA  
Age/Sex : 32 Years/Male  
Referred by : Dr. MEDIWHEEL  
Collection Time : 09:32

Reg. ID : P-2385-23  
Accession : 10374  
Order Dt/time : 01/08/2023 09:32

### Urine Analysis

Sample Type: Urine

Test Name	Result	Units	Biological Reference Interval
<b><u>Physical Examination</u></b>			
Quantity :	20	ml	0 - 500 ml
Colour :	Pale Yellow		Pale Yellow
Transparency :	Slight Turbid.		Clear
Reaction :	Acidic		4.6 - 8.0
Specific Gravity :	1.025		1.016 - 1.022
Sediment :	Present		
<b><u>Chemical Examination</u></b>			
Albumin :	Present (Faint Trace)		Absent
Sugar :	NIL		Absent
Acetone :	Absent		Absent
Bile Salts :	Absent		Absent
Bile Pigments :	Absent		Absent
Urobilogen :	Absent		Absent
Nitrites :	Absent		Absent
<b><u>Microscopic Examination</u></b>			
Red blood Cells :	Occasional	/h.p.f	Absent
Pus Cells :	1-2	/h.p.f	Absent
Epithelial Cells :	1-2	/h.p.f	< 10.0
Amorphous :	Absent	/h.p.f	Absent
Bacteria :	Absent	/h.p.f	Absent
Crystals :	Absent	/h.p.f	Absent
Casts :	Absent	/h.p.f	Absent
Fungus :	Not seen	/h.p.f	Absent

Dr. Gayatri M. Mehta  
M. D. (Patho)

Reg. No. G-32215



DR. ANAND D. PARIKH  
MD (PATHOLOGY)

Entered by : GM Enter Date/Time: 01/08/2023 1:37:00 PM (Verify by : GM Verify Date/Time: 01/08/2023 1:37:00 PM)

Vidhi Imaging Center | Pathology Department

L-86, Swatantra Senani Nagar, Opp. Akhbarnagar Petrol Pump, Nr. Akhbarnagar Circle, Nava-Vadaj, Ahmedabad - 380 013.

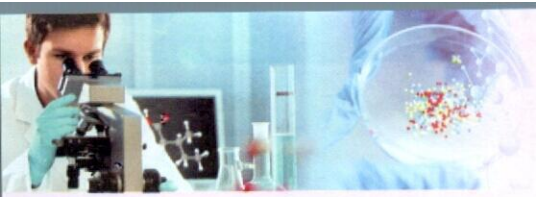Ph. (Pathology) : 8849893954 M. 98799 29406, 98250 09406, E-mail : vidhidiagnostics@gmail.com, Web. : www.vidhidiagnostics.com

Time (Pathology) : Mon. to Sat. 8.30 am to 8.00 pm, Sunday 9 am to 12 Noon

*Pathology means science behind medicine*

**CT SCAN & CBCT FACILITY NOW AVAILABLE**





Creating life in Science



### Pathology Department

Patient's name : ASHISH ARYA  
Age/Sex : 32 Years/Male  
Referred by : Dr. MEDIWHEEL  
Collection Time : 09:32

Reg. ID : P-2385-23  
Accession : 10374  
Order Dt/time : 01/08/2023 09:32

### Stool Examination

Sample Type: Stool

Test Name	Result	Units	Biological Reference Interval
<b><u>PHYSICAL EXAMINATION</u></b>			
Quantity	20 gms		
Colour	Brown		
Consistency	Semi-Solid		
Mucus	Nil		
Occult Blood	Negative		
Peroxidase Reaction with o-Dianisidine			
Reaction	Acidic		
pH Strip Method			

### MICROSCOPIC EXAMINATION

Pus Cells	Occasional/hpf
RBCs	Nil
Vegetable Cells	Absent
Trophozoites	Nil
Cysts	Nil
Ova	Nil
Fat Globules	Nil

----- End Of Report -----

*Dr. Gayatri M. Mehta*  
M. D. (Patho)

Reg. No. G-32215  
DR GAYATRI MEHTA  
MD(PATHOLOGY)

DR. ANAND D. PARIKH  
MD(PATHOLOGY)

LAB USE ONLY (Entered by :GM Enter Date/Time:01/08/2023 1:50:00 PM) (Verify by :GM Verify Date/Time:01/08/2023 1:50:00 PM)



Vidhi Imaging Center | Pathology Department

L-86, Swatantra Senani Nagar, Opp. Akharnagar Petrol Pump, Nr. Akharnagar Circle, Nava-Vadaj, Ahmedabad - 380 013.

Ph. (Pathology) : 8849893954 M. 98799 29406, 98250 09406, E-mail : vidhidiagnostics@gmail.com, Web. : www.vidhidiagnostics.com

Time (Pathology) : Mon. to Sat. 8.30 am to 8.00 pm, Sunday 9 am to 12 Noon

*Pathology means science behind medicine*

**CT SCAN & CBCT FACILITY NOW AVAILABLE**



भारत सरकार  
Government of India

आशीष आर्य  
Ashish Arya  
जन्म तिथि / DOB : 11/07/1991  
पुरुष / Male

7951 9897 7920

आधार - आम आदमी का अधिकार

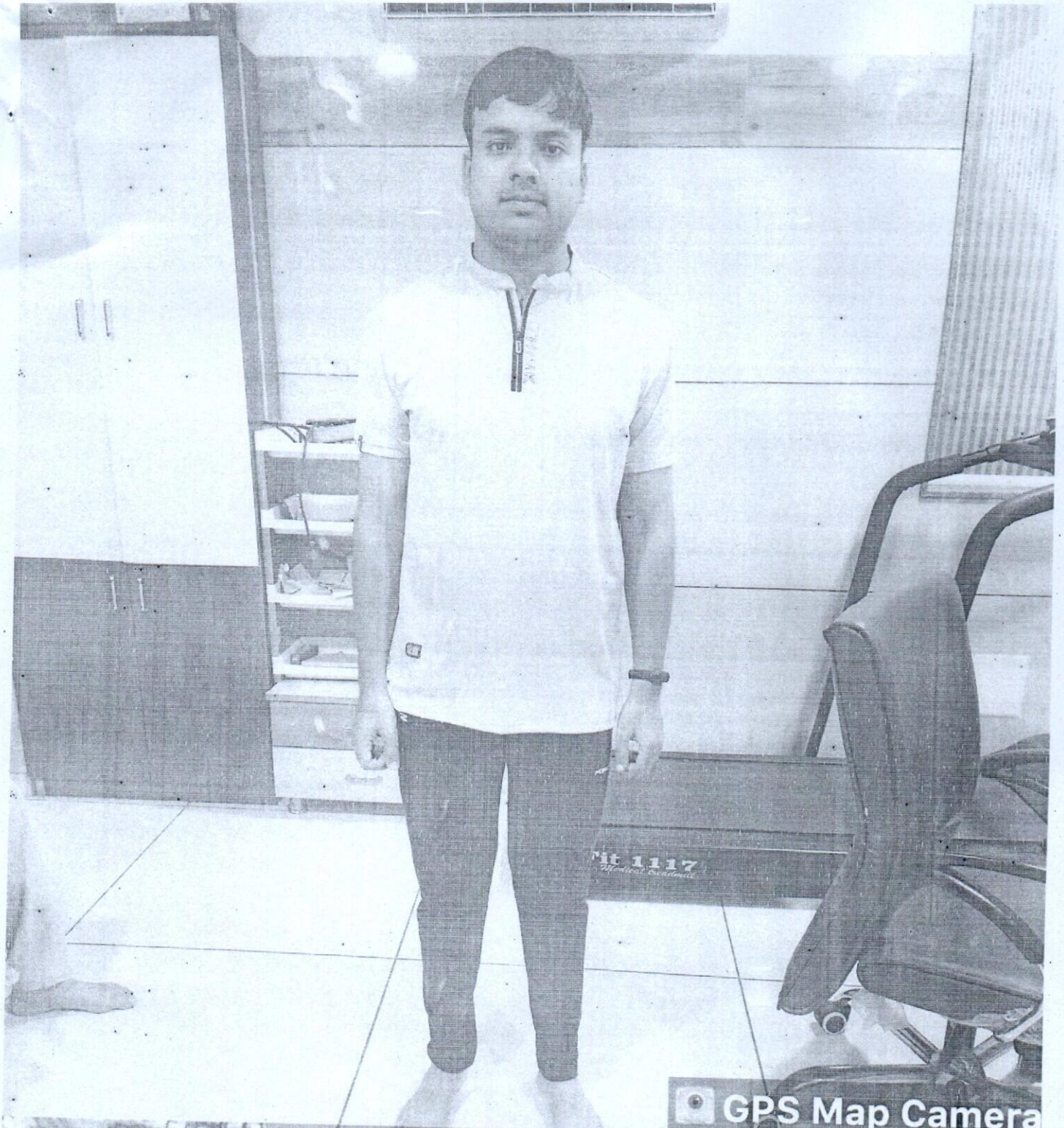


*Ashish*

Dr. Vidhi D. Modh  
MBBS  
Reg. No. G-74540

**Vidhi Diagnostics**  
L-86, Swatantra-Senani Nagar,  
Opp. Akharnagar Bus Terminals,  
Nr. Akharnagar Circle,  
New Wadaj, Ahmedabad-13.





 GPS Map Camera

Ahmedabad, Gujarat, India

3H95+RJP, Sector 45c, Nirnay Nagar, Ahmedabad, Gujarat  
380061, India

Lat 23.068122°

Long 72.561762°

01/08/23 09:21 AM GMT +05:30

Google

Dr. Vidhi D. Modh  
  
MBBS  
Reg. No. C-74540

**Vidhi Diagnostics**  
L-86, Swatantra-Senani Nagar,  
Opp. Akhbarnagar Bus Terminals,  
Nr. Akhbarnagar Circle,  
New Wada, Ahmedabad-13.