

2

भारत सरकार
Government of India




आधार
Ahaar
जन्म तिथि/DOB: 27/05/1974
लिंग/ GENDER: FEMALE



8105 0137 4788
VID : 9116 0724 6684 7854
मेरा आधार, मेरी पहचान

Ahaar

भारतीय अद्वितीय पहचान प्राधिकरण
Unique Identification Authority of India




पते
W/O Mohammad Idris, B-175, Second Floor,
Street No. 8, Ramesh Park, Laxmi Nagar (East),
Delhi - 110092

Address:
W/O Mohammad Idris, B-175, Second Floor,
Street No. 8, Ramesh Park, Laxmi Nagar (East),
Delhi, East Delhi,
Delhi - 110092



8105 0137 4788
VID : 9116 0724 6684 7854

1947 | help@uidai.gov.in | www.uidai.gov.in

Malik Radix Health Care Pvt. Ltd.
C-217, C-218, Nirman Vihar,
Delhi-110002
Ph.: 011-22011196, 22011192
Regd. No. 607



PHYSICAL EXAMINATION REPORT

NAME: Mrs. Afroz

AGE/GENDER: 49yrs/Female

DATE 03/11/23

HEIGHT	154cm
WEIGHT	67kg
BMI	28.3
BLOOD PRESSURE	120/80mmHg
OTHER	NAD, She is physically fit & Healthy

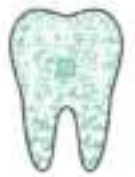Dr. SHEIKH NAZIR AHMED
M.D. (D)
F...
DMC-111499

Afroz

Malik Radix Health Care Pvt. Ltd.
C-217, C-218, Nirman Vihar,
Delhi-110092
Ph.: 011-22011198, 22011192
Regd. No. 607

Facilities Available

- Multispeciality Hospital - 24 Hours Emergency - X-Ray/ ECG/ Ultrasound/ CT Scan - Dental - Fully Equipped Operation Theatre
- Fully Functional Lab - 24/7 Casualty/ ICU-Nursery 24/7 Pharmacy - Labour Room - All Speciality OPD - Laproscopic Surgery - ECHO - Plastic Surgery



CONSULTANTS ON PANEL

PAEDIATRICS

Dr. Neer Malik (MBBS, MD)
Dr. Harit Prasad (MBBS, MD, FR)
Dr. Ritu Jain (MBBS, MD)

GYNAECOLOGY

Dr. Renu Malik (MBBS, MD)
Dr. Veena Mahotra (MBBS, MD)
Dr. Rani (MBBS, MD)
Dr. Manu Gupta (MBBS, MD)
Dr. Veeraj Sam (MBBS, DGO)
Dr. Rajam Anra (MBBS, MD)

DENTAL

Dr. Shrut Malik (BDS, MCh)
Dr. Annu Sam (BDS, MCh)
Dr. Ruchi Thakur (BDS, MCh)
Dr. Mohit Mangla (BDS, MCh)
Dr. Tanu Mittal (BDS, MCh)
Dr. Geetika Sharma (BDS)
Dr. Shilpa Verma (BDS)

CHILD GASTROENTEROLOGY

Dr. S. K. Mittal (MBBS, MD)

MEDICINE

Dr. A. S. Talwar (MBBS, MD)
Dr. Sunny Jajal (MBBS, MD)
Dr. Surendra Negpal (MBBS, MD)

RESPIRATORY MEDICINE PULMONOLOGY

Dr. Akhshay Sharma (MBBS, DNB)

LAPAROSCOPIC SURGERY

Dr. Raju Jain (MBBS, MD)
Dr. Deepak Saran (MBBS, MD)
Dr. Pradeep Saran (MBBS, MD)
Dr. G. J. Garg (MBBS, MD)

ORTHOPAEDICS

Dr. Vikas Shrivastava (MBBS, MS ORTHO, DNB)
Dr. Prabhakar Aggarwal (MBBS, MS ORTHO)
Dr. KB Tiwar (MBBS, MS ORTHO)
Dr. Deepak Kumar Anra (MBBS, MS ORTHO)

EYE/OPTHALMOLOGY

Dr. Nishi Gupta (MBBS, MS, DNB, PGDM)
Dr. Himanshu Singh Pundir (MBBS, MD)

ENT

Dr. Sharad Kumar Singh (MBBS, MD)
Dr. Prateek Sharma (MBBS, MD)
Dr. Ashok Singh (MBBS, MD)
Dr. A. K. Lohar (MBBS, MD)

RADIOLOGY (ULTRASOUND)

Dr. K. K. Sinha (MBBS, DNB)
Dr. T. K. Verma (MBBS, MD)
Dr. Rakesh Mahotra (MBBS, MD)
Dr. Ashish Tomar (MBBS, MD)

PATHOLOGY

Dr. Reema Dahiya (MBBS, MD PATH)
Dr. Veenu Aggarwal (MBBS, MD PATH)

ANAESTHESIA

Dr. Rakesh Dhal (MBBS, MD)
Dr. Rakesh Arora (MBBS, MD)
Dr. R. K. Arora (MBBS, MD)
Dr. Swarna Garg (MBBS, MD)

DERMATOLOGY

Dr. Niharika Jha (MBBS, MD)

PLASTIC & COSMETIC SURGERY

Dr. Ayash Jain (MBBS, MS, MCh)

PAEDIATRIC SURGERY

Dr. Dharmendra Singh (MBBS, MS, MCh)
Dr. Satish Aggarwal (MBBS, MS, MCh)

PAEDIATRIC NEPHROLOGY

Dr. A. T. Vasudevan (MD, Dip. in Paed.)

NEPHROLOGY

Dr. Javed (MBBS, MD, Nephro)

CARDIOLOGY

Dr. Nishant Tyagi (MBBS, MD)

NEUROLOGY

Dr. Anshu Bhatia (MBBS, MD)

GASTROENTEROLOGY

Dr. Deepak Lohar (MBBS, MD)
Dr. Nareesh Aggarwal (MBBS, MD)
Dr. Ashok Goyal (MBBS, MD)
Dr. Ankur Singhal (MBBS, MD)

UROLOGY

Dr. Nishi Sharma (MBBS, MCh)
Dr. Ankur Singhal (MBBS, MD)

PSYCHIATRY

Dr. Mohit Sharma (MBBS, MD)

PHYSIOTHERAPY

Dr. Rini Dandia
Dr. Ravi Kumar

NUTRITIONIST

Dr. Deepika Kati
Dr. Sakshi Rana

CLINICAL PSYCHOLOGIST

Dr. Tanika Singh

Dr. Shrut Malik

BDS, MDS (Endodontics)

(+91-9899561092)

Name : Afroz

Age/Sex : 494 / F

Date : 3/11/23

**Timings : 10:00 am. to 2:00 pm.
6:00 pm. to 8:30 pm.**

For Appointment

**011-45152510
+91-9999254639**

CLINICAL EXAMINATION:-

Routine Checkup

1. TMJ:-

M.H.-

H/O Hypertension.
(occasional).

2. DENTAL STATUS:

- a. Caries Teeth :
- b. Fracture Teeth :
- c. Root Stumps :
- d. Gingivitis :
- e. Periodontitis :
- f. Impacted Teeth :
- g. Malaligned Teeth :

0%

Caries

	7
--	---

Missing

7	7
---	---

Calculus +

Stains +

3. ORAL LESIONS:-

4. DIAGNOSIS:-

5. TREATMENT PLANNING:

Adv.

- OPG

6. FOLLOW UP:-

- P-kit

Referral To Other Consultant: Yes/ No

If Yes, please mention the Name:

Doctor's Signature Anny

Facilities Available :

- * MULTI-SPECIALITY HOSPITAL * MODULAR FULLY EQUIPPED OT * NURSERY * LAPROSCOPIC SURGERY
- * 24X7 EMERGENCY * OPG * DENTAL * 24X7 DIAGNOSTICS * LABOUR ROOM * ECHO * EEG * DIGITAL X-RAY * CT SCAN
- * ECG * ULTRASOUND * RICU/ICU * ALL SPECIALITY OPD * PLASTIC & COSMETIC SURGERY * DIALYSIS * PHARMACY

Ahmed

MALIK RADIX HEALTHCARE PVT LTD
UNI-EMC-217/218 NIRMAN VIHAR VIKAS MARG
DELHI 110092

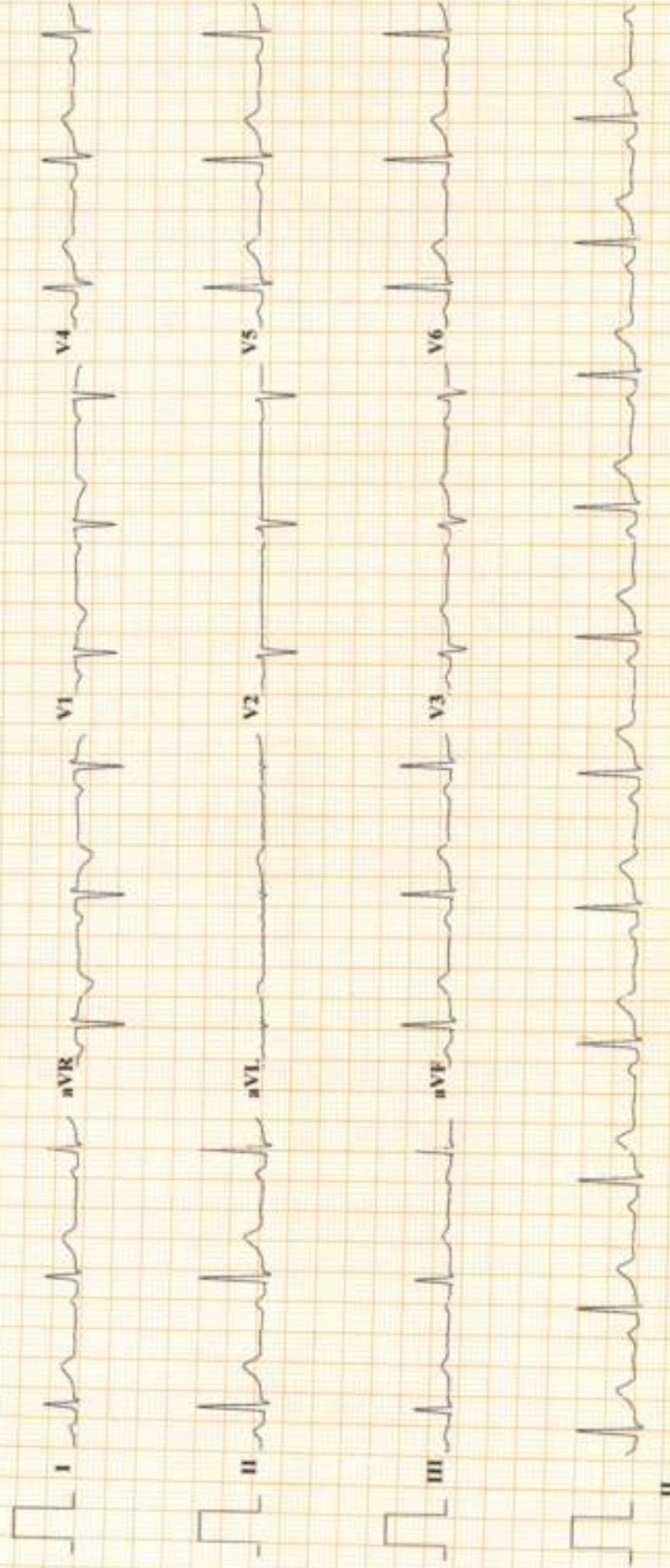
AFROZ
ID : 4330
AGE/SEX : 40 Yr / F
HT/WT : / /
DATE : 03-11-2023 11:57:31 AM
REI BY : Dr.

MACHINE INTERPRETATION : Normal ECG.

RATE : 71 bpm
BP : N/A
P Axis : 53 deg
QRS Axis : 61 deg
T Axis : 47 deg

P Duration : 112 ms
PR Duration : 172 ms
QRS Duration : 79 ms
QT Interval : 370 ms
QTc Interval : 393 ms

Linked Median
Speed : 25 mm/s
Sensitivity : 10 mm/mV



Imp :- Normal ECG.

(Signature)

Dr. SHEIKH NAZIR AHMED
M.D. - Physician
PGDCC

Apoor

MALIK RADIX HEALTHCARE PVT. LTD.
C-217, 218, VIKAS MARG, NIFMAN VIHAR, DELHI-110092
PHONE NO- 011-22011192 / 96

TREADMILL TEST REPORT

AFROZ : 1907
 ID : 1907
 DATE : 03-11-2023
 AGE/SEX : 49 / E
 HT/WT : 0 / 0
 REF. BY :

PROTOCOL : Bruce
 HISTORY :
 INDICATION :
 MEDICATION :

PHASE	TOTAL TIME	STAGE TIME	SPEED Km/hr	GRADE %	H.R. bpm	B.P. mmHg	RPP x100	ST LEVEL (MK)			METS
								II	V1	V5	
SUPINE					72	120 / 30	86	0.6	-0.2	0.5	
STANDING					74	120 / 30	88	0.6	-0.5	0.6	
HYPERVENT					77	120 / 30	92	0.6	-0.5	0.5	
Stage 1	2:55	0:3	2.7	10	126	124 / 32	156	1.2	-1.3	0.3	4.67
Stage 2	5:55	2:55	4	12	156	128 / 34	199	0.3	-0.1	0	7.04
PK-EXERCISE	6:8	0:8	5.4	14	162	136 / 36	220	0.5	0.2	-0.1	7.23
RECOVERY	9:11	2:55			98	134 / 34	131	0.1	-0.1	-0.2	
RECOVERY	12:11	5:55			87	132 / 30	114	0	0	-0.2	

RESULTS

EXERCISE DURATION : 6:8
 MAX HEART RATE : 162 bpm 94 % of target heart rate 171 bpm
 MAX BLOOD PRESSURE : 136 / 86 mm Hg
 REASON OF TERMINATION : **THR Achieved.**
 BP RESPONSE : **None**
 ARRHYTHMIA : **None**
 H.R. RESPONSE : **None**
 IMPRESSIONS : **IMT is Negative for Provocable myocardial Ischemia.**

MAX WORK LOAD : 7.23 METS

Dr. NISHANTYAGI
 MD, Medical Cardiology
 Senior Consultant, Cardiology
 D/MC No. 20902
 Malik Radix Healthcare Pvt. Ltd.
 C-217, 218, Nifman Vihar, Delhi-92

Technician :

MALIK RADIX HEALTHCARE PVT. LTD.

AFROU

I. D. 1907

Age 49/F

Date 03-11-2023

RATE 74bpm

B. P. 120/80

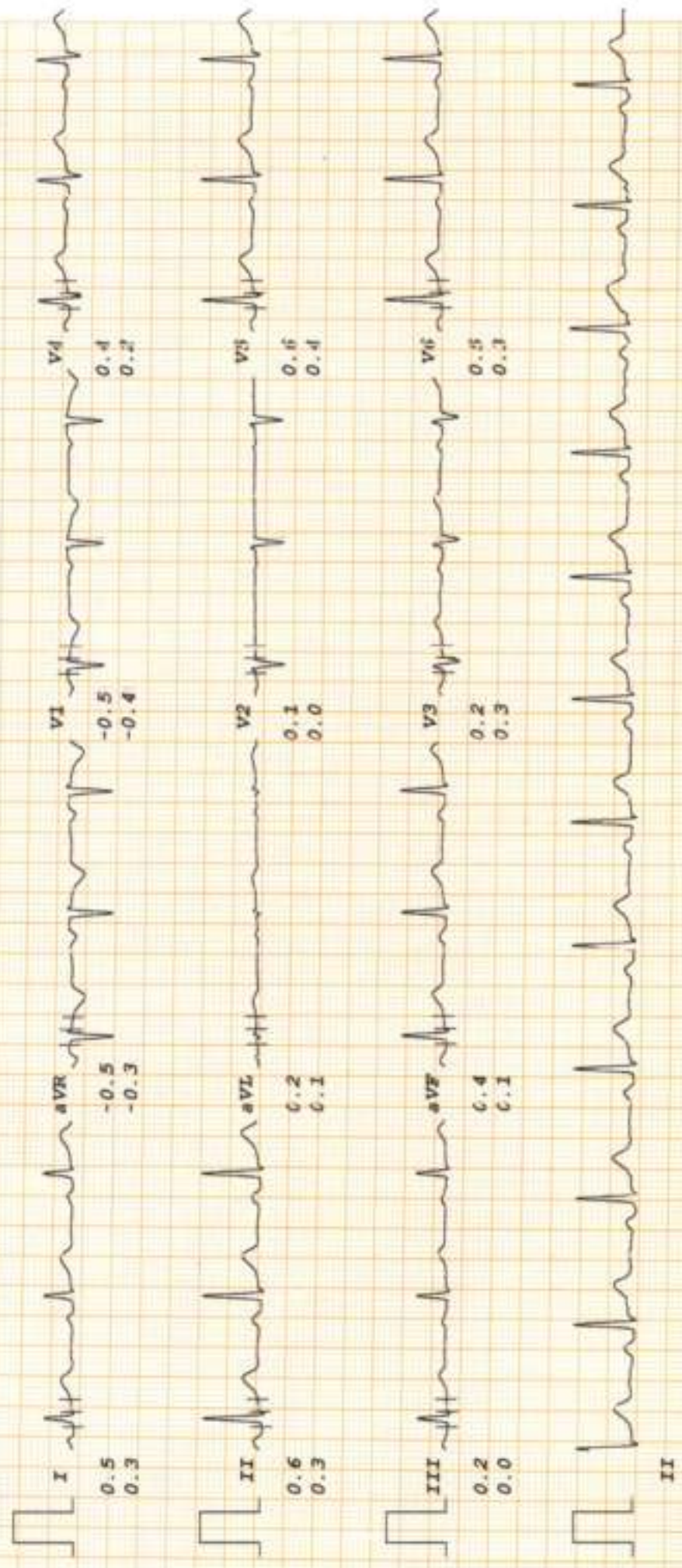
PRETEST

STANDING

ST ϕ 10mm/mV

80ms Post J

LINKED MEDIAN



MALIK RADIX HEALTHCARE PVT. LTD.

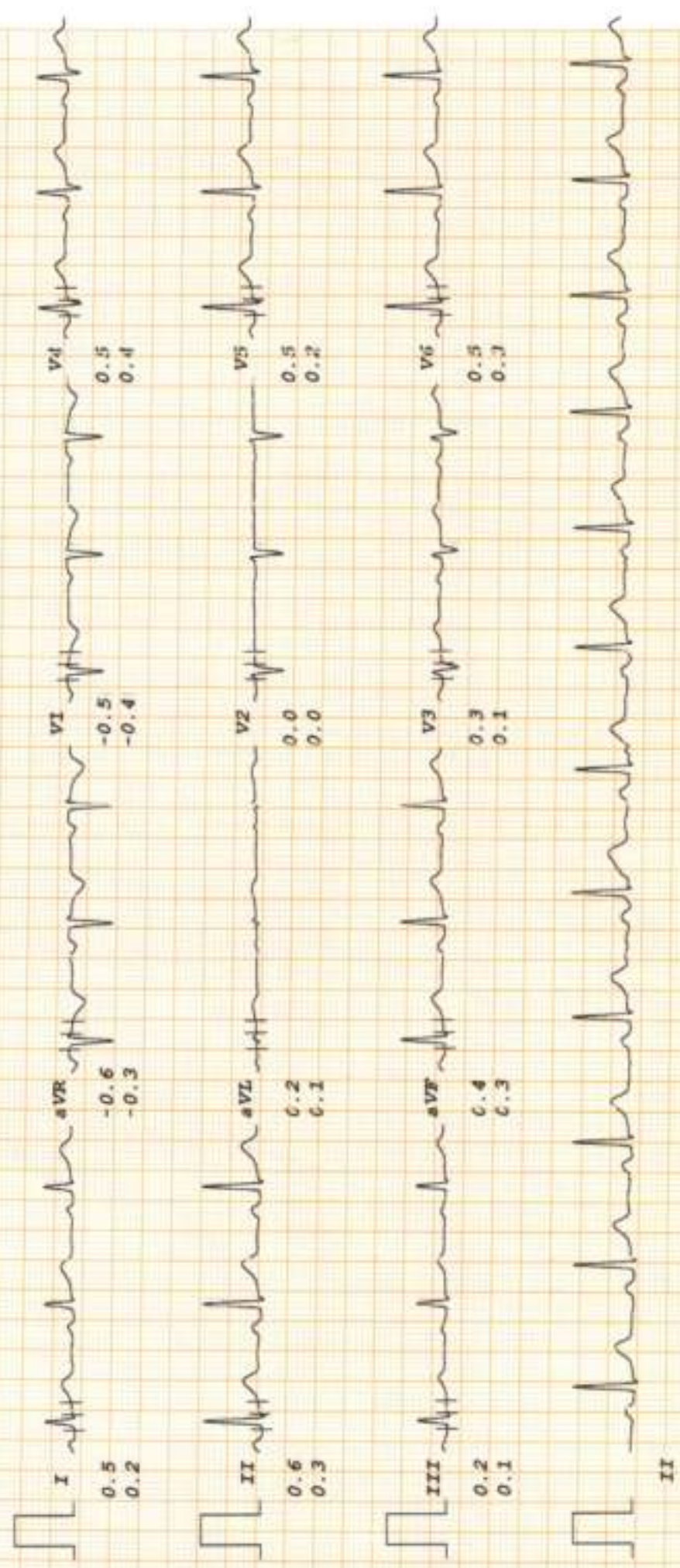
AFROH
I. D. 1907
Age 49/F
Date 03-11-2023

RATE 77bpm
B.P. 120/80

PRETEST
HYPERVENT
PHASE TIME 0:03

ST β 10mm/mV
80ms PostJ

LINKED MEDIAN



MALIK RADIX HEALTHCARE PVT. LTD.

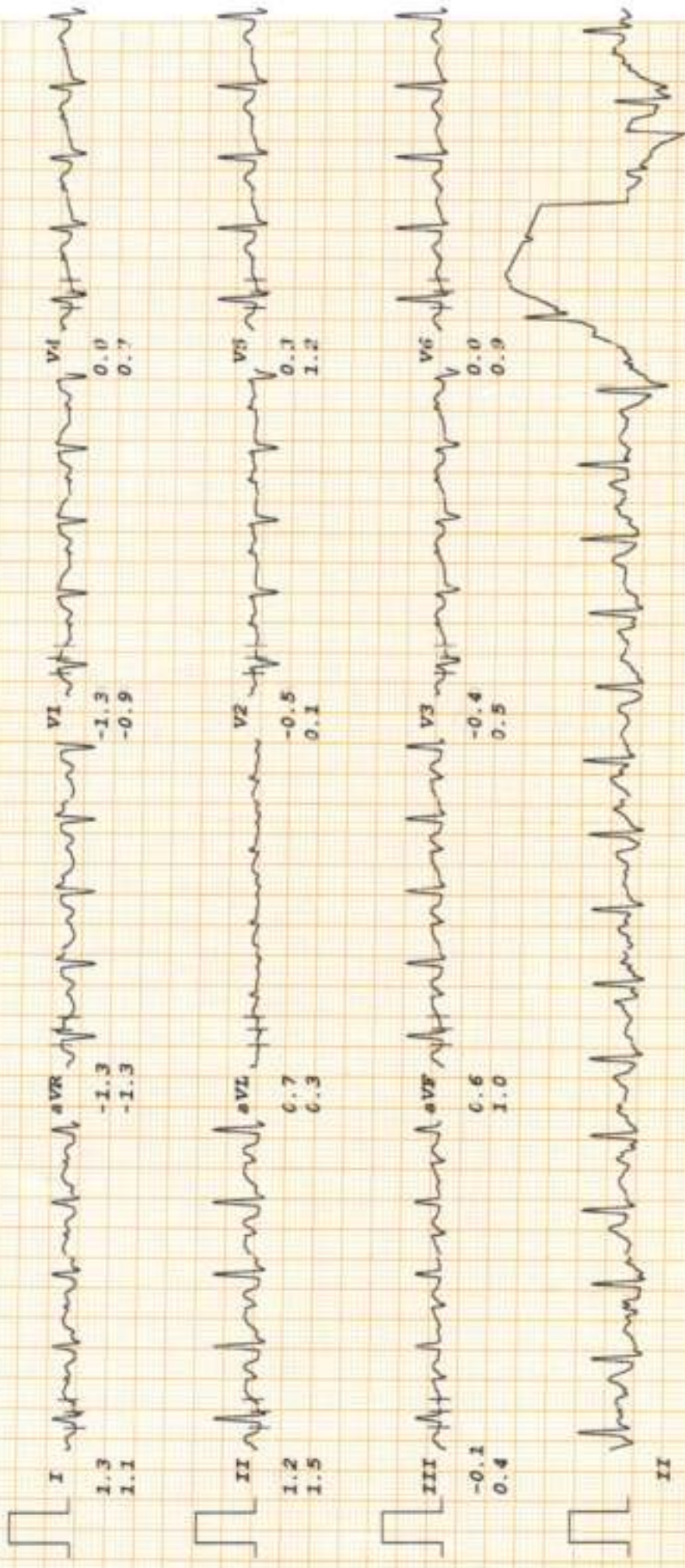
AFROZ
I.D. 1907
Age 49/F
Date 03-11-2023

RATE 126bpm
B.P. 124/82

Bruce
Stage 1
TOTAL TIME 2:55
PHASE TIME 2:55

ST. @ 10mm/mV
80ms Post J
Speed 2.7 km/hr
SLOPE 10 °

LINKED MEDIAN



MALIK RADIX HEALTHCARE PVT. LTD.

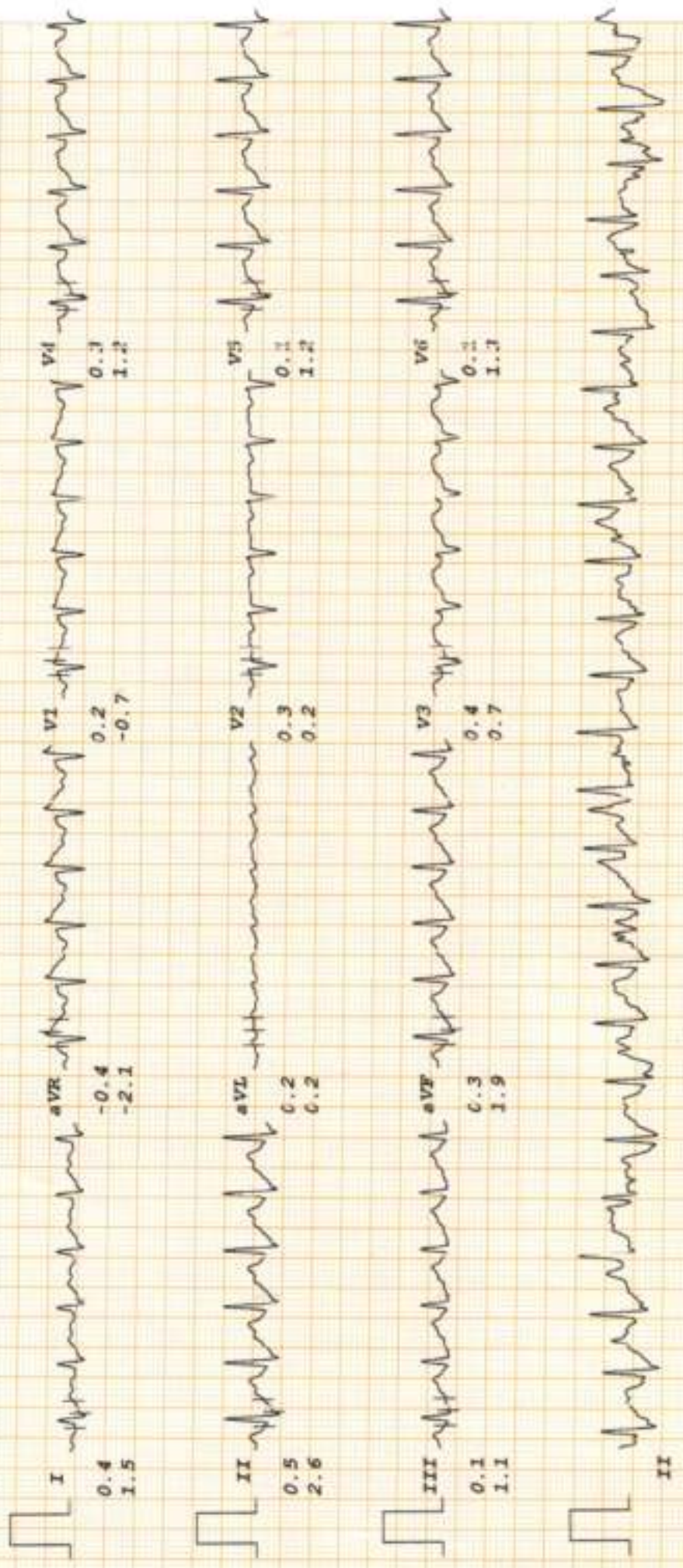
ST @ 10mm/mV
 80ms PostJ
 Speed 5.4 ka/hr
 SLOPE 14 #

LINKED MEDIAN

Bruce
 PK-EXERCISE
 TOTAL TIME 6:08
 PHASE TIME 0:08

RATE 162bpm
 B.P. 136/86

AFROZ
 I.D. 1907
 Age 49/F
 Date 03-11-2023



Dr. G. Ramesh Kumar, MD (General Medicine), DM (Cardiology), DNB (Cardiology), FICM (India), Fellowship in Advanced Cardiology, FACC (USA), FACC (Canada), FACC (UK), FACC (Australia), FACC (New Zealand), FACC (Singapore), FACC (South Africa), FACC (Japan), FACC (Korea), FACC (China), FACC (Taiwan), FACC (Hong Kong), FACC (Macau), FACC (Philippines), FACC (Thailand), FACC (Vietnam), FACC (Cambodia), FACC (Laos), FACC (Myanmar), FACC (Burma), FACC (Sri Lanka), FACC (Nepal), FACC (Bhutan), FACC (Maldives), FACC (Seychelles), FACC (Mauritius), FACC (Reunion), FACC (Mayotte), FACC (Guadeloupe), FACC (Martinique), FACC (French Guiana), FACC (Overseas French), FACC (Curaçao), FACC (Aruba), FACC (Trinidad and Tobago), FACC (Suriname), FACC (Guyana), FACC (Jamaica), FACC (Bahamas), FACC (Cuba), FACC (Haiti), FACC (Dominican Republic), FACC (Puerto Rico), FACC (Virgin Islands), FACC (Cayman Islands), FACC (Belize), FACC (Guatemala), FACC (El Salvador), FACC (Honduras), FACC (Nicaragua), FACC (Costa Rica), FACC (Panama), FACC (Cuba), FACC (Haiti), FACC (Dominican Republic), FACC (Puerto Rico), FACC (Virgin Islands), FACC (Cayman Islands), FACC (Belize), FACC (Guatemala), FACC (El Salvador), FACC (Honduras), FACC (Nicaragua), FACC (Costa Rica), FACC (Panama)

MALIK RADIX HEALTHCARE PVT. LTD.

AFROZ

I.D. 1907

Age 49/F

Date 03-11-2023

RATE 98bpm

B.P. 134/84

Brucis

RECOVERY

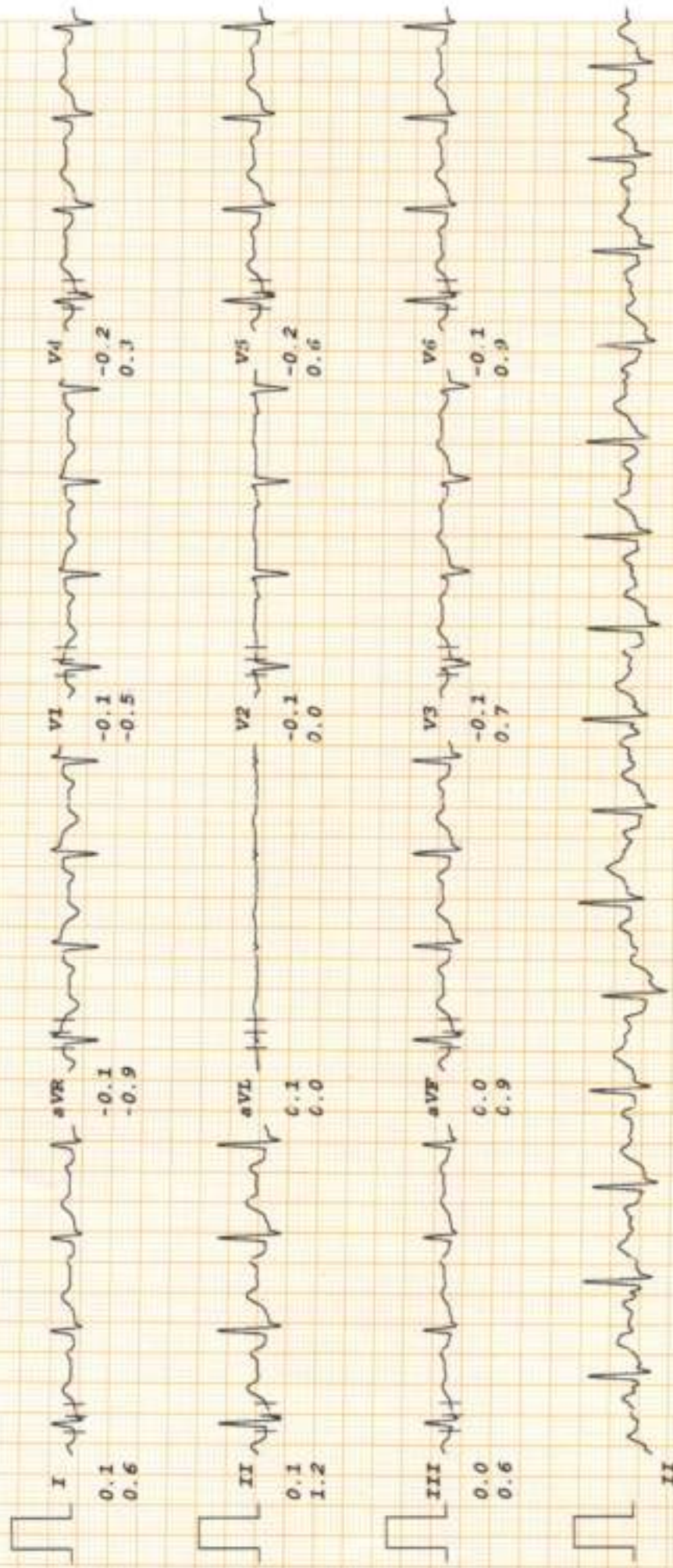
TOTAL TIME 9:11

PHASE TIME 4:55

ST θ 10mm/mV

80ms PostJ

LINKED MEDIAN



MALIK RADIX HEALTHCARE PVT. LTD.

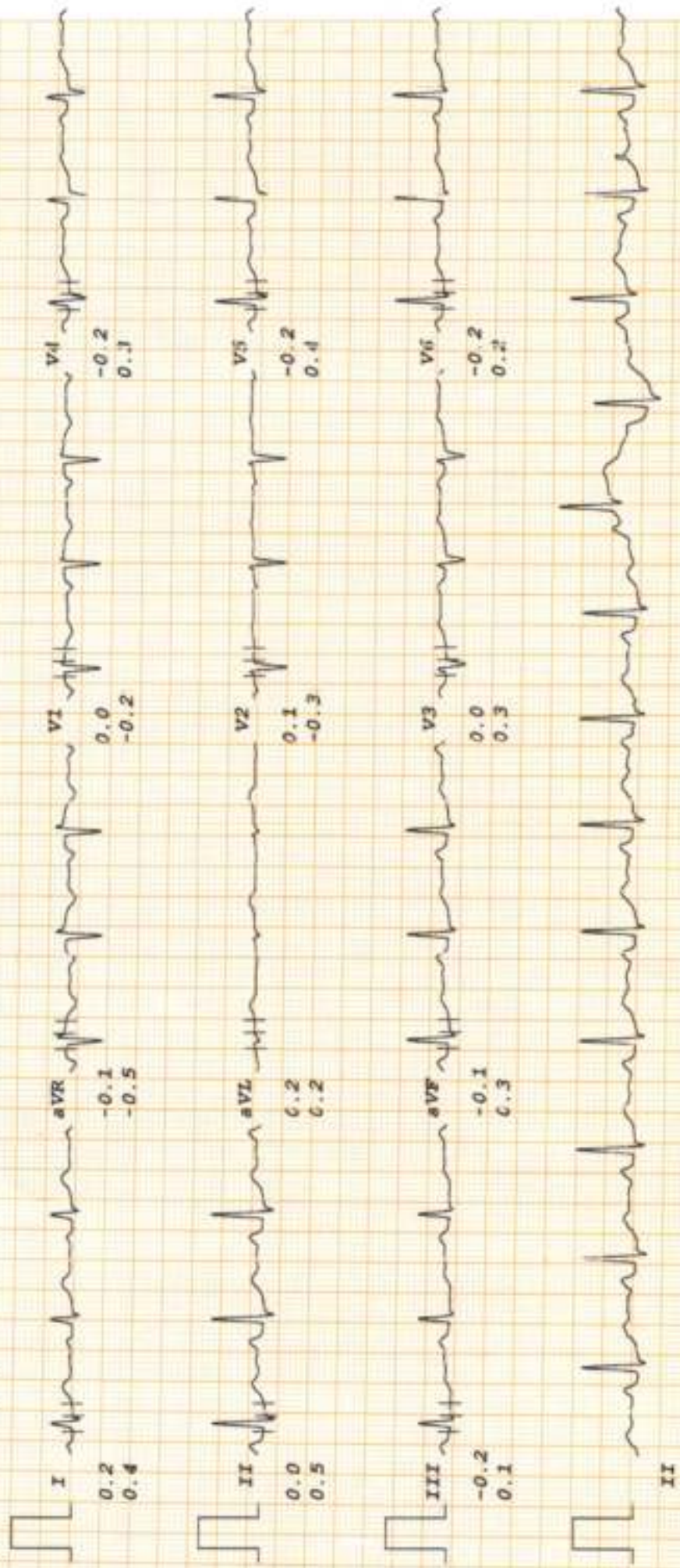
AFROE
 I.D. 1907
 Age 49/F
 Date 03-11-2023

RATE 87bpm
 B.P. 132/80

Bruc's
 RECOVERY
 TOTAL TIME 12:11
 PHASE TIME 5:55

ST. @ 10mm/mV
 80ms PostJ

LINKED MEDIAN





Name - Mrs. Afroz
Age - 49 yrs

03/11/2023

Routine Checkup

V → 4/6 ✓
 6/6 ✓

Uterus → No
 No

Cervix → WNL

Dr. N. G. Gupta
MBBS, DGO, DNB
Gynaecologist & Obstetrician
Malik Radix Healthcare
C/217, C/218, Vikas Marg, Nirman Vihar, New Delhi, Delhi 110092

Facilities Available

- Multispecialty Hospital - 24 Hours Emergency - X-Ray/ ECG/ Ultrasound/ CT Scan - Dental - Fully Equipped Operation Theatre
- Fully Functional Lab - 24/7 Casualty/ ICU-Nursery 24/7 Pharmacy - Labour Room - All Speciality OPD - Laproscopic Surgery - ECHO - Plastic Surgery



LAB REPORT

Reg. Date	03/11/2023	Patient Id	2311030001	DOB.	
Name	MRS. AFROZ	Gender	F	Perm. ID	
Age	49 Yrs.	Panel	MEDIWHEEL	Reported	03/11/2023 17:18:08
Ref. By	MEDIWHEEL				

Test Name	Result	Units	Ref. Range
-----------	--------	-------	------------

PLUS CHECK ADVANCED F ANNUAL

HAEMATOLOGY

COMPLETE HAEMOGRAM

HAEMOGLOBIN (HB%)	12.5	gm/dl	12 - 15
TOTAL LEUCOCYTE COUNT (TLC)	7,000	/cumm	4000 - 11000
<u>DIFFERENTIAL LEUCOCYTE COUNT (DLC)</u>			
NEUTROPHIL	59	%	40 - 80
LYMPHOCYTE	30	%	28 - 55
MONOCYTE	08	%	02 - 10
EOSINOPHIL	03	%	01 - 06
BASOPHIL	00	%	0 - 0
ESR (WESTEGREN'S METHOD)	10	mm/1st hr.	0 - 15
R B C COUNT	4.65	Millions/cmm	4,247 - 5.4
P.C.V / HAEMATOCRIT	42.4	%	35 - 45
M C V	91.2	fl.	80 - 100
M C H	26.9	Picogram	27.0 - 31.0
M C H C	29.5	gm/dl	33 - 37
PLATELET COUNT	2.68	Lakh/cu mm	1.50 - 4.50

Urine Routine Examination

PHYSICAL EXAMINATION

QUANTITY	30	ml.	
COLOUR	Pale Yellow		Pale Yellow
TRANSPARENCY	Clear		
SPECIFIC GRAVITY	1.025		
PH	6.0		

Checked by : _____
 Page 1 Contd..2

If test results are alarming or unexpected, patient is advised to contact the laboratory immediately for possible remedial action.

Facilities Available

- Multispeciality Hospital - 24 Hours Emergency - X-Ray/ ECG/ Ultrasound/ CT Scan - Dental- Fully Equipped Operation Theatre
- Fully Functional Lab - 24/7 Casualty/ ICU-Nursery 24/7 Pharmacy - Labour Room - All Speciality OPD - Laproscopic Surgery - ECHO - Plastic Surgery



LAB REPORT

Reg. Date	03/11/2023	Patient Id	2311030001	DOB.	
Name	MRS. AFROZ	Gender	F	Perm. ID	
Age	49 Yrs.	Panel	MEDIWHEEL	Reported	03/11/2023 17:18:08
Ref. By	MEDIWHEEL				

Test Name	Result	Units	Ref. Range
-----------	--------	-------	------------

CHEMICAL EXAMINATION

ALBUMIN	Nil		
SUGAR	Nil		

MICROSCOPIC EXAMINATION

PUS CELLS	2-3	/HPF	
RBC'S	Nil	/HPF	
CASTS	Nil		
CRYSTALS	NIL		
EPITHELIAL CELLS	2-3	/HPF	
BACTERIA	Nil		
OTHERS	Nil		

BLOOD GROUP ABO	" O "		
-----------------	-------	--	--

RH TYPING	Positive		
-----------	----------	--	--

BLOOD SUGAR FASTING	89.99	mg/dl	70 - 100
---------------------	-------	-------	----------

BLOOD SUGAR PP	149.98	mg/dl	90 - 140
----------------	--------	-------	----------

THYROID PROFILE

Free T3 ELIA	2.29	ng/ml	02 - 04
-----------------	------	-------	---------

Free T4 ELIA	1.41	ug/dl	0.8 - 2.7
-----------------	------	-------	-----------

TSH Serum/ELFA	1.200	uIU/ml	0.25 - 5.50 uIU/ml
-------------------	-------	--------	--------------------

Interpretation**Clinical Use**

- Diagnose Hypothyroidism and Hyperthyroidism

Checked by : _____
 Page 2 Contd...3

If test results are alarming or unexpected, patient is advised to contact the laboratory immediately for possible remedial action.

Facilities Available

- Multispeciality Hospital - 24 Hours Emergency - X-Ray/ ECG/ Ultrasound/ CT Scan - Dental- Fully Equipped Operation Theatre
 - Fully Functional Lab - 24/7 Casualty/ ICU-Nursery 24/7 Pharmacy - Labour Room - All Speciality OPD - Laproscopic Surgery -
 ECHO - Plastic Surgery



LAB REPORT

Reg. Date	03/11/2023	Patient Id	2311030001	DOB.	
Name	MRS. AFROZ	Gender	F	Perm. ID	
Age	49 Yrs.	Panel	MEDIWHEEL	Reported	03/11/2023 17:18:08
Ref. By	MEDIWHEEL				

Test Name	Result	Units	Ref. Range
-----------	--------	-------	------------

- Monitor T4 replacement or T4 suppressive Therapy
- Quantify TSH levels in the subnormal range

Increased Levels : Primary Hypothyroidism Subclinical Hypothyroidism, TSH dependent, Thyroid Hormone Resistance.

Decreased Levels : Grave's Disease, Autonomous Thyroid Hormone Secretion, TSH Deficiency

LIPID PROFILE

TOTAL CHOLESTEROL	166.80	mg/dL	130.0 - 200.0 (<200)
TRIGLYCERIDES	86.80	mg/dL	80.5 - 150.0 (<150)
H D L CHOLESTEROL DIRECT	52.82	mg/dL	42.0 - 60.0 (<40->59)
V L D L	17.4	mg/dL	4.0 - 30. (23-45)
L D L CHOLESTEROL	96.6	mg/dL	50.0 - 150.0 (50-150)
TOTAL CHOLESTEROL / HDL RATIO	3.2		3.3 - 5.1
LDL / HDL CHOLESTEROL RATIO	1.8		1.5 - 3.5
SERUM URIC ACID	4.77	mg/dl	2.4 - 6.0
BLOOD UREA NITROGEN (BUN)	8.65	mg/dl	6.0 - 21.0
SERUM CREATININE	0.75	mg/dl	0.6 - 1.2
BUN/CREAT RATIO	11.5	mg/dl	

10 - 20

LIVER FUNCTION TEST (LFT)

BILIRUBIN TOTAL	0.81	mg/dl	0.2 - 1.2
CONJUGATED (D. BILIRUBIN)	0.24	mg/dl	0.00 - 0.3
UNCONJUGATED (L.D. BILIRUBIN)	0.57	mg/dl	0.2 - 0.9

Checked by : _____
Page 3 Contd...4

If test results are alarming or unexpected, patient is advised to contact the laboratory immediately for possible remedial action.

Facilities Available

• Multispeciality Hospital - 24 Hours Emergency - X-Ray/ ECG/ Ultrasound/ CT Scan - Dental- Fully Equipped Operation Theatre
 • Fully Functional Lab - 24/7 Casualty/ ICU-Nursery 24/7 Pharmacy - Labour Room - All Speciality OPD - Laproscopic Surgery -
 ECHO - Plastic Surgery



LAB REPORT

Reg. Date	03/11/2023	Patient Id	2311030001	DOB.	
Name	MRS. AFROZ	Gender	F	Perm. ID	
Age	49 Yrs.	Panel	MEDIWHEEL	Reported	03/11/2023 17:18:08
Ref. By	MEDIWHEEL				

Test Name	Result	Units	Ref. Range
SGOT / AST	42.20	IU/L	0 - 35
SGPT / ALT	26.1	IU/L	0 - 35
ALKALINE PHOSPHATASE	126.40	U/L	64 - 306
TOTAL PROTEIN	7.64	gm/dl	6.0 - 8.3
ALBUMIN	4.37	gm/dl	3.2 - 5.0
GLOBULIN	3.27	gm/dl	2.5 - 5.6
A/G RATIO	1.34		0.9 - 2.0
GAMMA GT	23.10	IU/L	0.0 - 35.0

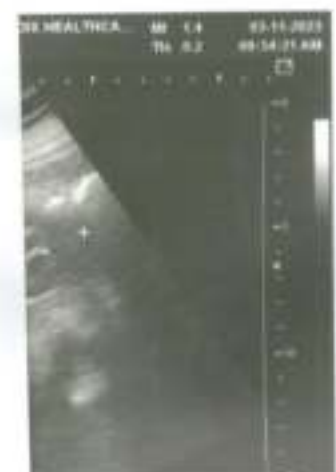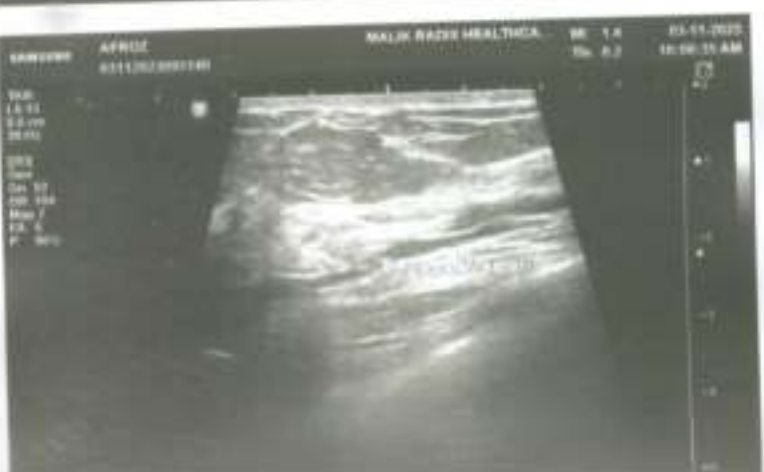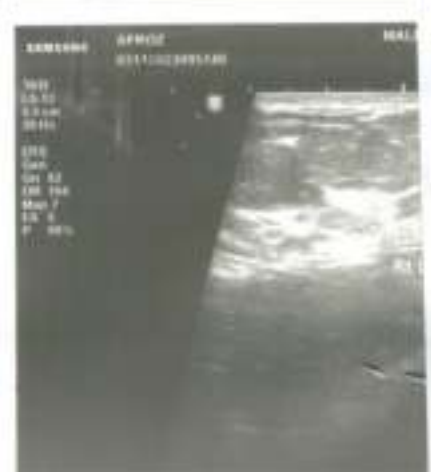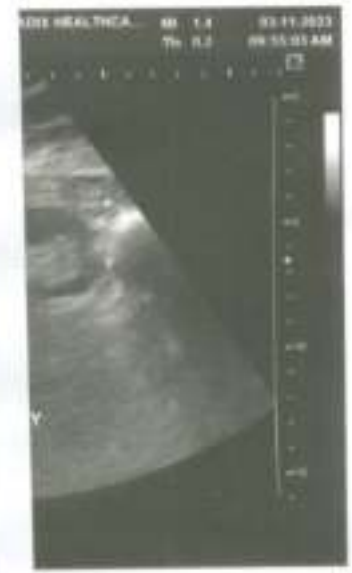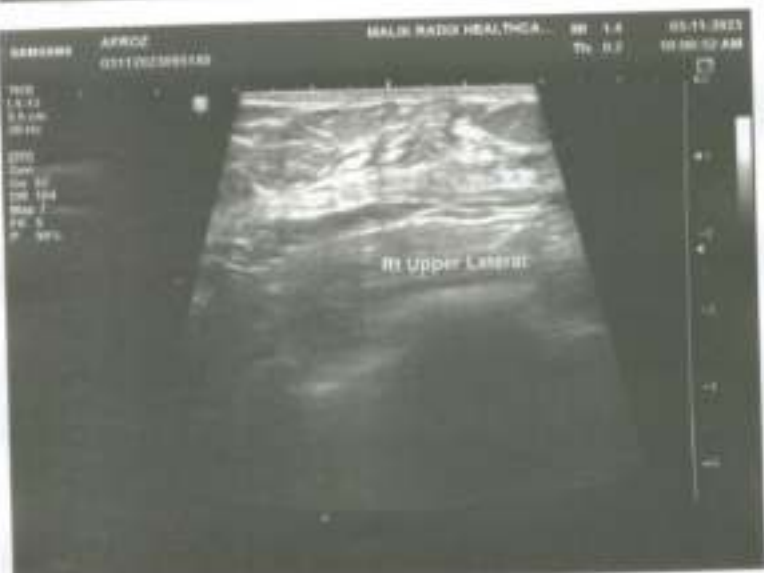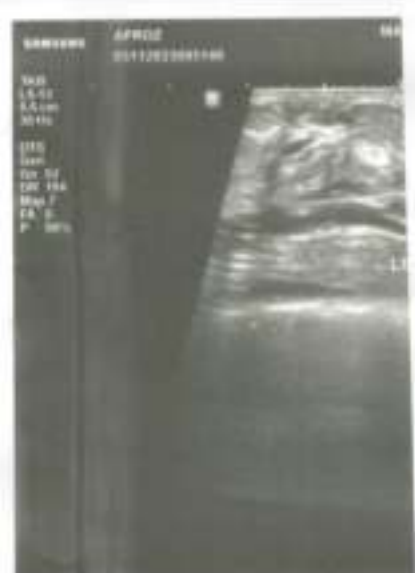

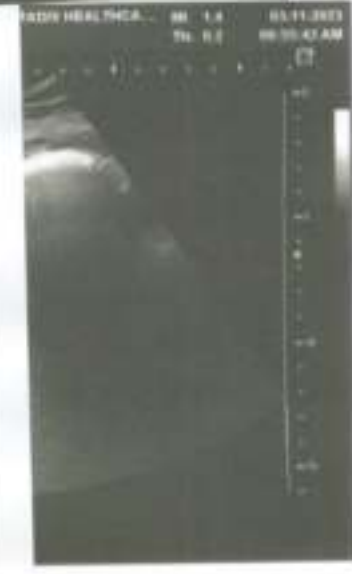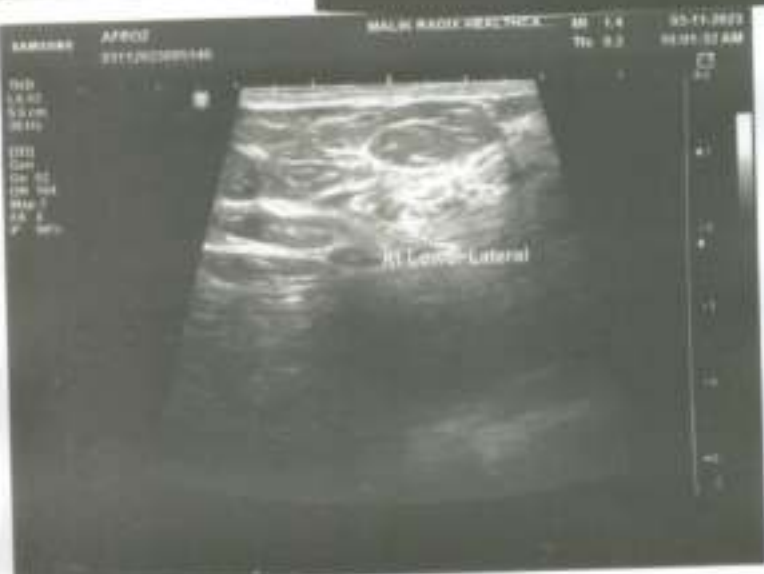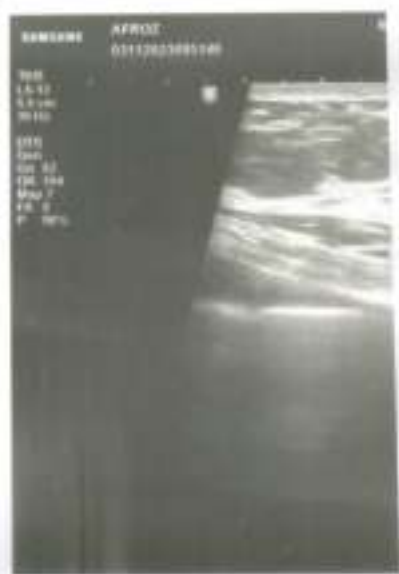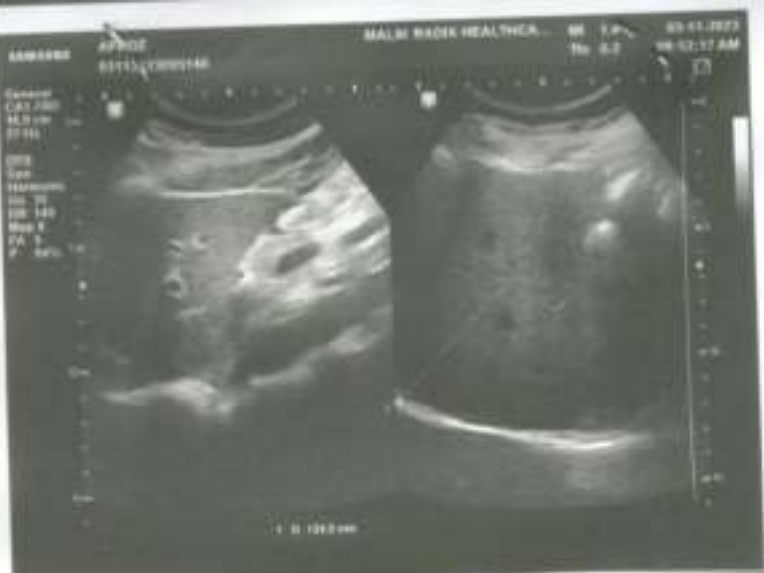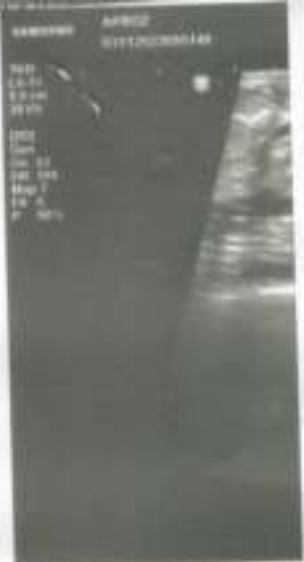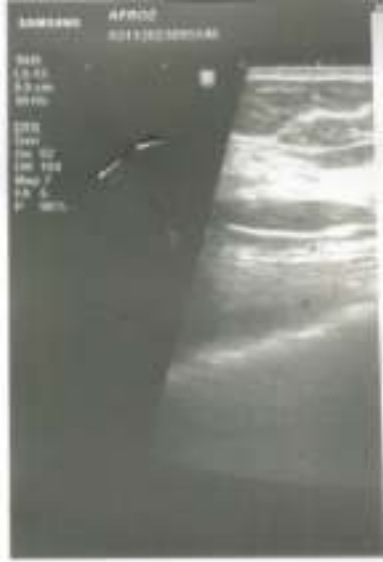Dr. REEMA DAHIYA
 M.B.B.S., MD (Path)
 Malik Radix Healthcare Pvt. Ltd.
 C/217, C/218, Vikas Marg, Nirman Vihar,
 New Delhi-110092
 Checked by _____
 Page 4 of 4

DR. MEENU AGGARWAL
 M.B.B.S., MD (Path.)

If test results are alarming or unexpected, patient is advised to contact the laboratory immediately for possible remedial action.

Facilities Available

- Multispeciality Hospital - 24 Hours Emergency - X-Ray/ ECG/ Ultrasound/ CT Scan - Dental- Fully Equipped Operation Theatre
- Fully Functional Lab - 24/7 Casualty/ ICU-Nursery 24/7 Pharmacy - Labour Room - All Speciality OPD - Laproscopic Surgery - ECHO - Plastic Surgery





NAME	MRS AFROZ	AGE	49 Y/F
REFD. BY	HELATH CHECK UP	DATE	03.11.23

Ultrasound Examination of Whole Abdomen & Pelvis:

Liver: Liver is normal in size (12.4 cm) with normal outlines and shows normal parenchymal echotexture. No focal lesion is seen. IHBR & portal radicles are normal.

Gallbladder: Gallbladder is well distended. No evidence of cholecystitis or cholelithiasis seen. Common bile duct is normal in course & caliber.

Pancreas: Pancreas shows normal size, outlines & echotexture. No focal lesion is seen. MPD is not dilated.

Spleen: Spleen shows normal size (7.7 cm), outline & echotexture.

Kidneys: Kidneys show normal size, shape, position & echotexture. No calculus/ hydronephrosis or SOL is seen in kidneys. Cortico- medullary differentiation and cortical thickness is normal on both sides.

Right kidney measures - 10.2 X 4.2 cm

Left kidney measures - 8.8 X 4.8 cm

Great abdominal vessels are normal.

No ascites seen

No para-aortic lymph nodes seen.

Urinary bladder: Urinary bladder is well distended. Walls and lumen appear normal.

Uterus: Uterus is retroverted normal in size outline and echotexture. No focal lesion is seen. Endometrium is central and measures 4 mm. Few Nabothian cyst seen in cervix.

Both adnexa appear unremarkable.

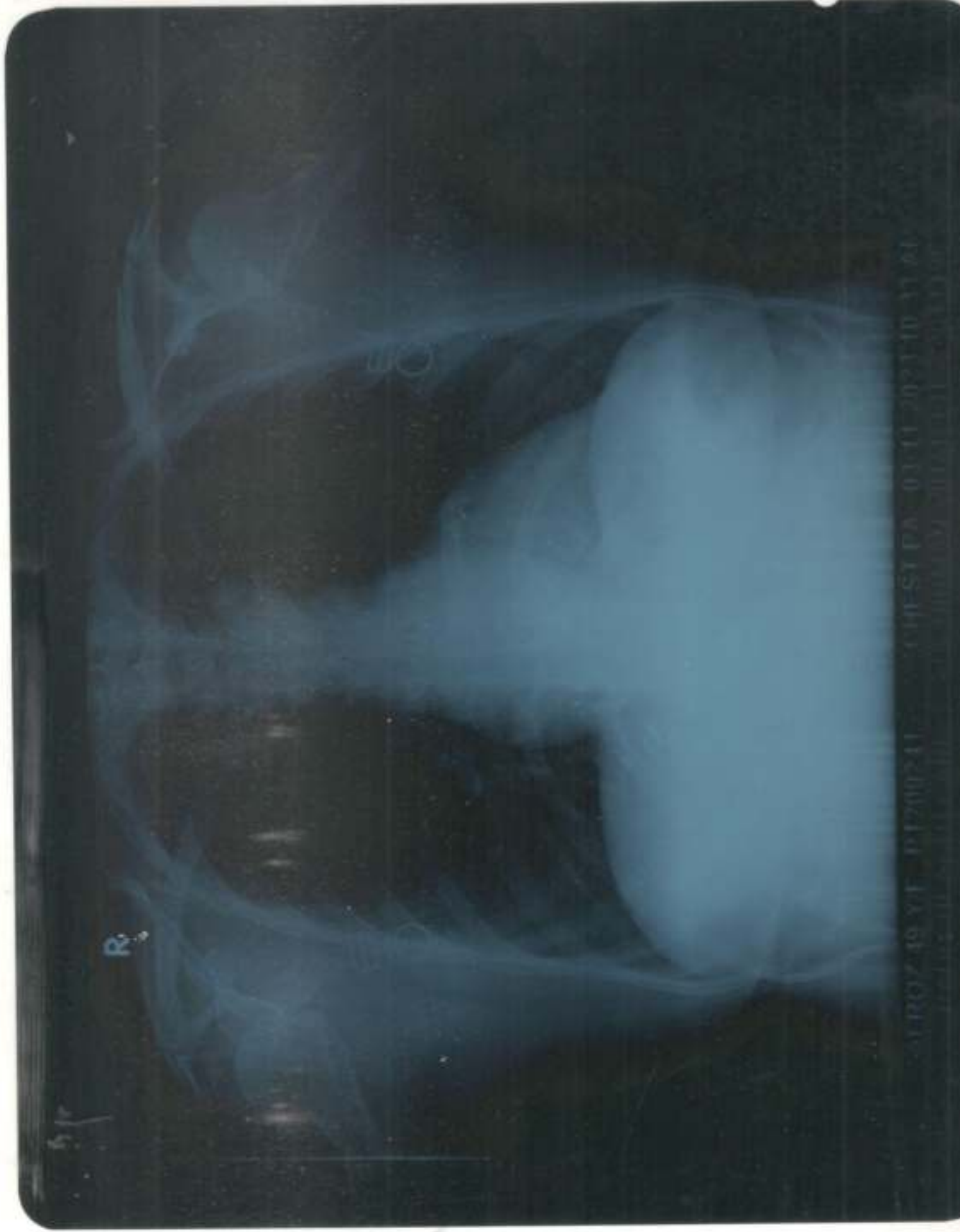IMPRESSION: Normal study

Dr Shreyash Tiwary MD (Rad- diag)

Regn. No. DMC 85807

RADIOLOGIST :

Facilities Available



R

PROZ 49 YF P1700241 CHEST PA 03 11 2013 10 33 04



UHID	PT200241	LAB No.	XRY2306450
Name	Mrs. AFROZ	Regn. No.	GEN2326788
Age / Sex	49 Yrs / F	Receiving Dt/Time	03-Nov-2023 10:33
		Reporting Dt/Time	03-Nov-2023 11:58 AM



XRAY

CHEST (PA)

Both lung fields are normal.

Cp angles are clear.

Hila are normal...

Heart size appears within normal limits.

Soft tissue shadows and bony thorax are normal.

IMP- NORMAL CHEST X-RAY

Advised... please correlate clinically.

***** END OF REPORT *****

DR. K.E. SINHA
M.B.B.S. D.V.R.D.
SENIOR CONSULTANT
Reg. No. 25437 (DMC)

DR. RAJESH MALHOTRA
MBBS, MD (RADIOLOGY)
CONSULTANT RADIOLOGY
Reg.No.DMC8299

DR. T. K VOHRA
MD (RADIODIAGNOSIS)
SENIOR CONSULTANT
Reg. No. 3272 (DMC)

DR. MUKESH KOSHAL
MBBS, MD (RADIOLOGY)
CONSULTANT RADIOLOGY
Reg No.DMC19407

DR. SHREYASH TIWARY
MBBS, MD (RADIOLOGY)
CONSULTANT RADIOLOGY
Reg.No.DMC8582

Facilities Available

- Multispecialty Hospital - 24 Hours Emergency - X-Ray/ ECG/ Ultrasound/ CT Scan - Dental - Fully Equipped Operation Theatre
- Fully Functional Lab - 24/7 Casualty/ICU-Nursery 24/7 Pharmacy - Labour Room - All Speciality OPD - Laproscopic Surgery - ECHO - Plastic Surgery