

भारत सरकार
GOVERNMENT OF INDIA



मूर्थी जहंसी लक्ष्मी
Murthy Jhansi Lakshmi
प्रसूत तिथि / DOB: 10/06/1984
स्त्री / FEMALE

4779 9905 0646

मेरा आधार - मेरी पहचान

भारतीय विशिष्ट पहचान प्राधिकरण
UNIQUE IDENTIFICATION AUTHORITY OF INDIA

पतेनामा: Address:
W/O K M Chandrasekhar, 1-1-
127, लक्ष्मी निलयम्, कोलमिडा,
Opposite Panchayat Water Tank,
Sullurpeta mandal, Sullurpeta,
Mettur,
Andhra Pradesh - 524121

4779 9905 0646

मेरा AADHAAR, मेरी PEHACHAN

Jhansi Lakshmi
(for medical checkup
25/2/22)



MURUGAN HOSPITALS

HEALING HANDS



LAB REPORT

Patient Name : Mrs. M.JHANSILAKSHMI
Age / Gender : 37-Years / Female
UHID ID : MH20220035117
Doctor Name : Dr. ARUN PRAKASH

OP Report No. : INVA2104596
Bill No. : INV2108059
Sample Date : 25/02/2022 - 11:20 AM
Report Date : 25/02/2022 - 01:51 PM

Test Name	Result	Units	Reference Interval
HAEMATOLOGY			
Complete Blood Cell Count(CBC)			
HAEMOGLOBIN	12.4	gms/dl	male :13.0 - 17.0 female :12.0 - 15.0
PACKED CELL VOLUME	38.5	%	male : 40 - 50 female : 36 - 46
RBC COUNT	4.50	millions cells/cu.mm	female: 3.8 - 4.8 male : 4.5 - 5.5
TOTAL WBC	7,600	Cells/Cumm	4,000 - 11,000
Differential Count			
NEUTROPHILS	65	%	40 - 65
LYMPHOCYTES	29	%	30-50
EOSINOPHILS	04	%	01-06
MONOCYTES	02	%	1-10
BASOPHILS	00	%	0-2
ESR 60 MTS	10	mm	5 - 20
PLATELET COUNT	2.24	Lakhs/cumm	1.5 - 4.5
MCV	85.6	fL	76 - 96
MCH	27.5	pg	27 - 32
MCHC	32.2	gms/dl	30 - 36

INTERPRETATION: Test done on automated three part cell counter, all abnormal results are reviewed and confirmed microscopically

BLOOD GROUPING & RH TYPING " B " POSITIVE

Page 1 of 4

Healing Hearts and Lives

264/125, Kilpauk Garden Road, Kilpauk, Chennai - 600 010.
Phone : +91 44 4644 8989 / 75500 53335 | Email : muruganhosp@gmail.com
Website : www.muruganhospitals.in



MURUGAN HOSPITALS

HEALING HANDS



LAB REPORT

Patient Name : Mrs. M.JHANSILAKSHMI
 Age / Gender : 37-Years / Female
 UHID ID : MH20220035117
 Doctor Name : Dr. ARUN PRAKASH

OP Report No. : INVA2104596
 Bill No. : INV2108059
 Sample Date : 25/02/2022 - 11:20 AM
 Report Date : 25/02/2022 - 01:51 PM

Test Name	Result	Units	Reference Interval
BIO CHEMISTRY			
BLOOD SUGAR FASTING	85	mgs/dl	70-110
BLOOD SUGAR POST PRANDIAL	93	mgs/dl	80- 160
SERUM URIC ACID	4.4	mg/dl	male 3.1-7.0 , female 2.5-5.6
SERUM CREATININE	0.7	mg/dl	0.7-1.4
LIPID PROFILE			
TOTALCHOLESTEROL	196	mg/dl	< 200
TRIGLYCERIDE	109	mg/dl	< 150
HDL	49	mg/dl	35 - 80
VLDL	22	mg/dl	2 to 30
LDL	125	mg/dl	<130
CHOLESTEROL/ HDL RATIO	4.0	mg/dl	

Healing Hearts and Lives

264/125, Kilpauk Garden Road, Kilpauk, Chennai - 600 010.

Phone : +91 44 4644 8989 / 75500 53335 | Email : muruganhosp@gmail.com

Website : www.muruganhospitals.in



MURUGAN HOSPITALS

HEALING HANDS



LAB REPORT

Patient Name : Mrs. M.JHANSILAKSHMI
 Age / Gender : 37-Years / Female
 UHID ID : MH20220035117
 Doctor Name : Dr. ARUN PRAKASH

OP Report No. : INVA2104596
 Bill No. : INV2108059
 Sample Date : 25/02/2022 - 11:20 AM
 Report Date : 25/02/2022 - 01:51 PM

Test Name	Result	Units	Reference Interval
LIVER FUNCTION TEST			
BILLIRUBIN(TOTAL)	0.8	mg/dl	0.0 -1.0
BILLIRUBIN(DIRECT)	0.2	mg/dl	0.1- 0.30
BILLIRUBIN(INDIRECT)	0.6	mg/dl	0.2-0.8
SGOT	23	IU/L	0-38
SGPT	24	IU/L	0.0-40
ALKALINE PHOSPHATASE	86	IU/L	40-140 4-6Years 93-309 13-15Years 74-390
TOTAL PROTEIN	7.6	gm/dl	6.6-8.7
ALBUMIN	4.5	gm/dl	3.5 - 5.5
GLOBULIN	3.1	gm/dl	2.0-3.5
AG RATIO	1.4		
GAMMA G T	20	U/L	male<49 female<32
BLOOD UREA NITROGEN	7.2	mg/dl	7-21
HBA1C	4.5	%	normal: <6.0 good control: 6.1-7.0 fair control: 7.1- 8.0 poor control:8.1 -10.0 unsatisfactory: >10.0

Healing Hearts and Lives

264/125, Kilpauk Garden Road, Kilpauk, Chennai - 600 010.

Phone : +91 44 4644 8989 / 75500 53335 | Email : muruganhosp@gmail.com

Website : www.muruganhospitals.in



LAB REPORT

Patient Name : Mrs. M.JHANSILAKSHMI
 Age / Gender : 37-Years / Female
 UHID ID : MH20220035117
 Doctor Name : Dr. ARUN PRAKASH

OP Report No. : INVA2104596
 Bill No. : INV2108059
 Sample Date : 25/02/2022 - 11:20 AM
 Report Date : 25/02/2022 - 01:51 PM

Test Name	Result	Units	Reference Interval
CLINICAL PATHOLOGY			
URINE SUGAR (F)	NIL		
URINE SUGAR (PP)	NIL		
URINE ROUTINE			
COLOUR	PALE YELLOW		
APPEARANCE	CLEAR		
REACTION	ACIDIC		
ALBUMIN	NIL		
DEPOSITES			
PUS CELLS	1 - 2	/ HPF	
EPI CELLS	2 - 3	/ HPF	
RBC COUNT	NIL	/ HPF	
CAST	NIL		
CRYSTALS	NIL		
OTHERS	NIL		

MALATHI

Verified by

*** End of Report ***



Healing Hearts and Lives



MIRUGAN HOSPITALS
HEALING HANDS

Mrs. M. JHANSILAKS-MI
OP21017974- MH202200351-7
37 Yrs 8 Months Female
25/02/2022 09:04
Dr. ARUN PRAKAS-

25/2/22

N

37/F

OLE: Bil. ears. Tympanic memb visualized.
no ear wax
no pus discharge
no perforation visualized.

Oral cavity: H/o Root canal treatment done
no other decay in teeth visualized.



264/125, Kilpauk Garden Road, Kilpauk, Chennai - 600 010.

☎ : +91 44 4644 8989 / 75500 53335 email : muruganhosp@gmail.com

Website : www.muruganhospitals.in



MURUGAN HOSPITALS
HEALING HANDS

Date : 25/02/2022

NAME OF PATIENT : **MRS.M.JHANSILAKSHMI**

AGE : 37 / **FEMALE**

Nil visual complaints

O/E

V/A

OD : 6/6 N6

OS : 6/6 N6

Within normal limits in both eyes.

IMPRESSION :

- Nil ophthalmic problem


Medical Officer

264/125, Kilpauk Garden Road, Kilpauk, Chennai - 600 010.

☎ : +91 44 4644 8989 / 75500 53335 email : muruganhosp@gmail.com

Website : www.muruganhospitals.in



MURUGAN HOSPITALS
HEALING HANDS



SCAN REPORT

NAME : Mrs.M.JHANSILAKSHMI

AGE / SEX: 37 YEARS / FEMALE

CONSULTANT: DR. ARUN PRAKASH

UHID NO : MH20220035117

DATE : 25- 02- 2022

OP/IP : OUT PATIENT

CHEST XRAY PA VIEW

- Trachea is in midline.
- Hila appear Normal.
- Mediastinal shadow appears normal.
- Costophrenic&Cardiophrenic angles appear free.
- Cardiothoracic ratio is within normal limits.
- Lungs fields appear clear
- Bony thorax and soft tissue appear normal

IMPRESSION:

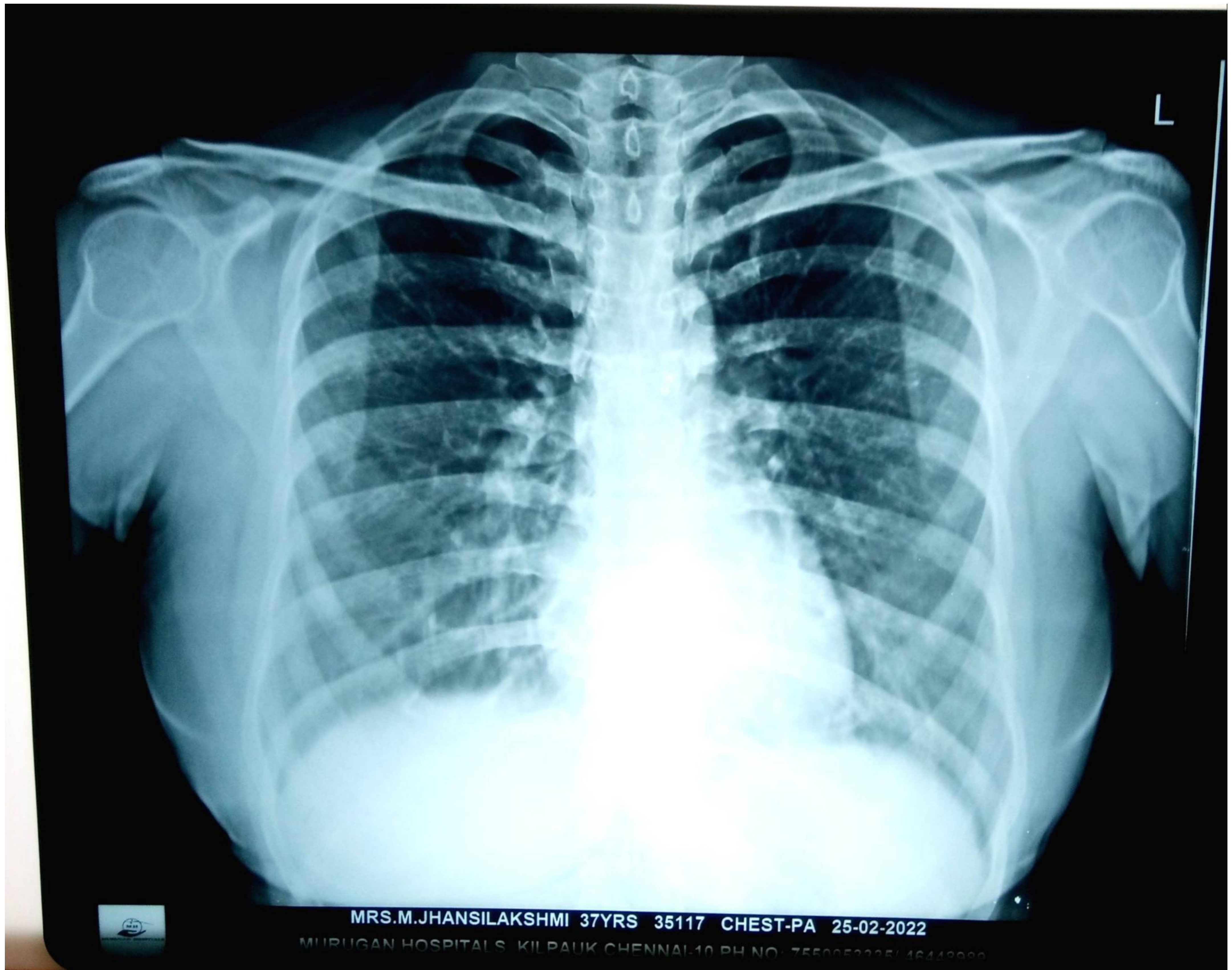
- No significant abnormality noted.



CONSULTANT RADIOLOGIST

Healing Hearts and Lives

264/125, Kilpauk Garden Road, Kilpauk, Chennai - 600 010. Phone : +91 44 4644 8989 / 75500 53335
Email : muruganhosp@gmail.com | Website : www.muruganhospitals.in



Scanned by TapScanner

ID : 2202250001
Name: jhansilakshmi
Sex : Female
Divisions:

DateTime: 2022-02-25 09:18
Age : 37
BP : 120/80 mmHg
Bed No. :

Hospital: MURUGAN HOSPITALS
Height : 162 cm
Weight : 63 kg
Hospital No. :

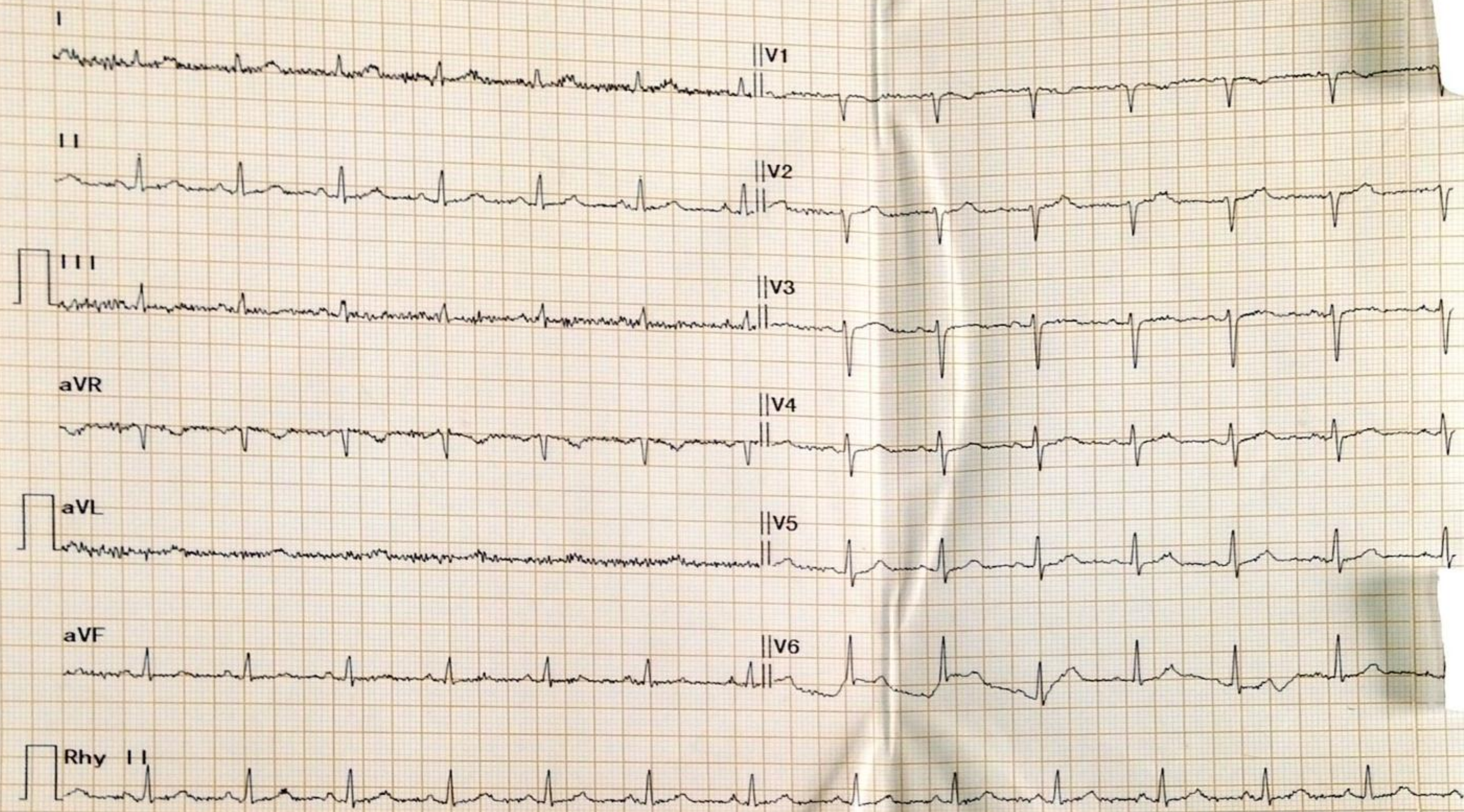
HR 83 bpm
P Dur / PR int 78 / 142ms
QRS Dur 83 ms
QT / QTC int 336 / 399 ms
P / QRS / T axis 65 / 59 / 26 °

RV5 / SV1 amp 0.613 / 0.561mV
RV5 + SV1 amp 1.174mV
RV6 / SV2 amp 0.841 / 0.629mV

Minnesota Code
1-1-2 (V1)
9-4-2 (V4)

Diagnosis Info
800: Sinus Rhythm

Normal ECG



Diagnosis for reference. ask your doctor to confirm
AUTO PRINT 6X2+1R 83bpm 10 mm/mV 0.50Hz-45Hz AC 60Hz 25 mm/sec Confirmed By:

Dr. SIDHARTHAN, MD, DM.
Consultant Cardiologist
Reg. No.: 62879



ECHO CARDIOGRAM REPORT

NAME : MR.M.JHANSI LAKSHMI UHID NO: MH20220035117
AGE&SEX : 37Y /FEMALE IP/OP : OUTPATIENT
CONSULTANT: DR. ARUN PRAKASH DATE : 25-02-2022

2D PLAX (mm)

RV - 36 mm
AO - 35 mm
LA - 28 mm

COLOR DOPPLER

Normal

M-Mode (mm)

IVS - 08 mm
PW - 10 mm
LVD - 48 mm
LVS - 26 mm
EF - 61 %
FS - 33 %

DOPPLER (m/sec)

MITRAL E - 0.3 m/s
MITRAL A - 0.5 m/s
PULMONARY - 0.6 m/s
AORTIC - 0.8 m/s
TRICUSPID - 0.4 m/s

IMPRESSION:

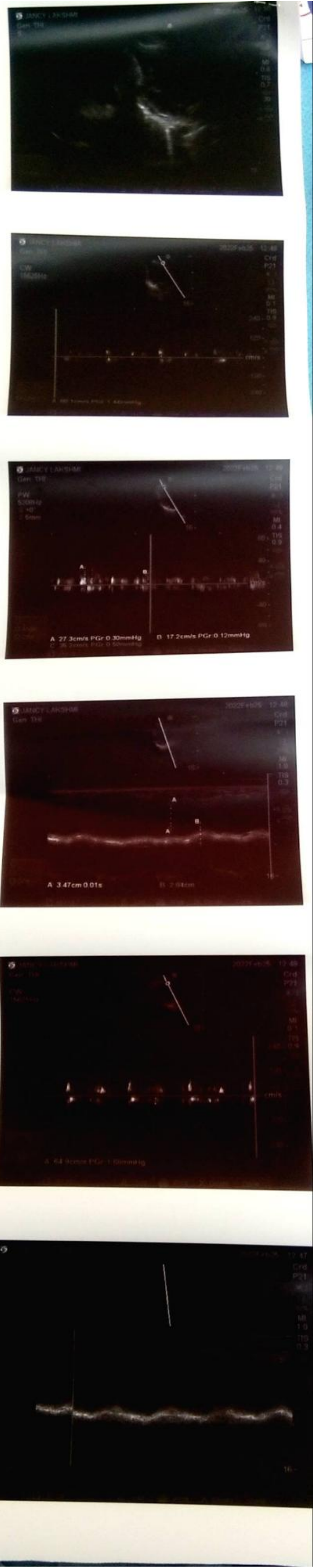
No RWMA
Normal LV Systolic function
Grade I left ventricular diastolic dysfunction
Normal RV function
No pulmonary hypertension
No pericardial effusion
No clot/ Vegetation.



DR.SIDHARTHAN MD.,DM.,
CONSULTANT CARDIOLOGIST

Healing Hearts and Lives

264/125, Kilpauk Garden Road, Kilpauk, Chennai - 600 010.
Phone : +91 44 4644 8989 / 75500 53335 | Email : muruganhosp@gmail.com
Website : www.muruganhospitals.in





SCAN REPORT

NAME : MRS.M.JHANSI LAKSHMI UHID NO : MH20220035117
AGE / SEX : 37/FEMALE IP / OP NO: OUTPATIENT
CONSULTANT: DR. ARUN PRAKASH DATE : 25-02-2022

ULTRA SOUND SCAN OF ABDOMEN WITH PELVIS

LIVER: Normal in size and normal in echotexture. No focal lesions are seen. No dilatation of intra-hepatic biliary radicals present. Hepatic veins and IVC appear normal. Portal vein is normal in caliber. Common bile duct is normal in caliber.

GALL BLADDER: Normal in size and wall thickness. No evidence of any calculus or mass present. No evidence of pericholecystic collections.

PANCREAS: Normal in size and echotexture. No focal lesions are seen. No evidence of calculi or calcifications. No evidence of pancreatic duct dilation.

PARA AORTIC AREAS: Aorta and IVC appear normal. No evidence of para aortic lymphadenopathy.

SPLEEN: Normal in size. Normal in echotexture. No evidence of focal lesions.

RIGHT KIDNEY: Measures 8.4 x 4.3cm and is normal in size and echotexture. Cortico medullary differentiation is well maintained. There is no calculus, hydronephrosis or mass.

LEFT KIDNEY: Measures 9.3 x 4.5cm and is normal in size and echotexture. Cortico medullary differentiation is well maintained. There is no or hydronephrosis or mass. **Microlith noted in mid pole of left kidney.**

Healing Hearts and Lives

264/125, Kilpauk Garden Road, Kilpauk, Chennai - 600 010. Phone : +91 44 4644 8989 / 75500 53335
Email : muruganhosp@gmail.com | Website : www.muruganhospitals.in

URINARY BLADDER: Minimally distended.

UTERUS AND OVARIES: Normal in size and echotexture. Measures 4.4 x 3.3 cm.
ET- 4.3 mm.

Bilateral ovaries appears normal in size and echotexture.

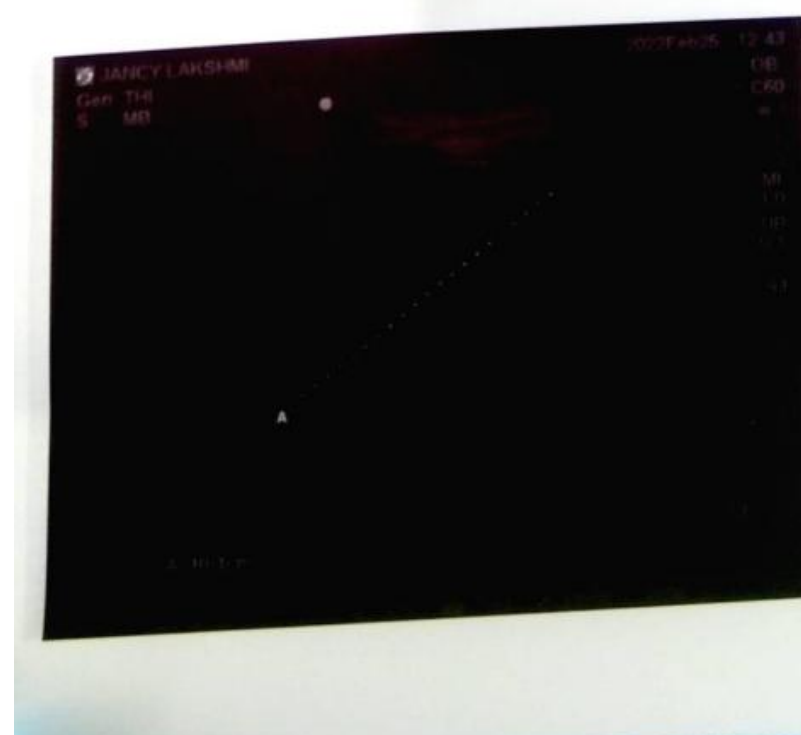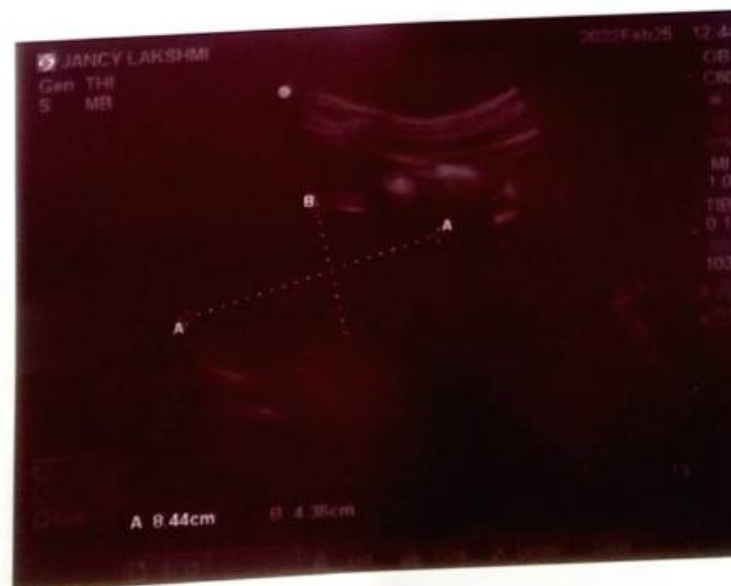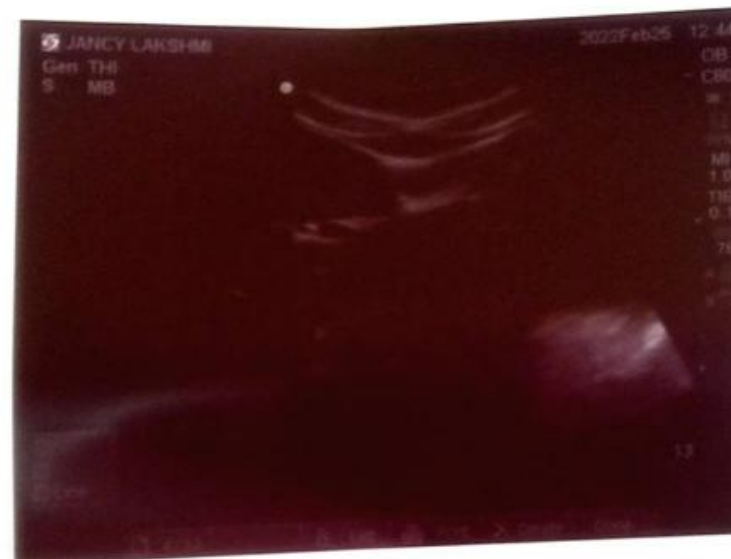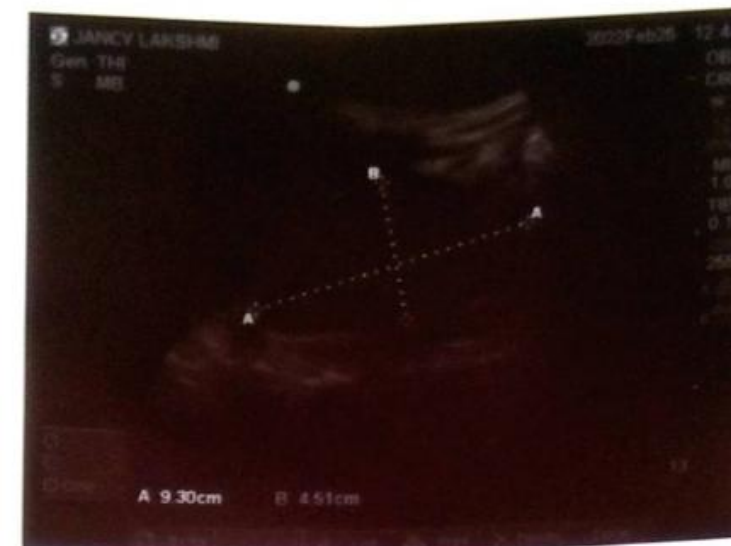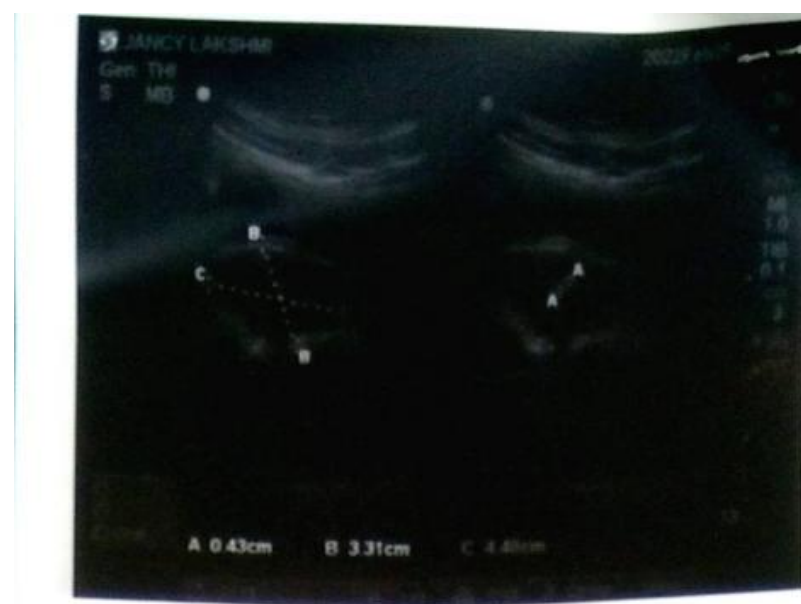No ascites present. No retroperitoneal lymphadenopathy present.

IMPRESSION:

- ✦ *Left renal microlith*
- ✦ *No other significant abnormality.*



Dr. SAKTHI, MDRD.
Consultant Radiologist.



This is M. Thansi Lakshmi, Bank of Baroda Employee.
Came ~~here~~ to Murugan hospitals, Kilpauk for annual health
medical check up which includes stool test. But I am
not interested to give sample. Hence this is for your
information.

Thansi Lakshmi

[M. Thansi Lakshmi
FC No - 161891]