

ARCOFEMI - MEDIWHEEL - FULL BODY ANNUAL PLUS CHECK 2600.00
 ADVANCED - FEMALE - 2D ECHO - PAN INDIA - FY2324

Credit

S. No.	Service Sub Group	Service Name
	Blood Bank	Blood Grouping And Typing (Abo And Rh)
	Bio Chemistry	Glycosylated Hemoglobin (HbA1C) - Whole Blood
	Bio Chemistry	THYROID PROFILE - I(T3, T4 AND TSH)
	Bio Chemistry	Lipid Profile (all Parameters)
	Bio Chemistry	Renal Function Test
	Bio Chemistry	LIVER FUNCTION TEST (PACKAGE)
	Bio Chemistry	GGTP: Gamma Glutamyl Transpeptidase - Serum
	Cardiology	EKG
	Ultrasound	Ultrasound - Whole Abdomen
0	Cytology	LBC PAP SMEAR Pending Peb smear
1	Consultations	Fitness by General Physician
2	Consultations	Consultation - Dental ✓
3	Consultations	Ophthal by General Physician ✓
4	Consultations	Package Consultation - ENT ✓
5	Consultations	Dietician consultation Done
6	Consultations	Package Gynaecological Consultation
7	Bio Chemistry	GLUCOSE - SERUM / PLASMA (FASTING AND POST PRANDIAL)
8	Bio Chemistry	URINE GLUCOSE (FASTING)
9	Bio Chemistry	URINE GLUCOSE (POST PRANDIAL)
0	Cardiology	2 D ECHO
1	X-Ray	X-Ray Chest PA
2	Mammography	SONO MAMOGRAPHY - SCREENING
3	Others	BMI ✓
4	Haematology	Urine Routine (CUE)
5	Haematology	HEMOGRAM (CBC+ESR)



सत्यमेव जयते
भारत सरकार



आधार

भारत सरकार

Unique Identification Authority of India

Government of India

नामांकन क्रम / Enrollment No 1001/18024/25984


To,
ममता शुक्ला
Mamta Shukla
W/O Santosh Bhooshan Shukla
SHUKULAN KA PURWA
Pure Noti
Babujanj Pratappgarh
Uttar Pradesh 230126
8960813318

31/03/2012

Ref: 2205 / 11F / 149495 / 149550 / P



UE570869534IN



आपका आधार क्रमांक / Your Aadhaar No. :

2253 8670 8041

आधार – आम आदमी का अधिकार



भारत सरकार
GOVERNMENT OF INDIA



ममता शुक्ला
Mamta Shukla
जन्म वर्ष / Year of Birth : 1977
महिला / Female



2253 8670 8041

आधार – आम आदमी का अधिकार


CERTIFICATE OF MEDICAL FITNESS

This is to certify that I have conducted the clinical examination

of Mrs. Mamta Shukla on 08/04/23

After reviewing the medical history and on clinical examination it has been found that he/she is

	Tick
<ul style="list-style-type: none"> • Medically Fit 	<input type="checkbox"/>
<ul style="list-style-type: none"> • Fit with restrictions/recommendations <p>Though following restrictions have been revealed, in my opinion, these are not impediments to the job.</p> <p>1. <u>Grade I fatty liver</u></p> <p>2. <u>Predrabotic</u></p> <p>3. <u>Dyslipidemia</u> <u>Uterine fibroid</u></p> <p>However, the employee should follow the advice/medication that has been communicated to him/her.</p> <p>Review after <u>3 months</u></p>	✓
<ul style="list-style-type: none"> • Currently Unfit. Review after _____ recommended 	<input type="checkbox"/>
<ul style="list-style-type: none"> • Unfit 	<input type="checkbox"/>

Dr. Saurabh Agarwal
Medical Officer
Apollo Clinic,

 Dr. Saurabh Agarwal
 MBBS, MD, FIDM (U) GE
 Reg. No. 68
 Apollo Clinic Hazratganj

This certificate is not meant for medico-legal purposes

Licensee: TECHNO MEDICALS INDIA

GST : 09ADNPA2038G1ZS

Address : TECHNO HERITAGE, Jehangirabad Palace,
Next to DM Residence, Hazratganj, Lucknow 226001

Online appointments : www.apolloclinic.com

Email : hazratganj.lko@apolloclinic.com

TO BOOK AN APPOINTMENT



Patient Name- Mrs. Mamta Shukla.	Date- 8/04/23
Age- 46	Sex- F.
B P - Systolic 136 Diastolic 85mmHg.	R.B.S.-
Pulse- 87b/min.	SPO2- 98%.
Temp- 96.7°F	Height- 159
Weight- 73.4kg	BMI- 29
Consultant- Dr. Saurabh Agarwal.	Fat- 29.8%.

- Dyslipidemia
- Prediabetic
- Grade I fatty liver

HbA_{1c} - 6.4%

- Bulky uterus + uterine fibroid
- Lt breast subcentimetric simple cysts

Rx @ Tab Atova 10mg 0-0-1 (HS) X 1 month

Advise : Avoid oily spicy food.
Avoid sugary things
Diet modification
Exercise 30 min/day

Saurabh
Dr. Saurabh Agarwal
MBBS, MD, FDM (H)
R. 11/12/2018
Apollo

Inw : USG Abdomen } after 3 months
Lipid profile }
HbA_{1c} }

- Consult Gynaecology dept.

Valid for 7 Days

Licensee: TECHNO MEDICALS INDIA

GST : 09ADNPA2038G1ZS

Address : TECHNO HERITAGE, Jehangirabad Palace,
Next to DM Residence, 12, Rani Laxmi Bai Marg,
Hazratganj, Lucknow 226001

Online appointments : www.apolloclinic.com

Email : hazratganj.lko@apolloclinic.com

TO BOOK AN APPOINTMENT

 7897 123 777

Patient Name	: MRS. MAMTA SHUKLA
Age/ Gender	: 46 Y/F
UHID/ MR No	: FHAZ.0000004166
Ref Doctor	: ARCOFEMI HEALTHCARE LTD


Reported	: 08.april.2023
Status	:
Client Name	:
Patient Location	: LUCKNOW

X-RAY CHEST PA

- Trachea is central in position.
- Bilateral lung fields are normally aerated.
- Both hilar shadows are normal.
- Both C.P angles are clear.
- Cardiac shadow is within normal limits.
- Bony cage appears normal.

OPINION: **NORMAL STUDY.**

Please correlate clinically



Dr. PRIYANK CHAUDHARY
(RADIOLOGIST)

Discrepancies due to technical or typing error should be reported for correction seven days. No compensation ability stands

PATIENT NAME : MRS MAMTA SHUKLA

AGE / SEX: 48 YRS/F

UHID : 3142

DATE : 08 , APRIL, 2023

2-D ECHO & M-MODE EXAMINATION VALVES

1. MITRAL VALVES STUDY:

a) **Motion:** Normal b) **Thickness:** Normal c) **Calcium-** none

2. AORTIC VALVE STUDY

a) **Aortic root** 2.5cm. b) **Aortic Opening** 1.7 cm. c) **Closure:** Central
d) **Calcium-** none e) **Eccentricity Index** 1 f) **Vegetation-** none
g) **Valve Structure :** Trileaflet

3. PULMONARY VALVE STUDY Normal

a) **EF Slope** Normal b) **A Wave +**
c) **Thickness** Normal d) **Others -**

4. TRICUSPID VALVE Normal.

6. AORTIC MITRAL CONTINUITY: maintained

Left Atrium 2.9x2.8cm. Clot : none Others:
Right Atrium Normal Clot none I.A.S.: intact

(Cont2)

(...2)

VENTRICLES

RIGHT VENTRICLE:	Normal	Ejection fraction: 71%
LEFT VENTRICLE :		Fractional Shortening 40%
IVS (D) 0.9cm.(S)	1.2 cm.	LV mass:116g
LVID(D) 4.17cm.(S)	2.50cm.	
PW (D) 0.8cm (S)	1.3 cm	
RWMA: None		
IVS: Intact		

TOMOGRAPHIC VIEWS

PARASTERNAL LONG AXIS VIEW:
Normal
Good LV contractility

SHORT AXIS VIEWS:

Aortic Valve Level	AOV- Normal MV-Normal PV-Normal TV-Normal
Mitral Valve Level	
Papillary Muscle Level:	

APICAL 4 CHAMBER VIEW No clot / vegetation
OTHER SPECIAL VIEWS:

(Cont.....3)


(.....3)

PERICARDIUM
Normal
DOPPLER STUDIES

	Velocity (m/ sec)	Flow Pattern	Regurgitation	Gradient mmHg
MITRAL	E=0.71;A=0.77 E/A=0.9	Normal	Nil	-
AORTIC	1.3	Normal	Nil	7.3
TRICUSPID	1.3	Normal	Trace	7.2
PULMONARY	0.8	Normal	Nil	2.9

CONCLUSIONS:

- No RWMA
- LVEF = 65%
- Trace TR
- IAS/IVS intact
- No MR/AR
- No clot / vegetation.
- No pericardial effusion.
- No Diastolic Dysfunction


DR. S. VAJPAYEE
MD, DIP. (CARD)

Licensee: TECHNO MEDICALS INDIA

GST : 09ADNPA2038G1ZS
Address : TECHNO HERITAGE, Jehangirabad Palace,
Next to DM Residence, 12, Rani Laxmi Bai Marg,
Hazratganj, Lucknow 226001

Online appointments : www.apolloclinic.com
Email : hazratganj.lko@apolloclinic.com

TO BOOK AN APPOINTMENT



NAME : MRS. MAMTA SHUKLA
DATE : 08.APRIL.2023
REFERRED BY : ARCOFEMI HEALTHCARE LTD

RTN : 4100
AGE : 46 Y
SEX : F

ULTRASOUND OF WHOLE ABDOMEN


- **LIVER:** is normal in size (14.8 cms) with normal shape & **increased echogenicity**. Biliary radicals are not dilated. No obvious focal lesion. Portal & hepatic veins are normal in caliber.
- **GALL BLADDER:** is partially distended. Wall thickness is normal. No pericholecystic fluid collection noted. CBD is not dilated.
- **PANCREAS:** is normal in size and contour. Parenchyma shows normal echotexture. No pancreatic duct dilatation is seen. No peri-pancreatic fluid collection seen.
- **SPLEEN:** is normal in size (9.6 cms), shape & position. Parenchyma shows normal echotexture. Splenic veins are not dilated.
- **B/L KIDNEYS:**
 - Both kidneys are normal in size, site, shape, position. Cortical echoes are normal. Cortico-medullary differentiation is maintained. Pelvicalyceal system are not dilated. No obvious calculus / mass / cyst seen.
- **URINARY BLADDER:** is well distended with normal contour. Wall appears regular. No evidence of any calculus /mass lesion is seen.
- **Uterus:** It is anteverted with bulky in size measuring 104x62x50 mm. Myometrial & endometrial echoes are normal. Endometrial stripe measures 7.2 mm is normal. No obvious fluid collection seen with in endometrial canal. **Well defined hypoechoic lesion of size approx. 18x16x10 mm is seen in posterior uterine wall s/o Fibroid.** Cervix appears normal.
- **RIGHT OVARY:** is normal in size, shape and echotexture.
- **LEFT OVARY:** is normal in size, shape and echotexture & **shows dominant follicle measuring approx. 23x19 mm in size.**
- No fluid in POD.

IMPRESSION:

- **GRADE I FATTY LIVER.**
- **BULKY UTERUS WITH UTERINE FIBROID.**

ADV: Please correlate clinically

Typed by
Poonam Tiwari


Dr. Priyank K.S. Chaudhary
MBBS, DMRD, DNB(Radiodiagnosis)

Note:- discrepancies due to technical or typing errors should be reported for correction for seven days. No compensation liability stands.

Licensee: TECHNO MEDICALS INDIA

GST : 09ADNPA2038G1Z5
 Address : TECHNO HERITAGE, Jehangirabad Palace,
 Next to DM Residence, 12, Rani Laxmi Bai Marg,
 Hazratganj, Lucknow 226001

Online appointments : www.apolloclinic.com
 Email : hazratganj.lko@apolloclinic.com

TO BOOK AN APPOINTMENT

 **7897 123 777**

NAME	: MRS. MAMTA SHUKLA	RT NO	: 4166
DATE	: 08.APRIL.2023	AGE	: 46 Y
REFERRED BY	: ARCOFEMI HEALTHCARE LTD	SEX	: F


SONOMAMMOGRAPHY OF BOTH BREASTS

- **Few subcentimetric simple cysts are noted in left breast.**
- Bilateral breast parenchyma shows normal echotexture in all quadrants. No evidence of architectural distortion seen.
- Retroareolar region appears normal.
- No evidence of any dilated ducts noted.
- No soft tissue edema.
- No axillary lymphadenopathy

IMPRESSION:

➤ **LEFT BREAST SUBCENTIMETRIC SIMPLE CYSTS (BIRADS 2).**

ADV: Please correlate clinically and with other investigations


Dr. Priyank Ks Chaudhary
MBBS, DMRD (Radiodiagnosis)
Reg. No. - 70108

Typed by
Poonam Tiwari

Dr. Priyank K.S. Chaudhary
MBBS, DMRD, DNB(Radiodiagnosis)

Note:- discrepancies due to technical or typing errors should be reported for correction for seven days. No compensation liability stands.

Licensee: TECHNO MEDICALS INDIA

GST : 09ADNPA2038G1Z5
Address : TECHNO HERITAGE, Jehangirabad Palace,
Next to DM Residence, 12, Rani Laxmi Bai Marg,
Hazratganj, Lucknow 226001

Online appointments : www.apolloclinic.com
Email : hazratganj.lko@apolloclinic.com

TO BOOK AN APPOINTMENT

 **7897 123 777**

Report Doc No.: **5132**

Patient No.: **3936-3926**

Name : **Mrs. Mamta Shukla / 46 Year / Female**

Collected On : **08-04-2023**

Referred By : **ARCOFEMI MEDIWHEEL**

Report On: **08-04-2023 04:07 PM**

ARCOFEMI MEDIWHEEL FEMALE HEALTH PACKAGE

CBC (Complete Blood Count)

Hemoglobin Method : (Cyanmethemoglobin)	13.2 gm%	Normal 12-15 gm%
Hematocrit (PCV) Method : (Calculated parameter)	36.9 %	Normal 36-45 %
RBC Count Method : (Electrical Impedence)	4.14 million/cmm	Normal 3.7-5 million/cmm
MCV Method : (Calculated parameter)	89.1 fl	Normal 83-101 fl
MCH Method : (Calculated parameter)	31.9 pg	Normal 27-32 pg
MCHC Method : (Calculated parameter)	35.8 g/dl	Normal 31-37 g/dl
RDW-CV Method : (Electrical Impedence)	14.4 %	Normal 11.6-14 %
TLC (Total Leucocyte Count) Method : (Electrical Impedence)	8300 cells/cu.mm	Normal 4000-10000 cells/cu.mm
DLC (Differential Leucocyte Count) Method : (Electrical Impedence)		
Neutrophil	62 %	40-80
Lymphocyte	34 %	20-40
Eosinophil	01 %	1-6
Monocyte	03 %	2-10
Basophil	00 %	0-1
ABSOLUTE LEUCOCYTE COUNT Method : (Electrical Impedence)		
NEUTROPHILS	5146 cells/cu.mm	2000-7000
LYMPHOCYTES	2822 cells/cu.mm	1000-3000
EOSINOPHILS	83 cells/cu.mm	20-500
MONOCYTES	249 cells/cu.mm	200-1000
Platelet Count Method : (Electrical Impedence)	284 thousand/mm ³	Normal 150-450 thousand/mm ³

GBP (Peripheral Blood smear)
RBC : Normocytic normochromic

WBC : Total leucocyte count is within normal limit with normal distribution of cells

Platelets : Platelets are adequate in number.

No hemoparasite or immature cells seen .

Checked By

Licence: TECHNO MEDICALS INDIA

GST : 09ADNPA2038G1Z5

Address : TECHNO HERITAGE, Jehangirabad Palace,
Next to DM Residence, 12, Rani Laxmi Bai Marg,
Hazratganj, Lucknow 226001

Online appointments : www.apolloclinic.com
Email : hazratganj.lko@apolloclinic.com

Page 1 End

TO BOOK AN APPOINTMENT



Report Doc No.: **5132**

Name : **Mrs. Mamta Shukla / 46 Year / Female**

Referred By : **ARCOFEMI MEDIWHEEL**

Patient No.: **3936-3926**

Collected On : **08-04-2023**

Report On: **08-04-2023 04:07 PM**

ESR (Wintrobs) 12 mm/h Normal 0-20 mm/h

Blood Grouping/ABO RH Typing

Blood Group : **"B"**

Rh Factor : **POSITIVE**

Blood Sugar (Fasting) 81 mg/dl Normal 70-110 mg/dl
Method : (GOD-POD)

Blood Sugar (PP) 112 mg/dl Normal 80-160 mg/dl
Method : (GOD-POD)

Checked By 

Page 2 End

Licensee: TECHNO MEDICALS INDIA

GST : 09ADNPA2038G1ZS

Address : TECHNO HERITAGE, Jehangirabad Palace,
Next to DM Residence, 12, Rani Laxmi Bai Marg,
Hazratganj, Lucknow 226001

Online appointments : www.apolloclinic.com

Email : hazratganj.lko@apolloclinic.com

TO BOOK AN APPOINTMENT



Report Doc No.: 5132

Name : Mrs. Mamta Shukla / 46 Year / Female

Referred By : ARCOFEMI MEDIWHEEL

Patient No.: 3936-3926

Collected On : 08-04-2023

Report On: 08-04-2023 04:07 PM

Kidney Function Test (KFT)

Serum Urea Method : (UREASE)	22 mg/dl	Normal 10-50 mg/dl
Serum Creatinine Method : (Creatinine amidohydrolase)	0.6 mg/dl	Normal 0.6-1.4 mg/dl
Serum Sodium Method : (Direct ISE)	140 mmol/L	Normal 135-146 mmol/L
Serum Potassium Method : (Direct ISE)	4.2 mmol/L	Normal 3.5-5.1 mmol/L

Checked By


Page 3 End

Licensee: TECHNO MEDICALS INDIA

GST : 09ADNPA2038G1ZS

Address : TECHNO HERITAGE, Jehangirabad Palace,
Next to DM Residence, 12, Rani Laxmi Bai Marg,
Hazratganj, Lucknow 226001

Online appointments : www.apolloclinic.com

Email : hazratganj.lko@apolloclinic.com

TO BOOK AN APPOINTMENT



Report Doc No.: **5132**
Name : **Mrs. Mamta Shukla / 46 Year / Female**
Referred By : **ARCOFEMI MEDIWHEEL**

Patient No.: **3936-3926**
Collected On : **08-04-2023**
Report On: **08-04-2023 04:07 PM**

Liver Function Test (LFT)

Serum Bilirubin - Total Method : <i>(Diazo sulfanilic)</i>	0.5 mg/dl	Normal 0.2-1.2 mg/dl
Serum Bilirubin - Direct Method : <i>(Diazo sulfanilic)</i>	0.2 mg/dl	Normal 0-0.3 mg/dl
Serum Bilirubin-Indirect Method : <i>(Calculated parameter)</i>	0.3 mg/dl	Normal 0.3-1 mg/dl
Serum SGOT/AST Method : <i>(UV with P-5-P)</i>	20 U/L	Normal 10-46 U/L
Serum SGPT/ALT Method : <i>(UV with P-5-P)</i>	24 U/L	Normal 10-49 U/L
Serum Alkaline Phosphatase (SALP) Method : <i>(p-nitrophenyl phosphate)</i>	91 U/L	Normal 35-104 U/L
Serum Gamma-Glutamyltransferase (GGT) Method : <i>(IFCC)</i>	28 U/L	Normal 0-38 U/L

Checked By

Page 4 End

Licensee: TECHNO MEDICALS INDIA

GST : 09ADNPA2038G1ZS
Address : TECHNO HERITAGE, Jehangirabad Palace,
Next to DM Residence, 12, Rani Laxmi Bai Marg,
Hazratganj, Lucknow 226001

Online appointments : www.apolloclinic.com
Email : hazratganj.jko@apolloclinic.com

TO BOOK AN APPOINTMENT



Report Doc No.: 5132

Name : Mrs. Mamta Shukla / 46 Year / Female

Referred By : ARCOFEMI MEDIWHEEL

Lipid Profile

Serum Cholesterol -Total Method : <i>(CHE/CHO/POD)</i>	181 mg/dl	Normal < 200
Serum Triglyceride Method : <i>(Enzymatic)</i>	206 mg/dl	Normal < 150
Serum Cholesterol VLDL Method : <i>(Calculated parameter)</i>	41 mg/dl	Normal < 30
Serum Choleterol HDL Method : <i>(Polymer-Detergent)</i>	39 mg/dl	Normal > 40
Serum Cholesterol LDL Method : <i>(Calculated parameter)</i>	101 mg/dl	Normal < 100
Total Cholesterol/HDL Ratio Method : <i>(Calculated parameter)</i>	4.64	Normal 0-4.5
LDL/HDL Ratio Method : <i>(Calculated parameter)</i>	3.51	Normal 0-3

Checked By

Page 5 End

Report Doc No.: 5132
Name : Mrs. Mamta Shukla / 46 Year / Female
Referred By : ARCOFEMI MEDIWHEEL

Patient No.: 3936-3926
Collected On : 08-04-2023
Report On: 08-04-2023 04:07 PM

HbA1c

TEST NAME	RESULT	UNIT	BIO. REF. RANGE	METHOD
HBA1C, GLYCATED HEAMOGLOBIN, WHOLE BLOOD EDTA	6.4	%		TURBIDIMETRIC

Comment:

Reference range as per American Diabetes Association (ADA):

REFERENCE GROUP	HBA1C IN %
NON DIABETIC ADULTS > 18 YEARS	<5.7
AT RISK (PREDIABETES)	5.7-6.4
DIAGNOSING DIABETES	≥6.5
DIABETICS	
EXCELENT CONTROL	6-7
FAIR TO GOOD CONTROL	7-8
UNSATISFACTORY CONTROL	8-10
POOR CONTROL	>10

Note: Dietary preparation or fasting is not required.

1. A1C test should be performed at least two times a year in patients who are meeting treatment goals (and who have stable glycemic control).
2. Lowering A1C to below or around 7% has been shown to reduce microvascular and neuropathic complications of type 1 and type 2 diabetes. When mean annual HbA1c is <1.1 times ULN (upper limit of normal), renal and retinal complications are rare, but complications occur in >70% of cases when HbA1c is >1.7 times ULN.
3. Falsely low HbA1c (below 4%) may be observed in patients with clinical conditions that shorten erythrocyte life span or decrease mean erythrocyte age. HbA1c may not accurately reflect glycemic control when clinical conditions that affect erythrocyte survival are present. Fructosamine may be used as an alternate measurement of glycemic control.

Checked By

Page 6 End

Licensee: TECHNO MEDICALS INDIA

GST : 09ADNPA2038G1ZS
Address : TECHNO HERITAGE, Jehangirabad Palace,
Next to DM Residence, 12, Rani Laxmi Bai Marg,
Hazratganj, Lucknow 226001

Online appointments : www.apolloclinic.com
Email : hazratganj.lko@apolloclinic.com

TO BOOK AN APPOINTMENT

 7897 123 777

Report Doc No.: **5132**
Name : **Mrs. Mamta Shukla / 46 Year / Female**
Referred By : **ARCOFEMI MEDIWHEEL**

Patient No.: **3936-3926**
Collected On : **08-04-2023**
Report On: **08-04-2023 04:07 PM**

T3 T4 TSH

Serum T3 Method : <i>(Chemiluminescence Immunoassay)</i>	0.92 ng/ml	Normal 0.7-2 ng/ml
Serum T4 Method : <i>(Chemiluminescence Immunoassay)</i>	10.16 µg/dl	Normal 6.1-12.2 µg/dl
Serum Thyroid Stimulating Hormone (TSH) Method : <i>(Chemiluminescence Immunoassay)</i>	1.31 uIU/ml	Normal 0.3-5.6 uIU/ml

End of Report



Checked By



Dr. Divya Mehdiratta
MBBS, MD (Pathologist)

CONSENT FORM

Patient Name: Mrs. Mamta Age: 26 yrs
UHID Number: _____ Company Name: _____

I ~~Mr~~/Mrs/ Ms: Mamta Shukla Employee of Ascofemi, Medi wheel
(Company) want to inform you that I am not interested in getting _____

Tests done which is a part of my routine health check package.

And I Claim the above statement in my full consciousness.

Patient signature:  Date: _____

PeP smear is not possible because
of menyoational cycle as my
menyoational cycle will completed
I will come for PeP smear test

Licensee: TECHNO MEDICALS INDIA

GST : 09ADNPA2038G1Z5

Address : TECHNO HERITAGE, Jehangirabad Palace,
Next to DM Residence, 12, Rani Laxmi Bai Marg,
Hazratganj, Lucknow 226001

Online appointments : www.apolloclinic.com
Email : hazratganj.lko@apolloclinic.com

TO BOOK AN APPOINTMENT

 **7897 123 777**

Patient Name- Mrs. Mamta Sunkla.	Date- 08/04/23
Age- 46	Sex- F.
B P – Systolic Diastolic	R.B.S.-
Pulse-	SPO2-
Temp-	Height-
Weight-	BMI-
Consultant- Dr. Sanhita Sinha,	Fat-

Routine ENT Check

	R	L
EAC	N.	N.
TMA		
Mastoid	Non tender.	Non tender.
TFT.		
Rinne	AC > BC.	AC > BC.
Weber	Central.	
ABC	SAE.	SAE.
FN	N.	N.
Nystagmus	NO	NO.
Nose	} WNL.	
PNS		
Oral cavity	} WNL.	
oro Rx		

Valid for 7 Days

Mrs Mamta shukla

Age - 46Y/F



C10 - Presbyopic

Vm { 6/6
6/6

Nvm { N24
N24

Cvm { 30/30 } 1/1/1/1

Presbyopic Correction:

* +1.75 DS BE^s { N6
N6

- only for near.

Licensee: TECHNO MEDICALS INDIA

GST : 09ADNPA2038G1Z5

Address : TECHNO HERITAGE, Jehangirabad Palace,
Next to DM Residence, 12, Rani Laxmi Bai Marg,
Hazratganj, Lucknow 226001

Online appointments : www.apolloclinic.com

Email : hazratganj.lko@apolloclinic.com

TO BOOK AN APPOINTMENT



mamta shukla 46/F

c/c - regular dental checkup

o/e - stains +
calculus +.

missing 4. (extraction 1.5 yr back).

Adv - ① oral prophylaxis

② replacement of missing

Dr. Rohit

Dr. ROHIT MADAN
MDS (Periodontist & Oral Implantologist)
Consultant Dentist
DCI Reg. No. 002259
Apollo Clinic, Hazratganj

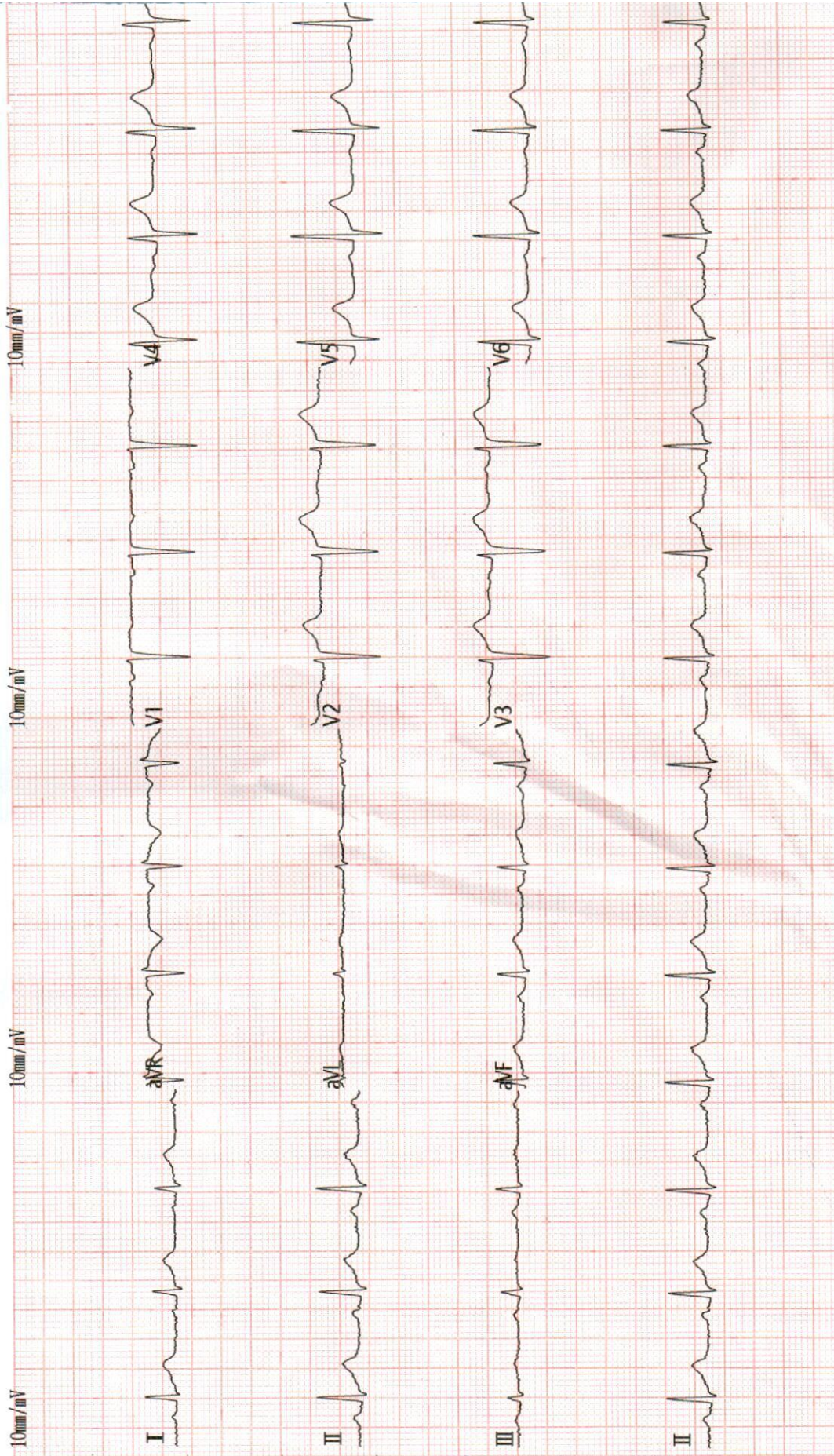
Licensee: TECHNO MEDICALS INDIA

GST : 09ADNPA2038G1ZS
Address : TECHNO HERITAGE, Jehangirabad Palace,
Next to DM Residence, 12, Rani Laxmi Bai Marg,
Hazratganj, Lucknow 226001

Online appointments : www.apolloclinic.com
Email : hazratganj.lko@apolloclinic.com

TO BOOK AN APPOINTMENT

 **7897 123 777**



Vent. Rate(BPM) : 82

PR Int.(ms) : 138
 P/QRS/T Int.(ms) : 96 97 178
 QT/QTc Int.(ms) : 358 421
 P/QRS/T Axis(Deg.) : 44 54 40
 RV1/SV5 Amp.(mV) : 0.06 0.41
 RV5/SV1 Amp.(mV) : 1.01 0.99

<ECG Analysis Result>:

800 Normal Sinus Rhythm
 *** Normal ECG ***

ST LEVEL(mV)

I	II	III	aVR	aVL	aVF
+0.02	+0.04	+0.01	-0.03	+0.00	+0.02
V1	V2	V3	V4	V5	V6
+0.01	+0.07	+0.06	+0.06	+0.05	+0.02

Note : Inconfirmed Report Need to Review.

V2 33 Technician :