

Dr. Siddharth Malaiya

MBBS, MS (Ophthalmology), FLVPEI, Hyd. (Cornea & LASIK)

FBHEC, Australia (Ocular surface & Stem cells)

Fellow L V Prasad Eye Institute, Hyderabad, Ex-Faculty ASG Eye Hospital, Jodhpur

Consultant Ophthalmologist & Cornea Super-specialist

Phaco-refractive & Cornea transplant surgeon



Name: Mr. Rakesh

Age/Sex: 40/M.

Date: 28/9/24

C/o

MHC.

Vision	UCVA	Glasses	Pinhole
RE	6/12 (P)		
LE	6/12 (P)		

AR	R	-0.25 [-1.25 x 90]
	L	-0.25 [-1.75 x 70]

Eye	Sphere	Cylinder	Axis	BCVA
RE	—	-1.00	90	6/6
LE	—	-1.00	70	6/6
Add	+1.00 Dsph —			No (Be)

PG	R	
	L	

Siddharth Malaiya

Dr. Siddharth Malaiya
MS Ophthal, FLVPEI (Cornea), FCOH
(Ocular Surface)
Consultant Ophthalmology & Cornea Specialist
Reg.No. : MP-13858

Apollo Sage Hospital - Bhopal

Regd No. NH/7272/Sept. 2022

(A unit of S. R. Associates)

KH.No. 98/3-99-100, E-8 Arera Colony, Bhopal - 462026 (MP) India



28.09.202 9:49:25

Male

Years

QRS : 86 ms
 QT / QTcBaz : 402 / 402 ms
 PR : 112 ms
 P : 72 ms
 RR / PP : 1002 / 1000 ms
 P / QRS / T : 51 / 59 / 46 degrees

Normal sinus rhythm
 Normal ECG

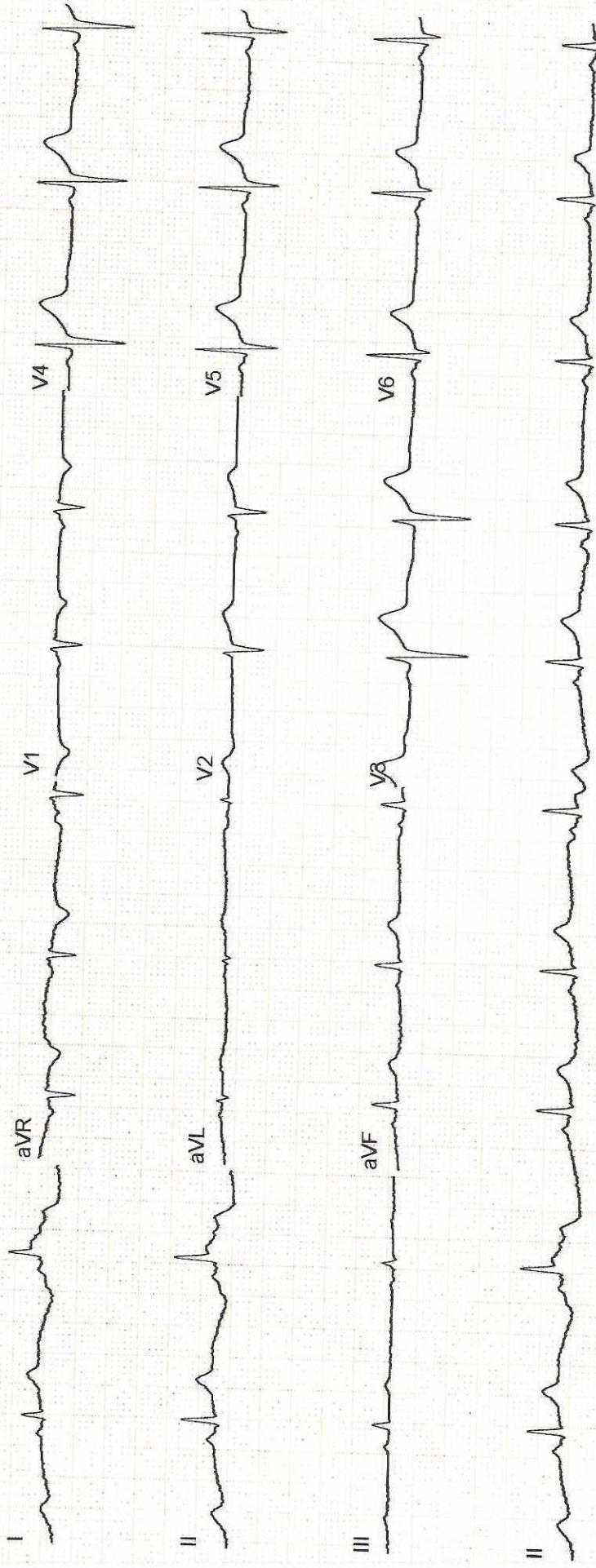
Location: R
 Order Num. 1:
 Indication:
 Medication 1:
 Medication 2:
 Medication 3:

Technician:
 Ordering Ph:
 Referring Ph:
 Attending Ph:

60 bpm

-- / -- mmHg

CE 0537 D 736



Patient's Name	Rakesh Ranjan	Date	28/09/2024
Age/Sex	41Y/M	UHID	HC-50176
Referred By	Health Check Up	Done By	Dr.Gaurav Khandelwal

-Left Ventricle : Normal Left Ventricular Size, Wall Thickness & Function.

-Left Ventricular Ejection Fraction is within Normal Limits (LVEF : 60%)

-Left Atrium : Normal Left Atrial Size & Functions.

-Right Ventricle : Normal Right Ventricular Size & Functions.


-Right Atrium : Normal Right Atrial Size & Function.

-Valvular Structures : Normal Mitral, Tricuspid, Pulmonic & Aortic Valve Structures.

-Aortic Root is Normal.

-No Evidence of Pericardial Effusion.

-No LA / LV Clot


DR. GAURAV KHANDELWAL
DM (Cardiology), FACC, FESC, FSCAI, FIC
INTERVENTIONAL CARDIOLOGIST

Patient Name:	RAKESH RANJAN	Patient ID:	ASHB.0000050176
Age:	41 Years	Sex:	M
Accession Number:	17101.224011117	Modality:	US
Referring Physician:	Akhil Kumar Tiwari	Study:	ULTRASOUND - WHOLE ABDOMEN
Study Date:	28-Sep-2024		

ULTRA SONOGRAPHY ABDOMEN

Liver:- is normal in size and shows mild increase hepatic parenchymal echotexture with preserved peri portal echoes . Portal and hepatic venous system appears normal. Intra and extra hepatic biliary radicals are not dilated.

Gall Bladder:- is normal in size and shape. Its lumen is echofree.

Pancreas is normal in size outline and echopattern.

Spleen is normal in size and echopattern.

Both kidneys are normal in size, shape and echogenicity. Central pelvicalyceal sinus and corticomedullary ratio are normal.

Right kidney measures:- 10.0x3.5cm

Left kidney measures:- 10.3x4.3cm

Urinary bladder is normal in shape and contour. Its wall is normal.


Prostate is borderline enlarged and shows heterogeneous parenchymal echotexture. Estimated volume is- 26cc.

No evidence of ascites is seen.

IMPRESSION:- Sonography Study Reveals:-

- Grade-I fatty liver.
- Borderline prostatomegaly (26cc).

ADV:- Clinical Correlation.



DR. HARI SANTOSH
CONSULTANT RADIOLOGIST



Patient Name:	RAKESH RANJAN	Patient ID:	ASHB.0000050176
Age:	41 Years	Sex:	M
Accession Number:	17101.124016290	Modality:	DX
Referring Physician:	Akhil Kumar Tiwari	Study:	CHEST
Study Date:	28-Sep-2024		

X-RAY CHEST (PA VIEW)

Both lung fields are clear. No active pleural or parenchymal lesion is seen.

The hila, mediastinum, bony thoracic cage and the diaphragmatic domes are normal.

The costophrenic and cardiophrenic angles are clear.

The cardiac silhouette is unremarkable.

IMP:- RADIOGRAPHIC IMAGE REVEALS:-

No significant abnormality detected.

Thanks for Ref



DR. HARI SANTOSH
CONSULTANT RADIOLOGIST

Date: 28-Sep-2024 10:14:48



--

Name : **Mr. RAKESH RANJAN** Age : **41Yr 2Mth 15Days** Gender : **Male**
UHID : ASHB.0000050176 /BPLAH10185 **W/BNo/RefNo:** AHC
SIN \ LRN : 175835 \ 175838 \ 175840 \ 175839 \ 69484
Specimen : Blood
Ref Doctor : Dr. Akhil Kumar Tiwari



ASHB.0000050176

Collected on : 28-SEP-2024 09:09:48 AM Received on : 28-SEP-2024 09:45:49 AM Reported on : 28-SEP-2024 11:26:27 AM

MEDIWHEEL FULL BODY ANNUAL PLUS ABOVE 50 MALE

<u>TEST NAME</u>	<u>RESULT</u>	<u>BIOLOGICAL REFERENCE INTERVALS</u>	<u>UNITS</u>
GLUCOSE - SERUM / PLASMA (FASTING)			
GLUCOSE - PLASMA (FASTING)	96	70-100	mg/dL
GLUCOSE - SERUM / PLASMA (POST PRANDIAL)			
GLUCOSE - PLASMA - (POST PRANDIAL)	104	70-140	mg/dL
GLYCOSYLATED HEMOGLOBIN (HBA1C) - WHOLE BLOOD	5.2	4.0-5.6	%
CHOLESTEROL - SERUM / PLASMA	174	Desirable: <200 Borderline High: 200-239 High >240	mg/dL
HDL CHOLESTEROL - SERUM / PLASMA	52	>40	mg/dL
LDL CHOLESTEROL - SERUM / PLASMA	129 *	Optimal: <100 Above optimal: 100-129 Borderline high: 130-159 High: 160-189 Very high: >190	mg/dL
TRIGLYCERIDES - SERUM / PLASMA	122	Normal<150 Borderline high 150-199	mg/dL

VLDL CHOLESTEROL - SERUM

24

High 200–499
Very high: ≥ 500

Name : **Mr. RAKESH RANJAN** Age : **41Yr 2Mth 15Days** Gender : **Male**
 UHID : ASHB.0000050176 / BPLAH10185 W/BNo/RefNo : AHC
 SIN \LRN : 175836 \ 175841 \ 69484
 Specimen : Urine
 Ref Doctor : Dr. Akhil Kumar Tiwari



Collected on : 28-SEP-2024 09:44:31 AM Received on : 28-SEP-2024 10:01:16 AM Reported on : 28-SEP-2024 11:57:17 AM

MEDIWHEEL FULL BODY ANNUAL PLUS ABOVE 50 MALE

<u>TEST NAME</u>	<u>RESULT</u>	<u>BIOLOGICAL REFERENCE INTERVALS</u>	<u>UNITS</u>
CBC			
HAEMOGLOBIN	13.0	13.0-17.0	g/dL
Packed cell volume (Calculated)	39.3	38.3-48.6	%
RBC COUNT(Impedance)	4.83	4.50-5.90	Million/ul
MCV-	81.4	80-100	fl
MCH-	26.8 *	27-32	pg
MCHC-	33.0	32-36	g/dL
RDW (Derived from RBC histogram)	15.4 *	11.8 - 14.5	%
TLC COUNT	5.56	4.0-11.0	10 ³ /mm ³
DIFFERENTIAL COUNT			
Neutrophils	55	40-80	%
Lymphocytes	37	20-40	%
Monocytes	5	2-10	%
Eosinophils	3	1-6	%
Basophils	0	0-2	%
Platelet Count(Impedance)	171.9	150-450	10 ³ /mm ³
Mean Platelet Volume	10.9	6.5-12.0	fl
ERYTHROCYTE SEDIMENTATION RATE (ESR)	1	0-15	mm/1st hr
URINE ROUTINE (CUE)			
MACROSCOPIC EXAMINATION			
Specific Gravity(Automated – Reflectance Spectrometer)	1.005	1.005 - 1.025	
Colour:(Naked Eye Examination)	Pale-Yellow		

Name : **Mr. RAKESH RANJAN** Age : **41Yr 2Mth 15Days** Gender : **Male**
 UHID : ASHB.0000050176 / BPLAH10185 W/BNo/RefNo : AHC
 SIN \LRN : 175836 \ 175841 \ 69484
 Specimen : Urine
 Ref Doctor : Dr. Akhil Kumar Tiwari



Collected on : 28-SEP-2024 09:44:31 AM Received on : 28-SEP-2024 10:01:16 AM Reported on : 28-SEP-2024 11:57:17 AM

Transparency:(Naked Eye Examination)	Clear		
pH(Automated – Reflectance Spectrometer)	Acidic		
Protein :(Automated – Reflectance Spectrometer/Sulpho salicylic acid method)	Nil		
Sugar:(Automated - Reflectance Spectrometer/ Benedict's Test)	Nil		
Ketone(Automated – Reflectance Spectrometer/Rothera's test)	Nil		
Bilirubin: (Automated – Reflectance Spectrometer/Fouchet's method)	Nil		
Cells:			
RBC(Automated - Reflectance spectrometer/Microscopy/Flow cytometric)	Nil		
Pus Cells(Automated – Reflectance spectrometer/Microscopy/Flow cytometric)	1-2	0.0 - 5.0/HPF	/hpf
Epithelial Cells(Microscopic /Flow cytometric)	1-2	<20	/hpf
Yeast Cells	Absent		
Bacteria:	Absent		
Casts:(Microscopic /Flow cytometric)	Absent	ABSENT	
Crystals:(Microscopic /Flow cytometric)	Absent		

Name : **Mr. RAKESH RANJAN** Age : **41Yr 2Mth 15Days** Gender : **Male**
UHID : ASHB.0000050176 / BPLAH10185 W/BNo/RefNo : AHC
SIN \LRN : 175836 \ 175841 \ 69484
Specimen : Urine
Ref Doctor : Dr. Akhil Kumar Tiwari



Collected on : 28-SEP-2024 09:44:31 AM Received on : 28-SEP-2024 10:01:16 AM Reported on : 28-SEP-2024 11:57:17 AM

Report Status:Final

* END OF REPORT *

CHECKED BY : 154491
727938

A handwritten signature in black ink, appearing to read 'Dr. Shubhra Prasad', written over a light blue rectangular background.

Dr. Shubhra Prasad
Consultant Pathologist

Printed On : 30-SEP-2024 11:25:29 AM

Name : **Mr. RAKESH RANJAN** Age : **41Yr 2Mth 15Days** Gender : **Male**
UHID : ASHB.0000050176 / BPLAH10185 W/BNo/RefNo : AHC
SIN \LRN : 175837 \ 69484
Specimen : Blood
Ref Doctor : Dr. Akhil Kumar Tiwari



Collected on : 28-SEP-2024 09:09:48 AM Received on : 28-SEP-2024 09:44:18 AM Reported on : 28-SEP-2024 10:30:20 AM

MEDIWHEEL FULL BODY ANNUAL PLUS ABOVE 50 MALE

<u>TEST NAME</u>	<u>RESULT</u>
------------------	---------------

BLOOD GROUPING AND TYPING (ABO and Rh)

ABO Group:	B
Rh (D) Type:	Positive

Report Status:Final

* END OF REPORT *

CHECKED BY : 154612
725449

A handwritten signature in blue ink, appearing to read 'Dr. Samir Singh'.

Dr. Samir Singh
Consultant Blood Bank

Printed On : 30-SEP-2024 11:25:56 AM