



LAB REPORT

Reg. Date	23/12/2023	Patient Id	2312230012	DOB.	
Name	MRS. ANKITA VERMA	Gender	F	Perm. ID	
Age	35 Yrs.	Panel	MEDIWHEEL	Reported	24/12/2023 12:09:10
Ref. By	MEDIWHEEL				

Test Name	Result	Units	Ref. Range
MEDIWHEEL ANNUAL PLUS CHECK			
HBA1C	5.0	%	

Interpretation

Non Diabetic	: 4-6%
Good Diabetic Control	: 6-8%
Fair Control	: 8-10%
Poor Control	: >10%

The Glycosylated haemoglobin assay has been validated as a reliable indicator Of mean blood glucose levels for a period of 8-12 week period. ADA recommended the testing twice a year in patients with stable blood glucose and quarterly. If treatment change, or if blood glucose levels are unstable.

TO BE CORRELATED CLINICALLY.

Dr. *Reema Dahiya*
DR. REEMA DAHIYA
 M.B.B.S, MD (Path.)
 Checked by: *Meenu Aggarwal*
 Malik Radix Healthcare
 C-217, C-218, Vikas Marg, Nirman Vihar, New Delhi-110092

DR. MEENU AGGARWAL
 M.B.B.S, MD (Path.)

If test results are alarming or unexpected, patient is advised to contact the laboratory immediately for possible remedial action.

Facilities Available

- Multispeciality Hospital - 24 Hours Emergency - X-Ray/ ECG/ Ultrasound/ CT-Scan - Dental- Fully Equipped Operation Theatre
 - Fully Functional Lab - 24/7 Casualty/ ICU-Nursery 24/7 Pharmacy - Labour Room - All Speciality OPD - Laproscopic Surgery -
 ECHO - Plastic Surgery



LAB REPORT

UHID	PT203438	LAB No.	LAB2324358
Name	Mrs. ANKITA VERMA	Regn. No.	GEN2332932
Father's/Husb Name	W/O	Receiving Dt/Time	23/Dec/2023 11:00 AM
Age/Sex	35 Yrs/F	Reporting Dt/Time	27/Dec/2023 12:15 PM



CYTOLOGY

PAP SMEAR

CYTOPATHOLOGY REPORT

2001 BETHESDA SYSTEM

SPECIMEN: CERVICOVAGINAL SMEAR.

SPECIMEN ADEQUACY:

Smear is satisfactory for evaluation. Smear shows squamous cells and endocervical cells. Background shows normal flora with mild neutrophilic infiltrate.

INTERPRETATION:

Negative for intra-epithelial lesion and malignancy .

IMPRESSION:

Mildly inflammatory Smear.

DISCLAIMER:

It is a screening procedure subject to both false negative or false Positive.
Result must be interpreted in context of historic and current Clinical information
in case of any mismatch biopsy and HPE may be considered.

Dr.Reema Dahiya
M.B.B.S, MD(PATH)
CONSULTANT PATHOLOGY
DMC/994/25

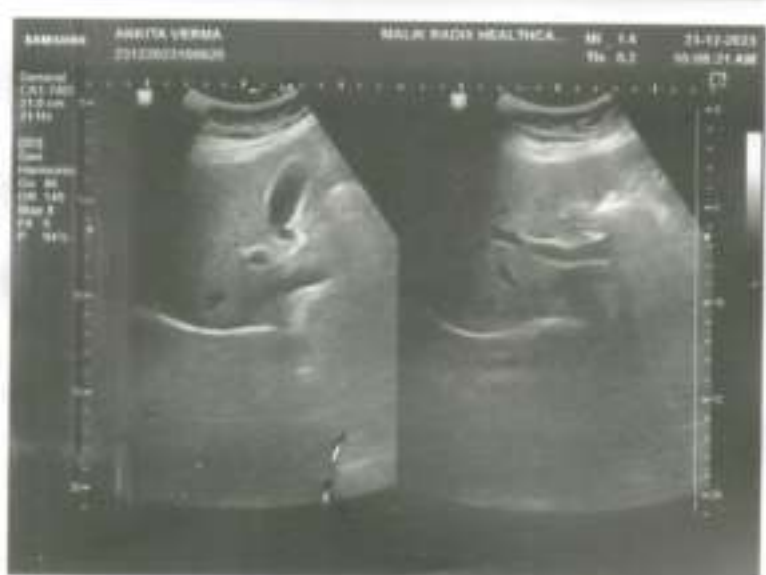
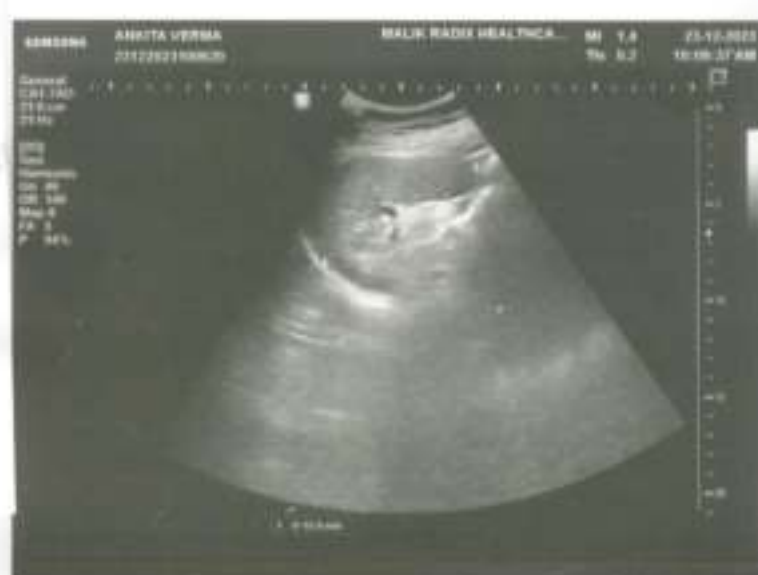
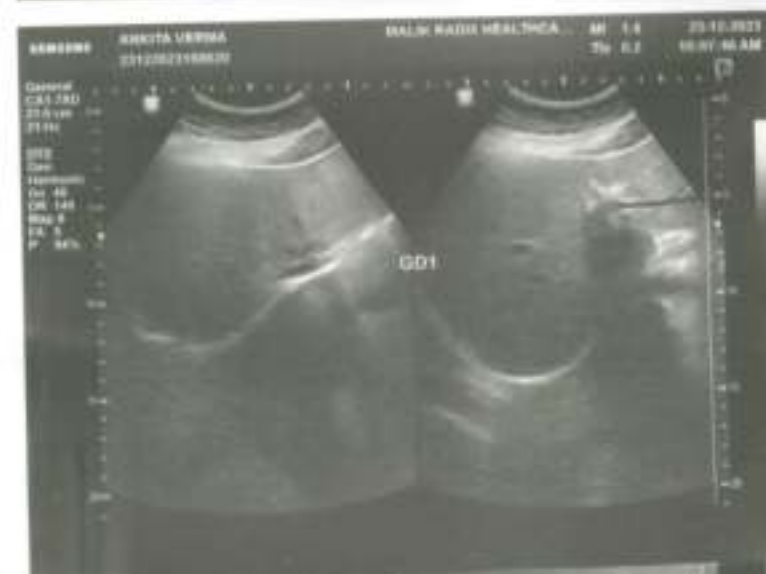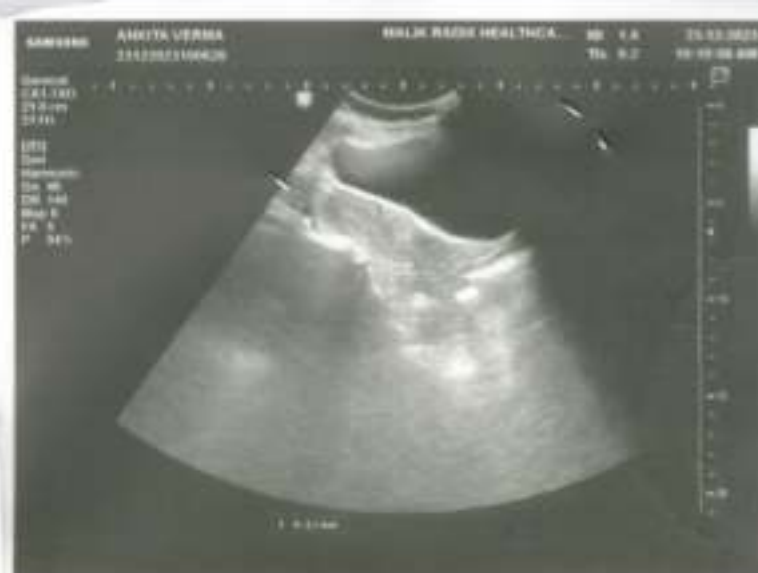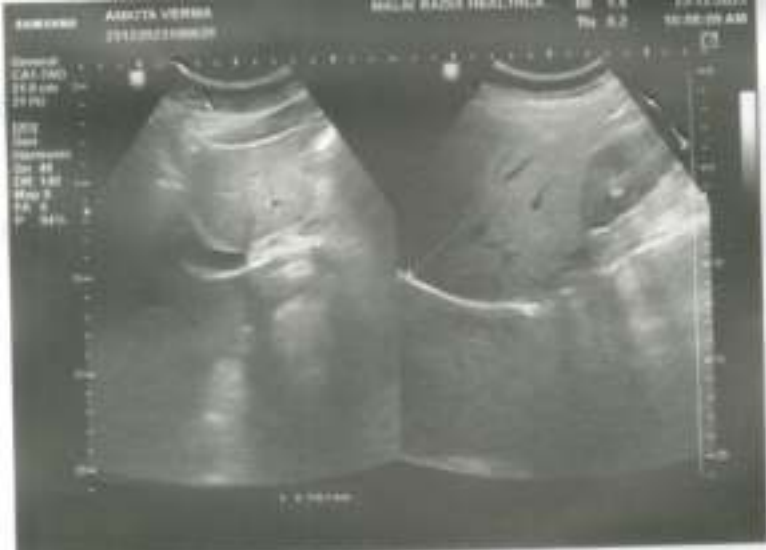The Test are not conducted under NABL scope.

Page 1 of 2

If test results are alarming or unexpected, patient is advised to contact the laboratory immediately for possible remedial action.

Facilities Available

- Multispeciality Hospital - 24 Hours Emergency - X-Ray/ ECG/ Ultrasound/ CT Scan - Dental- Fully Equipped Operation Theatre
- Fully Functional Lab - 24/7 Casualty/ ICU-Nursery 24/7 Pharmacy - Labour Room - All Speciality OPD - Laproscopic Surgery -
ECHO - Plastic Surgery





NAME	MRS ANKITA VERMA	AGE	35 Y/F
REFD. BY.	HEALTH CHECK UP	DATE	23.12.23

Ultrasound Examination of Whole Abdomen & Pelvis:

Liver: Liver is normal in size (13.9 cm) with normal outlines and shows increased parenchymal echotexture. No focal lesion is seen. IHBR & portal radicles are normal.

Gallbladder: Gallbladder is well distended. No evidence of cholecystitis or cholelithiasis seen. Common bile duct is normal in course & caliber.

Pancreas: Pancreas shows normal size, outlines & echotexture. No focal lesion is seen. MPD is not dilated.

Spleen: Spleen shows normal size (9.3 cm), outline & echotexture.

Kidneys: Kidneys show normal size, shape, position & echotexture. No calculus/ hydronephrosis or SOL is seen in left kidney. A calculus measuring about 9.7 mm noted at upper pole of right kidney. Cortico-medullary differentiation and cortical thickness is normal on both sides.

Right kidney measures --8.9 x 3.7 cm

Left kidney measures --9.6 X 4.6 cm

Great abdominal vessels are normal.

No ascites seen.

No para-aortic lymph nodes seen.

Urinary bladder: Urinary bladder is well distended. Walls and lumen appear normal.

Uterus is normal in size outline and echotexture. No focal lesion is seen. Endometrium is central and measures 4.7 mm. Cervix appears normal.

Both adnexa appear unremarkable.

IMPRESSION:

Grade I Fatty Liver

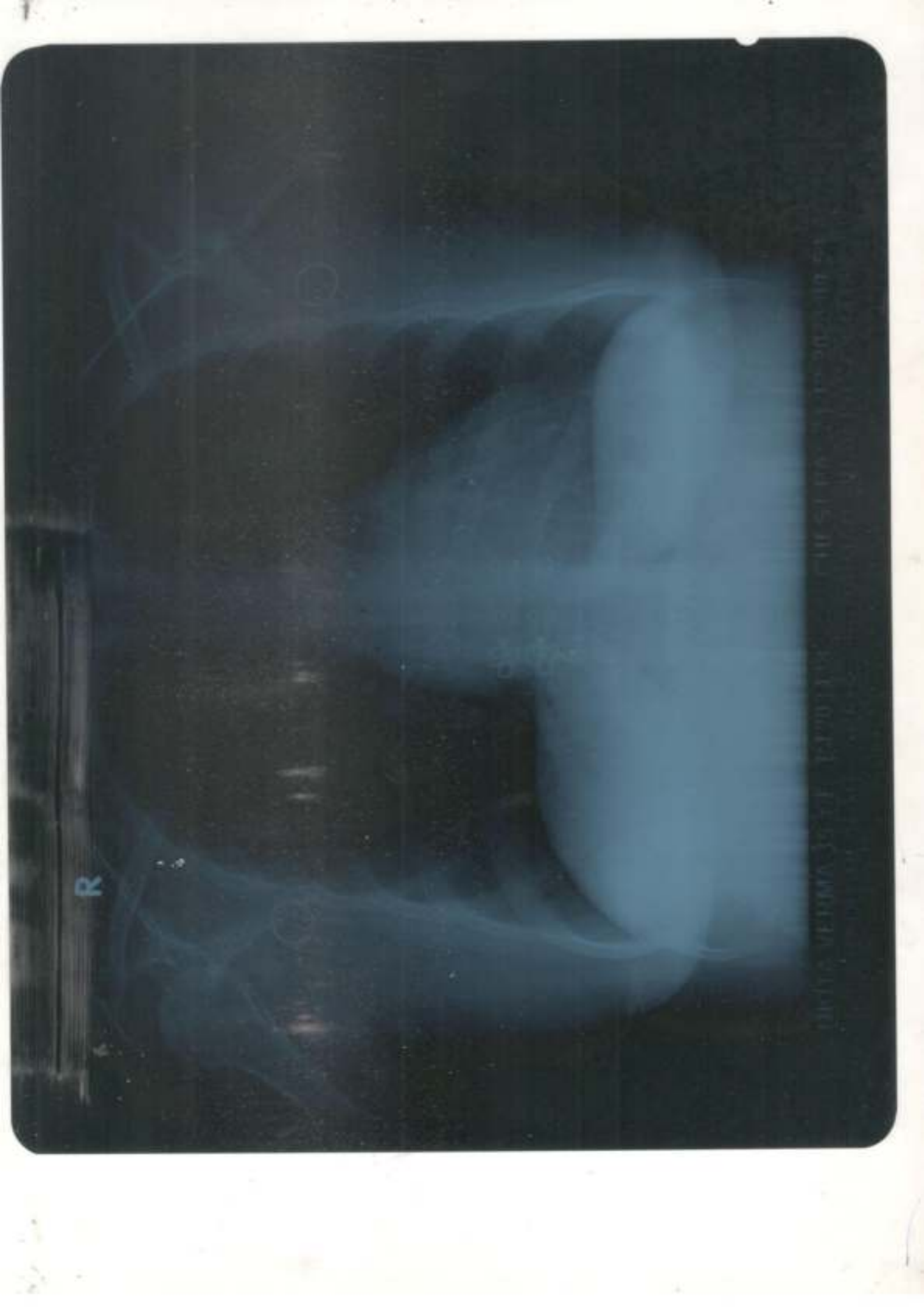Right renal calculus

Dr Shreyash Tiwary MD (Rad- diag)

Regn. No. DMC 85802

RADIOLOGIST :

Facilities Available





UHID	PT203438	LAB No.	XRY2308090
Name	Mrs. ANKITA VERMA	Regn. No.	GEN2332830
Age / Sex	35 Yrs / F	Receiving Dt/Time	23-Dec-2023 09:54
		Reporting Dt/Time	23-Dec-2023 11:33 AM



XRAY

CHEST (PA)

Both lung fields are normal.

Cp angles are clear.

Hila are normal...

Heart size appears within normal limits.

Soft tissue shadows and bony thorax are normal.

IMP- NORMAL CHEST X-RAY

Advised... please correlate clinically.

***** END OF REPORT *****


DR. K.K. SINGH
M.B.B.S. D.M.R.D.
SENIOR CONSULTANT
Reg. No. 25437 (DMC)

DR. RAJESH MALHOTRA
MBBS, MD (RADIOLOGY)
CONSULTANT RADIOLOGY
Reg.No.DMC9299

DR. T. K. VOHRA
MD (RADIOLOGY)
SENIOR CONSULTANT
Reg. No. 3272 (DMC)

DR. MUKESH KOSHAL
MBBS, MD (RADIOLOGY)
CONSULTANT RADIOLOGY
Reg.No.DMC10407

DR. SHREYASH TIWARY
MBBS, MD (RADIOLOGY)
CONSULTANT RADIOLOGY
Reg.No.DMC85802

Facilities Available

Multispecialty Hospital - 24 Hours Emergency - X-Ray/ ECG/ Ultrasound/ CT Scan - Dental - Fully Equipped Operation Theatre
- Fully Functional Lab - 24/7 Casualty/ ICU-Nursery 24/7 Pharmacy - Labour Room - All Speciality OPD - Laproscopic Surgery -
ECHO - Plastic Surgery



Echocardiogram Report

Patient Name	MRS. ANKITA VERMA
Date of Test	23/12/2023
Age	35 YRS/ FEMALE
Ref. by	MEDIWHEEL

Dimensions	Result	Normal Range
AO (ed)	2.1 cm	(2.1 -3.7cm)
LA (es)	2.4 cm	(2.1 -3.7cm)
RVID (ed)	1.9 cm	(1.1-3.0cm)
LVID (ed)	3.5 cm	(3.6 – 5.5 cm)
LVID (es)	2.4 cm	(2.3-3.9cm)
IVS (ed)	1.1 cm	(0.6 – 1-2 cm)
LVPW (ed)	0.8 cm	(0.6 – 1-2 cm)
EF	60 %	
FS	30 %	(28 % - 42 %)

Impression:

- NO REGIONAL WALL MOTION ABNORMALITY SEEN
- LVEF= 60 %
- NORMAL CHAMBER DIMENSIONS.
- STAGE I LV DIASTOLIC DYSFUCTION.
- NORMAL COLOR FLOW.
- NO INTRA CARDIAC CLOT/MASS/ VEGETATION/PERICARDIAL EFFUSION SEEN.

Dr. Sheikh Nazir Ahmed
 M.D. "Physician" PGDCC
 (Consultant Non – Invasive Cardiologist)

Facilities Available

- Multispecialty Hospital - 24 Hours Emergency - X-Ray/ ECG/ Ultrasound/ CT Scan - Dental - Fully Equipped Operation Theatre
 - Fully Functional Lab - 24/7 Casualty/ ICU-Nursery 24/7 Pharmacy - Labour Room - All Speciality OPD - Laproscopic Surgery -
 ECHO - Plastic Surgery



भारत सरकार

Unique Identification Authority of India

Government of India

समांकन क्रम / Enrollment No.: 2020/34010/00723

To
अंकिता वर्मा
ANKITA VERMA
850
TULSI NAGAR
Orai
Orai
Orai Jalaun
Uttar Pradesh 285001
9450296609

17/01/2014

10A010745



ML040197456FT



आपका आधार क्रमांक / Your Aadhaar No. :

3103 6393 3091

आधार - आम आदमी का अधिकार



भारत सरकार

Government of India



अंकिता वर्मा
ANKITA VERMA
पिता : शेट अरुण कुमार वर्मा
Father: Sh. Arun Kumar Verma
जन्म तिथि / DOB: 18/07/1988
लिंग / Gender: महिला / Female



3103 6393 3091

आधार - आम आदमी का अधिकार

Handwritten signature

MALIK RADIX HEALTH CARE PVT. LTD.
C-217, C-218, Nirman Vihar,
Delhi-110092
Ph.: 011-49287458, 011-61381379
Regd. No. 607



PHYSICAL EXAMINATION REPORT

NAME: Mrs. Ankita
Verma.

AGE/GENDER: 35yr/Female DATE 23/12/23

HEIGHT	140cm
WEIGHT	51kg
BMI	26.0
BLOOD PRESSURE	130/80
OTHER	NAD Physically Fit & Healthy

MALIK RADIX HEALTH CARE PVT. LTD.
C-217, C-218, Nirman Vihar,
Delhi-110092
Ph.: 011-49287450, 011-61381379
Regd. No. 807

Dr. SHEIKH HAZIR AHMED
M.D. "Physician"
PGDCC
DMC-46499

Facilities Available

- Multispeciality Hospital - 24 Hours Emergency - X-Ray/ ECG/ Ultrasound/ CT Scan - Dental - Fully Equipped Operation Theatre
- Fully Functional Lab - 24/7 Casualty/ ICU-Nursery 24/7 Pharmacy - Labour Room - All Speciality OPD - Laproscopic Surgery -
ECHO - Plastic Surgery



Mrs. Ankita Verma
Age - 35yr / F

23/12/23

Very 6/6 ~~2/3~~
i 6/6 ~~2/3~~
glass

Refractive chart

near U Mo
Hb

Colour U: normal

T - < 14
14


Dr. Nidhi Gupta
MBBS, MS, DNB
Casualty Ophthalmologist
Malik Radix Healthcare Pvt. Ltd.
DMC No. 121661

Facilities Available

- Multispecialty Hospital - 24 Hours Emergency - X-Ray/ ECG/ Ultrasound/ CT Scan - Dental - Fully Equipped Operation Theatre
- Fully Functional Lab - 24/7 Casualty/ ICU-Nursery 24/7 Pharmacy - Labour Room - All Speciality OPD - Laproscopic Surgery - ECHO - Plastic Surgery



CONSULTANTS ON PANEL

- PAEDIATRICS**
Dr. Ravi Malik (MBBS, MD)
Dr. Harit Prasad (MBBS, MS, PNH)
Dr. Ritu Jain (MBBS, MD)
- Gynaecology**
Dr. Renu Malik (MBBS, MD)
Dr. Meenu Mahotra (MBBS, MD)
Dr. Ravi (MBBS, MD)
Dr. Manu Gupta (MBBS, MS)
Dr. Vanshika Sam (MBBS, DGO)
Dr. Rupam Arora (MBBS, MD)
- DENTAL**
Dr. Shruti Malik (BDS, MDS)
Dr. Annu Sam (BDS, MDS)
Dr. Rachit Thakral (BDS, MDS)
Dr. Mohit Mangla (BDS, MDS)
Dr. Tanu Mittal (BDS, MDS)
Dr. Geetika Sharma (BDS)
Dr. Shilpa Verma (BDS)
- CHILD GASTROENTEROLOGY**
Dr. S. K. Mittal (MBBS, MD)
- MEDICINE**
Dr. A. S. Talwar (MBBS, MD)
Dr. Sunny Uppal (MBBS, MD)
Dr. Sunehra Rajpal (MBBS, MD)
- RESPIRATORY MEDICINE/PULMONOLOGY**
Dr. Abhinav Shrivastava (MBBS, DNB)
- LAPAROSCOPIC SURGERY**
Dr. Ajay Jain (MBBS, MS)
Dr. Deepak Sarin (MBBS, MS)
Dr. Praveen Sarin (MBBS, MS)
Dr. S. S. Gang (MBBS, MS)
- ORTHOPAEDICS**
Dr. Vikas Shrivastava (MBBS, MS, DOrtho, DNB)
Dr. Prabhakar Aggarwal (MBBS, MS, DOrtho)
Dr. K. S. Tiwari (MBBS, MS, DOrtho)
Dr. Deepak Kumar Arora (MBBS, MS, DOrtho)
- EYE/OPTHALMOLOGY**
Dr. Neetu Gupta (MBBS, MS, DNB, PGDM)
Dr. Himanshu Singh Pandey (MBBS, MS)
- ENT**
Dr. Sharan Kumar Singh (MBBS, MS)
Dr. Praveen Sharma (MBBS, MS)
Dr. Ashok Singh (MBBS, MS)
Dr. A. K. Lather (MBBS, MS)
- RADIOLOGY/ULTRASOUND**
Dr. A. K. Sinha (MBBS, DNB)
Dr. T. K. Vohra (MBBS, MS)
Dr. Rakesh Mahotra (MBBS, MD)
Dr. Ashish Tomar (MBBS, MD)
- PATHOLOGY**
Dr. Neema Dahiya (MBBS, MD, MCh)
Dr. Meenu Aggarwal (MBBS, MD, FRCG)
- ANAESTHESIA**
Dr. Rajesh Dhill (MBBS, MD)
Dr. Rajesh Ahuja (MBBS, MD)
Dr. R. K. Arora (MBBS, MD)
Dr. Suresh Gang (MBBS, MD)
- DERMATOLOGY**
Dr. Niharika Jha (MBBS, MD)
- PLASTIC & COSMETIC SURGERY**
Dr. Praveen Jain (MBBS, MS, MCh)
- PLASTIC SURGERY**
Dr. Dharmendra Singh (MBBS, MS, MCh)
Dr. Sachin Aggarwal (MBBS, MS, MCh)
- PAEDIATRIC NEPHROLOGY**
Dr. A. S. Vasudev (MD, Dip. in Paed.)
- NEPHROLOGY**
Dr. Javed (MBBS, MD, Nephro)
- CARDIOLOGY**
Dr. Nishant Tyagi (MBBS, MD)
- NEUROLOGY**
Dr. Anurag Bhatia (MBBS, MD)
- GASTROENTEROLOGY**
Dr. Deepak Luthi (MBBS, MD)
Dr. Harish Aggarwal (MBBS, MD)
Dr. Anshu Goyal (MBBS, MD)
Dr. Ankur Singhal (MBBS, MD)
- UROLOGY**
Dr. Nishi Sharma (MBBS, MCh)
Dr. Ankur Singhal (MBBS, MD)
- PSYCHIATRY**
Dr. Mohit Sharma (MBBS, MD)
- PHYSIOTHERAPY**
Dr. Karti Dhanraj
Dr. Ravi Kumar
- NUTRITIONIST**
Dr. Deepika Kohli
Dr. Sakshi Rana
- CLINICAL PSYCHOLOGIST**
Dr. Sarika Singh

Dr. Shruti Malik

BDS, MDS (Endodontics)

(+91-9899561092)

Name : Ankita Verma

Age/Sex : 35y / F

Date : 23/12/23

**Timings : 10:00 am. to 2:00 pm.
6:00 pm. to 8:30 pm.**

For Appointment

**011-45152510
+91-9999254639**

CLINICAL EXAMINATION:-

1. TMJ:-

Routine checkup

2. DENTAL STATUS:

- a. Caries Teeth :
- b. Fracture Teeth :
- c. Root Stumps :
- d. Gingivitis :
- e. Periodontitis :
- f. Impacted Teeth :
- g. Malaligned Teeth :

O/E

Calculus +

Ri

Periapical Mouthwash Rx

3. ORAL LESIONS:-

DIAGNOSIS:-

Leukoplakia

5. TREATMENT PLANNING:

6. FOLLOW UP:-

Referral To Other Consultant: Yes/ No

If Yes, please mention the Name:

Doctor's Signature

Facilities Available :

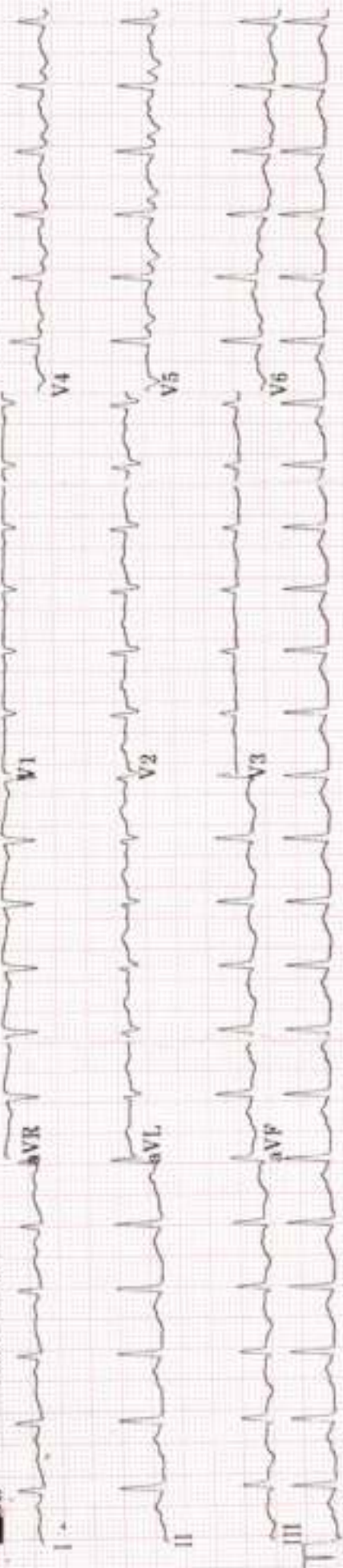
- * MULTI-SPECIALITY HOSPITAL * MODULAR FULLY EQUIPPED OT * NURSERY * LAPROSCOPIC SURGERY
- * 24X7 EMERGENCY * OPG * DENTAL * 24X7 DIAGNOSTICS * LABOUR ROOM * ECHO * EEG * DIGITAL X-RAY * CT SCAN
- * ECG * ULTRASOUND * RICU/ICU * ALL SPECIALITY OPD * PLASTIC & COSMETIC SURGERY * DIALYSIS * PHARMACY

GE

MAC600 1.02

ID: 8447695164

23-Dec-2023 12:32:34



Auto gain applied
 0.16-20Hz 25.0 mm/s 5.0||5.0 mm/mV

50Hz 144 bpm

↑ by 2.56 + 1 rhythm Id

ID: 8447695164

35years Female

Vent. rate 144 bpm
 QRS duration 64 ms
 QT/QTc 246/380 ms
 PR interval 122 ms
 P duration 92 ms
 RR interval 416 ms
 P-R-T axes 35 65 -69

MAC600 1.02

12SL™ v239

Ankita

Malik Radix HealthCare.

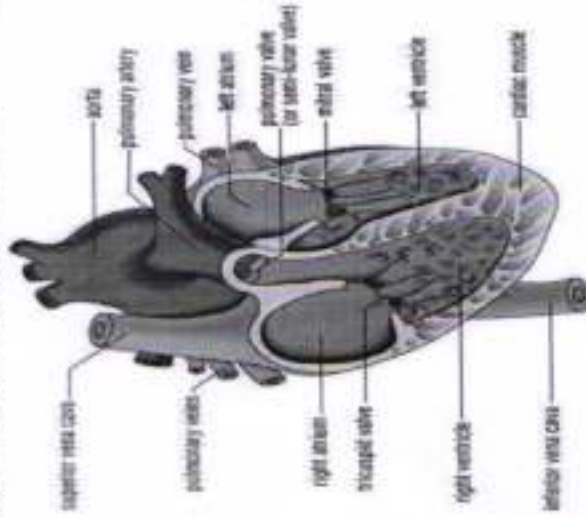
ELECTROCARDIOGRAM

Name: MRS. ANKITA VERMA

Age & Sex: 35 YR / FEMALE

Ref By: MEDIWHEEL

Date: 23/12/2023



EKG FINDINGS:

Rate 144 bpm Rhythm Sinus Mechanism Normal

Axis Normal P Wave Normal PR Interval 0.12/Sec

QRS Complex Normal QT Interval Normal Q Wave Normal

ST Segment Normal T Wave Normal

Conclusion Sinus Tachycardia (HR-144 bpm), Normal Axis. To be correlate.

Doctors Signature 
M.D. "Physician"
 PGDCC
 DMC-46498



LAB REPORT

Reg. Date	23/12/2023	Patient Id	2312230012	DOB,	
Name	MRS. ANKITA VERMA	Gender	F	Perm. ID	
Age	35 Yrs.	Panel	MEDIWHEEL	Reported	23/12/2023 17:29:52
Ref. By	MEDIWHEEL				

Test Name	Result	Units	Ref. Range
MEDIWHEEL ANNUAL PLUS CHECK			
<u>HAEMATOLOGY</u>			
<u>COMPLETE HAEMOGRAM</u>			
HAEMOGLOBIN (HB%)	13.1	gm/dl	12 - 15
TOTAL LEUCOCYTE COUNT (TLC)	7,800	/cumm	4000 - 11000
<u>DIFFERENTIAL LEUCOCYTE COUNT (DLC)</u>			
NEUTROPHIL	67	%	40 - 80
LYMPHOCYTE	25	%	28 - 55
MONOCYTE	04	%	02 - 10
EOSINOPHIL	04	%	01 - 06
BASOPHIL	00	%	0 - 0
ESR (WESTEGREN'S METHOD)	12	mm/1st hr.	0 - 15
R B C COUNT	4.99	Millions/cmm	4.247 - 5.4
P.C.V / HAEMATOCRIT	42.8	%	35 - 45
M C V	85.8	fl.	80 - 100
M C H	26.2	Picogram	27.0 - 31.0
M C H C	30.6	gm/dl	33 - 37
PLATELET COUNT	2.01	Lakh/cu mm	1.50 - 4.50
BLOOD GROUP ABO	" B "		
RH TYPING	Positive		
BLOOD SUGAR FASTING	94.89	mg/dl	70 - 100
BLOOD SUGAR PP	116.88	mg/dl	90 - 140
<u>THYROID PROFILE</u>			
Free T3 ELFA	2.81	ng/ml	02 - 04
Free T4 ELFA	0.98	ug/dl	0.8 - 2.7

Checked by : _____
Page 1 Contd...2

If test results are alarming or unexpected, patient is advised to contact the laboratory immediately for possible remedial action.

Facilities Available

- Multispeciality Hospital - 24 Hours Emergency - X-Ray/ ECG/ Ultrasound/ CT Scan - Dental- Fully Equipped Operation Theatre
- Fully Functional Lab - 24/7 Casualty/ ICU-Nursery 24/7 Pharmacy - Labour Room - All Speciality OPD - Laproscopic Surgery - ECHO - Plastic Surgery



LAB REPORT

Reg. Date	23/12/2023	Patient Id	2312230012	DOB.
Name	MRS. ANKITA VERMA	Gender	F	Perm. ID
Age	35 Yrs.	Panel	MEDIWHEEL	Reported
Ref. By	MEDIWHEEL			23/12/2023 17:29:52

Test Name	Result	Units	Ref. Range
TSH Serum/ELFA	3.260	uIU/ml	0.25 - 5.50 uIU/ml

Interpretation

Clinical Use

- Diagnose Hypothyroidism and Hyperthyroidism
- Monitor T4 replacement or T4 suppressive Therapy
- Quantify TSH levels in the subnormal range

Increased Levels : Primary Hypothyroidism Subclinical Hypothyroidism, TSH dependent, Thyroid Hormone Resistance.

Decreased Levels : Grave's Disease, Autonomous Thyroid Hormone Secretion, TSH Deficiency

LIPID PROFILE

TOTAL CHOLESTEROL	127.00	mg/dL	130.0 - 200.0 (<200)
TRIGLYCERIDES	90.30	mg/dL	80.5 - 150.0 (<150)
H D L CHOLESTEROL DIRECT	46.10	mg/dL	42.0 - 60.0 (<40->59)
V L D L	18.1	mg/dL	4.0 - 30. (23-45)
L D L CHOLESTEROL	62.8	mg/dL	50.0 - 150.0 (50-150)
TOTAL CHOLESTEROL / HDL RATIO	2.8		3.3 - 5.1
LDL / HDL CHOLESTEROL RATIO	1.4		1.5 - 3.5

LIVER FUNCTION TEST (LFT)

BILIRUBIN TOTAL	0.88	mg/dl	0.2 - 1.2
-----------------	------	-------	-----------

Checked by : _____
Page 2 Contd...3

If test results are alarming or unexpected, patient is advised to contact the laboratory immediately for possible remedial action.

Facilities Available

- Multispecialty Hospital - 24 Hours Emergency - X-Ray/ ECG/ Ultrasound/ CT Scan - Dental - Fully Equipped Operation Theatre - Fully Functional Lab - 24/7 Casualty/ ICU-Nursery 24/7 Pharmacy - Labour Room - All Speciality OPD - Laproscopic Surgery - ECHO - Plastic Surgery



LAB REPORT

Reg. Date	23/12/2023	Patient Id	2312230012	DOB.	
Name	MRS. ANKITA VERMA	Gender	F	Perm. ID	
Age	35 Yrs.	Panel	MEDIWHEEL	Reported	23/12/2023 17:29:52
Ref. By	MEDIWHEEL				

Test Name	Result	Units	Ref. Range
CONJUGATED (D. BILIRUBIN)	0.13	mg/dl	0.00 - 0.3
UNCONJUGATED (L.D.BILIRUBIN)	0.75	mg/dl	0.2 - 0.9
SGOT / AST	25.40	IU/L	0 - 35
SGPT / ALT	49.7	IU/L	0 - 35
ALKALINE PHOSPHATASE	95.00	U/L	64 - 306
TOTAL PROTEIN	8.21	gm/dl	6.0 - 8.3
ALBUMIN	4.62	gm/dl	3.2 - 5.0
GLOBULIN	3.59	gm/dl	2.5 - 5.6
A/G RATIO	1.29		0.9 - 2.0
GAMMA GT	30.21	IU/L	0.0 - 35.0
SERUM CREATININE	0.60	mg/dl	0.6 - 1.2
SERUM URIC ACID	6.17	mg/dl	2.4 - 6.0
BLOOD UREA NITROGEN (BUN)	12.40	mg/dl	6.0 - 21.0
BUN/CREAT RATIO	20.6	mg/dl	10 - 20
Urine Routine Examination			

PHYSICAL EXAMINATION

QUANTITY	20	ml.	
COLOUR	Pale Yellow		Pale Yellow
TRANSPARENCY	Clear		
SPECIFIC GRAVITY	1.025		
PH	6.0		

CHEMICAL EXAMINATION

ALBUMIN	Nil
SUGAR	Nil

MICROSCOPIC EXAMINATION

PUS CELLS	0-1	/HPF
-----------	-----	------

Checked by : _____
Page 3 Contd...4

If test results are alarming or unexpected, patient is advised to contact the laboratory immediately for possible remedial action.

Facilities Available

- Multispecialty Hospital - 24 Hours Emergency - X-Ray/ ECG/ Ultrasound/ CT Scan - Dental - Fully Equipped Operation Theatre
- Fully Functional Lab - 24/7 Casualty/ ICU-Nursery 24/7 Pharmacy - Labour Room - All Speciality OPD - Laproscopic Surgery -
ECHO - Plastic Surgery



LAB REPORT

Reg. Date	23/12/2023	Patient Id	2312230012	DOB.	
Name	MRS. ANKITA VERMA	Gender	F	Perm. ID	
Age	35 Yrs.	Panel	MEDIWHEEL	Reported	23/12/2023 17:29:52
Ref. By	MEDIWHEEL				

Test Name	Result	Units	Ref. Range
RBC'S	Nil	/HPF	
CASTS	Nil		
CRYSTALS	NIL		
EPITHELIAL CELLS	0-1	/HPF	
BACTERIA	Nil		
OTHERS	Nil		

DR. REENA DAHIYA
 M.B.B.S, MD (Path.)
 Checked by
 Malik Radix Healthcare Pvt. Ltd.
 Page 4 of 4

DR. MEENU AGGARWAL
 M.B.B.S, MD (Path.)

If test results are alarming or unexpected, patient is advised to contact the laboratory immediately for possible remedial action.

Facilities Available

- Multispeciality Hospital - 24 Hours Emergency - X-Ray/ ECG/ Ultrasound/ CT Scan - Dental- Fully Equipped Operation Theatre
- Fully Functional Lab - 24/7 Casualty/ ICU-Nursery 24/7 Pharmacy - Labour Room - All Speciality OPD - Laproscopic Surgery - ECHO - Plastic Surgery