



# PARKLINE DIAGNOSTICS PVT. LTD.

L.G. 3, 4 & 5, Bhuvana Towers, S.D. Road, Secunderabad - 500 003.  
Tel : +91 40-2784 5852, 6649 1787, 7995421787, 7093445852, Fax : +91 40 2784 7864  
Email parklinediagnostics@gmail.com www.parklinediagnostics.com



NABL Accredited  
Certificate No.MC-256

## MEDICAL EXAMINATION REPORT

Name	Mr. A. Srinivasa Rao		Date :	26/03/2022
Company	elo: mediwheel		Reg. No. :	1907101
Contact No.	99666690001		Sex	<input checked="" type="checkbox"/> M <input type="checkbox"/> F
			Age :	57
Type	Pre-Emp		Emp. No.:	150834
	Overseas		Height	170 cms
	Annual	<input checked="" type="checkbox"/>	Weight	80 kgs
Remarks	<p>Prediabetic state - HbA1c - 5.9% Advice follow up.</p> <p>- Hypertriglyceridemia (+). Advice follow up.</p> <p>USG - Simple exophytic renal cyst measuring 2.2 x 2.3 cms in the Upper pole of Left Kidney. Advice follow up.</p>			
Fitness Status	Medically Fit / Unfit		Physician's Signature	

DR. PRIYANKA SANNIDHI  
MBBS  
Regn. No: 11351

# COMPREHENSIVE MEDICAL EXAMINATION REPORT

NAME Mr. A. SRINIVASA RAO

AGE 57 yrs / male

MARITAL STATUS married CHILDREN : M  F

IDENTIFICATION (IF ANY) A mark on the dorsal part of neck.

## PAST HISTORY

Any family H/o : High Blood Pressure, Heart Disease, Tuberculosis, Diabetes, Asthma, Cancer

CA D

Any personal H/o Major illness like : Typhoid..... NIL..... Jaundice..... 1992..... Etc.

Any H/o STD..... Skin infection..... NIL

H/o Blood Transfusion..... Recent Vaccination.....

H/o Epilepsy..... NIL..... Giddiness..... NIL

H/o Surgery..... Fracture in the past..... NIL

## Any Personal H/O.

High Blood Pressure, Heart Disease Tuberculosis, Diabetes, Asthma, Cancer

x 9 yrs

Drug Abuse, Drug Allergy, Micturition, Bowels, Alcohol, Smoking, Sleep, MC, Wt. Loss/Wt. Gain

Present illness / Medication T. STAMLO BETA strong

## GENERAL EXAMINATION

Conjunctiva :

Skin :

Ears :

Nose :

Throat & Oral Cavity :

Bone, Joints : (N)

Nutritional Status : Well Nourished

Lymph Nodes : NPD

Edema Feet : NIL

Varicose Veins : NIL

NPD

**Distant Vision : Near Vision :**

Right Eye: 6/6

Right Eye: N/D + 2.75 sph N/G

With glasses / Without glasses

With glasses / Without glasses

left Eye: 6/6

left Eye: N/D + 2.75 sph N/G

with glasses / without glasses

with glasses / without glasses

Colour Vision: BE normal

**Ophthalmologist's Signature**

**DR. KATTA**  
M.S. D.O. F.R.F.  
Regd. 6307

**Right Ear**

**Left Ear**

Hearing: (N)

(N)

Rinee's Test ;

Weber Test :

Discharge : NIL

NIL

**SYSTEMIC EXAMINATION**

Pulse : 80 bpm

B.P. : 110/70 mmHg

Lungs : A. Shape of Chest B/C symmetrical  
B. Breath Sounds B/C clear  
C. Adventitious Sounds NO

Heart : A. Sounds S<sub>1</sub>, S<sub>2</sub> ⊕  
B. Murmurs NO murmur

**Nervous System**

Abdomen : A. Liver NPD  
B. Spleen NPD  
C. Piles NIL  
D. Any Lump NIL

A. Higher Function :  
B. Cranial Nerves :  
C. Sensory System : (N)  
D. Motor System :  
E. Jerks :

General : A. Hernia  
B. Hydrocele  
C. Varicocele  
NAD

Breast : Rt. (N) Lt. (N)

## CANDIDATE'S DECLARATION

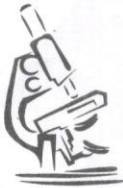I hereby solemnly declare that I am not suffering from Asthma, Hypertension, Diabetes, Occult Psychological disorders or any other ailment which can be suppressed without my voluntary declaration.

Date :

  
Signature

Place :

Note : General Physical Examination and Investigation included in the health check-up Have certain limitations and may not be able to detect all latent and asymptomatic diseases. Any new symptoms developing after the health check-up or persisting thereafter should be brought to the attention of the treating physician.



# PARKLINE DIAGNOSTICS PVT. LTD.

L.G. 3, 4 & 5, Bhuvana Towers, S.D. Road, Secunderabad - 500 003. Tel : +91 40-2784 5852, 6649 1787, 7995421787, 7093445852, Fax : +91 40 2784 7864 Email parklinediagnostics@gmail.com www.parklinediagnostics.com



NABL Accredited  
Certificate No.MC-2566

## ENT CONSULTATION

S.No. 154834      Emp.No. 154834      Date 26/3/22  
 Name Mr. A. Srinivasa Rao      Age 57 Yrs      Sex  M /  F

### EARS :

Right

Left

EAC : patent, no cerumen. -ob-

TM : Intact, pearly white. Cone of light (+) -ob-

TFT : Rinne's +ve Weber's - centrolone

NOSE : Septum (N). Bil. T'symmetry (N). polyc. (N) montade

THROAT : Oropharynx (N). Bil. v. c's a } (N) moving

NECK : (N) Asymmetry bil

IMPRESSION: ENT clinically NAD

*D. Hari Krishna Reddy*

Dr. D. Hari Krishna Reddy  
MS (ENT)  
Head & Neck Surgeon  
Reg. No: 88379

7799686970

Name : A. Srinivas Rao ..... Sex : M Age : 57 .....

Date : 26/3/22 .....

OPD No : 527 .....

O/E. Cat sn<sup>th</sup>  
 # it 6 - lingual.

# Res for n<sup>ut</sup> 7

Horizontal impac<sup>n</sup> it 8

Ro:

Adv. oral prophylaxis.

Adv. op<sub>4</sub>. for 8.




# PARKLINE DIAGNOSTICS PVT. LTD.

L.G 3, 4 & 5, Bhuvana Towers, Sarojini Devi Road, Secunderabad - 500 003.  
Tel. +91 40 2784 5852, 6649 1787, 77995421787, 7093445852, Fax : + 91 40 2784 7864  
Email : parklinediagnostics@gmail.com, www.parklinediagnostics.com



## TEST REPORT

Name : Mr . A SRINIVASA RAO [154834]  
Age / Gender : 57 Years / Male  
Ref.By : Medi Wheel  
Req. No : BIL1907141

TID : UMR0752876  
Registered on : 26-Mar-2022 07:31 AM  
Reported On : 26-Mar-2022 01:33 PM

### Ultrasound Whole Abdomen

**LIVER** is normal shape, size ( 12.9 cms) and has uniform echopattern.  
No evidence of focal lesion. No intrahepatic biliary ductal dilatation.  
Hepatic and portal vein radicals are normal.

**GALL BLADDER** shows normal shape and has clear contents.  
Gall bladder wall is of normal thickness. CBD is of normal calibre.

**PANCREAS** has normal shape, size and uniform echopattern.  
No evidence of ductal dilatation or calcification.

**SPLEEN** shows normal shape, size and echopattern.

**KIDNEYS** move well with respiration and have normal shape, size and echopattern.  
Cortico- medullary differentiations are well madeout.  
*E/o simple exophytic cyst measuring 2.2 x 2.3 cms noted in the upper pole of left kidney.*  
No evidence of calculus or hydronephrosis.  
Right kidney measures 9.0 X 5.2 cms, Left kidney measures 9.2 X 5.1 cms.

**URINARY BLADDER** shows normal shape and wall thickness.  
It has clear contents. No evidence of diverticula.


**PROSTATE** shows normal shape, size and echopattern.

No evidence of free fluid in the abdomen

### **IMPRESSION:**

\* Simple left renal exophytic cyst

Suggested clinical correlation and follow up

  
Dr. Abid Yazden  
Consultant Radiologist

The Test marked with\*are not accredited by NABL

Lab Timings (Weekdays) : 7.00 am to 8.30 pm  
Sundays & Holidays : 7.00 am to 1.00 pm

Radiologists Timings (Weekdays) : 7.30 am to 1.30 pm  
& 5.30 pm to 7.45 pm  
Sundays & Holidays : 7.30 am to 9.30 am



# PARKLINE DIAGNOSTICS PVT. LTD.

L.G 3, 4 & 5, Bhuvana Towers, Sarojini Devi Road, Secunderabad - 500 003.  
Tel. +91 40 2784 5852, 6649 1787, 77995421787, 7093445852, Fax : + 91 40 2784 7864  
Email : parklinediagnostics@gmail.com, www.parklinediagnostics.com



NABL Accredited  
Certificate No.: MC-2566

## TEST REPORT

Name : Mr . A SRINIVASA RAO [154834]  
Age / Gender : 57 Years / Male  
Ref.By : Medi Wheel  
Req. No : BIL1907141

TID : UMR0752876  
Registered on : 26-Mar-2022 07:31 AM  
Reported On : 26-Mar-2022 10:05 AM

### X-RAY CHEST PA VIEW

Lung fields are clear.

Cardia is normal.

Hila are normal.


C P angles are free.

Bony cage is normal.

Soft tissues are normal.

IMPRESSION : NORMAL CHEST X-RAY



  
Dr. D.J. MOHAN  
MD DMRD  
(Reg No. 8095)  
Consultant Radiologist

The Test marked with\*are not accredited by NABL

Lab Timings (Weekdays) : 7.00 am to 8.30 pm  
Sundays & Holidays : 7.00 am to 1.00 pm

Radiologists Timings (Weekdays) : 8.30 am to 1.30 pm  
& 5.30 pm to 7.45 pm  
Sundays & Holidays : 7.30 am to 9.30 am



ID: 190/141

26-03-2022 07:56:40 AM

CARDIART

MR.A.SRINIVASA RAO

Male 57Years

HR : 60 bpm  
P : 95 ms  
PR : 133 ms  
QRS : 78 ms  
QT/QTc : 407/408 ms  
P/QRS/T : -2/-3/20 °  
RV5/SV1 : 1.531/0.352 mV

Diagnosis Information:  
Sinus Rhythm  
\*\*\*Normal ECG\*\*\*

Report Confirmed by:

NCR  
NVL

Dr. NAVEEN KUMAR .C  
M.D., D.M.  
Consultant Cardiologist  
Reg. No. 52291

PATIENT SUMMARY REPORT

KLINE DIAGNOSTICS PVT.LTD

: 1907141  
E : MR A SRINIVAS RAO  
/ SEX : 57 / MALE

HEIGHT (cm) : 170  
WEIGHT (kg) : 70  
PROTOCOL : BRUCE

REF. BY : MEDIWHEEL  
DONE BY : DR NAVEEN KUMAR C  
TECHNICIAN : G.M.SURESH

03-2022, 09:00:  
C

ECG HISTORY :  
INDICATION :  
OBJECT OF TEST : Routine Check Up.  
RISK FACTOR : Hypertension.  
ACTIVITY : Very Active.  
PREVIOUS INVESTIGATION : ECG  
REASON FOR TERMINATION : THR ACHIEVED  
EXERCISE TOLERANCE : Good (> 10 METS).  
EXERCISE INDUCED ARRHYTHMIAS : No.  
ECG RESPONSE : Normal.  
SYMPTOM RESPONSE : Normal.

CLINICAL IMPRESSION :  
REMARKS : Negative for inducible ischemia

**Dr. NAVEEN KUMAR .C**  
M.D., D.M.  
Consultant Cardiologist  
Reg. No. 52291

Confirmed By : \_\_\_\_\_

Signature

