

Health Check up Booking Confirmed Request(22S32822),Package Code-PKG1000477, Beneficiary Code-320188

Mediwheel <wellness@mediwheel.in>
From: healthcare.medicals@gmail.com
To: customercare@mediwheel.in

Mon, Sep 9, 2024 at 11:30 AM



Mediwheel
...Your wellness partner

011-41195959

Hi **Healthcare Medical Centre and Diagnostic**,

The following booking has been confirmed. It is requested to honor the said booking & provide priority services to our client

Hospital Package Name : Mediwheel Full Body Health Checkup Female Above 40

Patient Package Name :

Hospital Address : 1st Floor Patel House,Rang Bhawan Building, MG Cross Rd, Vile Parle East,Mumbai 400057

Contact Details : 9819670305

Appointment Date : 10-09-2024

Confirmation Status : Booking Confirmed

Preferred Time : 09:00 AM - 09:30 AM

Member Information		
Booked Member Name	Age	Gender
JAYESH RATANLAL DALAL	75 year	Male

We request you to facilitate the employee on priority.

Thanks,
Mediwheel Team
Please Download Mediwheel App



You have received this mail because your e-mail ID is registered with **Arcofemi Healthcare Limited** This is a system-generated e-mail please don't reply to this message.

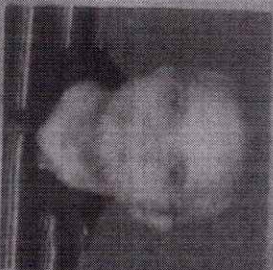Please visit to our Terms & Conditions for more informaion. Click here to unsubscribe.

आयकर विभाग

INCOME TAX DEPARTMENT



भारत सरकार
GOVT. OF INDIA



स्थायी लेखा संख्या कार्ड
Permanent Account Number Card


AACPPD5138J

नाम / Name
JAYESH RATANLAL DALAL

पिता का नाम / Father's Name
RATANLAL HIRALAL DALAL

जन्म की तारीख /
Date of Birth
13/09/1948

हस्ताक्षर / Signature



- COMPU. PATHOLOGY • ALLERGY TESTING
- DIGITAL WHOLE BODY X-RAYS
- DIGITAL 3D SONOGRAPHY
- DIGITAL WHOLE BODY COLOUR DOPPLER
- DIGITAL 2-D ECHO WITH COLOUR DOPPLER
- E.C.G. • LUNG FUNCTION TEST
- MAMMOGRAPHY & BONE MINERAL DENSITOMETRY

- COMPUTERISED STRESS TEST
- DENTAL
- ADVANCED DENTISTRY
- PHYSIOTHERAPY
- AUDIOMETRY & SPEECH THERAPY
- FULL BODY HEALTH CHECK-UPS
- CORPORATE HEALTH CHECKUPS



HEALTHCARE

MEDICAL CENTRE & DIAGNOSTICS

NAME	MR JAYESH DALAL	DATE	10 /9/24
HEIGHT: 161 CM	WEIGHT = 67.4 KG	AGE	76 YRS
REFERRED BY	MEDIWHEEL	SEX	MALE

PRESENT COMPLAINT: THYROID SINCE 40 YRS /BP SINCE 13YRS /DM SINCE 11YRS

CURRENT MEDICATION = TAB THYRONORM 75/TAB ROSUVAS 20 /TAB NEBIDAR 5MG/TAB GLYCI PHAGE 500/TAB ZESTOGAV 5

PAST HISTORY = BIL CATARACT IN 2013 /CA PROTRASTE /ANGIOPLASTY 2018

ALLERGY: NONE HABITS: NONE APPETITE: GOOD

SLEEP: GOOD BLADDER: INVOLUNTARY BOWEL: NAD

FAMILY HISTORY = FATHER-BP (DIED) STROKE MOTHER=BP (DIED)

GYNEC HISTOR=NOT APPLICABLE

GENERAL EXAMINATION: ADVICE- T. Livogen 5 to x 2 mnth

P:73 / MIN BP:120/60 MM HG T. Thyronorm 50 1 to 2 mnth - Friday

PALLOR:NO ICTERUS: NO T Thyronorm 75 1 to 2 mnth - Sun.


OEDEMA: NO OTHERS: NAD ↓ oily fatty food

RS: AEBE NO CVS: S1 S2 NORMAL Report T3 T4, TSH after 3 mnth continue other medicine as it is.

PA: NAD CNS: NAD

DR. YOGESH J, MEHTA M.D
DR. Y. J. MEHTA M.D Cardiologist
 Reg. No. - 71131

INVESTIGATION:



- COMPU. PATHOLOGY • ALLERGY TESTING
- DIGITAL WHOLE BODY X-RAYS
- DIGITAL 3D SONOGRAPHY
- DIGITAL WHOLE BODY COLOUR DOPPLER
- DIGITAL 2-D ECHO WITH COLOUR DOPPLER
- E.C.G. • LUNG FUNCTION TEST
- MAMMOGRAPHY & BONE MINERAL DENSITOMETRY

- COMPUTERISED STRESS TEST
- DENTAL
- ADVANCED DENTISTRY
- PHYSIOTHERAPY
- AUDIOMETRY & SPEECH THERAPY
- FULL BODY HEALTH CHECK-UPS
- CORPORATE HEALTH CHECKUPS



OPHTHALMIC REPORT

NAME = Jayesh R. Datal

DATE = 10/9/24

R- NO

AGE = 26

REF. BY DR.

SEX = M

RIGHT EYE

LEFT EYE

V.A. WITHOUT GLASSES : 8/9

V.A. WITH GLASSES: —

SLIT LAMP EXAMINATION: NORMAL —

IOP – SCHIOTZ TONOMETER: —

FUNDUS: NORMAL —

COLOUR VISION:
(ISHIHARA CHART)

NORMAL (BE)

Normal (BE)

OCULAR MOVEMENTS: NORMAL (BE)

RETINOSCOPY: —

Prescription:

	SPH	CYL	AXIS	SPH	CYL	AXIS
DISTANCE		-1.25	90°	-0.75		
NEAR			ADD +1.00			

CLINICAL IMPRESSION: (N)

ADVICE: EYE EXERCISE AND DECREASE SCREEN TIME

glasses

HEALTHCARE
MEDICAL CENTRE AND DIAGNOSTICS
RANG BHAWAN BLDG. (OPTOMETRIST)
VILE PARLE EAST, MUMBAI
MOBILE NO -- 8779865778

- COMPU. PATHOLOGY • ALLERGY TESTING
- DIGITAL WHOLE BODY X-RAYS
- DIGITAL 3D SONOGRAPHY
- DIGITAL WHOLE BODY COLOUR DOPPLER
- DIGITAL 2-D ECHO WITH COLOUR DOPPLER
- E.C.G. • LUNG FUNCTION TEST
- MAMMOGRAPHY & BONE MINERAL DENSITOMETRY

- COMPUTERISED STRESS TEST
- DENTAL
- ADVANCED DENTISTRY
- PHYSIOTHERAPY
- AUDIOMETRY & SPEECH THERAPY
- FULL BODY HEALTH CHECK-UPS
- CORPORATE HEALTH CHECKUPS



DATE : 10/09/2024

TO,

Mediwheel

This is regarding your client Miss/Mrs/Mr. Jayesh

Ratanlal Dalal Visited to our centre on 10.09.24 for

her/his proposed tests. All tests are done as scheduled except

Pending/skipped tests: Stool Test

Reason: could not pass any

✓ We are canceling / will reschedule it as per her/his convenience.

Thank you.

J.R. Dalal

Client's sign
DR. YOGESH J. MEHTA M.D
MEDICAL CENTRE AND DIAGNOSTICS
RANGSHAWAN BL-2 G CROSS RD
VILE PARLE EAST, MUMBAI-400057
MOBILE NO - 8779865778

DR. YOGESH J. MEHTA M.D
Physician & Cardiologist
Medical Examiner
Reg. No. - 71131

- COMPU. PATHOLOGY • ALLERGY TESTING
- DIGITAL WHOLE BODY X-RAYS
- DIGITAL 3D SONOGRAPHY
- DIGITAL WHOLE BODY COLOUR DOPPLER
- DIGITAL 2-D ECHO WITH COLOUR DOPPLER
- E.C.G. • LUNG FUNCTION TEST
- MAMMOGRAPHY & BONE MINERAL DENSITOMETRY

- COMPUTERISED STRESS TEST
- DENTAL
- ADVANCED DENTISTRY
- PHYSIOTHERAPY
- AUDIOMETRY & SPEECH THERAPY
- FULL BODY HEALTH CHECK-UPS
- CORPORATE HEALTH CHECKUPS



HEALTHCARE

MEDICAL CENTRE & DIAGNOSTICS

DENTAL CHECK UP

NAME	MR JAYESH DALAL	DATE	10/9/24
REFERRED BY	MEDIWHEEL	AGE - YRS	76
		SEX	M

CHIEF COMPLAINT : NONE

PAST DENTAL HISTORY : NONE

HABITS =NONE

ORAL EXAMINATION : NO CARIES

HEALTHY MUCOSA

NO ULCERS
NO STAINS

NO GUM BLEEDING

TREATMENT :REGULAR ORAL HYGIENE

USE FLUORIDE TOOTHPASTE AND FLOSS

HEALTHCARE
MEDICAL CENTRE & DIAGNOSTICS
RANG BRAWAN ROAD, VILE PARLE EAST, MUMBAI - 400 057
MOBILE NO. 9820057
DR SIGNATURE

- COMPU. PATHOLOGY • ALLERGY TESTING
- DIGITAL WHOLE BODY X-RAYS
- DIGITAL 3D SONOGRAPHY
- DIGITAL WHOLE BODY COLOUR DOPPLER
- DIGITAL 2-D ECHO WITH COLOUR DOPPLER
- E.C.G. • LUNG FUNCTION TEST
- MAMMOGRAPHY & BONE MINERAL DENSITOMETRY

- COMPUTERISED STRESS TEST
- DENTAL
- ADVANCED DENTISTRY
- PHYSIOTHERAPY
- AUDIOMETRY & SPEECH THERAPY
- FULL BODY HEALTH CHECK-UPS
- CORPORATE HEALTH CHECKUPS



HEALTHCARE

MEDICAL CENTRE & DIAGNOSTICS

NAME	MR JAYESH RATANLAL DALAL	DATE	10.09.2024
	Copyright © The McGraw-Hill Companies, Inc. Permission required for reproduction.	AGE	76 YRS
REF. BY	ARCOFEMI HEALTHCARE	SEX	MALE

X-RAY CHEST (PAVIEW).

The lungs on the either side show equal translucency.

The pleural spaces are normal.

The cardiac size is normal.

The domes of the diaphragms are normal in position, and show smooth outline.

Ribs appear normal.

IMPRESSION :

NO EVIDENCE OF PLEURAL OR PARENCHYMAL PATHOLOGY IS NOTED.

**DR.SUDHANSHU SAXENA
CONS.RADIOLOGIST.**

Note : Investigations have their limitations. Solitary radiological investigations never confirm the final diagnosis. They only help in diagnosing the disease in correlation to clinical symptoms and other related tests. Please interpret accordingly

- COMPU. PATHOLOGY • ALLERGY TESTING
- DIGITAL WHOLE BODY X-RAYS
- DIGITAL 3D SONOGRAPHY
- DIGITAL WHOLE BODY COLOUR DOPPLER
- DIGITAL 2-D ECHO WITH COLOUR DOPPLER
- E.C.G. • LUNG FUNCTION TEST
- MAMMOGRAPHY & BONE MINERAL DENSITOMETRY

- COMPUTERISED STRESS TEST
- DENTAL
- ADVANCED DENTISTRY
- PHYSIOTHERAPY
- AUDIOMETRY & SPEECH THERAPY
- FULL BODY HEALTH CHECK-UPS
- CORPORATE HEALTH CHECKUPS



NAME	MR JAYESH RATANLAL DALAL	DATE	10.09.2024
	Copyright © The McGraw-Hill Companies, Inc. Permission required for reproduction	AGE	76 YRS
REF. BY	ARCOFEMI HEALTHCARE	SEX	MALE

2D-ECHOCARDIOGRAPHY & DOPPLER FINDINGS:

Normal sized LA, RA, RV and LV
 2DEF= 60%
 Mild LV hypertrophy seen.
 No evidence of hypokinesia.
 All valves morphologically normal.
 Trivial tricuspid regurgitation seen.
 RVSP= 22mmHg
 No PAH.
 No thrombus/vegetation seen.
 IAS and IVS intact. No shunt lesion seen.
 IVC non dilated with more than 50% inspiratory collapse seen.
 Normal RV function seen.
 TAPSE=2.22cms, MAPSE=1.56cm
 Pericardium normal. No pericardial effusion
 Type 1 diastolic dysfunction seen.
 Normal LV systolic function.

M-MODE MEASUREMENT:

LEFT VENTRICULAR	
IVSd	12 mm
IVSs	17 mm
LVIDd	42 mm
LVIDs	22 mm
LVPWd	12 mm
LVPWs	16 mm
EF (Teich)	60 %
% FS	33 %

Cont on page 2....

- COMPU. PATHOLOGY • ALLERGY TESTING
- DIGITAL WHOLE BODY X-RAYS
- DIGITAL 3D SONOGRAPHY
- DIGITAL WHOLE BODY COLOUR DOPPLER
- DIGITAL 2-D ECHO WITH COLOUR DOPPLER
- E.C.G. • LUNG FUNCTION TEST
- MAMMOGRAPHY & BONE MINERAL DENSITOMETRY

- COMPUTERISED STRESS TEST
- DENTAL
- ADVANCED DENTISTRY
- PHYSIOTHERAPY
- AUDIOMETRY & SPEECH THERAPY
- FULL BODY HEALTH CHECK-UPS
- CORPORATE HEALTH CHECKUPS



Copyright © The McGraw-Hill Companies, Inc. Permission required for reproduction or display

NAME	MR JAYESH RATANLAL DALAL	DATE	10.09.2024
		AGE	76 YRS
REF. BY	ARCOFEMI HEALTHCARE	SEX	MALE

AORTA	
AO	25 mm
LA	33 mm
AVO	18

MITRAL	VALVE
DE	1.80 cm
EF SLOPE	0.12

DOPPLER STUDY:

PWD left ventricular inflow shows E < A waves.
 Mitral valve: Dec time= 175ms, E<A, E/E'=14
 Aortic valve: 2.48mmHg
 Pulmonary valve: 2.40mmHg
 IVC non dilated with more than 50% inspiratory collapse seen.


DR. DINESH ROHIRA
 MBBS, DNB MEDICINE

- COMPU. PATHOLOGY • ALLERGY TESTING
- DIGITAL WHOLE BODY X-RAYS
- DIGITAL 3D SONOGRAPHY
- DIGITAL WHOLE BODY COLOUR DOPPLER
- DIGITAL 2-D ECHO WITH COLOUR DOPPLER
- E.C.G. • LUNG FUNCTION TEST
- MAMMOGRAPHY & BONE MINERAL DENSITOMETRY

- COMPUTERISED STRESS TEST
- DENTAL
- ADVANCED DENTISTRY
- PHYSIOTHERAPY
- AUDIOMETRY & SPEECH THERAPY
- FULL BODY HEALTH CHECK-UPS
- CORPORATE HEALTH CHECKUPS



HEALTHCARE

MEDICAL CENTRE & DIAGNOSTICS

NAME	MR JAYESH R DALAL	DATE	10.06.2024
		AGE	76YRS
REF. BY	MEDIWHEEL	SEX	MALE

ABDOMIN AND PELVIC SONOGRAPHY

K/c/o Ca prostate.

LIVER: Liver is normal in size showing grade II fatty infiltration. There is no evidence of solid or cystic mass lesion. The portal and the hepatic venous system appears normal. No evidence of any intra or extrahepatic biliary radical's dilatation noted.

GALL BLADDER: The Gall bladder is well distended and shows a solitary 8 mm mobile calculus No evidence of gall stones. No evidence of wall thickening/pericholecystic collection noted. CBD appears normal and measures 5.3 mm.

PANCREAS: Pancreas shows homogenous parenchymal echotexture. No focal lesion seen.

KIDNEYS: Both kidneys are normal in size and shows homogenous cortical echotexture with mild anterior cortical scarring . There is no evidence of hydronephrosis/ focal lesion/calculi noted.

Right kidney measures: 8.1x4.6 cms.

Left kidney measures: 8.6x3.8cms.

SPLEEN: The spleen is normal in size with homogenous parenchymal echotexture. No focal lesions are seen.

AORTA: The upper aorta and para aortic regions appear normal.

URINARY BLADDER: Urinary bladder is partly distended. The wall thickness measures 5.6 mm.No evidence of calculus or intraluminal mass seen.

Prevoid volume is 71 cc.

Postvoid residue is negligible.

PROSTATE: Prostate is normal in size & and shows calcifications.
It measures: 2.4x3.0x2.8cms, Vol = 11 gms.

IMPRESSION :

- **Grade II fatty liver.**
- **Cholelithiasis.**
- **Mild renal anterior cortical scarring bilaterally.**
- **No other significant abnormality is seen.**

Suggest: Clinical correlation.

DR. SHEETAL THAKER

CONS.RADIOLOGIST.Note: Investigations have their limitations. Solitary radiological investigations never confirm the final diagnosis. They only help in diagnosing the disease in correlation to clinical symptoms and other related tests. USG is known to have interobserver variation. Further / Follow-up imaging may be needed in some cases for confirmation of USG findings..Please interpret accordingly.

- COMPU. PATHOLOGY
- DIGITAL X-RAY
- DIGITAL SONOGRAPHY
- DIGITAL COLOR DOPPLER
- 2D ECHO CARDIOGRAPHY
- MAMMOGRAPHY & BONE MINERAL DENSITOMETRY (BMD)
- ECG ■ PFT
- COMPU. TREADMILL TEST
- PHYSIOTHERAPY
- DENTAL
- HEALTH CHECK-UP



MR JAYESH RATANLAL DALA
ELIC7843 10-Sep-2024



ECG

ELECTROCARDIOGRAM (ECG)

PATIENT MR JAYESH R DALAL AGE 76 SEX M

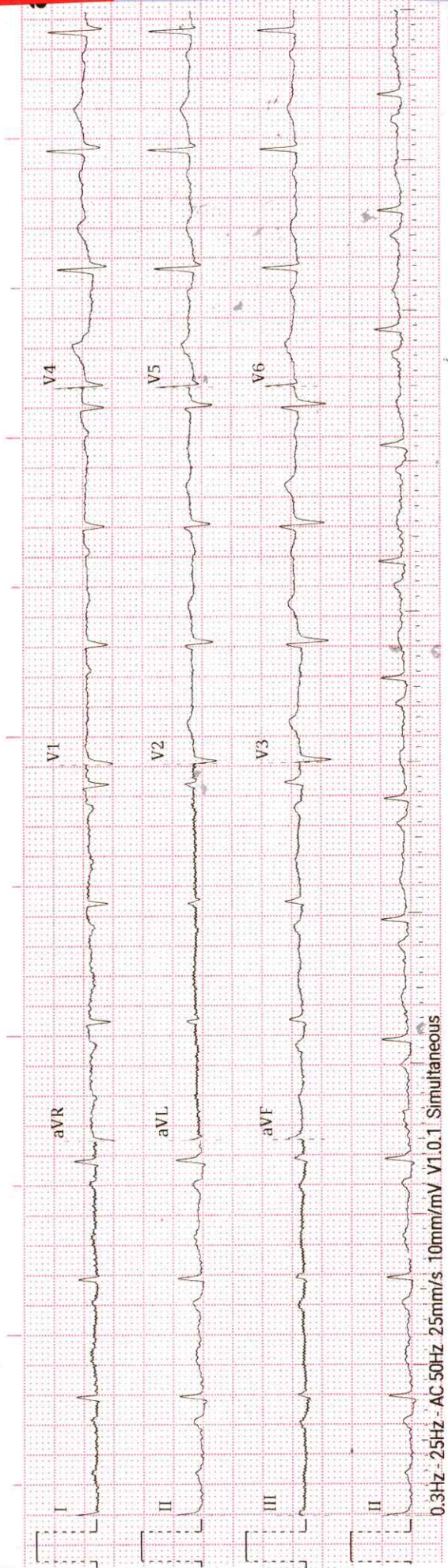
REF. BY DR. MEDIWHEEL DATE 10.09.2024

INTERPRETATION : within Normal limits

HEALTHCARE
MEDICAL CENTRE AND DIAGNOSTICS
RANG BAWAN BLDG MG CROSS RD
VILE PARLE EAST, MUMBAI-400057
MOBILE NO :- 8778865778

Dr. Dr. Jayesh
DR. YOGESH R. MEHTA M.D.
Physician & Cardiologist
Reg. No. - 71131

.....



0.3Hz - 25Hz - AC 50Hz 25mm/s 10mm/mV V1.0.1 Simultaneous

History : Axis : + 40

B.P. : P. Waves : Normal

Drugs : PR Interval : Normal

Standard : 10 mm. Q. Waves : —

Auricular Rate : 72/min QRS Interval : —

Ventricular Rate : 72/min ST Segment : N.

Rhythm : regular T. Waves : N.

Mechanism : Sinus QT Interval : —

Voltage : N Extra Systoles : —

REMARKS & CONCLUSIONS : N.H.C.

.....