

Established Patient: No

Vitals

Date	Pulse (Beats/min)	B.P (mmHg)	Resp (Rate/min)	Temp (F)	Height (cms)	Weight (Kgs)	Body Fat Percentage (%)	Visceral Fat Level (%)	Body Age (Years)	BMI	Waist Circum (cms)	Hip (cms)	Waist (cms)	Waist & Hip Ratio	User
28-11-2023 15:50	80 Beats/min	140/100 mmHg	20 Rate/min	96 F	167 cms	84 Kgs	%	%	Years	30.12	102 cms	106 cms	cms		AHLL02734

Patient Name : Mr. AJAY DONGARE

Age/Gender : 53 Y/M

UHID/MR No. : CAUN.0000138325

OP Visit No : CAUNOPV162796

Sample Collected on :

Reported on : 27-11-2023 16:15

LRN# : RAD2161625

Specimen :

Ref Doctor : SELF

Emp/Auth/TPA ID : 31549

DEPARTMENT OF RADIOLOGY

X-RAY CHEST PA

No evidence of any focal lesion.

Trachea is central in position.

Costophrenic angles are clear.

Cardio thoracic ratio is normal.

Cardiac silhouette is well maintained.


Mediastinal and hilar regions are normal.

Both diaphragmatic domes are well visualized and normal.

Visualized skeleton and soft tissues around thoracic cage appear normal.

COMMENT: No significant abnormality seen.

Please correlate clinically.



Dr. SUHAS SANJEEV KATHURIA
MBBS,DMRE, RADIOLOGY
Radiology

Patient Name : Mr. AJAY DONGARE

Age/Gender : 53 Y/M

UHID/MR No. : CAUN.0000138325

OP Visit No : CAUNOPV162796

Sample Collected on :

Reported on : 27-11-2023 17:08

LRN# : RAD2161625

Specimen :

Ref Doctor : SELF

Emp/Auth/TPA ID : 31549

DEPARTMENT OF RADIOLOGY

ULTRASOUND - WHOLE ABDOMEN

Liver appears normal in size and **shows enhanced in echotexture.**

No focal lesion is seen.

PV and CBD are normal.

No dilatation of the intrahepatic billiary radicals.

Gall bladder is well distended. No evidence of calculus. Wall thickness appears normal. No evidence of peri-GB collection. No evidence of focal lesion is seen.

Pancreas appears normal in echopattern. No focal/mass lesion/calcification. No evidence of peripancreatic free fluid or collection. Pancreatic duct appears normal.

Spleen appears normal. No focal lesion seen. Spleenic vein appears normal.

Right Kidney is - 10.0 x 5.2cm. **Left Kidney is** - 11.0 x 5.6 cm.

Both Kidneys are normal in size and echotexture.

The cortico medullary differentiation is maintained bilaterally.

No evidence of calculus / hydronephrosis seen on either side.

Urinary bladder is normal. No evidence of filling defect or mass effect. The wall thickness is normal.

Prostate is normal in size and echotexture. No evidence of calcification seen.

No obvious free fluid or lymphadenopathy is noted in the abdomen .

IMPRESSION :


- **Grade I fatty liver.**
- **No other significant abnormality seen.**

Patient Name : Mr. AJAY DONGARE

Age/Gender : 53 Y/M

Suggest – clinical correlation.

(The sonography findings should always be considered in correlation with the clinical and other investigation finding where applicable.) It is only a professional opinion, not valid for medico legal purpose.



Dr. SUHAS SANJEEV KATHURIA
MBBS,DMRE, RADIOLOGY

Radiology

Patient Name : Mr. SRINATH M R

Age/Gender : 54 Y/M

UHID/MR No. : CBAS.0000090300

OP Visit No : CBASOPV97211

Sample Collected on :

Reported on : 27-11-2023 10:10

LRN# : RAD2159723

Specimen :

Ref Doctor : SELF

Emp/Auth/TPA ID : 277258

DEPARTMENT OF RADIOLOGY

X-RAY CHEST PA

Both lungs fields appears normal and shows normal bronchovascular markings.

Bilateral hila appears normal.

Cardiac silhouette appears normal.

Both costophrenic and cardiophrenic angles are clear.

Both diaphragms are normal in position and contour.

Thoracic wall and soft tissues appear normal.

IMPRESSION:

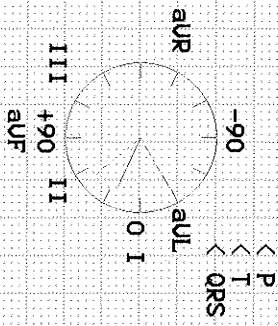
No obvious abnormality seen in the present study.



Dr. V K PRNAV VENKATESH
MBBS,MD
Radiology

Measurement Results:

QRS	100 ms
QT/QTcB	372 / 430 ms
PR	150 ms
P	118 ms
RR/PP	748 / 730 ms
P/ORS/T	50 / 25 / -30 degrees
QTd/QTcBd	46 / 53 ms
Sokolow	1.5 mV
NK	12



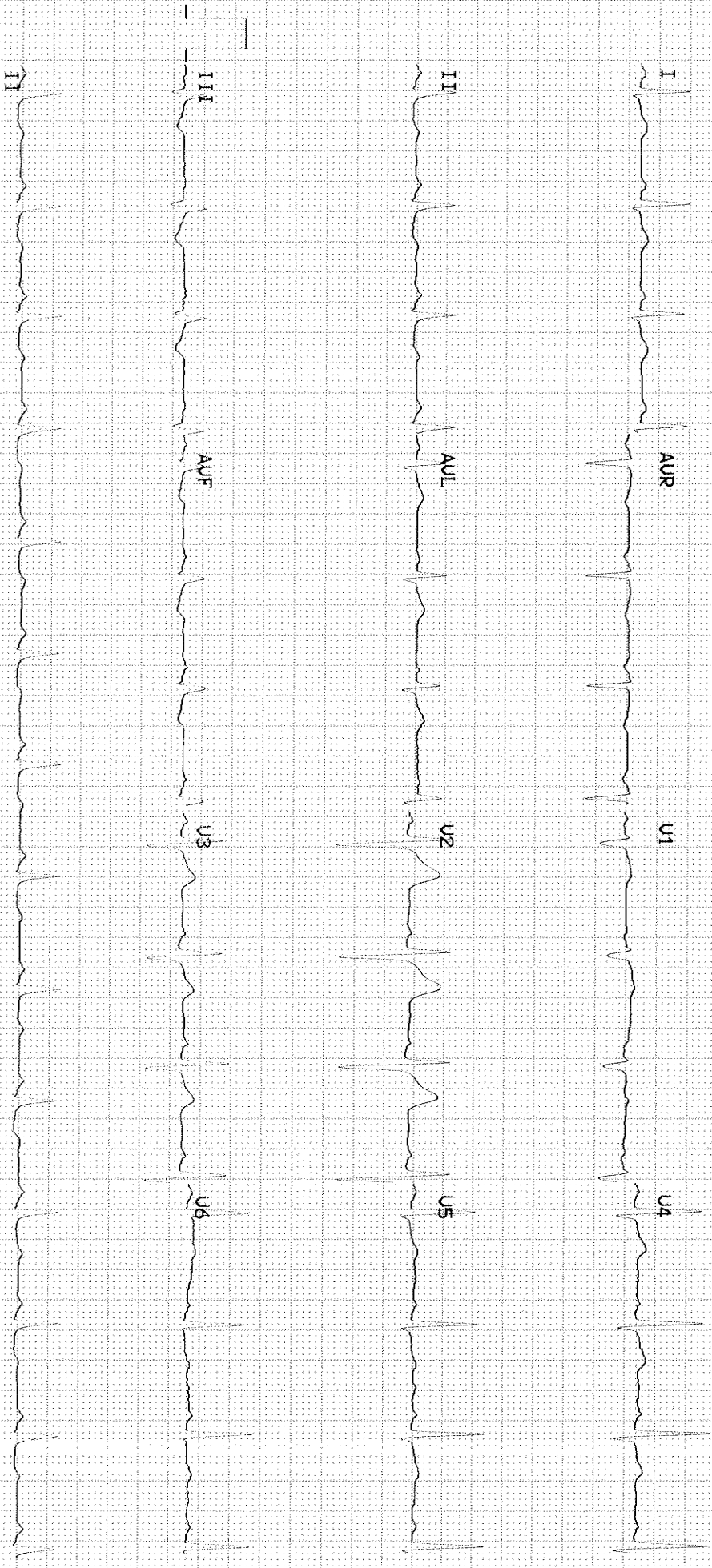
Interpretation:


no wave & III
 no significant ST-Tabnormality

Apollo Clinic

2nd Floor, Chhatrapati Shivaji Maharaj
 Hospital, Sion, Mumbai - 400 022

Unconfirmed report.



Name : Mr. SRKANTH <i>Srikanth M.R</i> Address : BLR Plan : ARCOFEMI MEDIWHEEL MALE AHC CREDIT PAN INDIA OP AGREEMENT	Age : 54 Y Sex : M	UHID :CBAS.0000090300  OP Number :CBASOPV97211 Bill No :CBAS-OCR-59151 Date : 25.11.2023 09:01
---	-------------------------------------	--

Sno	Service Type/ServiceName	Department
1	ARCOFEMI - MEDIWHEEL - FULL BODY STANDARD PLUS MALE - PAN INDIA - FY2324	
<input checked="" type="checkbox"/>	GAMMA GLUTAMYL TRANSFERASE (GGT)	
<input checked="" type="checkbox"/>	HbA1c, GLYCATED HEMOGLOBIN	
<input checked="" type="checkbox"/>	LIVER FUNCTION TEST (LFT)	
<input checked="" type="checkbox"/>	X-RAY CHEST PA	
<input checked="" type="checkbox"/>	GLUCOSE, FASTING	
<input checked="" type="checkbox"/>	HEMOGRAM + PERIPHERAL SMEAR	
<input checked="" type="checkbox"/>	FITNESS BY GENERAL PHYSICIAN -	
<input checked="" type="checkbox"/>	COMPLETE URINE EXAMINATION	
<input checked="" type="checkbox"/>	PERIPHERAL SMEAR	
<input checked="" type="checkbox"/>	ECG + Echo	
<input checked="" type="checkbox"/>	BLOOD GROUP ABO AND RH FACTOR	
<input checked="" type="checkbox"/>	LIPID PROFILE	
<input checked="" type="checkbox"/>	BODY MASS INDEX (BMI)	
<input checked="" type="checkbox"/>	OPHTHAL BY GENERAL PHYSICIAN B2	
<input checked="" type="checkbox"/>	RENAL PROFILE/RENAL FUNCTION TEST (RFT/KFT)	
<input checked="" type="checkbox"/>	THYROID PROFILE (TOTAL T3, TOTAL T4, TSH)	
<input checked="" type="checkbox"/>	GLUCOSE, POST PRANDIAL (PP), 2 HOURS (POST MEAL)	

Dental
Physio

2DEcho →

BP - 130/70
 PE - 96
 Wt - 96
 WtH - 88.3
 H5gh - 79
 Wtgh - 173.

54years
Male

Asian
79kg

Vent. rate 97 bpm
PR interval 144 ms
QRS duration 80 ms

QT/QTc 342/434 ms
P-R-T axes 71 69 52
BP 130/70mmHg

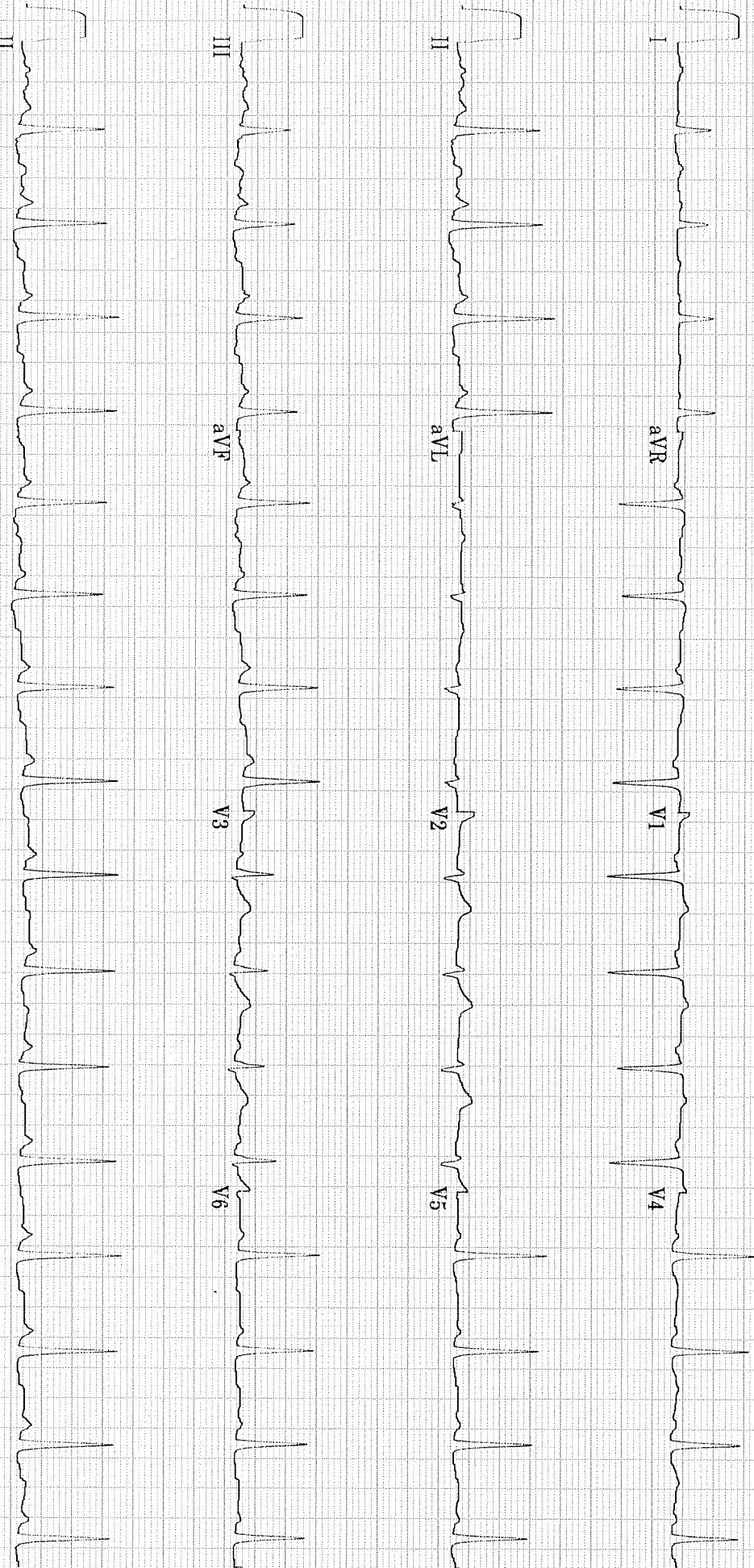
Normal sinus rhythm
Nonspecific T wave abnormality
Abnormal ECG

Technician:
Test ind:

Meds: BLOOD THINNER
HYPERTENSION

Referred by: AROCIMI

Unconfirmed



20 Hz 25.0 mm/s 10.0 mm/mV

4 by 2.5s + 1 rhythm Id

MAC55 009A

12SL™ V237

Mr. SRINATH
64/M

Dr Anukritha Puarink
MBBS, MS, DNB, FRCO.

Height :	Weight :	BMI :	Waist Circum :
Temp :	Pulse :	Resp :	B.P :

General Examination / Allergies
History

Clinical Diagnosis & Management Plan

Came for regular health check up.

→ post opent - 3 1/2 years
HTN / DM / Dyslipidemia :- 10 years &
is on Rx.

ofc: Ear }
Nose }
Throat } was

Adv: regular follow up.

Follow up date:

Doctor Signature

Mr. Swinath M R 54/M 90300 25/11/23

EYE CHECK UP REPORT

Vision Acuity $\left\{ \begin{array}{l} 6/6 \\ \text{unaided} \\ 6/6 \end{array} \right.$

Digital IOP $\left\{ \begin{array}{l} \text{N} \\ \text{N} \end{array} \right.$

Near Vision $\left\{ \begin{array}{l} \text{N6} \\ \text{egbar} \\ \text{N6} \end{array} \right.$

Colour Vision $\left\{ \begin{array}{l} \text{Normal} \\ \text{Normal} \end{array} \right.$

• Fundus: Normal @ study

• Ant. Segment :- LNM

• Media: Normal

• Pupil: normal

BC - pseudophakia

BC + 2.50, SPH N6, Adv glasses for near

Reading vision only

KAS



ಭಾರತೀಯ ವಿಶಿಷ್ಟ ಗುರುತಿನ ಪ್ರಾಧಿಕಾರ

ಭಾರತ ಸರ್ಕಾರ
Unique Identification Authority of India
Government of India

ನೋಂದಾವಣೆ ಕ್ರಮ ಸಂಖ್ಯೆ / Enrollment No.: 1208/71019/07075

To
ಶ್ರೀನಾಥ್ ಎಮ್ ಆರ್
Srinath M R
S/O: M Ramachandra Rao
#796 Brigadier Gokhale Road
Near Rangamandira 3rd Stage BEML Layout
Rajarajeshwarinagar Bangalore South
Rajarajeshwarinagar Bangalore South Bangalore
Karnataka 560098
9980565624

02/12/2012

11755763



MN117557630DF



ನಿಮ್ಮ ಆಧಾರ್ ಸಂಖ್ಯೆ / Your Aadhaar No. :

5246 2194 9381

ಆಧಾರ್ - ಶ್ರೀನಾಥ್ ಎಮ್ ಆರ್



ಭಾರತ ಸರ್ಕಾರ
GOVERNMENT OF INDIA



ಶ್ರೀನಾಥ್ ಎಮ್ ಆರ್
Srinath M R
ಹುಟ್ಟಿದ ವರ್ಷ / Year of Birth : 1969
ಪುರುಷ / Male



5246 2194 9381

Address of Diagnostic/Hospital- Apollo Clinic, # 99, Bull Temple Road , Next to Ramakrishna mutt, Basavanagudi - 560019
City : Bangalore
State :
Pincode : 560019
Appointment Date : 25-11-2023
Confirmation Status : Booking Confirmed
Preferred Time : 8:30am-9:30am
Booking Status : Booking Confirmed

Member Information		
Booked Member Name	Age	Gender
Lathas s	48 year	Female
SRINATH M R	54 year	Male

Note - Please note to not pay any amount .

Instructions to undergo Health Check:

- Please ensure you are on complete fasting for 10-To-12-Hours prior to check.
- During fasting time do not take any kind of medication, alcohol, cigarettes, tobacco or any other liquids (except Water) in the morning.
- Bring urine sample in a container if possible (containers are available at the Health Check centre).
- Please bring all your medical prescriptions and previous health medical records with you.
- Kindly inform the health check reception in case if you have a history of diabetes and cardiac problems.

For Women:

- Pregnant Women or those suspecting are advised not to undergo any X-Ray test.
- It is advisable not to undergo any Health Check during menstrual cycle.

Request you to reach half an hour before the scheduled time.

In case of further assistance, Please reach out to Team Mediwheel.

Note- Please do not pay any amount at the time of check up.

Thanks,
Mediwheel Team

You have received this mail because your e-mail ID is registered with This is a system-generated e-mail **Arcofemi Healthcare Limited**, please don't reply to this

Name: Mr. AJAY DONGARE
Age/Gender: 53 Y/M
Address: PUNE
Location: PUNE, MAHARASHTRA
Doctor:
Department: GENERAL
Rate Plan: AUNDH_06042023
Sponsor: ARCOFEMI HEALTHCARE LIMITED
Consulting Doctor: Dr. RUCHIKA SRIVASTAVA

MR No: CAUN.0000138325
Visit ID: CAUNOPV162796
Visit Date: 27-11-2023 11:06
Discharge Date:
Referred By: SELF

HT-CHIEF COMPLAINTS AND PRESENT KNOWN ILLNESS

SYSTEMIC REVIEW

HT-HISTORY

PHYSICAL EXAMINATION

SYSTEMIC EXAMINATION

IMPRESSION

RECOMMENDATION

Doctor's Signature

Name: Mr. AJAY DONGARE
Age/Gender: 53 Y/M
Address: PUNE
Location: PUNE, MAHARASHTRA
Doctor:
Department: GENERAL
Rate Plan: AUNDH_06042023
Sponsor: ARCOFEMI HEALTHCARE LIMITED
Consulting Doctor: Dr. BALKRISHNA SURYAKANTRAO RANGDAL

MR No: CAUN.0000138325
Visit ID: CAUNOPV162796
Visit Date: 27-11-2023 11:06
Discharge Date:
Referred By: SELF

Doctor's Signature

Name: Mr. AJAY DONGARE
Age/Gender: 53 Y/M
Address: PUNE
Location: PUNE, MAHARASHTRA
Doctor:
Department: GENERAL
Rate Plan: AUNDH_06042023
Sponsor: ARCOFEMI HEALTHCARE LIMITED
Consulting Doctor: Dr. PADMA RAJENDRA ITHAPE

MR No: CAUN.0000138325
Visit ID: CAUNOPV162796
Visit Date: 27-11-2023 11:06
Discharge Date:
Referred By: SELF

HT-CHIEF COMPLAINTS AND PRESENT KNOWN ILLNESS

SYSTEMIC REVIEW

HT-HISTORY

PHYSICAL EXAMINATION

SYSTEMIC EXAMINATION

IMPRESSION

RECOMMENDATION

Doctor's Signature