

(methi powder)

SAMPLE MENU PLAN

DIET:

2 glass warm water (onea)

ON - RISING 6.00 - 6.30 am	Milk / coffee/ tea (sugarless) = (100ml)
BREAKFAST 8.00 - 8.30 am <i>Salad sprouts</i>	Idly (2 nos) OR mix dhal dosa (2 nos) OR vegetable upma (bansi) 100gms OR Phoha 100gms OR oats uppma (1 small cup).
MID - MORNING 11 - 11.30 am	Fruit (100 grams) with chia seed (1 tsp) or soaked peanuts (15 nos) OR Makanna (unsalted)50 gms OR butter milk (200ml)
LUNCH 1.00 - 2.00 pm	Jowar / wheat roti : 1small + Red rice : 50 gms + cooked vegetables : 100 gms + raw salad : 100gms + cooked p ulses 50 gms / lean chicken 50 gms / soya chunks 30gms curds : 100ml
EVENING 4.00 - 5.00 pm	Green tea / coffee / tea 100 mixed sprouts salad (1 cup) OR Nuts (mixed 10 nos) soaked over night OR
DINNER 7.30 - 8.00 pm	Jowar roti : 2 nos + vegetable: 2 cup OR Brown rice 100gms + Thick dhal (50 gms) + vegetable (100 gms)
BED TIME 10 pm	Low fat milk with termeric (100ml)

POINTS TO REMEMBER

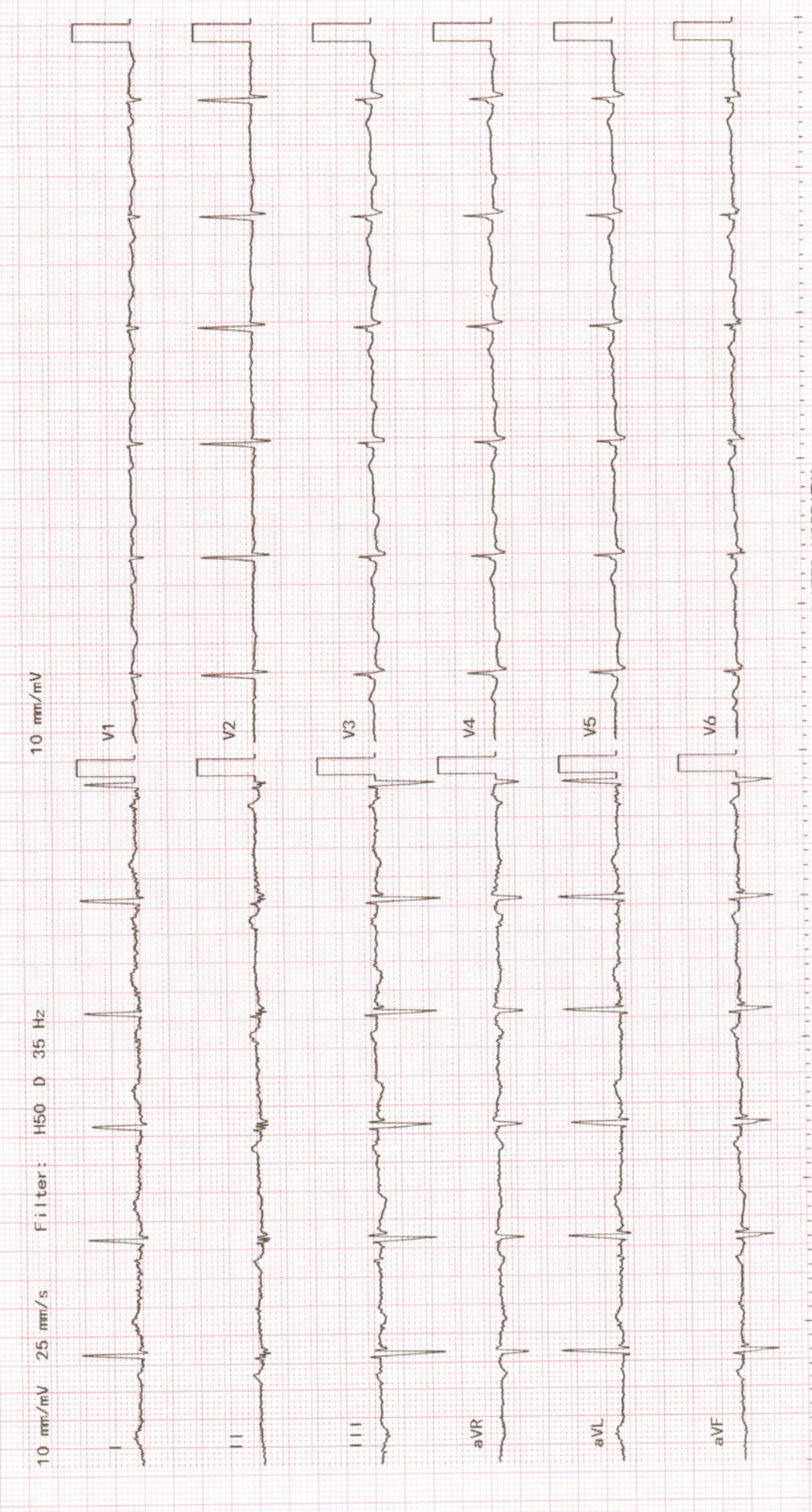
- Control portion size, eat bit sized small pices and chew food slowly
- Maintain a gap of 2 to 3 hours between your dinner and sleeping time.
- Consume oil in limited quantity only. (3 to 4tsp / day). - coonut oil / ghee
- Exercise regularly atleast 30 mits per day.
- Add variety of vegetables in each of your main meal . Always include salads for lunch and dinner.

POORNIMA.H

ID: 24005798
 Name: MRS BASANTI
 Birth date: /
 ex: cm kg mmHg
 66 years

Indication: Sinus rhythm
 Symptoms: Nonspecific Twave abnormality [flat T or negative T (V4, V5)]
 History: Abnormal left axis deviation [-90 deg. < QRS axis < -30 deg.]
 1100 9130
 4068 ** borderline ECG **
 7200

Unconfirmed Report
 Reviewed by:





Out Patient Record

NABH No.1
Patient Name : Mrs.BASANTI BISWAL

UHID : UHJA24005798

Age / Sex : 66 Years / Female

OP NO/Reg Dt : 21-09-2024 09:25 AM

Spouse / Father Name : SUKANT KUMAR BISWAL

Department :

Address : 327, DS MAN SAANJH AKSHAY NAGAR
BEGURU, , Bengaluru Urban, Karnataka,

Referred By :

Consultant : Dr.Preventive Health Check Up

KMC No. :

Complaints / Findings / Observations :

SpO2 = 96%
PA = 72.5m
Bp = 120/70
WT = 65 kg

Investigations:

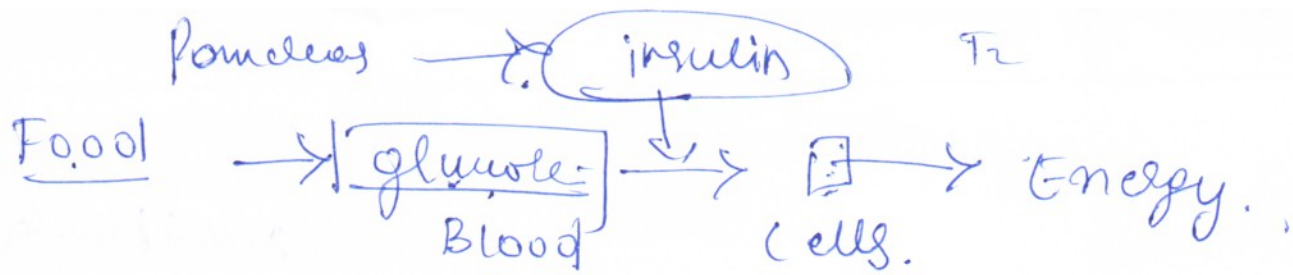
HbA1c - 6.6%
Hb - 10.5%

Treatment / Care of Plan / Provisional Diagnosis :

R
tab. Glyconet (R Long
1-0-0.

Follow Up Advice :

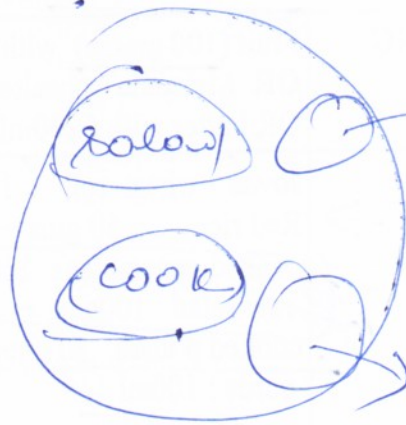
Signature of the Doctor



- ① Diet ② Exercise ③ Stress ④ Medication ⑤ Monitoring

Fasting (100-120) 2H after food (150-170)
 HbA1C [< 6.5% - 6.5%]

Fiber
 Vegetables. (3 types)
 leafy-greens.
 asprouts
 (Methi 2 tsp)



Protein
 pulses, /phal.
 Paneer / Soya chunky

Carbohydrate
 Gud Rice (Gru. Sood)

Avoid
 Sweets
 Bakery foods.
 Junk foods.
 carbonating drinks.

Jowar / Bajra / Ragi /
 Jowar.



Out Patient Record

NABH No.1 Patient Name : Mrs.BASANTI BISWAL

UHID : UHJA24005798

Age / Sex : 66 Years / Female

OP NO/Reg Dt : 21-09-2024 09:25 AM

Spouse / Father Name : SUKANT KUMAR BISWAL

Department :

Address : 327, DS MAN SAANJH AKSHAY NAGAR BEGURU, , Bengaluru Urban, Karnataka,

Referred By :

optical

Consultant : Dr.Preventive Health Check Up

KMC No. :

Complaints / Findings / Observations :

Investigations: *Vh* } *g/6p* } *g/6p* } *Mb.* *DM - Predictable*

Mg ov normal

Treatment / Care of Plan / Provisional Diagnosis :

Fund's ov c/d to 0.3°1 (added) (R+L)

Follow Up Advice : *If: ov R/L Eye. Continue same glass.*

Signature of the Doctor
[Signature]
21/9/24.



Out Patient Record

Care Par Excellence
Jayanagar, Bangalore

NABH No.1
Patient Name : Mrs.BASANTI BISWAL

UHID : UHJA24005798

Age / Sex : 66 Years / Female

OP NO/Reg Dt : 21-09-2024 09:25 AM

Spouse / Father Name : SUKANT KUMAR BISWAL

Department : *Gynae*

Address : 327, DS MAN SAANJH AKSHAY NAGAR
BEGURU, , Bengaluru Urban, Karnataka,

Referred By :

Consultant : Dr.Preventive Health Check Up

KMC No. :

Complaints / Findings / Observations :

Investigations:

Re Lab done H/O
14/06. As per → On H/O
100 u/ sm, thr, sy
Dr. Yoga Lakshmi SK
MBBS, MS OBG, FMAS
Consultant Obstetrics and
Gynecologist, Laparoscopic
and IVF Specialist
KMC Reg. No. 90384
BP-102
67

Treatment / Care of Plan / Provisional Diagnosis :

ex by
H. post hyster
VH
act. treatment
mepa-50g

Follow Up Advice :

no h. any fever

No
Dr
Dr

Dr
Dr

Signature of the Doctor



NABH



No.1



DEPARTMENT OF RADIODIAGNOSIS

Name	Basanti Biswal	Date	21/09/24
Age	66 years	Hospital ID	UHJA24005798
Sex	Female	Ref.	Health check

RADIOGRAPH OF THE CHEST (PA – VIEW)

FINDINGS:

Bilateral lung fields are normal.

Bilateral costo-phrenic angles are normal.

Mild cardiomegaly is seen.

The bony thorax is grossly normal.

IMPRESSION:

- Mild cardiomegaly.
- No other significant radiographic abnormality.

Dr. Elluru Santosh Kumar
Consultant Radiologist



DEPARTMENT OF RADIODIAGNOSIS

Name	Basanti Biswal	Date	21/09/24
Age	66 years	Hospital ID	UHJA24005798
Sex	Female	Ref.	Health check

ULTRASOUND ABDOMEN AND PELVIS

FINDINGS:

Liver is enlarged in size (16.4 cms) and shows moderately increased echopattern. No intra or extra hepatic biliary duct dilatation. No focal lesions. **Portal vein** is normal in size, course and caliber. **CBD** is not dilated.

Gall bladder is normal without evidence of calculi, wall thickening or pericholecystic fluid.

Pancreas - Visualized part of the pancreatic head and body appears normal in size, contour and echogenicity. Rest of the pancreas is obscured by bowel gas.

Spleen is normal in size, shape, contour and echopattern. No evidence of mass or focal lesions.

Right Kidney is normal in size (10.1 x 3.4 cms), position, shape and echopattern. Corticomedullary differentiation is maintained. No evidence of calculi or hydronephrosis.

Left Kidney is normal in size (10.6 x 3.9 cms), position, shape and echopattern. Corticomedullary differentiation is maintained. No evidence of calculi or hydronephrosis.

Retroperitoneum- Visualized aorta appeared normal. No obvious enlarged para-aortic nodes.

Urinary Bladder is distended, normal in contour and wall thickness. No evidence of calculi.

Uterus is surgically absent.

Both ovaries could not be visualized.

There is no ascites or pleural effusion. Appendix could not be localized. No RIF probe tenderness.

IMPRESSION:

- Mild hepatomegaly with moderate fatty infiltration (Grade II).
- No other definite sonological abnormality detected.

Dr. Elluru Santosh Kumar
Consultant Radiologist



Out Patient Record

NABH No.1
Patient Name : Mrs.BASANTI BISWAL
Age / Sex : 66 Years / Female
Spouse / Father Name : SUKANT KUMAR BISWAL
Address : 327, DS MAN SAANJH AKSHAY NAGAR
BEGURU, , Bengaluru Urban, Karnataka,

UHID : UHJA24005798
OP NO/Reg Dt : 21-09-2024 09:25 AM
Department :
Referred By :
Consultant : Dr.Preventive Health Check Up
KMC No. :

Complaints / Findings / Observations :

HT: 157. Cm
WT: 64.3kg
SpO₂: 97.1.
PR: 80 bpm
Bp: 102/63
mmHg

Investigations:

Treatment / Care of Plan / Provisional Diagnosis :

Follow Up Advice :

Signature of the Doctor



NABH



No.1



DEPARTMENT OF RADIODIAGNOSIS

Name	Basanti Biswal	Date	21/09/24
Age	66 years	Hospital ID	UHJA24005798
Sex	Female	Ref.	Health check

BILATERAL SONOMAMMOGRAPHY

FINDINGS:

Skin and subcutaneous fat of bilateral breasts appear normal.
Homogeneous fatty background echotexture is seen in both breasts.
No focal solid / cystic lesions seen.
Ducts appear normal.
No significant lymphnodes noted in bilateral axilla.

IMPRESSION: *Suboptimal evaluation due to large fatty breasts.*

- **No significant abnormality detected in this study.**

Note: *X-ray mammography is the investigation of choice for screening of breast cancer, especially in large fatty breasts.*

Dr. Elluru Santosh Kumar
Consultant Radiologist