


**भारतीय पहचान अधिकारिता**  
**Unique Identification Authority of India**



**पता:**  
 S/O शंकर प्रसाद साह, बलु तोला, गार्ल हाई विद्यालय के पास, वार्ड नं-08, कास्ता, पुर्निया, कास्ता, पुर्निया, बिहार - 854330

**Address:**  
 S/O Shankar Prasad Sah, belu tola, near girls high school, ward no-08, kasba, purnia, Kasba, Purnia, Bihar - 854330




**6679 9665 5873**  
**VID : 9195 1383 7420 9729**

1947 | [help@uidai.gov.in](mailto:help@uidai.gov.in) | [www.uidai.gov.in](http://www.uidai.gov.in)


**भारत सरकार**  
**Government of India**

**शंकर प्रसाद साह**  
 Ramchandra Sah  
 854330/08 16/08/1983  
 पुरुष/MALE



**6679 9665 5873**  
**VID : 9195 1383 7420 9729**

**मेरा आधार, मेरी पहचान**

RAMCHANDRA SAH

Male  
Years

HR : 76 bpm

P : 95 ms

PR : 154 ms

QRS : 84 ms

QT/QTc : 339/383 ms

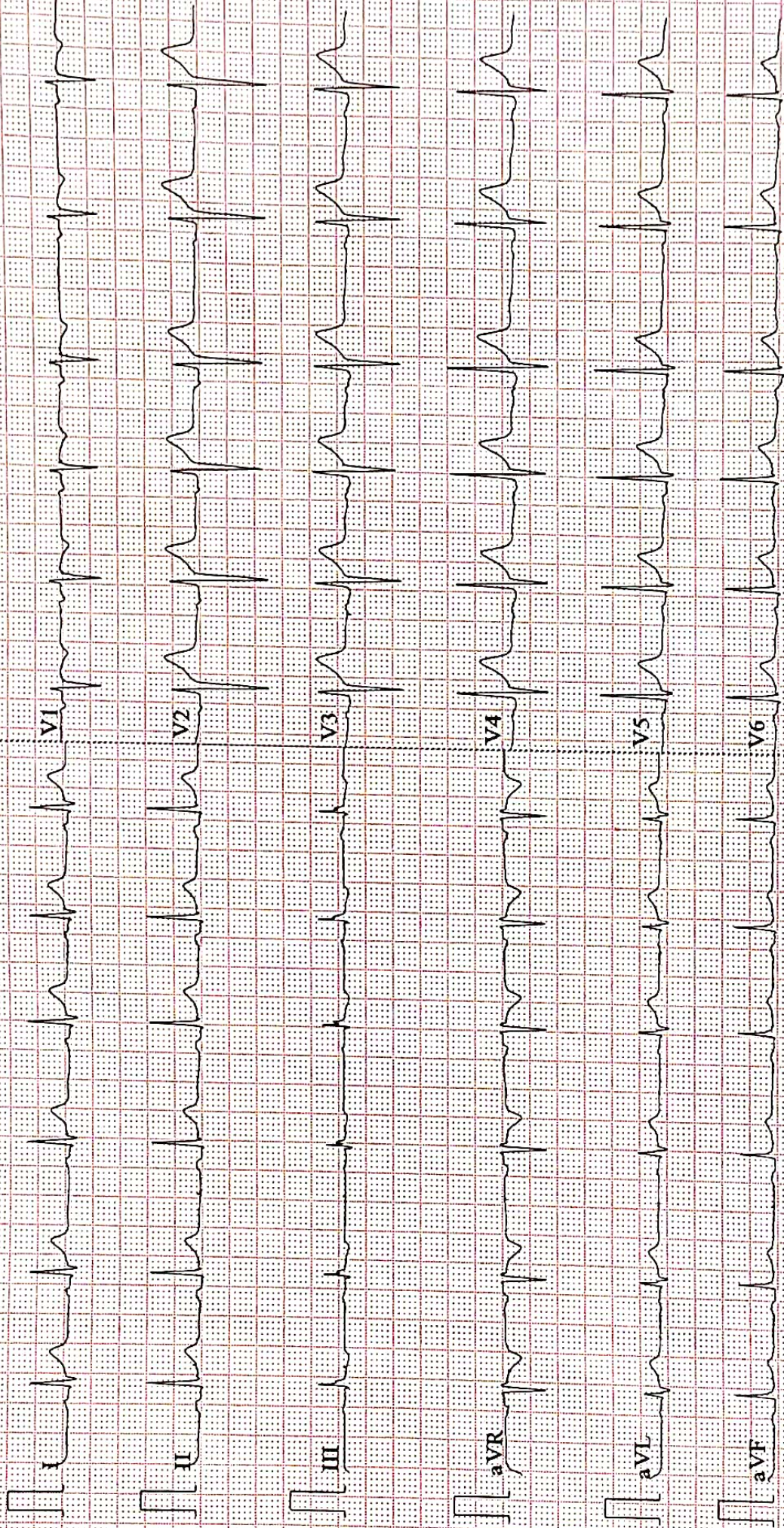
P/QRS/T : 53/51/18 °

RV5/SV1 : 1.234/0.692 mV

Diagnosis Information:

Sinus Arrhythmia

Report Confirmed by:





# SUBHAM IMAGING & A.L.C. DIAGNOSTICS CENTRE

H.O. : Ajay Market, Dena Bank Building, East Adhok Nagar, Kankarbagh, Patna - 70

B.O. : Khanpura Road (Below Gyan Sherawat School), Patliganj, Patna.

e-mail : subham.pat.usg@gmail.com # website : www.abheshincheckup.in

OPINION MUST BE CORRELATES WITH CLINICAL & OTHER INVESTIGATION FOR DIAGNOSIS NOT FOR PREVENTIVE, CURATIVE PURPOSE.

Pt. Name :- RAMCHANDAR SAH  
Ref. By :- DR. B O B AAROGYAM

Date :- 22-Jul-21  
Age / Sex :- 37 Yrs. M.

## REAL TIME U.S.G. OF WHOLE ABDOMEN

Thanks for your kind referral

(Report.)

- LIVER** :- Measures 15.26 cm. Mild Enlarged in shape, size and echo texture fatty change seen in liver parenchyma. I.H.B.R. are not dilated.  
Hepatic veins are normal. No SOL seen.
- G.BL.** :- Lumen is echo free. Wall thickness appears normal.
- C.B.D.** :- Measures 3.5 mm in diameter with echo free lumen. No calculi or mass seen.
- P.V.** :- Measures 7.7 mm in diameter. Appears normal. No thrombus seen.
- PANCREAS** :- Normal in shape, size and echo texture. No calcification mass seen.
- SPLEEN** :- Measures 11.15 cm. Normal in shape, size and echo texture.  
No SOL seen.
- KIDNEY** :- Both kidney shows normal shape, size & echotexture. C.M.D.intact.  
P.C.S.is not dilated.  
*Right Kidney :- Measures 9.0 X 3.50 cm.*  
*Left Kidney :- Measures 9.10 X 3.50 cm.*
- URETER** :- Not dilated. No apparent calculi seen.
- U.BLADDER** :- Shows normal in outline with echo free lumen. No calculi or mass seen.  
*Pre void - 320 ml. Post void - is in significant*
- PROSTATE** :- Measures 15 gms.(approx). Appears Normal in size, shape, and echo texture.  
No calcification, mass, growth seen. capsule is intact.
- R.I.F.** :- Son graphically no appendicular mass or collection seen.
- OTHERS** :- Excess Gasses bowel distention seen in Abdomen. No Ascites No Lymph Adenopathy. No pleural Effusion seen on either side

## IMPRESSION

- Mild Hepatomegaly With fatty liver G-I
- Excess Gasses bowel distention seen in Abdomen
- Adv:- Further work up other investigation  
Otherwise son graphically normal scan. of rest organs

20/7/21

Consultant Radiologist

ESTD BY:-

**Dr. P. K. Tiwari**  
MD, BRIT (Radio Imaging)  
Consultant Imaginologist & Sonologist  
A.L.C. Diagnostics & Research Centre, Patna

**Dr. S. Kumar**  
MD. (Pat)  
Consultant Pathologist

**Dr. A. K. Singh**  
MBBS, PGDIPLOMA  
Consultant Radiologist & Sonologist