



भारत सरकार



आधार

भारत सरकार
Government of India

भारतीय विशिष्ट पहचान प्राधिकरण
Unique Identification Authority of India


नामांकन क्रम / Enrollment No. : 0013/05005/25191

To
Ravi Raj Yadav
रवि राज यादव
C/O: Ramesh Kumar,
P-29,
Priyadarshini Paramount,
Near Ashima Mall Hoshangabad Road,
VTC: Bhopal, PO: University,
Sub District: Huzur, District: Bhopal,
State: Madhya Pradesh, PIN Code: 462026,
Mobile: 9630188762

28821910



KF288219108FI



(Handwritten signature)

आपका आधार क्रमांक / Your Aadhaar No. :

9827 6919 0822

मेरा आधार, मेरी पहचान



भारत सरकार
Government of India



आधार

Issue Date: 14/01/2012



रवि राज यादव
Ravi Raj Yadav
जन्म तिथि / DOB: 17/06/1977
पुरुष / Male

Dr. B. M. Agarwal
MBBS, DCP
Consultant Pathologist

9827 6919 0822

मेरा आधार मेरी पहचान

Scanned with CamScanner



Scanned with CamScanner



दिवकर डायग्नोस्टिक सेंटर

E-7/636, पंजाब नेशनल बैंक के पास, मैन रोड, अरेरा कॉलोनी भोपाल (म.प्र.)


फोन: 0755-2465288, 0755-3520545 मो: 9826340190

Pt Name :	Mr. Ravi Raj Yadav
Age :	45/M
Ref.By :	BOB
Lab. No. :	291
Date :	25/06/2022

EXAMINATION OF BLOOD

TEST	RESULT	NORMAL VALUE
Haemoglobin	16.2mgs%	Female 12-16gms%, Male 14-18gms%
Red Cell count	5.1	4.5-5.6 million /cumm
Platelet Count	2.89	1.5-5.6 Lac/cumm
Leucocytes per.cu.mm	7600/cumm	5000-11000/cumm
Neutrophils	58%	50-70%
Lymphocytes	32%	20-40%
Eosinophils	06%	0-7%
Monocytes	05%	2-8%
PCV	40.3	37-47
MCV	84.6	76-96
MCH	30.2	27-32
MCHC	32.0	31-35
ESR	06	Male 0-9, Female 0-20mm/FHR
Blood Group	"O" Positive	By Slide Method
S.Bilirubin(Total)	0.86	0.2-1.0mg/dl
Direct	0.32	0.0-0.25mg/dl
Indirect	0.54	
SGOT	31.6	5-35U/L
SGPT	38.5	8-40U/L
Alk Phosphatase	10.4	3-13 KA units
S. Protein(Total)	7.0	6.0-8.0mg%
Albumin	4.0	3.7-5.3mg%
Globulin	3.0	1.5 to 3.5 mg%
AG Ratio	1.23	1.-2.0
Blood Urea Nitrogen (BUN)	15.1	7-20 mg/dl
S.Creatine	1.0	0.5-1.4mg/dl
Uric Acid	5.8	4.8 to 7.5 mg/dl
Calcium	9.1	8.5-10.5 gm/dl
GGTP	32.8	5-35 UL/dl
Fasting Blood Sugar	85.9	70 to 110mg/dl
Post Prandial Blood Sugar	139.6	Up to 150mg/dl
Total Serum Cholesterol	184.6	100-250 mg%
Serum Triglyceride	178.8	Up to 160 mg%
Serum Cholesterol HDL	48.0	Up to 65 mg%
Serum Cholesterol LDL	100.8	Up to 125 mg%
VLDL	35.7	Up to 30 mg%
TC/HDL Ratio	3.38	Bellow 5
Glycosylated Hemoglobin HBA1c	5.8	Below - 6.0 % -Non Diabetic control 6-7 % -Excellent control Above- 8 % -Poor control

All test have technical limitation. Collaborative clinic pathological interpretation is mandatory. In case of disparity test may be repeated immediately. Typographical mistakes should be get correct instantly. This report is not valid for medico legal purpose



Dr. B. W. Agarwal
MBBS, DCP
Consultant Pathologist



दिवाकर डायग्नोस्टिक सेंटर

E-7/636, पंजाब नेशनल बैंक के पास, मैन रोड, अरेरा कॉलोनी भोपाल (म.प्र.)

फोन: 0755-2465288, 0755-3520545 मो: 9826340190

Pt Name :	Mr. Ravi Raj Yadav
Age :	45/M
Ref.By :	BOB
Lab. No. :	291
Date :	25/06/2022

URINE ANALYSIS

<u>A. PHYSICALEXAMINATION</u>		<u>C. MICROSCOPIEXAMINATION</u>	
1. Colour	Yellow	Pus Cells	2-4/HPF
2. Appearance	Clear	R.B.C.	Nil
3. Specific Gravity	Q.N.S.	Epithelial Cell	occ/HPF
<u>B. CHEMICAL EXAMINATION</u>		Cast	Nil
1.Reaction	Acidic	Crystals(Cal.Oxa)	Nil
2.Albumin	Absent	Bacteria	Nil
3.Sugar	Nil	Amorphous	Nil
4.Bile Salts	Absent	T. Vaginitis	Nil

URINE COTININE	Negative	By Card method
----------------	----------	----------------



Dr. B. M. Agarwal
MBBS, DCP
Consultant Pathologist

All test have technical limitation. Collaborative clinic pathological interpretation is mandatory. In case of disparity test may be repeated immediately. Typographical mistakes should be get correct instantly. This report is not valid for medico legal purpose



दिवकर डायग्नोस्टिक सेंटर

E-7/636, पंजाब नेशनल बैंक के पास, मैन रोड, अरेरा कॉलोनी भोपाल (म.प्र.)

फोन: 0755-2465288, 0755-3520545 मो: 9826340190

Pt Name :	Mr. Ravi Raj Yadav
Age :	45/M
Ref.By :	BOB
Lab. No. :	291
Date :	25/06/2022
Skigram	X Ray Chest PA View
Radiologist	Dr. B.M.Agarwal MD (Radiology)

REPORT

Tricia Central

Thoracic cage normal

Both Lungs Field Clear.

Both hilers normal

Cardiac border normal

Both cp angles clear

Both domes and diaphragm normal

IMPRESSION

-NO CARDIO PULMONARY PATHOLOGY

-COORELATE WITH CLINICAL FINDINGS.

Dr. B. M. Agarwal
MD, Radiology
Consultant Radiologist
Radiologist





दिवाकर डायग्नोस्टिक सेंटर

E-7/636, पंजाब नेशनल बैंक के पास, मैन रोड, अरेरा कॉलोनी भोपाल (म.प्र.)

फोन: 0755-2465288, 0755-3520545 मो: 9826340190

Pt Name :	Mr. Ravi Raj Yadav
Age :	45/M
Ref.By :	BOB
Lab. No. :	291
Date :	25/06/2022

EXAMINATION OF BLOOD

Thyroid profile

<u>TEST</u>	<u>RESULT</u>	<u>NORMAL VALUE</u>
T3 - TOTAL	94.1	82-213 ng/dL
T4 - TOTAL	6.89	6.09-12.23 ug/dL
THYROID STIMULATING HORMONE (TSH)	1.82	0.45-4.25 ul/mL

Interpretation:

TSH Levels will be elevated in primary hypothyroidism, TSH levels will be low in Hyperthyroidism there is decreased production of thyroid hormones by the thyroid hence the person may experience symptoms such as weight gain, constipation, cold intolerance and fatigue. Iodine deficiency and Hashimoto thyroiditis is the most common cause of hypothyroidism It makes Thyroid stimulating hormone. If TSH levels are abnormally high it could mean you have an underactive thyroid or hypothyroidism.



Dr. B. M. Agarwal
MBBS, DCP
Consultant Pathologist

All test have technical limitation. Collaborative clinic pathological interpretation is mandatory. In case of disparity test may be repeated immediately. Typographical mistakes should be get correct instantly. This report is not valid for medico legal purpose.



द्विवाकर डायग्नोस्टिक सेंटर


E-7/636, पंजाब नेशनल बैंक के पास, मैन रोड, अरेरा कॉलोनी भोपाल (म.प्र.)

फोन: 0755-2465288, 0755-3520545 मो: 9826340190

Pt Name :	Mr. Ravi Raj Yadav
Age :	45/M
Ref.By :	BOB
Lab. No. :	291
Date :	25/06/2022

EXAMINATION OF BLOOD

<u>TEST</u>	<u>RESULT</u>	<u>NORMAL VALUE</u>
PSA	4.96 ng/ml.	0.21-6.77 ng/ml.

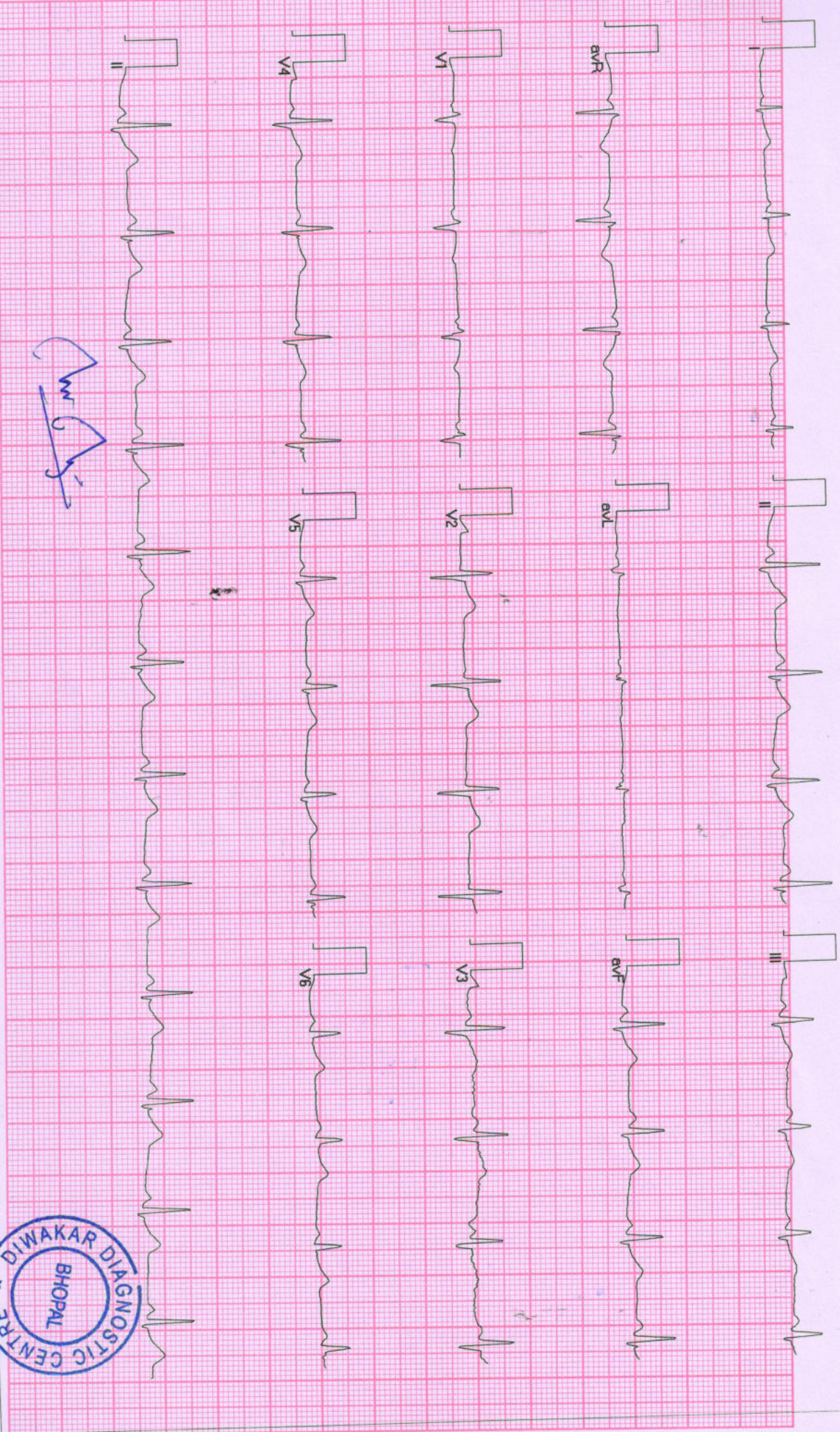

Dr. B. M. Agarwal
MBBS, DCP
Consultant Pathologist
Pathologist

All test have technical limitation. Collaborative clinic pathological interpretation is mandatory. In case of disparity test may be repeated immediately. Typographical mistakes should be get correct instantly. This report is not valid for medico legal purpose






BPL-DYNATRAC



Handwritten signature





डॉ. सविता क्लिनिक

34, भूतल, मोहिनी अदिति आर्केड, शाहपुरा मस्जिद के पास
भरत नगर रोड, ई-7/194, अरेरा कॉलोनी, भोपाल - 462038

Mob. : 8989649694, 9516333619

Clinic Registration : CL/5392/Jun/2017

PNDT Registration : MPPCPNDT/BPL/2017/206



Name : Mrs.

Ravi Raj Yadav.

Age

45

Male

R/B

Health check up.

No.

Date

25/6/22

WHOLE ABDOMES ULTRASOUND REPORT

Indication:

Liver appears normal in size and shape with normal outline. ~~Normal/~~ increased parenchymal echogenicity is noted. No E/O focal lesion/ IHBR dilatation is seen. Hepatic veins and portal veins appear normal. *gr I*

Fatty liver

No E/O subdiaphragmatic Collection.

Gall Bladder is physiologically well distended. No E/O echogenic foci in GB lumen. GB wall is normal / ~~thickened~~. No E/O pericholecystic collection. Common duct reveals normal course and caliber.

Pancreas appear normal in size, shape and echo texture with smooth contour. No peripancreatic pathology seen. (~~Not seen due to gases~~)

Spleen is normal in size and echo texture.

IVC and aorta appear to be normal.

No evidence of lymphadenopathy is noted.

No evidence of free fluid is noted.

Right Kidney is normal in size, size, shape and position. Corticomedullary differentiation (CMD) is well maintained. Normal cortical thickness is noted. No E/O hydronephrosis or calculus is noted.

PTO

Dr. P. Savita, MD

MBBS, MD (O&G) Reg. No. 9971

स्त्री रोग विशेषज्ञ

Dr. Jayant Yadav, MD

MBBS, MD (Radiologist) Reg. No. 4166

रेडियोलॉजिस्ट

Left Kidney is normal in size, shape and position. CMD is well maintained. Normal cortical thickness is noted. No E/O hydronephrosis or calculus is noted.

Urinary Bladder is well distended (physiological). its contents are echo free. No E/O bladder wall thickening is noted. ~~Post void residue is insignificant.~~

Prostate is normal in size. Shape and echo texture with smooth outline. No E/O focal lesion is noted.

Uterus is ante/ retroverted and normal in size, shape and echo texture with smooth outline. No E/O focal lesion is noted. Endometrial echo appears normal. Cervical and vaginal shadows appear normal.

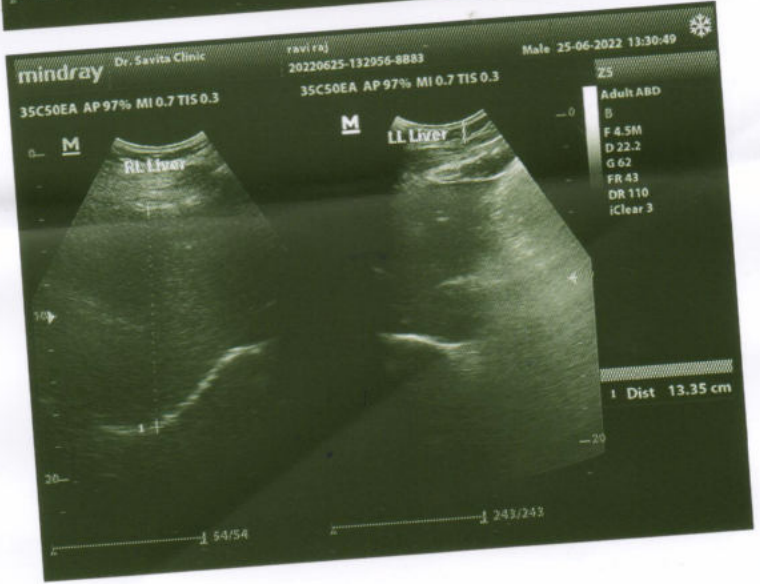
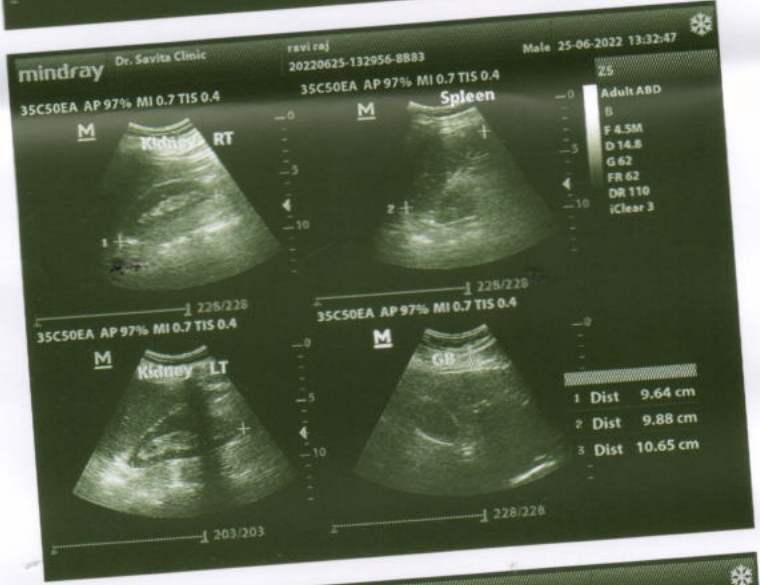
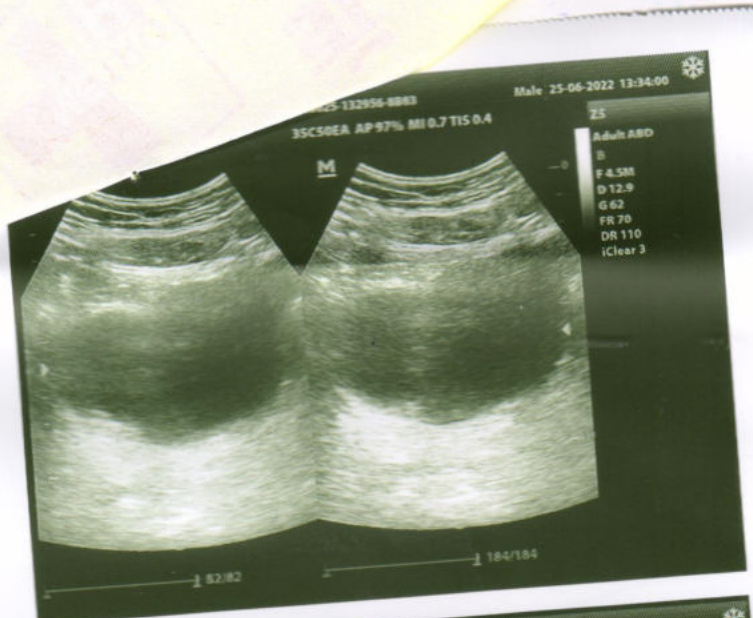
Right Ovary appears enlarged / Normal in size, shape and echo texture.

Left Ovary appears enlarged / Normal in size, shape and echo texture.

Impression : ~~Normal study.~~ *Grade I fatty liver.*

Advised clinical Correlation.

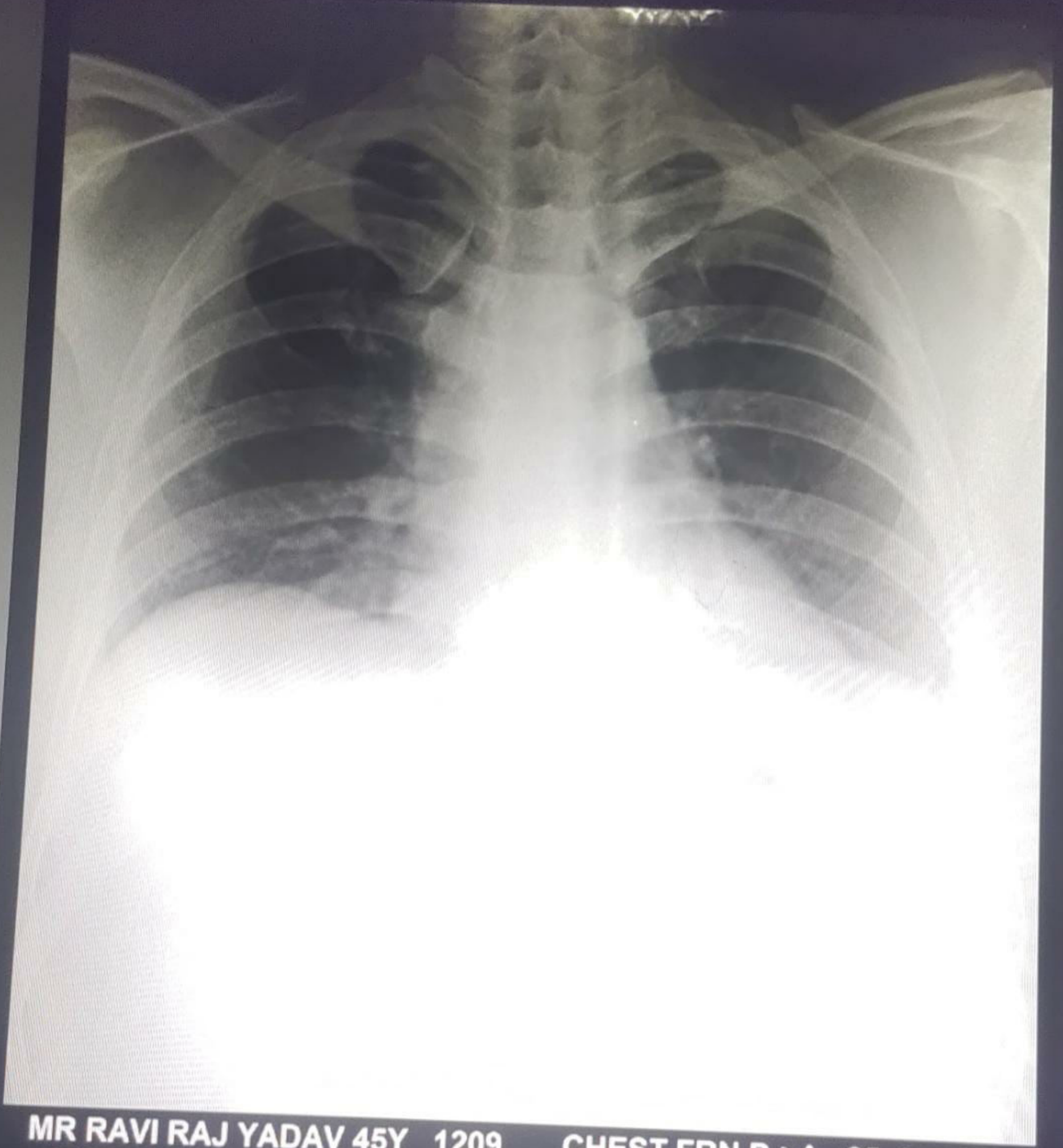
JY





Diwaka Diagnostic Centre

पेथोलोजी | टी.एम्.डी. | सी.जी. | एको कार्डियो ग्राफी | सोनोग्राफी



**MR RAVI RAJ YADAV 45Y 1209 CHEST,FRN P->A 25-Jun-22
DIWAKAR DIAGNOSTIC CENTRE , ARERA COLONY ,BHOPAL**