

DAKSH HOSPITAL

396 - 397, Gandhi Nagar, Scheme No. 8, ALWAR - 301001

Ref. No.

Date.....

MEDICAL EXAMINATION REPORT

Mediwheel (BOB)

Name: Mrs Neelam Yadav

Age: 36 yrs Sex: Female

Date: 08/04/2023

General Physical Examination

Height	:	168cm	Weight	74kg
Pulse	:	86/w	BP	120/80
Temp.	:	AF	Respiration	16/min
BMI	:	26.2		

Systemic Exam:- NORMALDental Check up :- NORMALEye check-up :- NORMALSkin Check up:- NORMALENT Check up:- NORMALGynae Check up:-NORMAL Cx Unhealthy
Cx 1st WTA VAF NIS FIM JfjuImpression:- NORMALRecommendation:-

COLPOSCOPY



Dr. Mukesh Kumar Gupta

MD Gen. Medicine

Reg. No 5423/16262

डॉ० मुकेश गुप्ता

M.D. F.C.C.S.

फिजिशियन एंव मधुमेह रोग विशेषज्ञ

दक्ष हॉस्पिटल, अलवर

रजि. नं.- 5423/16262

Results

Run Date 08/04/2023 11:05:12 AM

Operator DAKSH

Last Name

Sample ID 9

First Name MRS NEELAM YADAV

Department

Gender Female Age

Physician DR. MUKESH GUPTA M.D

Patient ID AUTO_PID12897

Type Woman

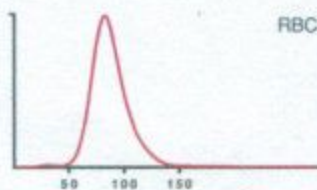
Date of birth

Sample comments


Susp. Pathologies

Anisocytosis

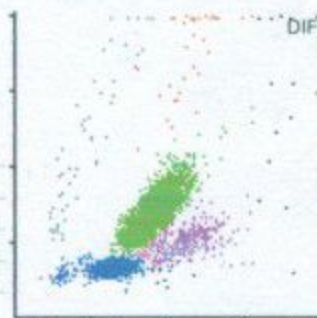
				Range
RBC	3.97	*	10 ⁶ /μL	3.80 - 5.50
HGB	10.9		g/dL	11.5 - 15.2
HCT	36.6	*	%	35.0 - 46.0
MCV	92.2	*	μm ³	77.0 - 97.0
MCH	27.6		pg	26.0 - 34.0
MCHC	29.9	L	g/dL	32.0 - 35.0
RDW-CV	17.6	H	%	11.0 - 17.0
RDW-SD	60.4	H	μm ³	37.0 - 49.0



				Range
PLT	201		10 ³ /μL	150 - 450
PCT	0.24		%	0.15 - 0.40
MPV	11.8	h	μm ³	8.0 - 11.0
PDW	22.2	h	μm ³	11.0 - 22.0
P-LCC	90		10 ³ /μL	44 - 140
P-LCR	45.0		%	18.0 - 50.0



				Range
WBC	7.89		10 ³ /μL	3.50 - 10.00
	#			
NEU	5.70		1.60 - 7.00	72.7
LYM	1.89		1.00 - 3.00	24.0
MON	0.14		0.20 - 0.80	1.7
EOS	0.06		0.00 - 0.50	0.7
BAS	0.07		0.00 - 0.15	0.9
LIC	0.03		0.00 - 0.10	0.3



डॉ० मुकेश गुप्ता

M.D. F.C.C.S.

फिजिशियन एवं मधुमेह रोग विशेषज्ञ

दक्ष हॉस्पिटल, अलवर

रजि. नं.- 5423/16252

Date :- 08/04/2023

Name :- MRS. NEELAM YADAV

Age & Sex :- 31 Yrs/ male

Refd. :- Dr Mukesh Gupta M.D.

	TEST NAME	RESULT	REFERENCE RANGE	
	ESR	12	00 -20 mm/hrs	
	Blood Group & Rh Factor	O * POSITIVE		
	HbA1C	4.9	4 - 5.6%	
	Blood Sugar (F)	77.2	< 70 - 100 mg/dl	
	Blood Sugar (PP)	110.1	< 140 mg/dl	
	Urine Sugar (F)	NIL	-	
	Urine Sugar (PP)	NIL	-	
LIVER	S.Bilirubin Total	1.20	0.30 - 1.20 mg/dl	
	S.Bilirubin Direct	0.40	0.10 - 0.30 mg/dl	
	S.Bilirubin Indirect	0.80	0.30 - 0.90 mg/dl	
	S.G.O.T.	24	u/l	
	S.G.P.T.	33	u/l	
	S.Alk. Phosp.	189	u/l	
	G.G.T.	25	5 -40 u/l	
	Total Protein	6.8	6.5 - 8.5 gm/dl	
	Albumin	3.8	3.8 - 5.4 gm/dl	
	Globulin	3.0	2.3 - 3.5 gm/dl	
	A/G Ratio	1.2	-	
AST/ALT Ratio	0.7	-		
KIDNEY	Blood Urea	25.4	15 -45 mg/dl	
	S.Creatinine	0.74	0.60 - 1.30 mg/dl	
	BUN	15.0	6 -24 mg/dl	
	S.Uric Acid	4.9	M 3.1 - 7.0, F 2.5 - 5.6 mg/dl	
	BUN/Creatinine Ratio	20.2	-	
LIPID PROFILE	Total Cholesterol	175.1	Up to 200 mg/dl	
	S.HDL	44.1	30 - 70 mg/dl	
	S.LDL	95.1	Up to 170 mg/dl	
	S.VLDL	26.1	5.0 - 40 mg/dl	
	S. Triglycerides	130.1	Up to 170 mg/dl	
	LDL/HDL Ratio	3.1	-	
	Total Cholesterol/ HDL Ratio	3.9	-	
THYROID	T3	99.2	1.2 - 2.8 nmol/L	
	T4	7.8	77 -155 nmol/L	
	TSH	2.79	0.30 - 5.0 mU/L	
URINE EXAMINATION			Microscopic Examination :	
General/Chemical Examination:	Colour	Pale Yellow	RBC	Absent
	Reaction	Acidic	WBC	1 - 2
	Specific Gravity	QNS	Epithelial Cells	0- 1
	Appearance	Clear	Cast	Absent
	Albumin	Nil	Crystal	Absent
	Sugar	Nil	Spermatozoa	Absent
			Amorphous Sediments	Absent
		Other	Absent	
X-RAY CHEST	NORMAL STUDY			
STOOL EXAMINATION			Microscopic Examination :	
General/ Chemical Examination:	Colour	-	RBC	-
	Consistency	-	WBC	-
	PH	-	Ova & Parasites	-
	Reddish Substances	-		

Dr. Mukesh Gupta
M.D. F.C.C.S.
फिजिशियन एवं मधुमेह रोग विशेषज्ञ

TECHNOLOGIST

All investigation done in the laboratory regarding the sensitivity & specificity of individual assay procedures, isolated laboratory investigations never confirm the final diagnosis of the disease. They only help in arriving at a diagnosis in conjunction with clinical presentation and other related investigations. Report is not valid for medico-legal purpose subject to ALWAR jurisdiction only.

Date :- 08/04/2023

Name :- Mrs Neelam Yadav

Age & Sex :- 36Yrs/ Female

Refd. :- Dr Mukesh Gupta MD

CYTO-PATHOLOGY

PAP SMEAR

1. Specimen type	Received two conventional smears.
2. Specimen adequacy	Smears are satisfactory for evaluation.
3. Microscopic finding	Smears are moderately cellular comprises of predominantly intermediate with mature superficial squamous epithelial cells arranged in clusters & scattered singly.
4. Inflammation	Not seen
5. Bacilli	Not seen
6. Endocervical cells	Not seen
7. Koilocytic changes	Not seen
8. Trichomonas	Not seen
9. Dysplasia	Nil
10. Neoplasia	Nil
11. Endometrial cells	Nil

Impression:- Negative for intraepithelial lesion or malignancy

डॉ० मुकेश गुप्ता

M.D. F.C.C.S.

फिजिशियन एवं मधुमेह रोग विशेषज्ञ

दक्ष हॉस्पिटल, अलवर

रजि. नं. 5/2/116257

Doctor**TECHNOLOGIST**

All investigation have their own limitations regarding the sensitivity & specificity of individual assay procedures, isolated laboratory investigations never confirm the final diagnosis of the disease. They only help in arriving at a diagnosis in conjunction with clinical presentation and other related investigations. Report is not valid for medico-legal purpose subject to ALWAR jurisdiction only.



दक्ष हॉस्पिटल

396, गाँधी नगर स्कीम नं.8, अलवर (राज०) ☎ 0144-2703340

Sonography / 2D Echo Cardiography / Doppler Report

NAME :- MRS NEELAM YADAV/F/36 YRS

8-Apr-23

BOB HEALTH CHECKUP

U.S.G. OF ABDOMEN & PELVIS

LIVER

Liver is normal in size shape with normal echo-texture. Intra hepatic biliary radicals Are not dilated. No evidence of focal or diffuse lesion.

GALL BLADDER

Gall bladder is normal.

PANCREAS

Pancreas is normal in size, shape & echo-texture. No evidence of focal or diffuse lesion. MPD not dilated.

SPLEEN

Normal in size with normal shape & echo- texture. Spleen vein is normal. No evidence of focal or diffuse lesion

KIDNEY

Both kidneys are normal.

URINARY BLADDER

UB is normal.

UTERUS:

Uterus is normal in size with homogenous echo-texture. Endometrial 5 mm in thickness & echo genicity
Cervix appear bulky & has neobothelian cyst.

OVARIES:

Both ovaries appear normal.

Advice- follow up/ hormonal study review at higher center for confirmation

Please correlate clinically. USG accuracy is 95 % due to technical limitations as well as inaccuracies inherent in the laboratory and statistical analysis biological process.
This report is not valid for medico-legal cases


DR. MUKESH KUMAR GUPTA
Physician & Sonologist
RM 5423/16262



"भ्रूण लिंग परीक्षण की शिकायत
104 टोल फ्री सेवा पर भी की
जा सकती है"

भ्रूण लिंग परीक्षण की शिकायत 104 टोल फ्री सेवा पर भी की जा सकती है।



दक्ष हॉस्पिटल

396, गाँधी नगर स्कीम नं.8, अलवर (राज०) ☎ 0144-2703340

Sonography / 2D Echo Cardiography / Doppler Report

2D/ ECHO REPORT

Name: - Smt. Neelam Yadav

Age: - 36 Yrs

Date: - 8-Apr-23

Reg. No.: - Alw/2009/04

BOB health checkup

PROCEDURES:

M-MODE/2D/DOPPLER/COLOR/CONTRAST B.A.S. M²

MEASUREMENT:		DOPPLER:	
AOD	28	NORMAL (20- 37mm)	NORMAL (cm/sec.)
LA	24	(19- 40mm)	MV 0.6 (0.8- 1.3) MR No
AVO	19	(12- 25mm)	AV 1.2 (1.2- 1.8) AR No
RVDd.	11	(03- 09mm)	TV 0.6 (0.3- 0.8) TR No
			PV 0.8 (0.7- 1.1) PR No
LV Dd	40	(37- 56mm)	MITRAL VALVE-
LV Ds	25	(22- 40mm)	AML Normal
IVS d	10	(06- 12mm)	PML Normal
IVS s	9		
PWd	6	(05- 10mm)	AORTIC VALVE Normal
LV FUNCTION		TV & PV are normal.	
M- E- S Separation		<0.9cm	
Minor		24.42%	
LV Ejection Fraction	70%	65 +/- 12%	

LV WALL MOTION: NO RWMA
ALL CARDIAC CHAMBERS ARE NORMAL
ALL VALVES ARE NORMAL
NO CLOT, VEGETATION, PERICARDIAL EFFUSION

FINAL DIAGNOSIS: NORMAL STUDY

Adv: - Follow up/ review at higher center for confirmation

Note:- Please Correlate clinically. Due to technical limitations as well as inaccuracies inherent in the laboratory and statistical analysis of biological process. Diagnostic accuracy of ECHO is up to 95% only.
Report is not valid for medico-legal purpose.

DR. MUKESH GUPTA
Physician & Sonologist
RM 5423/16282



"भ्रूण लिंग परीक्षण की शिकायत
104 टोल फ्री सेवा पर भी की

भ्रूण लिंग परीक्षण की शिकायत 104 टोल फ्री सेवा पर भी की जा सकती है।

ID: 584

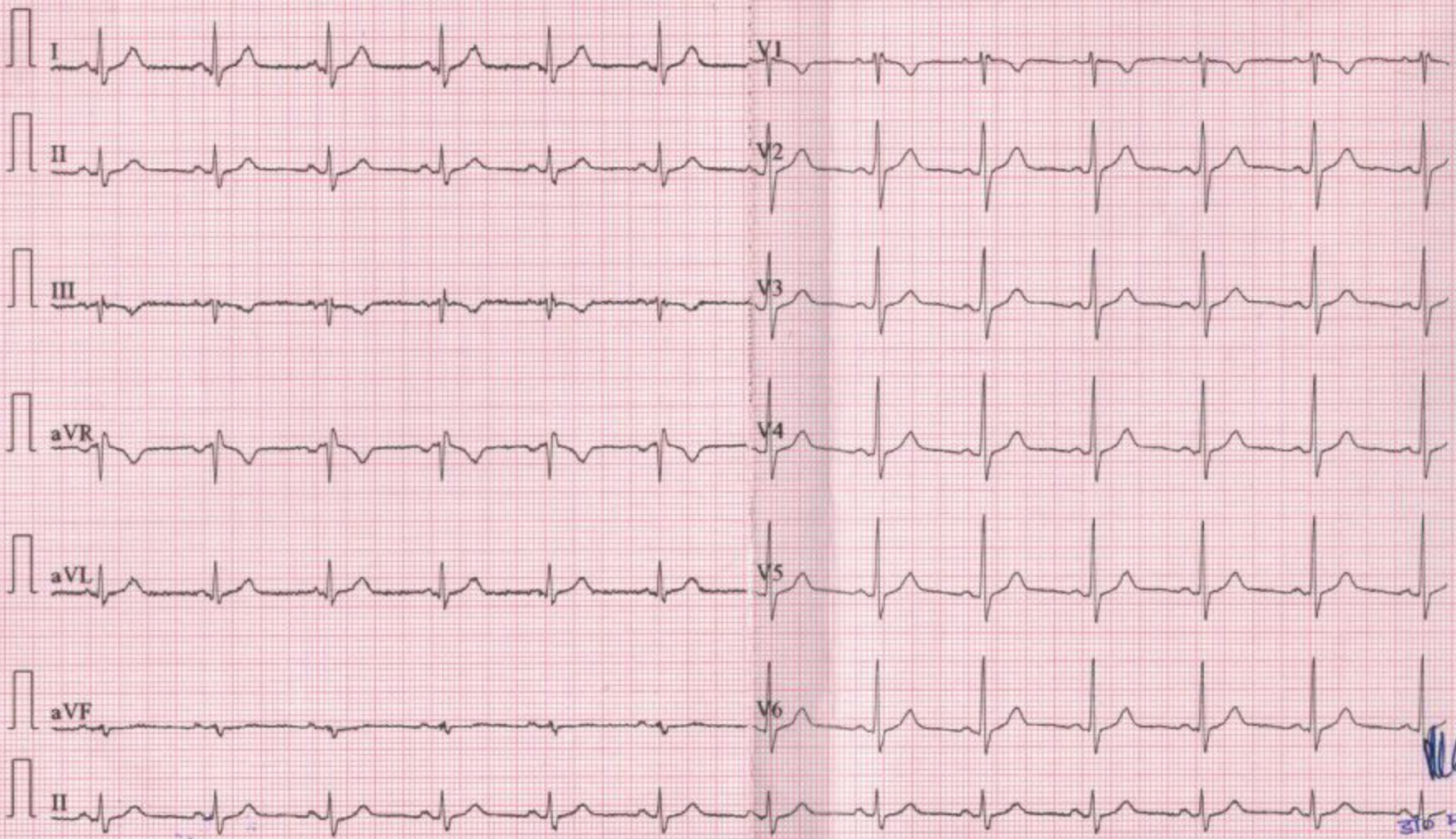
08-04-2023 13:44:09

Female Years
Req. No. :

HR : 76 bpm
 P : 104 ms
 PR : 130 ms
 QRS : 96 ms
 QT/QTcBz : 366/412 ms
 P/QRS/T : 22/1/4 °
 RV5/SV1 : 1.347/0.426 mV

Diagnosis Information:
 Sinus rhythm
 Normal ECG

Report Confirmed by:



डॉ० मुकेश गुप्त
 M.D. F.C.C.
 किजिशियन एव मधुमेह रोग
 दस हॉस्पिटल

R

