

CID#	: 2208524762	SID#	: 177400894973
Name	: MR.RITESH MANDAL	Registered	: 26-Mar-2022 / 08:41
Age / Gender	: 40 Years/Male	Collected	: 26-Mar-2022 / 08:41
Consulting Dr.	: -	Reported	: 27-Mar-2022 / 08:22
Reg.Location	: Kandivali East (Main Centre)	Printed	: 27-Mar-2022 / 15:01

PHYSICAL EXAMINATION REPORT

History and Complaints:

No

EXAMINATION FINDINGS:

Height (cms):	171 cms	Weight (kg):	81 kgs
Temp (0c):	Afebrile	Skin:	Normal
Blood Pressure (mm/hg):	130/80	Nails:	Normal
Pulse:	72/min	Lymph Node:	Not palpable

Systems

Cardiovascular: Normal
Respiratory: Normal
Genitourinary: Normal
GI System: Normal
CNS: Normal

IMPRESSION:

*↑ SGOT, SGPT
TMT - Stress test +ve for stress induced Ischemia
ECG - LVH
USA - fatty liver
- umbilical hernia*

ADVICE:

*Low fatty diet
Cardiologist
Surgical / opinion*

CID# : 2208524762 SID# : 177400894973
Name : MR.RITESH MANDAL Registered : 26-Mar-2022 / 08:41
Age / Gender : 40 Years/Male Collected : 26-Mar-2022 / 08:41
Consulting Dr. : - Reported : 27-Mar-2022 / 08:22
Reg.Location : Kandivali East (Main Centre) Printed : 27-Mar-2022 / 15:01

CHIEF COMPLAINTS:

- 1) Hypertension: No
- 2) IHD No
- 3) Arrhythmia No
- 4) Diabetes Mellitus No
- 5) Tuberculosis No
- 6) Asthama No
- 7) Pulmonary Disease No
- 8) Thyroid/ Endocrine disorders No
- 9) Nervous disorders No
- 10) GI system No
- 11) Genital urinary disorder No
- 12) Rheumatic joint diseases or symptoms No
- 13) Blood disease or disorder No
- 14) Cancer/lump growth/cyst No
- 15) Congenital disease No
- 16) Surgeries Right knee jt orthoscopy 20 yrs ago, Anal fissure 10 yrs ago
- 17) Musculoskeletal System No

PERSONAL HISTORY:

- 1) Alcohol No
- 2) Smoking No
- 3) Diet Mixed
- 4) Medication No

*** End Of Report ***

SUBURBAN DIAGNOSTICS (INDIA) PVT. LTD.
Row House No. 3, Aangan,
Thakur Village, Kandivali (east),
Mumbai - 400101.
Tel : 61700000


Dr. Jagruti Dhale
MBBS
Consultant Physician
Reg. No. 69548

ADDRESS: 2nd Floor, Aston, Sundervan Complex, Above Mercedes Showroom, Andheri West - 400053

HEALTHLINE - MUMBAI: 022-6170-0000 | **OTHER CITIES:** 1800-266-4343

Page:2 of 2

For Feedback - customerservice@suburbandiagnosics.com | **www.suburbandiagnosics.com**

DENTAL CHECK - UP

Name:- *Ritesh Mandal*

CID : *2208524762* Sex / Age : *M / 40*

Occupation:-

Date: *26/3/2022*

Chief complaints:- *No complaints*

Medical / dental history:- *No relevant history*

GENERAL EXAMINATION:

1) Extra Oral Examination:

- a) TMJ: *Normal movements*
- b) Facial Symmetry: *Bilateral symmetrical*

2) Intra Oral Examination:

- a) Soft Tissue Examination: *Ti missing*
 - b) Hard Tissue Examination:
 - c) Calculus: *+*
 - Stains: *+*
- Habits -> Tobacco / Pan chewer ???*

18	17	16	15	14	13	12	11	21	22	23	24	25	26	27	28
48	47	46	45	44	43	42	41	31	32	33	34	35	36	37	38

	Missing	#	Fractured
○	Filled/Restored	RCT	Root Canal Treatment
○	Cavity/Caries	RP	Root Piece


Advised: *a) Scaling & Polishing [Cleaning]*

Provisional Diagnosis:-

- NIL -

SUBURBAN DIAGNOSTICS (INDIA) PVT. LTD.
Row House No. 3, Aangan,
Thakur Village, Kandivali (east),
Mumbai - 400101.
Tel : 61700000

DR. BHUMIK PATEL
(B.D.S) A - 23378

Dr Bhumik Patel


ADDRESS: 2nd Floor, Aston, Sundervan Complex, Above Mercedes Showroom, Andheri West - 400053

HEALTHLINE - MUMBAI: 022-6170-0000 | OTHER CITIES: 1800-266-4343

For Feedback - customerservice@suburbandiagnosics.com | www.suburbandiagnosics.com

Date: - 26/3/22

CID: 2208524762

Name: - Mr. Ritesh Mandale

Sex/Age: m/40

EYE CHECK UP

Chief complaints: Routine checkup

Systemic Diseases: NO H/O STK

Past history: NO H/O Ocular sx long way

Unaided Vision: 6/6 6/6

Aided Vision: - -

Refraction: EOMB: Normal

	(Right Eye)				(Left Eye)			
	Sph	Cyl	Axis	Vn	Sph	Cyl	Axis	Vn
Distance	- plano	-	-	6/6	- plano	-	-	6/6
Near	+1.0	-	-	N/6	+1.0	-	-	N/6

Colour Vision: Normal / Abnormal

Remark: Vm within normal limit

Adv. progressive I w/gl EAR

Kajal H.
KAJAL NAGRECHA

SUBURBAN DIAGNOSTICS (INDIA) PVT. LTD. OPTOMETRIST
 Row House No. 3, Aangan,
 Thakur Village, Kandivali (east),
 Mumbai - 400101.
 Tel : 61700000

ADDRESS: 2nd Floor, Aston, Sundervan Complex, Above Mercedes Showroom, Andheri West - 400053

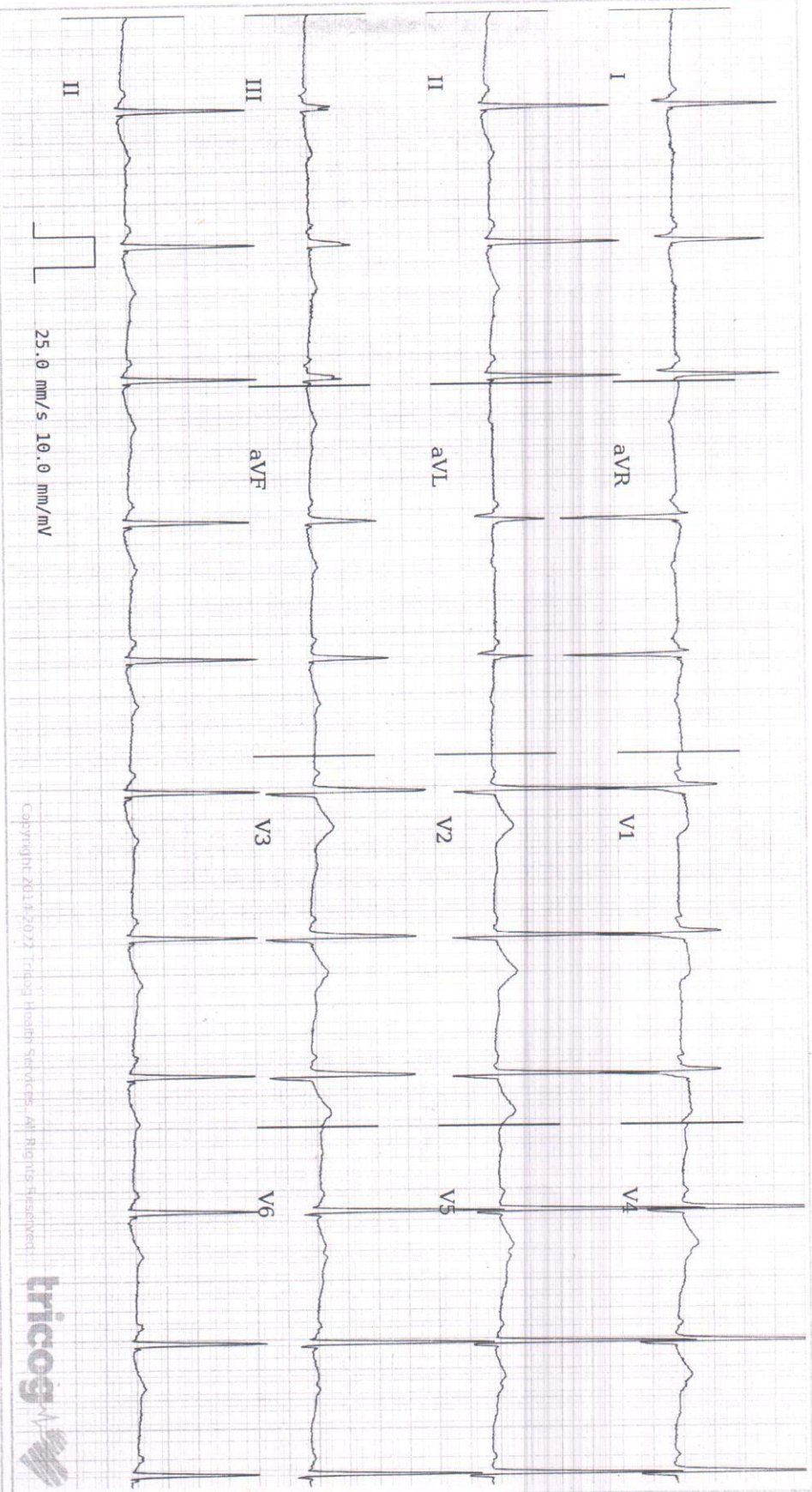
HEALTHLINE - MUMBAI: 022-6170-0000 | OTHER CITIES: 1800-266-4343

For Feedback - customerservice@suburbandiagnosics.com | www.suburbandiagnosics.com

SUBURBAN DIAGNOSTICS - KANDIVALI EAST

Patient Name: RITESH MANDAL
Patient ID: 2208524762

Date and Time: 26th Mar 22 9:18 AM



Age	40	11	21
	years	months	days
Gender	Male		
Heart Rate	67bpm		
Patient Vitals			
BP:	130/80 mmHg		
Weight:	81 kg		
Height:	171 cm		
Pulse:	NA		
Spo2:	NA		
Resp:	NA		
Others:			
Measurements			
QSRD:	86ms		
QT:	418ms		
QTc:	441ms		
PR:	108ms		
P-R-T:	33° 42° 58°		

Sinus Rhythm, Normal Axis, Left Ventricular Hypertrophy. Please correlate clinically.

SUBURBAN DIAGNOSTICS (INDIA) PVT. LTD.
Row House No. 3, Aangan,
Thakur Village, Kandivali (east),
Mumbai - 400101.
Tel : 61700000

REPORTED BY

DR AKHIL PARULEKAR
MBBS, MD, MEDICINE, DNB Cardiology
Cardiologist
2012082483

Disclaimer: 1) Analysis in this report is based on ECG alone and should be used as an adjunct to clinical history, symptoms, and results of other invasive and non-invasive tests and must be interpreted by a qualified physician. 2) Patient zials are as entered by the clinician and not derived from the ECG



CID#	: 2208524762	SID#	: 177400894973
Name	: MR.RITESH MANDAL	Registered	: 26-Mar-2022 / 08:41
Age / Gender	: 40 Years/Male	Collected	: 26-Mar-2022 / 08:41
Consulting Dr.	: -	Reported	: 26-Mar-2022 / 12:44
Reg.Location	: Kandivali East (Main Centre)	Printed	: 26-Mar-2022 / 15:29

X-RAY CHEST PA VIEW

The lung fields are clear with no parenchymal lesion.

The cardiothoracic ratio is maintained and the cardiac outline is normal

The domes of the diaphragm are normal.

The cardio and costophrenic angles are clear.

Bony thorax is normal.

IMPRESSION:

No significant abnormality detected.

*** End Of Report ***

Khilji F.R.A

Dr.Faizur Khilji
MBBS, Consultant Radiologist

ADDRESS: 2nd Floor, Aston, Sundervan Complex, Above Mercedes Showroom, Andheri West - 400053

HEALTHLINE - MUMBAI: 022-6170-0000 | OTHER CITIES: 1800-266-4343

For Feedback - customerservice@suburbandiagnosics.com | www.suburbandiagnosics.com

CID#	: 2208524762	SID#	: 177400894973
Name	: MR.RITESH MANDAL	Registered	: 26-Mar-2022 / 08:41
Age / Gender	: 40 Years/Male	Collected	: 26-Mar-2022 / 08:41
Consulting Dr.	: -	Reported	: 26-Mar-2022 / 10:11
Reg.Location	: Kandivali East (Main Centre)	Printed	: 26-Mar-2022 / 10:17

USG WHOLE ABDOMEN

LIVER :

The liver is normal in size, shape and smooth margins. It shows **bright** parenchymal echo pattern. The intra hepatic biliary and portal radical appear normal. No evidence of any intra hepatic cystic or solid lesion seen. The main portal vein and CBD appears normal.

GALL BLADDER :

The gall bladder is physiologically distended and appears normal. No evidence of gall stones or mass lesions seen

PANCREAS :

The pancreas is well visualised and appears normal. No evidence of solid or cystic mass lesion.

KIDNEYS :

Both the kidneys are normal in size shape and echotexture. No evidence of any calculus, hydronephrosis or mass lesion seen. Right kidney measures 10.5 x 4.5 cm. Left kidney measures 11.0 x 5.0 cm.

SPLEEN :

The spleen is normal in size and echotexture. No evidence of focal lesion is noted. There is no evidence of any lymphadenopathy or ascites.

URINARY BLADDER :

The urinary bladder is well distended and reveal no intraluminal abnormality.

PROSTATE :

The prostate is normal in size and volume is 22 cc.

Umbilical hernia noted. Defect measuring 3.9mm.

ADDRESS: 2nd Floor, Aston, Sundervan Complex, Above Mercedes Showroom, Andheri West - 400053

HEALTHLINE - MUMBAI: 022-6170-0000 | OTHER CITIES: 1800-266-4343

For Feedback - customerservice@suburbandiagnosics.com | www.suburbandiagnosics.com

CID#	: 2208524762	SID#	: 177400894973
Name	: MR.RITESH MANDAL	Registered	: 26-Mar-2022 / 08:41
Age / Gender	: 40 Years/Male	Collected	: 26-Mar-2022 / 08:41
Consulting Dr.	: -	Reported	: 26-Mar-2022 / 10:11
Reg.Location	: Kandivali East (Main Centre)	Printed	: 26-Mar-2022 / 10:17

IMPRESSION :

**Grade I fatty liver.
Umbilical hernia.**

Note: Investigations have their limitations. Solitary radiological investigations never confirm the final diagnosis. They only help in diagnosing the disease in correlation to clinical symptoms and other related tests. USG is known to have inter-observer variations. Further / Follow-up imaging may be needed in some cases for confirmation / exclusion of diagnosis. Patient was explained in detail verbally about the USG findings, USG measurements and its limitations. In case of any typographical error in the report, patient is requested to immediately contact the centre for rectification. Please interpret accordingly. All safety precautions were taken before, during and after the USG examination in view of the ongoing Covid 19 pandemic.

*** End Of Report ***

Khilji F.R.A
Dr.Faizur Khilji
MBBS, Consultant Radiologist

ADDRESS: 2nd Floor, Aston, Sundervan Complex, Above Mercedes Showroom, Andheri West - 400053

HEALTHLINE - MUMBAI: 022-6170-0000 | OTHER CITIES: 1800-266-4343

For Feedback - customerservice@suburbandiagnosics.com | www.suburbandiagnosics.com

बैंक ऑफ बड़ोदा
Bank of Baroda



नाम **रितेश कुमार मंडल**
 Name **Ritesh Kumar Mandal**

कर्मचारी कूट क्र. **72032**
 E.C. No. **72032**

जारीकर्ता प्राधिकारी
 Issuing Authority

भारत के इस्तेमाल
 Signature of Holder




[Handwritten Signature]

SUBERTAN DIAGNOSTICS (INDIA) PVT. LTD.
 Power House No. 3, Aangan,
 Thakur Village, Kandivalli (east),
 Mumbai - 400101.
 Tel : 61700000

[Handwritten Signature]

Dr. Jagruti Dharia
 Consultant Physiotherapist
 Reg. No. 69