

DR. NETRAVALKAR'S ASHWINI PATHOLOGY LABORATORY

(For all investigation in Histopathology, Cytopathology, Haematology, Clinical Pathology, Microbiology & Hormonal Chemistry)

Consultant Pathologist : **Dr. Prasad Netravalkar** MBBS, MD (Path) BOM

(HOME COLLECTION FACILITY AVAILABLE)

Panaji : 1st, Floor, Rizvi Sadan, Above Saroj Emporium, Near Inox Theatre, Opp. Municipal Market, Panaji.

Ph.: 2229142, 8407912840, 8390242524

E-mail : ashwinilabpanaji@gmail.com, drprasadnetravalkar@gmail.com

Mapusa : F8, Ramchandra Chambers, 1st Floor, Mapusa Clinic Road, Mapusa - Bardez, Goa. Ph. : 2252320, 2250709

Sanquelim : 1st floor, Shanta Commercial Complex, Sanquelim - Goa. Ph.: 2364524, 9067292714

Pt.No. : 63 100224

Pt.Name : Mr. Kelam Dileep

Age : 32 Yrs. Sex : M

Ref. By : -

Date : 10-02-2024

Normal Range

COMPLETE HEMOGRAM


| | | |
|--------------------|-------------------------|----------------------------|
| Haemoglobin | : 17.5 g/dl | 13.5 - 18 g/dl |
| W.B.C Count | : 5400 cells/ cu-mm | 4000 - 11000 cells/ cu-mm |
| R.B.C Count | : 5.17 millions / cu-mm | 4.5 - 6.5 millions / cu-mm |
| MCV | : 86.8 fl | 80 - 96 fl |
| MCH | : 33.9 Pg | 27 - 33 Pg |
| MCHC | : 39.1 % | 32 - 37 % |
| PCV | : 44.9 % | 40 - 54 % |
| Platelet Count | : 2.17 lakhs /cu mm | 1.5 - 4.5 lakhs /cu mm |
| E.S.R (Westergren) | : 10 mm/hr | 0 - 20 mm/hr |

DIFFERENTIAL COUNT

| | | |
|----------------|--------|-----------|
| Stab Cells | : 02 % | 1-5 % |
| Neutrophils | : 38 % | 40 - 60 % |
| Lymphocytes | : 52 % | 20 - 45 % |
| Eosinophils | : 04 % | 1 - 6 % |
| Monocytes | : 04 % | 0 - 10 % |
| Basophils | : 00 % | 0 - 1 % |
| Abnormal Cells | : Nil | |

SMEAR EXAMINATION

| | |
|--------------------|-----------------------------|
| RBC Morphology | : Normocytic , Normochromic |
| W.B.C Morphology | : Within Normal Limits |
| Platelets on Smear | : Adequate |
| Parasites | : Absent |
| Blood Group | : 'B' Rh Positive |



Pathologist

Dr. Prasad Netravalkar

MBBS, MD (Bom)

GMC Reg. No. 1294

We Care

All Diagnostic facilities under one roof in Panaji centre - Lab, ultrasound, X ray, ECG, TMT, ECHO

**DR. NETRAVALKAR'S
ASHWINI PATHOLOGY LABORATORY**

(For all investigation in Histopathology, Cytopathology, Haematology, Clinical Pathology, Microbiology & Hormonal Chemistry)

Consultant Pathologist : **Dr. Prasad Netravalkar** MBBS, MD (Path) BOM

(HOME COLLECTION FACILITY AVAILABLE)

Panaji : 1st, Floor, Rizvi Sadan, Above Saroj Emporium, Near Inox Theatre, Opp. Municipal Market, Panaji.
Ph.: 2229142, 8407912840, 8390242524

E-mail : ashwinilabpanaji@gmail.com, drprasadnetravalkar@gmail.com

Mapusa : F8, Ramchandra Chambers, 1st Floor, Mapusa Clinic Road, Mapusa - Bardez, Goa. Ph.: 2252320, 2250709

Sanquelim : 1st floor, Shanta Commercial Complex, Sanquelim - Goa. Ph.: 2364524, 9067292714

Pt.No. : 63 100224

Pt.Name : Mr. Kelam Dileep

Age : 32 Yrs. Sex : M


Ref. By : -

Date : 10-02-2024

Normal Range

LIPID PROFILE

| | | |
|-------------------|---------------|-----------------|
| Total Cholesterol | : 143.0 mg/dl | 130 - 220 mg/dl |
| S. Triglycerides | : 78.0 mg/dl | 35 - 170 mg/dl |
| HDL Cholesterol | : 38.0 mg/dl | > 35 mg/dl |
| LDL Cholesterol | : 89 mg/dl | < 130 mg/dl |
| VLDL Cholesterol | : 16 mg/dl | Upto 35 mg/dl |
| TC/HDL Ratio | : 3.8 | < 4.5 |
| LDLC/HDL Ratio | : 2.3 | 2.5 - 3.5 |



Handwritten signature of Dr. Prasad Netravalkar

Pathologist

Dr. Prasad Netravalkar
MBBS, MD (Bom)
GMC Reg. No. 1294

We Care

All Diagnostic facilities under one roof in Panaji centre - Lab, ultrasound, X ray, ECG, TMT, ECHO

DR. NETRAVALKAR'S ASHWINI PATHOLOGY LABORATORY

(For all investigation in Histopathology, Cytopathology, Haematology, Clinical Pathology, Microbiology & Hormonal Chemistry)

Consultant Pathologist : **Dr. Prasad Netravalkar** MBBS, MD. (Path) BOM

(HOME COLLECTION FACILITY AVAILABLE)

Panaji : 1st, Floor, Rizvi Sadan, Above Saroj Emporium, Near Inox Theatre, Opp. Municipal Market, Panaji.
Ph.: 2229142, 8407912840, 8390242524

E-mail : ashwinilabpanaji@gmail.com, drprasadnetravalkar@gmail.com

Mapusa : FS, Ramchandra Chambers, 1st Floor, Mapusa Clinic Road, Mapusa - Bardez, Goa. Ph.: 2252320, 2250709

Sanquelim : 1st floor, Shanta Commercial Complex, Sanquelim - Goa. Ph.: 2364524, 9067292714

Pt.No. : 63 100224

Pt.Name : Mr. Kelam Dileep

Age : 32 Yrs. Sex : M

Ref. By : -

Date : 10-02-2024

| | | Normal Range |
|---------------------|---------------|----------------|
| Fasting Blood Sugar | : 90.0 mg/dl | 70 - 110 mg/dl |
| 2 Hrs. Blood Sugar | : 101.0 mg/dl | 110 -140 mg/dl |

GLYCOSYLATED HAEMOGLOBIN IN BLOOD (HPLC METHOD)

HbA1C : 5.40 %

Mean Blood Glucose : 107 mg %

INTERPRETATION:

HbA1c %

NORMAL

Below 6.5 %

GOOD DIABETIC CONTROL

6.5 % - 7.5 %

FAIR CONTROL

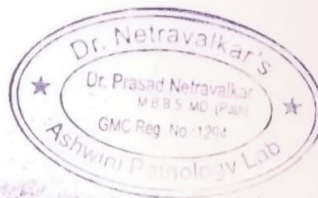
7.5 % - 8.0 %

UNSATISFACTORY CONTROL

8.0 % - 10.0 %

POOR CONTROL

Above 10.0 %



(Signature)
Pathologist

Dr. Prasad Netravalkar
MBBS, MD (Bom)
GMC Reg. No. 1294

We Care

All Diagnostic facilities under one roof in Panaji centre - Lab, ultrasound, X ray, ECG, TMT, ECHO

DR. NETRAVALKAR'S ASHWINI PATHOLOGY LABORATORY

(For all investigation in Histopathology, Cytopathology, Haematology, Clinical Pathology, Microbiology & Hormonal Chemistry)

Consultant Pathologist **Dr. Prasad Netravalkar** MBBS, MD (Path) BOM

(HOME COLLECTION FACILITY AVAILABLE)

Panaji : 1st, Floor, Rizvi Sadan, Above Saroj Emporium, Near Inox Theatre, Opp. Municipal Market, Panaji.
Ph.: 2229142, 8407912840, 8390242524

E-mail : ashwinilabpanaji@gmail.com, drprasadnetravalkar@gmail.com

Mapusa : F8, Ramchandra Chambers, 1st Floor, Mapusa Clinic Road, Mapusa - Bardez, Goa. Ph.: 2252320, 2250709

Sanquelim : 1st floor, Shanta Commercial Complex, Sanquelim - Goa Ph.: 2364524, 9067292714

Pt.No. : 63 100224

Pt.Name : Mr. Kalam Dileep

Age : 32 Yrs. Sex : M


Ref. By : -

Date : 10-02-2024

Normal Range

LIVER FUNCTION TEST

| | | | |
|-------------------------|-----------|-------|-----------------|
| S. Bilirubin (Total) | : 0.61 | mg/dl | 0 - 1 mg/dl |
| S. Bilirubin (Direct) | : 0.20 | mg/dl | 0 - 0.25 mg/dl |
| S. Bilirubin (Indirect) | : 0.41 | mg/dl | 0 - 0.75 mg/dl |
| S.G.O.T | : 17.0 | U/L | 0 - 42 U/L |
| S.G.P.T | : 16.0 | U/L | 0 - 42 U/L |
| S. Alkaline Phosphatase | : 52.0 | IU/L | 15 - 112 IU/L |
| GGTP | : 24.0 | U/L | 11-43 U/L |
| Total Proteins | : 6.80 | g/dl | 6.0 - 10.0 g/dl |
| S. Albumin | : 3.91 | gm% | 3.2 - 5.5 gm% |
| S. Globulin | : 2.9 | g/dl | 2.3 - 3.5 g/dl |
| A/G Ratio | : 1.4 : 1 | | |



Pathologist

Dr. Prasad Netravalkar

MBBS, MD (Bom)

GMC Reg. No. 1294

We Care

All Diagnostic facilities under one roof in Panaji centre - Lab, ultrasound, X ray, ECG, TMT, ECHO

DR. NETRAVALKAR'S ASHWINI PATHOLOGY LABORATORY

(For all investigation in Histopathology, Cytopathology, Haematology, Clinical Pathology, Microbiology & Hormonal Chemistry)

Consultant Pathologist - **Dr. Prasad Netravalkar** MBBS, MD (Path) BOM

(HOME COLLECTION FACILITY AVAILABLE)

Panaji : 1st, Floor, Rizvi Sadan, Above Saroj Emporium, Near Inox Theatre, Opp. Municipal Market, Panaji.
Ph.: 2229142, 8407912840, 8390242524

E-mail : ashwinilabpanaji@gmail.com, drprasadnetravalkar@gmail.com

Mapusa : FS, Ramchandra Chambers, 1st Floor, Mapusa Clinic Road, Mapusa - Bardez, Goa. Ph.: 2252320, 2250709

Sanquelim : 1st floor, Shanta Commercial Complex, Sanquelim - Goa. Ph.: 2364524, 9067292714

Pt.No. : 63 100224

Pt.Name : Mr. Kelam Dileep

Age : 32 Yrs. Sex : M

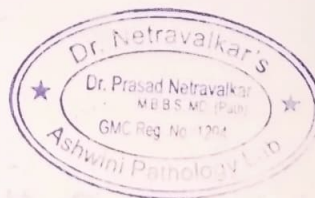
Ref. By : -


Date : 10-02-2024

Normal Range

KIDNEY FUNCTION TESTS

| | | |
|---------------|---------------|-----------------|
| Blood Urea | : 27.0 mg/dl | 15 - 40 mg/dl |
| S. Creatinine | : 0.73 mg/dl | 0.7 - 1.4 mg/dl |
| S. Uric Acid. | : 5.10 mg/dl | 2.5-7.5 mg/dl |
| S. Sodium | : 141.6 mEq/L | 135 - 155 mEq/L |
| S. Potassium | : 3.81 mEq/L | 3.5 - 5.5 mEq/L |
| S. Chlorides | : 100.2 mEq/L | 99 - 108 mEq/L |




Pathologist

Dr. Prasad Netravalkar
MBBS, MD (Bom)
GMC Reg. No. 1294

We Care

All Diagnostic facilities under one roof in Panaji; centre - Lab, ultrasound, X ray, ECG, TMT, ECHO

**DR. NETRAVALKAR'S
ASHWINI PATHOLOGY LABORATORY**

(For all investigation in Histopathology, Cytopathology, Haematology, Clinical Pathology, Microbiology & Hormonal Chemistry)

Consultant Pathologist : **Dr. Prasad Netravalkar** MBBS, MD (Path) BOM

(HOME COLLECTION FACILITY AVAILABLE)

Panaji : 1st, Floor, Rizvi Sadan, Above Saroj Emporium, Near Inox Theatre, Opp. Municipal Market, Panaji.
Ph.: 2229142, 8407912840, 8390242524

E-mail : ashwinilabpanaji@gmail.com, drprasadnetravalkar@gmail.com

Mapusa : F8, Ramchandra Chambers, 1st Floor, Mapusa Clinic Road, Mapusa - Bardez, Goa. Ph : 2252320, 2250709

Sanquelim : 1st floor, Shanta Commercial Complex, Sanquelim - Goa. Ph.: 2364524, 9067292714

Pt.No. : 63 100224

Pt.Name : Mr. Kelam Dileep

Ref. By : -

Age : 32 Yrs. Sex : M

Date : 10-02-2024

BIOCHEMISTRY REPORTS

Fasting Urine Glucose : Absent

2 Hrs. Urine Glucose : Absent



Pathologist

Dr. Prasad Netravalkar
MBBS, MD (Bom)
GMC Reg. No. 1294

We Care

All Diagnostic facilities under one roof in Panaji centre - Lab, ultrasound, X ray, ECG, TMT, ECHO

DR. NETRAVALKAR'S ASHWINI PATHOLOGY LABORATORY

(For all investigation in Histopathology, Cytopathology, Haematology, Clinical Pathology, Microbiology & Hormonal Chemistry)

Consultant Pathologist: **Dr. Prasad Netravalkar** MBBS, MD (Path) BOM

(HOME COLLECTION FACILITY AVAILABLE)

Panaji : 1st. Floor, Rizvi Sadan, Above Saroj Emporium, Near Inox Theatre, Opp. Municipal Market, Panaji.
Ph.: 2229142, 8407912840, 8390242524

E-mail : ashwinilabpanaji@gmail.com, drprasadnetravalkar@gmail.com

Mapusa : FS, Ramchandra Chambers, 1st Floor, Mapusa Clinic Road, Mapusa - Bardez, Goa. Ph.: 2252320, 2250709

Sanquelim : 1st floor, Shanta Commercial Complex, Sanquelim - Goa. Ph.: 2364524, 9067292714

Pt.No. : 63 100224

Pt.Name : Mr. Kelam Dileep

Ref. By : -

Age : 32 Yrs. Sex : M

Date : 10-02-2024

EXAMINATION OF URINE

PHYSICAL EXAMINATION

Quantity : 20 ml
Colour : Pale Yellow
Appearance : Slightly Hazy
pH : 6.5
Specific Gravity : 1.010

CHEMICAL EXAMINATION

Proteins : Absent
Glucose : Absent
Ketone Bodies : Absent
Bile Salts : Absent
Bile Pigments : Absent
Occult Blood : Negative
Urobilinogen : Normal

MICROSCOPIC EXAMINATION [As per hpf]

Epithelial Cells : 0 - 1 /hpf
Pus Cells : 2 - 4 /hpf
Red Blood Cells : Absent
Casts : Absent
Crystals : Absent

OTHER FINDINGS

Bacteria : Present (+)



[Handwritten Signature]
Pathologist

Dr. Prasad Netravalkar
MBBS, MD (Bom)
GMC Reg. No. 1294

We Care

All Diagnostic facilities under one roof in Panaji centre - Lab, ultrasound, X ray, ECG, TMT, ECHO

**DR. NETRAVALKAR'S
ASHWINI PATHOLOGY LABORATORY**

(For all investigation in Histopathology, Cytopathology, Haematology, Clinical Pathology, Microbiology & Hormonal Chemistry)

Consultant Pathologist **Dr. Prasad Netravalkar** MBBS, MD (Path) BOM

(HOME COLLECTION FACILITY AVAILABLE)

Panaji : 1st, Floor, Rizvi Sadan, Above Saroj Emporium, Near Inox Theatre, Opp. Municipal Market, Panaji.
Ph.: 2229142, 8407912840, 8390242524

E-mail : ashwinilabpanaji@gmail.com, drprasadnetravalkar@gmail.com

Mapusa : F8, Ramchandra Chambers, 1st Floor, Mapusa Clinic Road, Mapusa - Bardez, Goa. Ph.: 2252320, 2250799

Sanquelim : 1st floor, Shanta Commercial Complex, Sanquelim - Goa. Ph.: 2364524, 9067292714

Patient Name : MR. KELAM DILEEP

Age / Gender : 32 / Male

Patient ID : 30645

Source : DIRECT

Referral : SELF

Reporting Time : Feb 10, 2024, 02:28 p.m.

Sample ID :



| Test Description | Value(s) | Reference Range | Unit |
|--|----------|-----------------|--------|
| Thyroid Profile | | | |
| T3 (Total) Method : Serum ECL | 1.83 | 1.30 - 3.10 | nmol/l |
| T4 (Total)* Method : Serum ECL | 93.50 | 66.0 - 181.0 | nmol/l |
| TSH(Ultrasensitive)* Method : Serum ECL | 3.51 | 0.270 - 4.20 | uIU/ml |

END OF REPORT



Pathologist

Dr. Prasad Netravalkar
MBBS, MD (Bom)
GMC Reg. No. 1294

We Care

All Diagnostic facilities under one roof in Panaji centre - Lab, ultrasound, X ray, ECG, TMT, ECHO

CERTIFICATE OF MEDICAL FITNESS

This is to certify that I have conducted the clinical examination

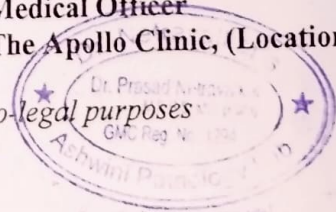
of Kelam Dileep on 10/2/24

After reviewing the medical history and on clinical examination it has been found that he/she is

| | Tick |
|--|-------------------------------------|
| <ul style="list-style-type: none">• Medically Fit | <input checked="" type="checkbox"/> |
| <ul style="list-style-type: none">• Fit with restrictions/recommendations <p>Though following restrictions have been revealed, in my opinion, these are not impediments to the job.</p> <p>1.....</p> <p>2.....</p> <p>3.....</p> <p>However the employee should follow the advice/medication that has been communicated to him/her.</p> <p>Review after _____</p> | |
| <ul style="list-style-type: none">• Currently Unfit. <p>Review after _____ recommended</p> | |
| <ul style="list-style-type: none">• Unfit | |


Dr. [Signature]
Medical Officer
The Apollo Clinic, (Location)

This certificate is not meant for medico-legal purposes







MER- MEDICAL EXAMINATION REPORT

| | |
|---|-------------------------|
| Date of Examination | 10/2/24 |
| NAME | Kelam Dileep |
| AGE | 32 |
| Gender | male |
| HEIGHT(cm) | 173 |
| WEIGHT (kg) | 65 |
| B.P. | 126/86 mmHg |
| ECG | normal |
| X Ray | normal |
| Vision Checkup | Color Vision : Normal |
| | Far Vision Ratio : 6/6 |
| | Near Vision Ratio : 6/6 |
| Present Ailments | - No - |
| Details of Past ailments (If Any) | - No - |
| Comments / Advice : She /He is Physically Fit | He is Physically Fit |



Signature With Stamp of Medical Ex





Name / नाम
Kelam Dilip
 Date of Birth / DOB / 03/07/1992
 Gender / MALE

9055 3194 0154

मेरा आधार, मेरी पहचान

Kelam Dilip




[Handwritten Signature]

4 PM



GPS Map Camera



Google

Panaji, Goa, India
B 165, New Municipal Market, Panaji, Goa 403001, India
Lat 15.498482°
Long 73.82239°
10/02/24 09:08 AM GMT +05:30

Dr. Prasad M. Patil
 MD
 UG No 12-4
 Anand Medical Lab

201,202,203, Rizvi Sadan, 2nd Floor, Near Municipal Market, Next to Vaidya Hospital, Panaji - Goa.
Tel.: 0832 2238122 | Email : drashanetravalkar@gmail.com

NAME: MRS.KELAM VANI
AGE: 29/YRS
REF BY: DR.SELF

DATE: 10/02/2024
SEX: F

X-RAY CHEST--- PA VIEW

Lung fields are clear.

Both costophrenic angles are clear.


Cardiac size is normal

Both domes of diaphragm are normal.

Rib cage is normal.

IMPRESSION : Normal study

With regards,



RADIOLOGIST

DR.ASHADEVI NETRAVALKAR,MD

DR. ASHADEVI NETRAVALKAR

MBBS, MD, AFIP

Consultant Radiologist

2nd Floor, Rizvi Sadan Panaji

Tel.: 0832-2238122 | 9822125224..

201,202,203, Rizvi Sadan, 2nd Floor, Near Municipal Market, Next to Vaidya Hospital, Panaji - Goa.
Tel.: 0832 2238122 | Email : drashanetravalkar@gmail.com

NAME: MRS.KELAM VANI
AGE: 29/YRS
REF BY: DR.SELF

DATE: 10/02/2024
SEX: F

ULTRASONOGRAPHY OF ABDOMEN AND PELVIS

LIVER – It shows normal echotexture and size. No focal lesions are seen. Intrahepatic biliary and portal radicals appear normal. Length of liver is 12.8cm.PV -8mm.

PANCREAS— It shows normal echotexture and size. No focal lesions are seen.

GALL BLADDER---It is moderately distended. No calculus is seen. Pericholecystic space is normal.CBD is normal.

SPLEEN----- It shows normal echotexture and size. Length of spleen is 9.2cm.

BOTH KIDNEYS Both kidneys show normal echotexture and size. Perirenal space is normal.

Corticomedullary differentiation is seen well .No calculus or hydronephrosis is seen .

Right kidney--measures 10.5cm x 3.6cms .

Left kidney—measures 10.5cms x3.6cms.

Urinary Bladder is well distended .No calculus and mass is seen.Both vesicoureteric junctions are normal.

UTERUS : It is anteverted and It measures 7.2cms x4.7cms x 2.6cms.

Myometrium shows normal echotexture .No mass is seen.

Endometrial thickness is 6mm.

Both ovaries show multiple follicles measuring 2mm-10mm at the periphery .


Right ovary—measures 4.2cms x 2.5cms x1.3cms. Volume is 7ml

Left ovary -measures 4.1cms x 2.6cms x1.3cms. Volume is 8ml

No adnexal mass is seen. No free fluid is seen in pelvis. Plenty of bowel gases are seen.

Impression: Multicystic ovaries.

With regards,



DR.ASHADEVINETRAVALKAR,MD
RADIOLOGIST

DR. ASHADEVI NETRAVALKAR
MBBS, MD, AFIH
Consultant Radiologist
2nd Floor, Rizvi Sadan Panaji

201,202,203, Rizvi Sadan, 2nd Floor, Near Municipal Market, Next to Vaidya Hospital, Panaji - Goa.
Tel: 0832 2238122 | Email: drashanetravalkar@gmail.com

Cardiology Report

Page 1/2

ASHWINI LABORATORY

Patient / Exam Information

Date of Exam 10.02.2024

Patient ID VS8802280-24-02-10-4
Name KELAM DILEEP 32
DOB Age
Sex Other
Height
Weight
BSA
HR

Perf. Phys. Ref. Phys. Sonographer
Comment Indication

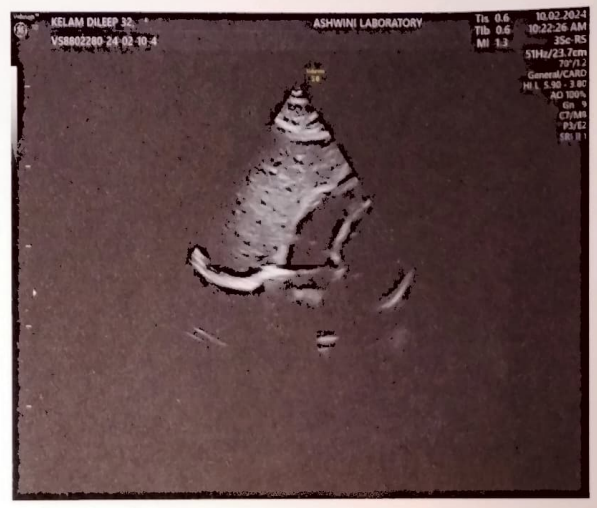
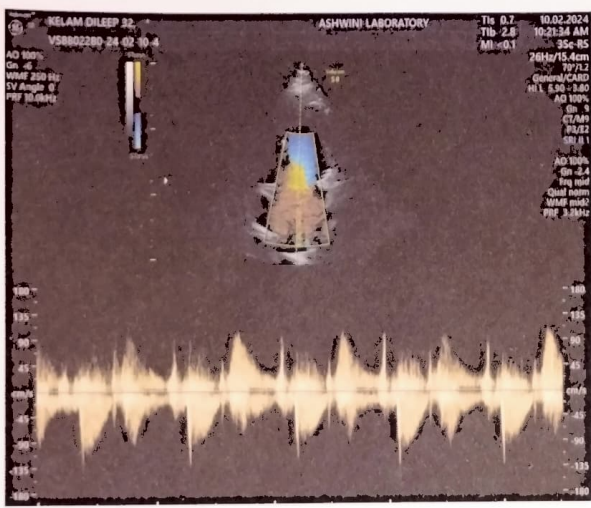
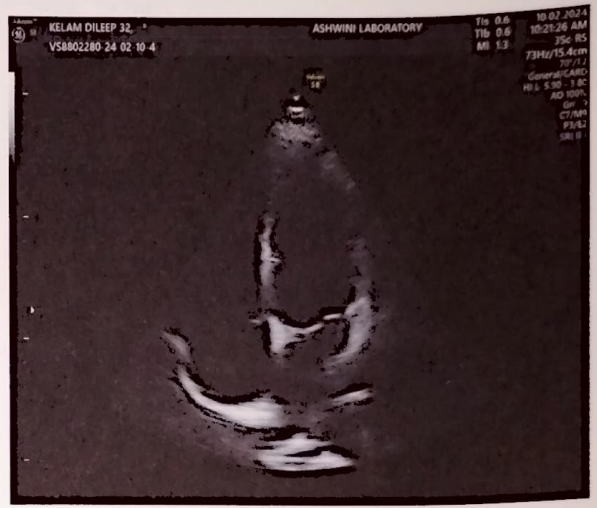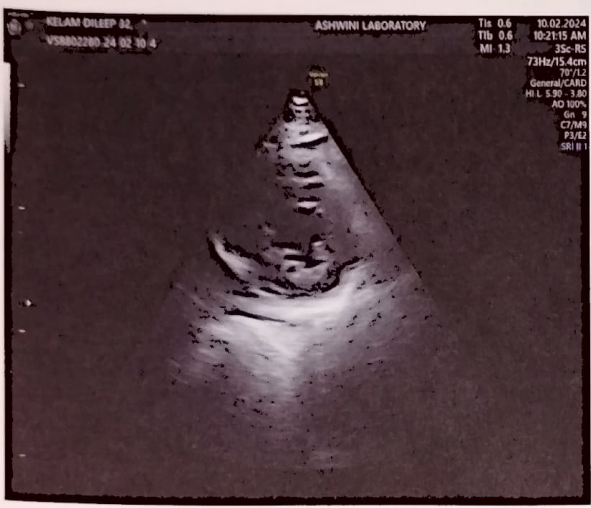
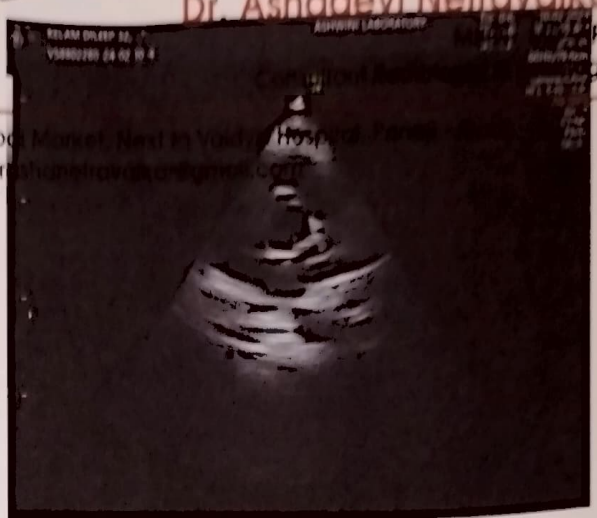
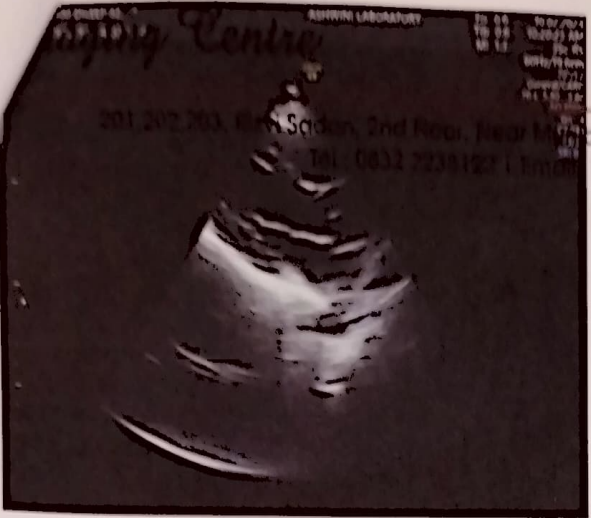| M-Mode Measurements | Value | m1 | m2 | m3 | m4 | m5 | m6 | Meth |
|-----------------------|-----------|--------|----|----|----|----|----|------|
| AV/LA | | | | | | | | |
| Ao Root Diam. | 2.65 cm | 2.65 | | | | | | avg. |
| LA Diam. | 2.55 cm | 2.55 | | | | | | avg. |
| Left Ventricle | | | | | | | | |
| IVSd | 0.95 cm | 0.95 | | | | | | avg. |
| LVDd | 3.54 cm | 3.54 | | | | | | avg. |
| LVPWd | 1.05 cm | 1.05 | | | | | | avg. |
| IVSs | 1.30 cm | 1.30 | | | | | | avg. |
| LVDs | 2.55 cm | 2.55 | | | | | | avg. |
| LVPWs | 1.30 cm | 1.30 | | | | | | avg. |
| EDV (Teich) | 52.278 ml | 52.278 | | | | | | |
| EDV (Cubed) | 44.362 ml | 44.362 | | | | | | |
| ESV (Teich) | 23.448 ml | 23.448 | | | | | | |
| ESV (Cubed) | 16.581 ml | 16.581 | | | | | | |
| SV (Teich) | 28.830 ml | 28.830 | | | | | | |
| SV (Cube) | 27.781 ml | 27.781 | | | | | | |
| EF (Teich) | 55.15 % | 55.15 | | | | | | |
| EF (Cube) | 62.62 % | 62.62 | | | | | | |
| Fract. Short. | 27.97 % | 27.97 | | | | | | |
| LV Mass | 117.10 g | 117.10 | | | | | | |

Comment

NORMAL CARDIAC CHAMBERS DIMENSIONS. NORMAL BI VENTRICLE SYSTOLIC FUNCTION. NO REGIONAL WALL MOION ABNORMALITIES. VALVES ARE NORMAL. AORTIC ROOT IS NORMAL PERICARDIUM IS NORMAL.

Ane Lone

1/2
10.02.2024 10:24:05 AM



Dr. Netravalkar's Imaging Centre

Dr. Ashadevi Netravalkar

MBBS., MD, AFIH

Consultant Radiologist & Sonologist

Name : Dileep Kelam
Age : 32 M/F M Date : 10.02.24
Investigation : ECG
Ref. by Dr. : _____

201,202,203

2nd Floor, Near Municipal Market,
Hospital, Panaji - Goa.

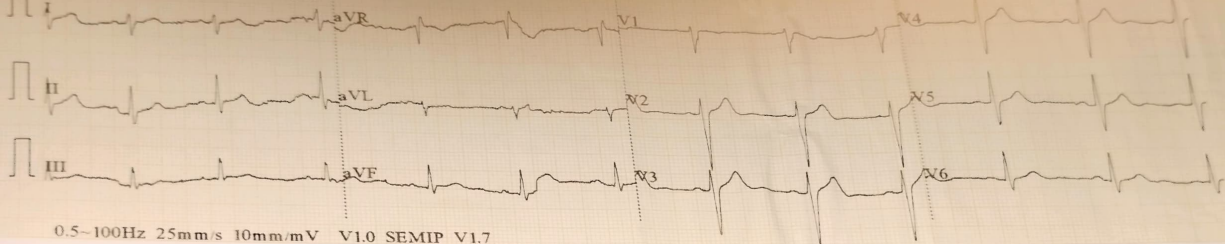
Tel.: 0832 2

Mail : drashanetravalkar@gmail.com

Timing : 8.00

to 1.00 pm | 4.00 pm to 7.00 pm

ID: 4141 10-02-2024 11:53:18



0.5-100Hz 25mm/s 10mm/mV V1.0 SEMIP V1.7

ID: 4141


male / mmHg
 32 Years
 cm kg

K. Nilesh

HR : 70 bpm
 P : 96 ms
 PR : 154 ms
 QRS : 89 ms
 QT/QTc : 357/387 ms
 P/QRS/T : 53/103/65 °
 RV5/SV1 : 0.844/0.581 mV

ECG Normal

10/2/24



DR.